

Izoenzimi alkalne fosfataze u djece s respiracijskim bolestima

Alkaline phosphatase isoenzymes in children with respiratory diseases

Slavica Dodig¹, Jadranka Demirović², Žaneta Jelčić¹, Darko Richter¹, Ivana Čepelak³, Miljenko Raos¹, Rajka Petrinović², Kornelija Kovač¹, Nina Peruško Matasić¹

¹Dječja bolnica Srebrnjak, Zagreb

¹Srebrnjak Children's Hospital, Zagreb, Croatia

²Medicinsko-biokemijski laboratorij, Klinika za tumore, Zagreb

²Clinical Laboratory, University Hospital for Tumors, Zagreb, Croatia

³Zavod za medicinsku biokemiju i hematologiju, Farmaceutsko-biokemijski fakultet Sveučilišta u Zagrebu, Zagreb

³Department of Medical Biochemistry and Hematology, School of Pharmacy and Biochemistry, University of Zagreb, Zagreb, Croatia

Sažetak

Cilj:0 Prikazati elektroforetsku sliku izoenzima ALP u serumu dojenčadi i djece koja su u tijeku akutne respiracijske bolesti imala povećanu ukupnu katalitičku aktivnost ALP.

Ispitanici i metode: Prikazani su rezultati u 21 djeteta (od toga 17 dojenčadi), 8 djevojčica i 13 dječaka, u dobi od 2 mjeseca do 8 godina, hospitaliziranih zbog respiracijskih bolesti. U serumu djece određena je ukupna katalitička aktivnost ALP i provedeno elektroforetsko razdvajanje izoenzima ALP.

Rezultati: Osmoro djece (38,1%) je u tijeku hospitalizacije imalo povećanu ukupnu katalitičku aktivnost ALP (raspon od 528 do 5622 U/L). Tipičnu sliku benigne prolazne hiperfosfatazemije, koja podrazumijeva pojavu brze anodne frakcije (brža od jetrene frakcije) i tzv. katodne frakcije (brža od koštane frakcije), imalo je petero djece. Izoenzim nalik placentalom izoenzimu izdvojio se u dvoje djece. Izraženu koštanu frakciju, ali i frakciju nalik placentaloj imalo je dijete s rahitisom. Predjetreni oblik ALP otkriven je kod dvoje djece, a jetreni izoenzim u jednog djeteta.

Zaključak: Akutna respiracijska bolest u dojenčadi i djece može imati za posljedicu prolazno povećanje katalitičke aktivnosti ALP odnosno pojavu različitih izoenzimskih vrpca, primjerice brze anodne i tzv. katodne frakcije (kod prolazne hiperfosfatazemije), predjetrene frakcije i frakcije koja odgovara placentalom izoenzimu. Prolazna hiperfosfatazemija se dokazuje nakon što se ukupna aktivnost ALP značajno smanji odnosno vrati u referentne raspone unutar 3-4 mjeseca. U tom slučaju daljnje analize nisu potrebne.

Ključne riječi: alkalna fosfataza, dijete, dojenče, hiperfosfatazemija, izoenzimi, respiracijske bolesti

Summary

Aim: To present the electrophoretic pattern of alkaline phosphatase (ALP) isoenzymes in serum of infants and children exhibiting increased total ALP catalytic activity in the course of acute respiratory disease.

Subjects and methods: Results obtained in 21 children (17 of them infants), including 13 male and eight female children aged 2 months to 8 years, hospitalized for respiratory diseases are presented. Total ALP catalytic activity was determined and electrophoretic separation of ALP isoenzymes was performed in children's sera.

Results: Increased total ALP catalytic activity (range, 528–5622 U/L) during hospital stay was recorded in eight (38.1%) children. A typical picture of benign transient hyperphosphatasemia (TH), which implies the occurrence of fast anodal fraction (faster than hepatic fraction) and near-cathode fraction (faster than bone fraction), was recorded in five children. The placental-like isoenzyme was detected in two children. Expression of bone fraction and placental-like fraction was recorded in a rachitic child. Prehepatic ALP was expressed in two children, and hepatic ALP isoenzyme in one child.

Conclusion: Acute respiratory disease in infants and children may entail transient increase in the ALP catalytic activity with the occurrence of various isoenzyme bands such as fast anodal and near-cathode fraction (in TH), prehepatic fraction and placental-like fraction. TH is verified when total ALP activity has decreased and returned to reference intervals. In this case, no additional testing is required.

Key words: alkaline phosphatase, child, infant, hyperphosphatasemia, isoenzymes, respiratory diseases

Pristiglo: 12. ožujka 2007.

Prihvaćeno: 4. travanj 2007.

Received: March 12, 2007

Accepted: April 4, 2007

Uvod

Alkalna fosfataza, ortofosfat-monoester-fosfohidrolaza (ALP; EC 3.1.3.1) je zajednički naziv za skupinu glikoziliranih enzima (izoenzima) s optimumom aktivnosti u alkalnom području (pH 9,8 do 10,5). Izoenzimski oblici različitog podrijetla (jetra, bubreg, kost, placenta i crijeva) imaju različite fizikalno-kemijske, kao i imunološke značajke koje se rabe u metodama razdvajanja izoenzima (1). Kalitička aktivnost ALP mijenja se u djetinjstvu zbog koštanog rasta: prva tri mjeseca života djeteta umjereno je povećana, a u pubertetu je dvostruko do trostruko veća nego u odrasle osobe.

Prolazna hiperfosfatazemija (engl. *transient hyperphosphatemia*, TH) dojenčadi i male djece benigna je pojava povećanja katalitičke aktivnosti serumske alkalne fosfataze koja može trajati nekoliko tjedana (2). Prvi je put opisana 1954. godine (3). Budući da u djece nema kliničkih znakova metabolične koštane ili jetrene bolesti (4), otkriva se slučajno u okviru uobičajene laboratorijske obrade. Obično se pojavljuje do pete godine života, a opisana je i ponavljajuća pojava u odrasle osobe (5). Dijagnoza se postavlja nakon što se vrijednosti alkalne fosfataze značajno smanje ili vrate u referentne raspone unutar 3–4 mjeseca (5–7).

Budući da se TH može pojaviti u djece s respiracijskim bolestima (2), ovim smo radom željeli prikazati elektroforetsku sliku izoenzima ALP u serumu djece koja su u tijeku akutne respiracijske bolesti imala povećanu ukupnu katalitičku aktivnost ALP.

Ispitanici i metode

Ispitanici

Prikazani su rezultati ukupno 21 djeteta (od toga 17 dojenčadi, 81%), 8 djevojčica i 13 dječaka, u dobi od 2 mjeseca do 8 godina (tablica 1.). Djeca su zbog težine akutne respiracijske bolesti (većina zbog bronhiolitisa) morala biti primljena na bolničko liječenje (Dječja bolnica Srebrnjak, Zagreb) u razdoblju od 1. siječnja do 28. veljače 2007. godine. Radiološka slika, leukocitoza, te izrazito povećane koncentracije C-reaktivnog proteina (CRP) u troje djece ukazivali su na bakterijsku etiologiju respiracijske bolesti. U većine djece dokazana je infekcija respiracijskim sincicijskim virusom (RSV). Uz djecu s povećanom katalitičkom aktivnošću ukupne ALP, prikazana su i djeca s bronhiolitom/pneumonijom kod kojih je ukupna aktivnost ALP bila unutar referentnih raspona.

Metode

Određivanje alkalne fosfataze

Ukupna aktivnost ALP određena je preporučenom fotometrijskom, kontinuiranom metodom, uz *p*-nitrofenilfosfat, AMP pufer, Mg acetat, Zn-sulfat, HEDTA (8).

Introduction

Alkaline phosphatase, orthophosphate-phosphohydrolase (ALP; EC 3.1.3.1) is a common term for a group of glycosylated enzymes (isoenzymes) with optimal activity in the alkaline range (pH 9.8–10.5). The isoenzymatic forms of different origin (liver, kidney, bone, placenta and intestine) have different physicochemical and immunologic characteristics that are employed in the methods of isoenzyme separation (1). The catalytic activity of ALP undergoes modification in childhood due to bone growth; it is moderately increased in the first three months of life, while in puberty it is two- to three-fold that in adults.

Transient hyperphosphatasemia (TH) in infants and children is a benign increase in the catalytic activity of serum ALP, which may persist for several weeks (2). TH was first described in 1954 (3). As these children show no clinical signs of a bone or liver metabolic disease (4), TH is detected incidentally, on routine laboratory work-up. TH generally occurs by the age of 5 years; however, recurrences in adults have been described (5). The diagnosis of TH is made when ALP values have significantly decreased or returned to reference range within 3–4 months (5–7).

As TH may occur in children with respiratory diseases (2), the aim of the study was to show the electrophoretic pattern of ALP isoenzymes in serum of children exhibiting an increased total ALP catalytic activity in the course of acute respiratory disease.

Subjects and Methods

Subjects

Results obtained in 21 children (17 or 81% of them infants), 13 male and eight female, aged 2 months to 8 years, are presented (Table 1). Because of the severity of acute respiratory disease (mostly bronchiolitis), study children were hospitalized at Srebrnjak Children's Hospital in Zagreb between January 1 and February 28, 2007. In three children, radiological examination, leukocytosis and marked increase in the C-reactive protein (CRP) concentration pointed to bacterial etiology of their respiratory disease. The respiratory syncytial virus (RSV) infection was demonstrated in most children. Besides children with an increased total ALP catalytic activity, presentation is made of the children with bronchiolitis/pneumonia whose total ALP activity was within the reference range.

Methods

Determination of alkaline phosphatase

Total ALP activity was determined by the recommended photometric continuous method with *p*-nitrophenylphosphate, AMP buffer, Mg acetate, Zn-sulfate, HEDTA (8).

TABLICA 1. Opće značajke bolesnika

TABLE 1. General characteristics of study patients

Patient No.	Gender	Age (months)	Diagnosis	Etiology
1	F	4	<i>Bronchiolitis, pneumonia</i>	Bacterial
2	M	15	<i>Bronchitis diffusa</i>	RSV
3	M	10	<i>Bronchitis diffusa</i>	RSV
4	M	11	<i>Bronchitis obstructiva recidivans</i>	Bacterial
5	M	6	<i>Laryngotracheobronchitis acuta</i>	RSV
6	M	6	<i>Laryngotracheobronchitis acuta</i>	RSV
7	M	2	<i>Bronchiolitis, rachitis</i>	RSV
8	F	45	<i>Pneumonia</i>	RSV
9	F	2	<i>Bronchiolitis</i>	RSV
10	F	102	<i>Pneumonia</i>	Bacterial
11	F	7	<i>Bronchiolitis</i>	RSV
12	M	2	<i>Bronchiolitis</i>	RSV
13	M	2	<i>Bronchiolitis</i>	RSV
14	M	4	<i>Bronchiolitis</i>	RSV
15	F	2	<i>Bronchiolitis</i>	RSV
16	M	8	<i>Bronchiolitis, pneumonia</i>	Bacterial
17	M	3	<i>Bronchiolitis</i>	RSV
18	M	3	<i>Bronchiolitis</i>	RSV
19	F	4	<i>Bronchiolitis</i>	RSV
20	M	8	<i>Bronchitis diffusa</i>	RSV
21	F	36	<i>Bronchitis diffusa</i>	RSV

M, male; F, female; RSV, respiratory syncytial virus

Elektroforetsko razdvajanje izoenzima alkalne fosfataze

Učinjeno je elektroforetsko razdvajanje izoenzima ALP na agaroznom gelu (Hydragel 7/15 ISO-PAL gelovi), uz automatski elektroforetski sustav Hydrasis, denzitometar Hydrasis 2 (Sebia system, Francuska) uz prethodnu obradu seruma lektinom (9).

Rezultati

Osmero (38,1%) djece imalo je povećanu ukupnu katalitičku aktivnost ALP (raspon od 528 do 5622 U/L), a četrnaestero djece imalo je povećanu ukupnu aktivnost jednog ili više ostalih enzima: aspartat-aminotransferaze (AST), alanin-aminotransferaze (ALT), gama-glutamilttransferaze (GGT) ili laktat-dehidrogenaze (LD). Mjesec i pol dana nakon završetka bolničkog liječenja ukupna aktivnost ALP bila je kod sve djece unutar referentnih raspona za dob. Elektroforetsko razdvajanje izoenzima ALP (tablica 2.) pokazalo je u desetero (47,6%) djece normalnu izoenzimsku

Electrophoretic separation of alkaline phosphatase isoenzymes

Electrophoretic separation of ALP isoenzymes was performed on agarose gel (Hydragel 7/15 ISO-PAL gels) by use of the automated Hydrasis electrophoresis system, Hydrasis 2 densitometer (Sebia System, France), with serum lectin pretreatment (9).

Results

Increased total ALP catalytic activity (range, 528-5622 U/L) was found in eight (38.1%) children, and increased total activity of one or more other enzymes, i.e. aspartate aminotransferase (AST), alanine aminotransferase (ALT), gamma glutamyltransferase (GGT) and lactate dehydrogenase (LD), in 14 children. One month and a half upon completion of hospital treatment, total ALP activity was within the age-adjusted reference range in all study children. Electrophoretic separation of ALP isoenzymes showed normal age-specific isoenzyme pattern in ten (47.6%) chil-

sliku (tablica 2., br. 12–21), svojstvenu dječjoj dobi (10). Tipičnu sliku TH koja podrazumijeva pojavu brze anodne frakcije (brža od jetrene frakcije) i tzv. katodne frakcije (brža od koštane frakcije) imalo je petero djece (tablica 2., br. 1–5). Izoenzim nalik placentalnom izoenzimu (engl. *placental-like*) nađen je kod dvoje djece (br. 6, 11). Izraženu koštanu frakciju, ali i frakciju nalik placentalnom izoenzimu imalo je dijete s rahitisom (br. 7). Predjetreni izoenzimi otkriveni su kod dvoje djece (br. 8, 9), a izražen jetreni izoenzim imalo je jedno dijete (br. 10). Slika 1. uspoređuje

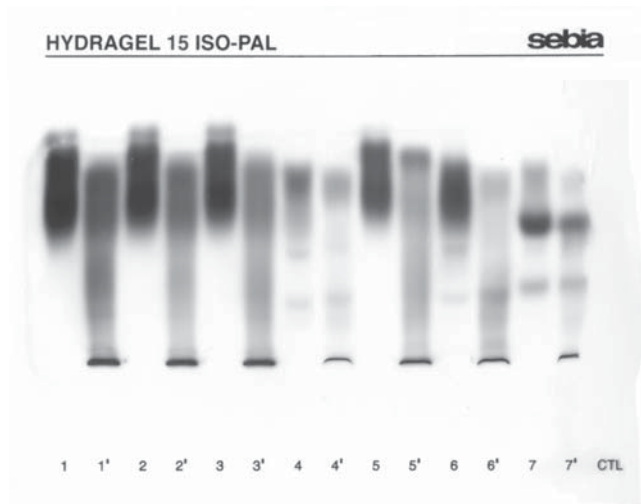
dren (Table 2, No. 12–21) (10). A characteristic TH picture with the appearance of fast anodal fraction (faster than hepatic fraction) and near-cathode fraction (faster than bone fraction) was recorded in five children (Table 2, No. 1–5). The placental-like isoenzyme was found in two children (No. 6 and 11), and bone fraction along with the placental-like isoenzyme fraction in one rachitic child (No. 7). Prehepatic isoenzymes were detected in two children (No. 8 and 9), whereas hepatic isoenzyme was found in one child (No. 10). Comparison of diluted patient samples

TABLICA 2. Vrijednosti analita u djece u tijeku bolničkog liječenja (zadebljanim brojkama prikazane su vrijednosti analita izvan referentnih raspona)

TABLE 2 Analyte values in children during hospital stay (bold, analyte values exceeding reference range)

Patient No	ESR (mm)	Lkc (x 10 ⁹ /L)	Plt (x 10 ⁹ /L)	CRP (mg/L)	Iron (μmol/L)	ALP (U/L)	Iso-enzymes	AST/ALT (U/L)	GGT (U/L)	LD (U/L)	Bilirubin (μmol/L)
1	11	17.3	363	111.3	2.1	5622	TH	38/18	14	361	4.9
2	39	6.8	356	6.1	2.7	1184	TH	54/16	10	394	6.1
3	50	18.7	526	0.2		913	TH	38/14	11	248	5.3
4	41	17	470	104.3	1.8	596	TH				
5	17	7.5	676	2.3	3.9	1200	TH	41/32	37	352	4
6	17	12.4	571	4.1	2.8	535	PI	57/73	73	248	5.2
7	17	5.8	331	0.2	15.9	867	B. PI	107/89	33	305	54.7
8	86					140	Pre-L	89/176	78		
9	17	31.6	1155	0.4	9	491	Pre-L	44/35	56	419	7.5
10	102	24.7	841	172.5	3.8	237	L	111/235	218	258	12.4
11	22	15	698	0.7	2.6	499	PI	38/52	14	289	5.3
12	7	22.4	354	2.5	2.4	304	N	52/67	31	277	10
13	28	9.3	468	9.2	7.7	408	N	37/27	40	225	6.3
14	21	7.5	485	2	9.9	494	N	30/20	45	265	9.5
15	5	8.1	546	0.3	11.8	394	N	42/30	49	204	6.7
16	19	11.5	498	2.8	11.5	376	N	36/39	23	286	8.4
17		8.1	459	0.1	5.7	359	N	58/39	22	290	
18	70	9.6	647	2.5	10.7	294	N	95/80	272	305	6.6
19	8	5.4	382	1	15.2	528	N	50/29	113	280	7.8
20	2	15.1	428	3.2	3.5	458	N	39/22	27	281	9.2
21	10	12.4	288	28.7		463	N	29/14	12	264	10.9

ESR, erythrocyte sedimentation rate; Lkc, leukocytes; Plt, platelets; ALP, alkaline phosphatase; AST, aspartate aminotransferase; ALT, alanine aminotransferase; GGT, gamma glutamyltransferase; LD, lactate dehydrogenase; TH, transient hyperphosphatasemia with atypical anodal and near-cathode fraction; B, bone isoenzyme; L, elevated liver isoenzyme; PI, placental-like isoenzyme; Pre-L, prehepatic isoenzyme



SLIKA 1. Elektroforetsko razdvajanje izoenzima ALP. Linije 1-7: razrijeđeni serum; linije 1'-7': isti uzorci nakon obrade lektinom.

A. Dojenčad br. 1, 3 i 4 s TH (1-3); majka dojenčeta br. 1 pokazuje jetrenu, intestinalnu i koštanu ALP (4); dojenče br. 2 s TH (5); dijete br. 21 s jetrenom, intestinalnom i koštanom ALP (6); trudnica s jetrenom, placentalom i koštanom ALP (7).

B. Kontrolni uzorak 1 (1); dojenče s TH (2, 3); dojenče s koštanim izoenzimom i izoenzimom nalik placentaloj ALP (4, 7); dojenče br. 1. na kontrolnom pregledu nakon 54 dana pokazuje jetreni, koštani i intestinalni izoenzim ALP (6); kontrolni uzorak 2 (CTL).

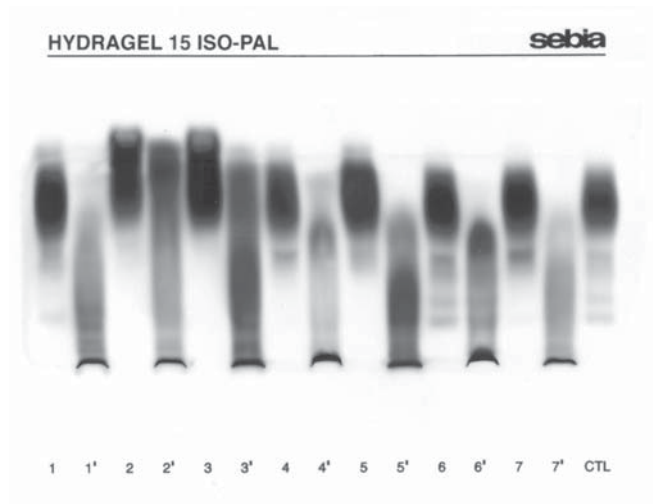


FIGURE 1 Electrophoretic separation of alkaline phosphatase (ALP) isoenzymes; lanes 1-7: diluted sera; lanes 1'-7': the same serum samples pretreated with lectin.

A. Infants No. 1, 3 and 4 with transient hyperphosphatasemia (TH) (1-3); No. 1 infant's mother showing hepatic, intestinal and bone ALP (4); infant No. 2 with TH (5); child No. 21 showing hepatic, intestinal and bone ALP (6); pregnant woman showing hepatic, placental and bone ALP (7).

B. Control sample 1 (1); infant with TH (2, 3); infant showing bone isoenzyme and placental-like ALP isoenzyme (4, 7); infant No. 1 at control testing on day 54 showing hepatic, bone and intestinal ALP isoenzymes (6); control sample 2 (CTL).

uzorke razrijeđenih seruma bolesnika (linije 1-7) i seruma obrađenih lektinom (linije 1'-7'). Ukupna katalitička aktivnost ALP dojenčeta s bronhiolitisom/pneumonijom (5622 U/L) smanjila se nakon 54 dana unutar referentnih raspona (349 U/L), a izoenzimska slika je pokazivala normalan nalaz. U djeteta s rahitisom se nakon terapije vitaminom D smanjila katalitička aktivnost ALP.

Rasprava

Prikazana su djeca koja su u tijeku akutne respiracijske bolesti imala povećanu ukupnu katalitičku aktivnost ALP, a elektroforetskim razdvajanjem izoenzima dobivene su različite izoenzimske slike: 1. tipična slika TH, 2. izoenzim nalik placentalom izoenzimu, 3. predjetreni izoenzim, 4. izrazito povećan jetreni izoenzim, 5. izražen koštani izoenzim ALP kod djeteta s rahitisom.

Kriteriji postavljanja dijagnoze benigne TH su: dob djeteta manja od 5 godina; različiti simptomi, primjerice respiracijske infekcije, diareja, povraćanje; nedostatak kliničkih i biokemijskih znakova koštane i jetrene bolesti; povećanje ukupne katalitičke aktivnosti ALP 3 do 50 puta od gornje granice referentnog raspona za dob; povratak u granice referentnog raspona unutar 4 mjeseca (2). Izoenzimi

(lanes 1-7) and lectin pretreated samples (lanes 1'-7') is presented in Figure 1.

In the infant affected with bronchiolitis/pneumonia, total ALP catalytic activity (5622 U/L) decreased in 54 days to the reference range (349 U/L), while the isoenzyme pattern showed normal finding. In the rachitic child, the value of ALP decreased with vitamin D therapy.

Discussion

The study included children exhibiting increased total ALP catalytic activity in the course of acute respiratory disease, and varying isoenzyme patterns obtained by electrophoretic separation of ALP isoenzymes, i.e. 1) typical TH pattern; 2) placental-like isoenzyme; 3) prehepatic isoenzyme; 4) markedly increased hepatic isoenzyme; and 5) bone ALP isoenzyme expression in the rachitic child.

The criteria for the diagnosis of benign TH include age below 5 years; various symptoms such as respiratory infection, diarrhea and vomiting; no clinical or biochemical signs of bone or liver disease; increased total ALP values of 3- to 50-fold upper reference value for age; and return to the reference range within 4 months (2). Qualitati-

pokazuju, u kvalitativnom i kvantitativnom smislu, specifičnu sliku: povećanje aktivnosti brže anodne i tzv. katodne frakcije (11). Obično se pojavljuje u tijeku infekcija (12), osobito akutnih virusnih infekcija (13,14), češće u djevojčica nego u dječaka (omjer 1,29:1) (15). Može se pojaviti kod blagih respiracijskih ili intestinalnih infekcija (16). U ovom prikazu dojenčadi s TH radilo se o ozbiljnoj akutnoj respiracijskoj bolesti, virusne (RSV) odnosno bakterijske etiologije. Suzuki i sur. su kod djece s TH, koja se pojavila uz infektivne bolesti gornjih dišnih putova praćene vrućicom i diarejom, dokazali i povećanu koncentraciju antitijela protiv enterovirusa Echo 22, Entero 71 i Coxsackie B4 (15), a opisan je i slučaj infekcije rotavirusom u djeteta s transplantiranom jetrom (7). Parisi i sur. su TH opisali i u bolesnika s egzantematoznom vrućicom nakon primjene cjepiva protiv ospica (17). TH se može pojaviti u 2,8% djece s presađenom jetrom ili bubregom (18).

Placentalni izoenzim ne može se naći u novorođenčadi (19). Pojava izoenzima nalik placentalnom, o podrijetlu kojega se može samo nagađati, dosad nije opisana kao popratna pojava respiracijskih bolesti u dojenčadi i djece. Valja ispitati potječe li možda iz timusa (20) ili pluća u tijeku respiracijske bolesti. Može se pretpostaviti da je pojava predjetrenog izoenzima ALP te povećana aktivnost jetrenog izoenzima u naših ispitanika bila posljedica primjene lijekova (bolesnici su imali i povećane katalitičke aktivnosti aminotransferaza, GGT odnosno LD), no i to bi trebalo ispitati.

Elektroforetskim razdvajanjem je utvrđeno da se kod TH uglavnom radi o izoenzimima koštanog i jetrenog podrijetla (21). Čini se da je promijenjena pokretljivost jetrenih i koštanih izoenzima (anodna i tzv. katodna frakcija) uzrokovana povećanom količinom sijalinske kiseline. Naime, povećanje katalitičke aktivnosti alkalne fosfataze tumači se mogućom povećanom sintezom alkalne fosfataze pod djelovanjem metabolita vitamina D, a u tijeku bolesti zbog mogućega smanjenog jetrenog klirensa iz cirkulacije, uzrokovanog pojačanom sijalinizacijom ili utjecajem nekih lijekova na jetra (21). Međutim, temeljem elektroforetskog razdvajanja izoenzima ALP ne može se procijeniti podrijetlo izoenzima. Nalaz fragmentiranih jetrenih i koštanih izoenzima može biti posljedica smanjenog klirensa u tijeku virusnih infekcija (22). Za razliku od prolazne, opisani su slučajevi trajne hiperfosfatazemije koja može biti nasljedna asimptomatska (23), nenasljedna (24), a opisan je i slučaj u osobe s mentalnom retardacijom (25).

Prema našem znanju u Hrvatskoj je pojava prolazne TH opisana 1986. godine (26). Koliko se ona prepoznaje? Ili se jednostavno pripisuje fiziološkom rastu koštane mase? Kolika je njezina pojavnost u djece s akutnim infekcijama? Ili se samo manjem broju djece s infekcijama odredi aktivnost ALP?

Pojava povećane katalitičke aktivnosti alkalne fosfataze u dojenčeta u tijeku akutne respiracijske infekcije ukazuje

vely and quantitatively, the isoenzymes display a specific pattern, i.e. increase in the activity of the fast anodal and near-cathode fraction (11). TH usually develops during the course of an infection (12), acute viral infections in particular (13,14), showing a male predominance (male to female ratio, 1.29:1) (15). TH may occur in mild respiratory or intestinal infections (16). Our infants with TH suffered from a serious acute respiratory disease of viral (RSV) or bacterial etiology. Suzuki *et al.* report elevated concentration of antibodies to Echo 22, Entero 71 and Coxsackie B4 enteroviruses in children with infectious diseases of upper airways accompanied by fever and diarrhea that developed TH (15). A case of rotavirus infection in a liver transplanted child has also been described (7). Parisi *et al.* report on TH in a patient with exanthematous fever following anti-measles vaccination (17). TH may occur in 2.8% of children with liver or kidney transplant (18). Placental isoenzyme cannot be detected in newborns (19). The occurrence of placental-like isoenzyme, the origin of which can only be speculated, has not yet been reported as a phenomenon accompanying respiratory disease in infants and children. It remains to determine whether it maybe derives from the thymus (20) or the lungs in the course of respiratory disease. The occurrence of prehepatic ALP isoenzyme and the increased activity of hepatic isoenzyme in our subjects may have been consequential to medicamentous therapy (the patients also showed increased catalytic activity of aminotransferases, GGT and LD), however, it should be additionally investigated.

Electrophoretic separation mostly identified isoenzymes of bone and hepatic origin in TH (21). The changed motility of hepatic and bone isoenzymes (anodal and near-cathode fraction) seems to be caused by the increased amount of sialic acid. The increase in the catalytic activity of ALP has been attributed to the possibly increased ALP synthesis due to the action of vitamin D metabolites, and in disease due to the possibly reduced hepatic clearance from the circulation caused by enhanced sialinization or hepatic effect of some drugs (21). However, the true origin of ALP isoenzymes cannot be assessed on the basis of electrophoretic separation. The finding of fragmented hepatic and bone isoenzymes may be consequential to a decreased clearance in the course of viral infection (22). Apart from transient hyperphosphatasemia, cases of permanent hyperphosphatasemia, which may be hereditary asymptomatic (23), non-hereditary (24), or in association with mental retardation (25), have also been reported.

To our knowledge, the occurrence of TH in Croatia was described in 1986 (26). How well is TH recognized? Or, is it simply ascribed to the physiological growth of bone mass? What is the prevalence of TH in children with acute infections? Is the ALP activity determined only in a minor proportion of children with infections?

The occurrence of increased ALP catalytic activity in an infant in the course of an acute respiratory infection poin-

na postojanje benigne prolazne hiperfosfatazemije. Doka-
zuje se naknadno nakon što se aktivnost alkalne fosfataze
značajno smanji odnosno vrati unutar referentnog raspo-
na. Ako se vrijednosti normaliziraju unutar 4 mjeseca daljn-
ja ispitivanja nisu potrebna (6, 7).

ts to the existence of benign TH. TH is subsequently veri-
fied, i.e. when the activity of ALP has significantly decrea-
sed and returned to the reference range. If the values of
ALP normalize within 4 months, no additional testing is
required (6,7).

Adresa za dopisivanje:

Slavica Dodig
Dječja bolnica Srebrnjak
Srebrnjak 100
10000 Zagreb
e-pošta: slavica.dodig@zg.t-com.hr
tel: +385 1 6391 100
faks: +385 1 2430-784

Corresponding author:

Slavica Dodig
Srebrnjak Children's Hospital
Srebrnjak 100
HR-10000 Zagreb, Croatia
e-mail: slavica.dodig@zg.t-com.hr
phone: +385 1 6391 100
fax: +385 1 2430-784

Literatura/References

- Štraus B. *Medicinska biokemija. Medicinska naklada, Zagreb 1992.*
- Kraut JR, Metrick M, Maxwell NR, Kaplan MM. Isoenzyme studies in transient hyperphosphatasemia of infancy. Ten new cases and a review of the literature. *Am J Dis Child* 1985;139:736-40.
- Bach U. Das Verhalten der alkalischen Serum-Phosphatase bei Frühgeborenen, Rachitikern und Spasmophilen. *Z Kinderheilkd* 1954;74:593-609.
- Kutilek S, Bayer M. Transient hyperphosphatasemia – where we stand? *Turk J Pediatr* 1999;41:151-60.
- Onica D, Torssander J, Waldenlind L. Recurrent transient hyperphosphatasemia of infancy in an adult. *Clin Chem* 1992;38:1913-5.
- Tolaymat N, deMelo MCN. Benign transient hyperphosphatasemia of infancy and childhood. *South Med J* 2000;93:1162-4.
- Arikan C, Arslan MT, Kilic M, Aydogdu S. Transient hyperphosphatase-mia after pediatric liver transplantation. *Pediatr Int* 2006;48:390-2.
- Harmonizacija laboratorijskih nalaza u području opće medicinske bio-kemije. Hrvatska komora medicinskih biokemičara, Klinička bolnica Merkur, Zavod za kliničku kemiju, Zagreb 2004, p. 8.
- Rosalki SB, Foo AY. Lectin affinity electrophoresis of alkaline phosphatase for the differentiation of bone and hepatobiliary disease. *Electrophoresis* 1989;10:604-11.
- Alkaline phosphatase isoenzymes, Available at: <http://www.aruplab.com/guides/ug/tests/0021020.jsp>. Accessed Feb 27, 2007.
- Behulova D, Bzduch V, Ksanicka A, Ticha L, Kucekova G. Electrophoresis of alkaline phosphatase isoenzymes – the key to rapid diagnosis in transient hyperphosphatemia. *Cesk Pediatr* 1993;48:193-5.
- Oggero R, Mostert M, Spinello M, Iavarone A, Buffa J. Transient hyperphosphatasemia in infancy. Fifteen new cases. *Acta Paediatr Scand* 1988;77:257-9.
- Eboriadou M, Skouli G, Panagopoulou P, Haidopoulou K, Makedou A, Varlamis G. Acute laryngotracheobronchitis and associated transient hyperphosphatasemia: a new case of transient hyperphosphatasemia in early childhood. *J Pediatr Child Health* 2006;42:149-50.
- Griffiths J, Vernocchi A, Simoni E. Transient hyperphosphatasemia of infancy and childhood. A study of serum alkaline phosphatase by electrofocusing techniques. *Arch Pathol Lab Med* 1995;119:784-9.
- Suzuki M, Okazaki T, Nagai T, Toro K, Setony P. Viral infection of infants and children with benign transient hyperphosphatasemia. *FEMS Immunol Med Microbiol* 2002;12:215-8.
- Garty BZ, Nitzan M. Benign transient hyperphosphatasemia. *Isr J Med Sci* 1994;30:66-9.
- Parisi G, Chiarelli A, Brandani M, D'Onofrio A. Transient alkaline hyperphosphatasemia in childhood. A report of 4 clinical cases and etiopathogenetic hypotheses. *Minerva Pediatr* 1991;43:337-41.
- Ranchin B, Villard F, Andre JL, Canterino I, Said MH, Boisson RC, et al. Transient hyperphosphatasemia after organ transplantation in children. *Pediatr Transplant* 2002;6:308-12.
- Crofton PM. Properties of alkaline phosphatase isoenzymes in plasma of preterm and term neonates. *Clin Chem* 1987;33:1778-82.
- Sokolić B, Čepelak I. Izoenzimi i višestruki oblici alkalne fosfataze; značenje, mogućnosti određivanja. *Biochemia Medica* 1994;4:113-21.
- Crofton PM. What is the cause of benign transient hyperphosphatasemia? A study of 35 cases. *Clin Chem* 1988;34:335-40.
- Schoenau E, Herzog KH, Boehles HJ. "Fragmented" isoenzymes of alkaline phosphatase in the diagnosis of transient hyperphosphatasemia. *Clin Chem* 1986;32:2211-3.
- Asami T, Gomi T, Uchijama M. Persistent non-familial asymptomatic hyperphosphatasemia: a report on three cases. *Acta Paediatr* 1995;84:346-8.
- Wilson JW. Inherited elevation of alkaline phosphatase activity in the absence of disease. *N Engl J Med* 1979;301:983-4.
- Kruse K, Hanefeld F, Kohlschutter A, Roskamp R, Gross-Selbeck G. Hyperphosphatasia with mental retardation. *J Pediatr* 1988;112:436-9.
- Jurčić Z, Rudar D, Hajnčić TF, Cvitanaović Lj, Babić M. Benigna tranzitorna hiperfosfatazemija. Knjiga sažetaka. V. Jugoslavensko-austrijski simpozij o bolestima jetre. Zadar, 1986:59.