

Observation

MULTIDOSE ACTIVATED CHARCOAL IN THE TREATMENT OF CARBAMAZEPINE OVERDOSE WITH SEIZURES: A CASE REPORT

Stjepan MIŠE, Ivana JUJKIĆ, Ante TONKIĆ, Marina TITLIĆ, and Sandro MIŠE

Clinical Hospital Split, Split, Croatia

Received in November 2004

Serious complications after carbamazepine poisoning, such as coma, seizures, respiratory failure, cardiac conduction abnormalities, and death are more likely with serum levels greater than $170 \mu\text{mol L}^{-1}$. We report a case of a single massive carbamazepine overdose in a 19-year-old male, following attempted suicide, without prior history of seizure disorder. On admission, three hours after ingestion, serum carbamazepine concentration was $179 \mu\text{mol L}^{-1}$ and Glasgow Coma Scale scored 6. The patient was intubated and treated with multiple doses of activated charcoal for 48 hours. Twelve hours after ingestion, two repeated generalised myoclonic seizures were noted when serum carbamazepine levels peaked at $181 \mu\text{mol L}^{-1}$, and were successfully treated with diazepam. Carbamazepine serum level fell within the therapeutic range 63 hours after ingestion and the patient was discharged without any long-term sequelae. As there is no antidote for carbamazepine poisoning, supportive treatment remains the only, but usually potent option.

KEY WORDS: *intoxication, myoclonic seizures, poisoning, suicide*

Carbamazepine is a well known and widely used iminostilbene derivative anticonvulsant with a chemical structure closely related to cyclic antidepressants. It is used to control generalized and partial seizure disorders, bipolar and depressive disorders as well as migraine and chronic pain states. Due to growing carbamazepine indications and far greater availability of this drug observed over the recent years, a higher number of acute intoxications is to be expected (1, 2).

Signs of toxicity usually appear at plasma concentrations above the upper therapeutic limit ($17 \mu\text{mol L}^{-1}$ to $51 \mu\text{mol L}^{-1}$), but serious complications, such as coma, seizures, respiratory failure, cardiac conduction abnormalities, and death are more likely with serum levels greater than $170 \mu\text{mol L}^{-1}$ (3, 4). The highest known carbamazepine plasma levels associated with a fatal course were $347 \mu\text{mol L}^{-1}$ and $1100 \mu\text{mol L}^{-1}$ (5, 6), and other previously reported

fatalities had levels around or above $200 \mu\text{mol L}^{-1}$ (3, 7-9).

Carbamazepine has a greater affinity for binding to the inactivated state of the sodium channel as opposed to the activated state, and this binding has the effect of increasing the number of sodium channels in the inactivated state. It is also a powerful inhibitor of the muscarinic and nicotinic acetylcholine receptors, N-methyl-D-aspartate (NMDA) receptors, and the central nervous system adenosine receptors (10-13).

Today, there are contraindicating reports about the efficiency of hemodialysis, haemoperfusion, plasmapheresis and multiple doses of activated charcoal for the treatment of carbamazepine poisoning (14-21). Carbamazepine overdose has raised controversies about the relationship between serum carbamazepine and the severity of toxicity and between the history of seizure disorder and increased risk of seizure (3, 4).

We report a successful and rapid treatment outcome of a patient with a severe acute carbamazepine poisoning (peak serum concentration was $181 \mu\text{mol L}^{-1}$) due to a suicide attempt, followed by generalized seizures, who was treated with multiple doses of activated charcoal.

CASE REPORT

A 19-year-old male was found by his brother unconscious on the floor of his apartment and vomiting. He was admitted to the Emergency Unit of Clinical Hospital Split about 3 hours after the ingestion of about 10 g of carbamazepine (Tegretol, Pliva d.d., Croatia, 50 tablets of 200 mg), according to his elder brother. No history of seizure disorder was established from the interview with the patient's mother, and the patient was not taking any medication at the time. The carbamazepine tablets were of his father's. On admission, the patient was in stupor, scored 6 on the Glasgow Coma Scale, with horizontal nystagmus, pulse 95 bpm, and arterial blood pressure 173/107 hPa (130/80 mm Hg). A 12-lead electrocardiogram revealed sinus tachycardia, PR interval 200 ms, QRS 120 ms, and incomplete right bundle branch block. Body temperature reached 40°C without signs of infection.

Serum carbamazepine concentration measured (Abbott AxSYM System, Abbott Laboratories, USA) on admission was $179 \mu\text{mol L}^{-1}$ (therapeutic $17 \mu\text{mol L}^{-1}$ to $51 \mu\text{mol L}^{-1}$) 3 hours after ingestion. Urine qualitative screening for drugs of abuse (benzodiazepines, opiates, methadone, amphetamines, cocaine, barbiturates, phencyclidine and cannabinoids) was positive for cannabinoids alone. No alcohol was detected.

Initial arterial blood gas was within the normal range, and there was need for mechanical ventilation. The patient was intubated, and a gastric lavage was performed, followed by initial administration of 50 g activated charcoal (diluted in water) via a nasogastric tube, with a single dose of sorbitol in addition. The patient was admitted to the Intensive Care Unit and his electrocardiogram was monitored continuously to detect any cardiac arrhythmias or conduction defects. He was detoxified with multiple doses of activated charcoal (50 g every 4 h for 48 h), adequately hydrated [2500 mL 5 % glucosaline (5 % glucose + 0.9 % NaCl, HZTM) i.v. per 24 h], and haemodynamic monitoring was also performed. Chest X-ray did not reveal

any pathological findings. Hypokalemia (the mean recorded potassium concentration was 3.3 mmol L^{-1}) was corrected with 7.4 % potassium chloride (Kalij-klorid, Pliva d.d., Croatia) given intravenously. At 12 h after ingestion, the patient (without a previous history of seizure disorder) experienced two repeated, four-minute, generalised myoclonic seizures when serum carbamazepine levels peaked at $181 \mu\text{mol L}^{-1}$. He was successfully treated with intravenous diazepam 10 mg (Normabel, Belupo, Croatia). Systolic pressure fell to 100 hPa (75 mm Hg) after the diazepam infusion, and dopamine treatment started in the dose of $2 \mu\text{g kg}^{-1} \text{ min}^{-1}$. Thirty minutes later, dopamine was discontinued and blood pressure was 173/107 hPa (130/80 mm Hg). A nephrologist was consulted and he recommended charcoal haemoperfusion, but as the charcoal haemoperfusion cartridge was unavailable for six hours, the detoxification was continued using activated charcoal. The patient's neurological status improved during that time, as carbamazepine serum levels declined ($152 \mu\text{mol L}^{-1}$). We decided not to treat the patient by charcoal haemoperfusion, and multiple doses of activated charcoal were continued. The patient became responsive, opened his eyes spontaneously, and was oriented in space. Mean daily diuresis was 2800 mL. On day three from the ingestion, when the carbamazepine level declined to 30 mmol L^{-1} , the patient's neurological status improved completely, and his serum potassium and body temperature reached normal values. A psychiatrist was also consulted, who diagnosed a personality disorder with external frustration situation. The patient was discharged and referred to a psychiatrist for further therapy 63 h after ingestion, without any long-term sequelae. A summary of serum carbamazepine concentrations, patient's clinical course and treatment are shown in Figure 1.

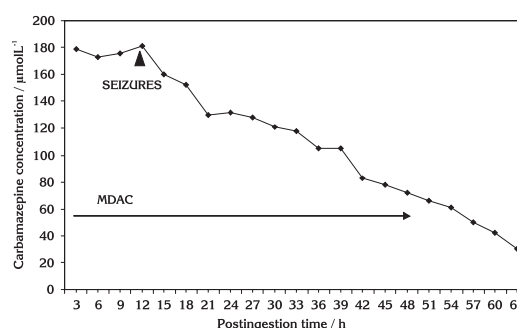


Figure 1 Serum carbamazepine concentrations following the ingestion of 10 g of carbamazepine. MDAC stands for "multiple-dose activated charcoal".

DISCUSSION

In the reported case of poisoning with 10 g of immediate-release carbamazepine following attempted suicide, serum carbamazepine levels peaked at $181 \mu\text{mol L}^{-1}$ 12 h after ingestion and were associated with generalized myoclonic seizures. Serum concentrations of carbamazepine fell within the therapeutic range after treatment by multiple doses of activated charcoal for 48 h, and the patient was discharged 63 h after ingestion, without any long-term sequelae.

The absorption of carbamazepine from the gastrointestinal tract is slow and erratic, but complete. Peak plasma concentrations occur approximately 8 h to 12 h after ingestion, but they may be delayed up to 70 h after overdose. The distribution volume varies from 0.5 L kg^{-1} to 2.0 L kg^{-1} , with 75 % plasma protein binding, and the plasma half-life from 18 h to 55 h following a single dose, and from 12 h to 17 h in chronic therapy (2, 22). Carbamazepine is extensively metabolised by the liver, and the primary metabolite produced in the cascade of metabolites is carbamazepine-10, 11-epoxide, which has lower protein binding and a shorter half-life (5 h to 10 h) than the parent compound (23). Carbamazepine induces its own metabolism, and after oral administration, 72 % of the dose is excreted in the urine and 28 % is eliminated in the faeces. In the urine, about 2 % of the dose is recovered unchanged and about 1 % as the pharmacologically active carbamazepine-10, 11-epoxide metabolite (2, 22, 23).

The side effects, symptoms and the treatment of carbamazepine overdose have been studied extensively (1-22). The pathological signs seen in this case include neurological signs such as seizure, nystagmus and stupor, cardiovascular signs such as sinus tachycardia, incomplete right bundle branch block, and hypotension, and other findings such as hyperthermia, vomiting, and hypokalaemia. Seizures are not uncommon, occurring in 11 % to 18 % of overdose patients, but are usually discrete (3-5, 24). A peak carbamazepine concentration above $170 \mu\text{mol L}^{-1}$ is associated with a significantly greater degree of hypokalemia, suggesting a dose-related effect; in our case probably caused by vomiting (24).

The management of carbamazepine poisoning is primarily supportive, and although other authors suggest that haemoperfusion is a better option than haemodialysis, this has been challenged

(15-17). *Schuerer et al.* reported high-efficiency hemodialysis clearance rates similar or better than those attributed to haemoperfusion (16). Finally, its advantage over hemodialysis is that it has no side effects associated with haemoperfusion such as hypocalcaemia, thrombocytopenia, coagulopathies, and hypothermia. Furthermore, *Duzova et al.* suggested that a simple plasma exchange by plasma replacement is an effective method to treat carbamazepine poisoning (18).

Activated charcoal is known to bind to carbamazepine, and is recommended by the American Academy of Clinical Toxicologists and the European Association of Poison Centres and Clinical Toxicologists for the management of severe or life-threatening carbamazepine poisoning. The use of multiple doses of activated charcoal has been shown to increase clearance and reduce the half-life of the drug (20, 21). However, it should be noted that, at this point, there are no prospective controlled studies to demonstrate an improved clinical outcome following the use of multidose activated charcoal in carbamazepine poisoning. Present recommendations discourage routine use of forced diuresis in the treatment of carbamazepine poisoning, because tubular resorption renders forced diuresis ineffective. It does not enhance carbamazepine elimination and can even increase the risk of electrolyte disturbances. Fluids and vasopressors should be given for haemodynamic instability as required (24).

Carbamazepine powerfully inhibits gastrointestinal motility (clinicians should be careful to monitor the patient for the development of intestinal ileus), and this was reason for us to perform gastric lavage, even though three hours had passed after drug ingestion, which is contrary to conventional international guidelines (26).

We report a successful treatment of life-threatening carbamazepine poisoning by multidose activated charcoal during 48 h, without the development of ileus. Although hemoperfusion was indicated when generalized myoclonic seizures appeared and serum carbamazepine levels peaked at $181 \mu\text{mol L}^{-1}$, but as the charcoal haemoperfusion cartridge was unavailable for 6 h, the detoxification was continued using activated charcoal, and the patient's neurological status improved with the decline in carbamazepine serum levels. Although *Wason et al.* reported that multidose activated charcoal was not associated

with a more rapid clinical recovery, our experience is the opposite. We did not note any development of urinary retention, which is possible antidiuretic effect of carbamazepine.

According to Hojer *et al.* serious complications, such as coma, seizures, respiratory depression and cardiac conduction abnormalities, in our case seizures, are more likely with serum levels greater than $170 \mu\text{mol L}^{-1}$ (3). This correlation between serum carbamazepine and toxicity was confirmed in our case with seizures. Although Spiller *et al.* and Weaver *et al.* reported that a history of a seizure disorder appears to pose increased risk of seizure in carbamazepine overdose, generalized myoclonic seizures in our case were without a prior history of seizure disorder (4, 25). In addition, Hojer *et al.* have not found a significant correlation between the occurrence of seizures and the history of epilepsy (3).

Our case of acute carbamazepine poisoning is remarkable because of the fast and favourable outcome of the treatment with multidose activated charcoal in spite of high carbamazepine serum levels of up to $181 \mu\text{mol L}^{-1}$. Also remarkable is the successful diazepam treatment of generalized seizures without prior history of epileptic disorder. In this situation, potential enzyme saturation and auto-induction could render the interpretation of plasma concentrations extremely difficult.

Although there is no antidote for carbamazepine poisoning, supportive treatment remains the only, but usually potent option.

REFERENCES

- Graudins A, Peden G, Dowsett RP. Massive overdose with controlled-release carbamazepine resulting in delayed peak serum concentrations and life-threatening toxicity. *Emerg Med* 2002;14:89-94.
- Sweetman S, editor. Martindale: The Complete Drug Reference. London: Pharmaceutical Press; 2001.
- Hojer J, Malmlund HO, Berg A. Clinical features in 28 consecutive cases of laboratory confirmed massive poisoning with carbamazepine alone. *Clin Toxicol* 1993;31:449-58.
- Spiller HA, Krenzlok EP, Cookson E. A prospective study of serum levels and toxicity. *Clin Toxicol* 1990;28:445-58.
- Schmidt S, Schmitz-Buhl M. Signs and symptoms of carbamazepine overdose. *J Neurol* 1995;242:169-73.
- Schwartau M, Wahl G, Bücking J. Intrakardialer block bei carbamazepin-intoxikation. *Dtsch Med Wochenschr* 1983;108:1841-3.
- Denning DW, Matheson L, Bryson SM, Streete J, Berry DJ, Henry JA. Death due to carbamazepine self-poisoning: remedies reviewed. *Hum Toxicol* 1985;4:255-60.
- Insley Vuignier B, Woo OF, Becker CE. Fatal carbamazepine overdose with seizures: role of charcoal hemoperfusion. *Vet Hum Toxicol* 1986;28:504-5.
- Fisher RS, Cysyk B. A fatal overdose of carbamazepine: case report and review of literature. *J Toxicol Clin Toxicol* 1988;26:477-86.
- Lingamaneni R, Hemmings HC. Effects of anticonvulsant on veratridine and KCL evoked glutamate release from rat cortical synaptosomes. *Neurosci Lett* 1999;276:127-30.
- Yoshimura R, Yanagihara N, Terao T, Minami K, Abe K, Izumi K. Inhibition by carbamazepine of various ion channels mediated catecholamine secretion in cultured bovine adrenal medullary cells. *Naunyn-Schmiedeberg's Arch Pharmacol* 1995;352:297-303.
- Okada M, Kiryu K, Kawata Y, Mizuno K, Wada K, Tasaki H, Kaneko S. Determination of the effects of caffeine and carbamazepine on the striatal dopamine release by *in vivo* microdialysis. *Eur J Pharmacol* 1997;321:181-8.
- Skerritt JH, Davies LP, Johnston GA. Interactions of the anticonvulsant carbamazepine with adenosine receptors. *Epilepsia* 1983;24:634-42.
- Spiller HA. Management of carbamazepine overdose. *Pediatr Emerg Care* 2001;17:452-6.
- Kielstein JT, Schwarz A, Arnavaz A, Sehlberg O, Ernich HM, Fliser D. High-flux hemodialysis—an effective alternative to hemoperfusion in the treatment of carbamazepine intoxication. *Clin Nephrol* 2002;57:484-6.
- Schuerer DJE, Brophy PD, Maxvold NJ, Kudelka T, Bunchman TE. High-efficiency dialysis for carbamazepine overdose. *J Toxicol Clin Toxicol* 2000;38:321-3.
- Topolyai M, Cambell M, Dailey K, Udvari-Nagy S. Hemodialysis is as effective as hemoperfusion for drug removal in carbamazepine poisoning. *Nephron* 2002;90:213-5.
- Duzova A, Baskin E, Usta Y, Ozen S. Carbamazepine poisoning: treatment with plasma exchange. *Hum Exp Toxicol* 2001;20:175-7.
- Schlafke D, Kloock R. Carbamazepine poisoning. *Anaesthesiol Reanim* 1991;16:220-4.

20. Vale JA, Krenzelok EP, Barceloux GD. Position statement and practice guidelines on the use of multi-dose activated charcoal in the treatment of acute poisoning. *American Academy of Clinical Toxicology; European Association of Poisons Centres and Clinical Toxicologists. J Toxicol Clin Toxicol* 1999;37:731-51.
21. Wason S, Baker RC, Carolan P, Seigel R, Druckenbrod RW. Carbamazepine overdose – the effects of multiple dose activated charcoal. *J Toxicol Clin Toxicol* 1992;30:39-48.
22. Sethna M, Solomon G, Cedarbaum J, Kutt H. Successful treatment of massive carbamazepine overdose. *Epilepsia* 1989;30:71-3.
23. Patsalos PN, Krishna S, Elyas AA, Lascelles PT. Carbamazepine and carbamazepine-10, 11-epoxide pharmacokinetics in an overdose patient. *Hum Toxicol* 1987;6:241-4.
24. Seymour JF. Carbamazepine overdose. Features of 33 cases. *Drug Safety* 1993;8:81-8.
25. Watson WA, Cremer KF, Chapman JA. Gastrointestinal obstruction associated with multiple-dose activated charcoal. *J Emerg Med* 1986;4:401-7.
26. Weaver DF, Camfield P, Fraser A. Massive carbamazepine overdose: clinical and pharmacological observation in five episodes. *Neurology* 1988;38:755-9.

Sažetak**OPIS VIŠEKRAATNE PRIMJENE AKTIVNOG UGLJENA U LIJEČENJU PREDOZIRANJA KARBAMAZEPINOM POPRAĆENOG EPILEPTIČKIM NAPADAJIMA**

Pri razinama u serumu višim od $170 \mu\text{mol L}^{-1}$ veći su izgledi da će trovanje karbamazepinom dovesti do ozbiljnih komplikacija poput kome, epileptičkih napadaja, zatajenja dišnog sustava, poremećaja u srčanoj provodljivosti te smrti. U ovome je opažanju prikazan slučaj jednokratnoga snažnog predoziranja karbamazepinom prilikom pokušaja samoubojstva devetnaestogodišnjaka bez povijesti epileptičkih napadaja. Koncentracija karbamazepina u trenutku prijma, a tri sata nakon unosa, bila je $179 \mu\text{mol L}^{-1}$, a ocjena kome prema Glasgowskoj ljestvici (engl. Glasgow Coma Scale) bila je 6. Bolesnik je intubiran endotrahealno i liječen 48 sati višekratnim dozama aktivnog ugljena. Dvanaest sati nakon uzimanja otrova zabilježena su dva mioklonička napadaja pri vršnim koncentracijama karbamazepina od $181 \mu\text{mol L}^{-1}$ koji su uspješno liječeni diazepamom. Razine karbamazepina u serumu spustile su se na terapijsku razinu 63 sata nakon unosa te je bolesnik otpušten iz bolnice bez dugotrajnih posljedica. Budući da nema protuotrova za karbamazepin, potporno je liječenje i dalje jedini, ali djelotvoran izbor.

KLJUČNE RIJEČI: *mioklonički napadaj, samoubojstvo, trovanje*

REQUESTS FOR REPRINTS:

Ivana Jukić, M.D.
Department of Internal Medicine, Clinical Hospital Split
Spinčićeva 1, HR-21000 Split, Croatia
E-mail: ivjukic@yahoo.com