

Efficacy and Safety of Nebulized Recombinant Human DNase as Rescue Treatment for Persistent Atelectasis in Newborns: Case-series

Omer Erdeve¹, Nurdan Uras², Begum Atasay¹, Saadet Arsan¹

¹Department of Pediatrics, Division of Neonatology, Ankara University School of Medicine, Ankara, Turkey

²Department of Pediatrics, Division of Neonatology, Fatih University School of Medicine, Ankara, Turkey

Aim To evaluate the efficacy and safety of using recombinant human DNase (rhDNase) in diminishing persistent atelectasis unresponsive to conventional treatment and mucus plugging in newborns with insufficient ability to clear thick and purulent airway secretions.

Methods Twelve newborns (10 preterms), who did not respond to conventional methods, received rhDNase nebulized therapy at a dose of 1.25 mg over a 15-minute period, twice a day (2 hours between the doses) for up to 3 days. The application of the drug was continued for up to 3 days or until the improvement of atelectasis. After a three-day therapy, if atelectasis did not improve, a single dose (1.25 mg) of the same drug in liquid form was administered endotracheally. Clinical (respiration rate, requirement for oxygen concentration) and radiological response (chest x-ray scoring), duration of the treatment, recurrence of atelectasis and requirement for additional therapy were evaluated.

Results Ten out of 12 patients showed rapid clinical and radiological improvement after nebulized treatment. Two patients who did not respond to the three-day regimen received a single dose of the drug endotracheally and both recovered completely. Six patients did not require completion of three day regimen for radiological recovery. Chest x-ray scores and respiratory parameters showed significant improvement after the treatment. The respective median (range) values before and after treatment were 4 (1-5) and 0 (0-4) points for chest x-ray scores, 66 (60-78) and 49 (44-64) breaths/min for respiratory rates, and 45% (35-64) and 30% (21-40) for oxygen requirement. Comparison of pCO₂ before (median, 56 mm Hg; range, 46-64) and after treatment (median, 41 mm Hg; range 38-58) in 7 patients showed significant improvement.

Conclusion In a large series of newborns to receive rhDNase and we demonstrated the usefulness of rhDNase as a mucolytic agent in treating newborns with persistent atelectasis who do not respond to other treatments.

> **Correspondence to:**

Omer Erdeve
10. Cadde Agacseven Sokak
Eliit Blok 3/18 06830
Cayyolu
Ankara, Turkey
omererdeve@yahoo.com

> **Received:** November 21, 2006

> **Accepted:** February 9, 2007

> **Croat Med J. 2007;48:234-9**

Inflammatory response in the airway leads to the necrosis of the respiratory epithelium and sloughing into the airway lumen. Also, tissue edema and mucus production occur, resulting in the formation of thick mucous plugs within the airway lumen. This process leads to a disruption of the normal airflow (1). Some airways become partially or completely occluded, leading to air trapping and hyperinflation or atelectasis (2). Due to the lysis of inflammatory cells, there are large amounts of DNA present in the mucous plugs. DNA is a polyanion molecular compound that contributes to the increased viscosity and adhesiveness of lung secretions. Recombinant human DNase (rhDNase) liquefies the mucus within minutes by hydrolysing extracellular DNA in mucus and transforms it from a viscous gel to a flowing liquid (3). Its nebulized use is accepted as an effective drug in the liquefaction of viscous mucus in patients with cystic fibrosis (3), and anecdotal evidence suggests a beneficial effect in other respiratory diseases, such as respiratory syncytial virus bronchiolitis (1,2) and atelectasis due to mucus plugs (4-6).

Limited therapeutic options in newborns (especially preterms) with unresponsive atelectasis created the need for a new treatment which would be safe and effective. The use of rhDNase for the treatment of atelectasis in newborns is one of the new concepts. To our knowledge, there are only two reports on this issue, which included a total of 3 successfully treated patients (4,5). El Hassan et al (4) described the first case series of successful rhDNase treatment which included 3 preterm neonates with atelectasis. Kupeli et al (5) reported an unsuccessful endotracheal trial on a preterm baby with 29 weeks of gestational age. Beside these reports, Marcus et al (2) reported 2 mechanically ventilated infants with respiratory syncytial virus bronchiolitis just beyond newborn age. These patients were treated by nebulized rhDNase, upon which clinical and radiological parameters improved quickly. Because of limited data in newborns, there is a need

to confirm the efficacy and safety of rhDNase treatment in a larger series.

We hypothesized that rhDNase would diminish atelectasis and mucus plugging in newborns with insufficient ability to clear thick and purulent airway secretions due to small airway caliber and ineffective cough mechanisms. We also aimed to evaluate clinical and radiological changes in newborns who received rhDNase for persistent atelectasis unresponsive to treatment with physiotherapy and other medical treatments.

Patients and methods

Patients

Twelve newborns who did not respond to conventional methods such as frequent positioning, chest physiotherapy, aspiration, selective endotracheal suctioning, and medical treatment by salbutamol and N-acetylcysteine to release the mucus plugging were enrolled to receive rhDNase. The therapy was explained to the parents, and informed consent was obtained from all families. Because rhDNase was administered as a part of patient's treatment and not as a medical trial, formal approval from the local ethic committee was not required, and therefore was not requested.

Ten out of 12 patients were preterm. Gestational age of preterm patients ranged between 25 to 37 weeks and birth weight between 760 and 2250 g. Two term babies were postoperative patients who had birth weight of 3700 g and 3300 g. Male to female ratio was 0.7 (5/7). Half of the patients were under mechanical ventilation when they developed atelectasis (Table 1).

Treatment

Patients received rhDNase (Pulmozyme[®], Roche, Genentech Inc, San Francisco, CA, USA) nebulized therapy at a dose of 1.25 mg twice daily (2 hours between the doses) for up to 3 days. The

Table 1. Demographic and treatment data of the study group

Parameter	Finding
Gestation week (median, range)	32 (25-39)
Birth weight (median, range) (g)	2187 (760-3700)
Sex (male/female)	5/7
On ventilator/no ventilator	6/6
Age during DNase treatment (median, range) (days)	11 (4-28)
Duration of nebulized DNase treatment (median, range) (days)	2.5 (1-3)

dose was based on the only successful report on preterm newborns by El Hassan et al (4). The drug was administered by a nebulizer (Aeroneb Professional Nebulizer System, Aerogen, Dangan, Ireland) over 15 minutes. Two hours after the second dose, appropriate physiotherapy, frequent positioning, and suctioning were performed to increase the drainage of the liquefied mucus. Chest radiogram was repeated two hours after the second dose to evaluate the efficacy of the drug. If the atelectasis improved the treatment was terminated, otherwise the administration of the drug was continued for up to 3 days. After the three-day therapy, if there was no improvement in atelectasis, the drug was administered as a single dose of 1.25 mg in a liquid form endotracheally.

Analysis

Gestational age, birth weight, sex, and primary diagnosis of all patients were recorded. After a complete physical examination, all patients had chest radiograms that demonstrated the localization of the atelectasis. If needed, arterial blood gas analysis was performed before and after the last dose of the treatment.

Anteroposterior chest x-rays were coded and interpreted retrospectively by radiologists who were blinded to the study. A scoring system based on the available literature was used (7). It was based on the points for atelectasis, hyperinflation, and mediastinal shift. The presence or absence of hyperinflation and mediastinal shift was scored as 1 and 0, respectively. Atelectasis scoring was performed for each lobe of the lung and a partial atelectasis was scored as 1 point, whereas

a total atelectasis was scored as 2 points. These results were summed for each chest x-ray and the scores of the chest x-rays taken 2 hours after the treatment were compared with the scores before the treatment. Beside the radiological and arterial blood gas response, all patients were evaluated clinically (respiration rate, requirement for oxygen concentration), duration of the treatment, recurrence of atelectasis, and requirement of additional therapy on follow-up.

Results

Ten out of 12 patients showed rapid clinical and radiological improvement after nebulized treatment (Figure 1 and Figure 2). Two patients who did not respond to the three-day regimen required a single instillation of the drug endotracheally and both of them recovered completely

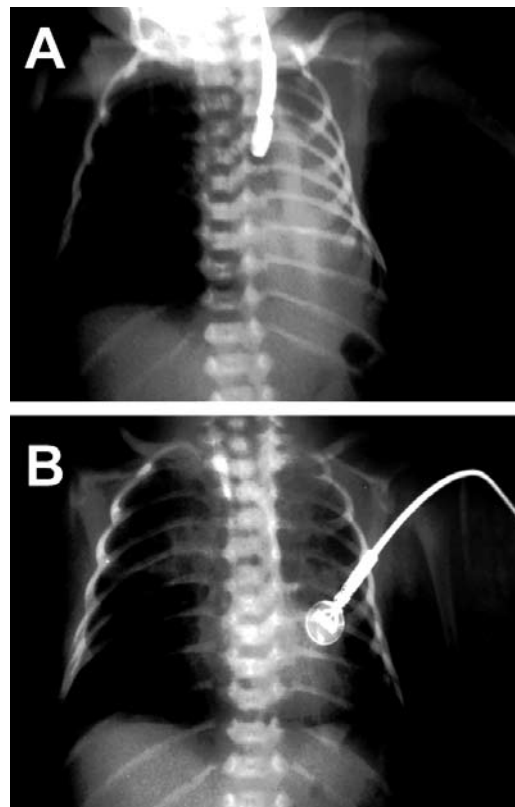


Figure 1. rhDNase treatment resolved almost complete atelectasis. Left side total atelectasis in Case 8 responded to only one day regimen of rhDNase by a nebulizer.

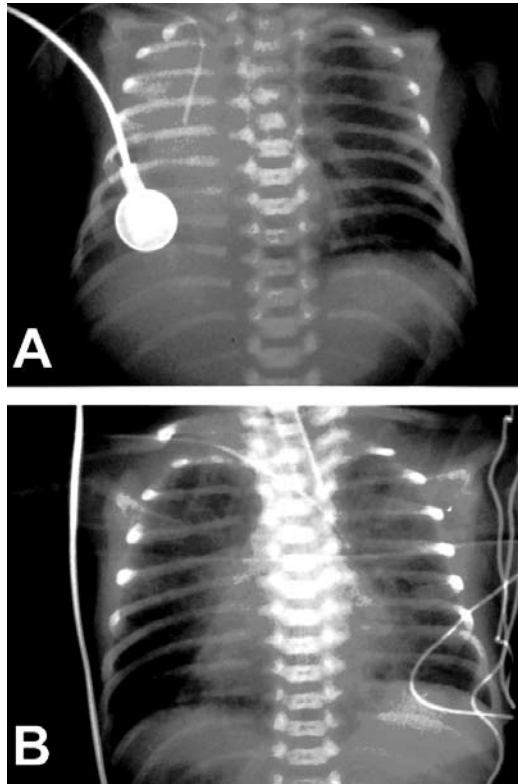


Figure 2. Localization of percutaneous central venous catheter in Case 4 demonstrates the shift of the heart due to right total atelectasis (A); this case was on mechanical ventilation and treated by nebulized rhDNase for three days (B).

(Table 2). Half of the patients did not require completion of the three-day regimen for radiological recovery. Two patients developed recurrent atelectasis; one a day and the other six days after the treatment. Both patients received a second-regimen of the drug by a nebulizer and recovered in two days. No adverse event was

observed for both administration options of rhDNase.

Chest x-ray scores and respiratory parameters such as respiratory rate and oxygen requirement showed significant improvement after the treatment (Table 3). Arterial blood gas analysis was obtained from 7 patients (6 of them were on mechanical ventilation) and comparison of pCO₂ before and after the last dose of nebulized rhDNase showed significant improvement (Table 3).

Table 3. Change of radiological and respiratory parameters (median, range) of patients before and after the nebulized rhDNase treatment

Parameter	Before treatment	After treatment	P
Chest X-ray score	4 (1-5)	0 (0-4)	0.005
Respiratory rate	66 (60-78)	49 (44-64)	0.002
O ₂ requirement (FiO ₂) (%)	45 (35-60)	30 (21-40)	0.005
pCO ₂ * (mmHg)	56 (46-64)	41 (38-58)	0.018

*pCO₂ was obtained from 7 newborns.

Discussion

Six of our 12 patients were under mechanical ventilation and received nebulized rhDNase by an adaptor connected to the circuit. Riethmueler et al (8) reported that rhDNase treatment in mechanically ventilated children decreased the incidence of atelectasis, median ventilation time, median length of intensive care stay, and mean costs in patients. Excessive or thick pulmonary secretions are a common clinical challenge and the presence of mucus accumulation in a newborn lung is a risk factor for pulmonary infection,

Table 2. The distribution of the patients according to their diagnosis, localization of atelectasis, and the rhDNase treatment*

Case No.	Primary diagnosis	Localization of atelectasis	Mechanical ventilation	Postnatal age at treatment (day)	Duration of treatment (day)	Endotracheal rhDNase	Recurrent atelectasis	Repeated rhDNase treatment
1	RDS	right total		28	3		+	+
2	RDS	left total		22	3	+		
3	RDS	right middle	+	10	2			
4	RDS+VAP	right total	+	7	3			
5	RDS+VAP	right upper	+	9	3	+		
6	HIE	left total		12	2			
7	RDS+VAP	left upper	+	14	2			
8	RDS	left total		9	1			
9	RDS+VAP	right upper	+	4	1		+	+
10	Congenital heart disease (postop)	left total	+	21	1			
11	Cricopharyngeal achalasia	right upper		6	3			
12	RDS	right total		24	3			

*Abbreviations: RDS – respiratory distress syndrome; VAP – ventilator associated pneumonia; HIE – hypoxic ischemic encephalopathy.

prolonged artificial ventilation, damage to the lungs and indirectly to other organs (4,9). Treatment of atelectasis with chest physiotherapy or nebulized bronchodilator is not always effective, but the rescue use of rhDNase was reported to be effective in reestablishing airway patency. Its efficacy has been well documented in cystic fibrosis, whereas case reports have described a beneficial effect in other respiratory disorders (2-5). Hendriks et al (7) reported that the use of rhDNase for atelectasis of presumably infectious origin in non-cystic fibrosis pediatric patients resulted in rapid clinical improvement within two hours and radiologic improvement in the large majority of children within 24 hours. Sixteen patients in this study were younger than one year, and two were born prematurely, but were 6 and 7 months of corrected age at the time of admission. The rhDNase dose was either 2.5 mg administered twice daily with a jet nebulizer in children breathing spontaneously or 10% of that dose diluted with 5 mL NaCl 0.9% and given slowly as droplets into endotracheal tube during 30 minutes twice daily. The dose we used was equal to half of the dose in the study by Hendriks et al (7) and we administered the drug to all patients by nebulizer even when they were on mechanical ventilation. Chest x-ray scoring that we used was similar to the study of Hendriks et al (7) and both studies showed marked improvement in chest x-ray scores and respiratory response. Nasr et al (1) used a different chest x-ray scoring in patients with RSV bronchiolitis but showed a significant improvement in the chest x-ray with the use of nebulized rhDNase, compared with a significant worsening in the placebo group.

There are only few case reports on rhDNase use in newborns. Merkus et al (2) administered 2.5 mg nebulized dose of rhDNase twice daily to two mechanical ventilated infants just beyond newborn age and reported that following administration of nebulized rhDNase, clinical and radiological parameters improved quickly. Kupeleli et al (5) administered rhDNase of 0.2 mg per

nebulizer endotracheally over 15 minutes, once a day for 5 days to a patient who was a preterm with 29 weeks of gestational age. They reported that mucus plugs were seen to liquefy in response to the drug, but even though frequent suctioning continued, profuse secretions created new atelectatic areas (5). El Hassan et al (4) administered rhDNase as rescue treatment to three mechanically ventilated preterms (two bronchopulmonary dysplasia, one respiratory distress syndrome) and concluded that the rescue use of DNase was effective in reestablishing airway patency. This was the only series in newborns for rescue treatment and our dose of nebulized rhDNase was based on this literature.

Our experience showed that this treatment option is safe and effective in newborns who do not respond to conventional treatments. Inhalation of rhDNase seems to have no serious side effects. An increased incidence of voice alterations, laryngitis, pharyngitis, dyspepsia, and facial edema were reported in some patients in literature, but in our patients this was not the case (10).

After the three-day treatment, two patients needed to receive rhDNase in a liquid form endotracheally in the same dose. We think that endotracheal instillation of rhDNase should be considered in cases of persistent atelectasis unresponsive to nebulized treatment. Wills et al showed that rhDNase did not improve ciliary transportability (11). They postulated that gravitational drainage of the thinned mucus may be easier from the upper lobes. Newborn's position does not permit the gravitational drainage so we speculate that chest physiotherapy and appropriate positioning of the baby may facilitate the drainage of the thinned mucus from the atelectatic lobe.

To the best of our knowledge, this is the largest published study on usefulness of rhDNase as a mucolytic agent in treating newborns with persistent atelectasis who do not respond to other types of treatment. We conclude that our series with nebulized rhDNase demonstrates effective,

safe and easy therapeutic option for use in treating persistent atelectasis in newborns on the basis of clinical and radiological improvement. Although the results of our series are promising, the study was limited with a small number of patients, retrospective nature of the study, and the lack of a comparison, so that further randomized controlled trials are needed to confirm our results and investigate the clinical changes under appropriate dosage of this drug.

References

- 1 Nasr SZ, Strouse PJ, Soskolne E, Maxvold NJ, Garver KA, Rubin BK, et al. Efficacy of recombinant human deoxyribonuclease I in the hospital management of respiratory syncytial virus bronchiolitis. *Chest*. 2001;120:203-8. [Medline:11451839](#)
- 2 Merkus PJ, de Hoog M, van Gent R, de Jongste JC. DNase treatment for atelectasis in infants with severe respiratory syncytial virus bronchiolitis. *Eur Respir J*. 2001;18:734-7. [Medline:11716180](#)
- 3 Fitzgerald DA, Hilton J, Jepson B, Smith L. A crossover, randomized, controlled trial of dornase alfa before versus after physiotherapy in cystic fibrosis. *Pediatrics*. 2005;116:e549-54. [Medline:16147970](#)
- 4 El Hassan NO, Chess PR, Huysman MW, Merkus P, de Jongste JC. Rescue use of DNase in critical lung atelectasis and mucus retention in premature neonates. *Pediatrics*. 2001;108:468-70. [Medline:11483817](#)
- 5 Kupeli S, Teksam O, Dogru D, Yurdakok M. Use of recombinant human DNase in a premature infant with recurrent atelectasis. *Pediatr Int*. 2003;45:584-6. [Medline:14521538](#)
- 6 Kamin W, Klar-Hlawatsch B, Truebel H. Easy removal of a large mucus plug with a flexible paediatric bronchoscope after administration of rhDNase (Pulmozyme). *Klin Padiatr*. 2006;218:88-91. [Medline:16506110](#)
- 7 Hendriks T, de Hoog M, Lequin MH, Devos AS, Merkus PJ. DNase and atelectasis in non-cystic fibrosis pediatric patients. *Crit Care*. 2005;9:R351-6. [Medline:16137347](#)
- 8 Riethmueller J, Borth-Bruhns T, Kumpf M, Vonthein R, Wiskirchen J, Stern M, et al. Recombinant human deoxyribonuclease shortens ventilation time in young, mechanically ventilated children. *Pediatr Pulmonol*. 2006;41:61-6. [Medline:16265663](#)
- 9 O'Donnell AE, Barker AF, Ilowite JS, Fick RB. Treatment of idiopathic bronchiectasis with aerosolized recombinant human DNase I. rhDNase Study Group. *Chest*. 1998;113:1329-34. [Medline:9596315](#)
- 10 Bryson HM, Sorokin EM. Dornase alfa. A review of its pharmacological properties and therapeutic potential in cystic fibrosis. *Drugs*. 1994;48:894-906. [Medline:7533697](#)
- 11 Wills PJ, Wodehouse T, Corkery K, Mallon K, Wilson R, Cole PJ. Short-term recombinant human DNase in bronchiectasis. Effect on clinical state and in vitro sputum