

Use of the bubaline acellular diaphragm matrix for umbilical hernioplasty in pigs

Vineet Kumar^{1,2*}, Anil K. Gangwar², Naveen Kumar², and Himani Singh²

¹*Department of Veterinary Surgery and Radiology, College of Veterinary Science and Animal Husbandry, Junagadh, Gujarat, India*

²*Division of Surgery, Indian Veterinary Research Institute, Izatnagar, Uttar Pradesh, India*

KUMAR, V., A. K. GANGWAR, N. KUMAR, H. SINGH: Use of the bubaline acellular diaphragm matrix for umbilical hernioplasty in pigs. Vet. arhiv 85, 49-58, 2015.

ABSTRACT

Acellularization of xenogenic biomaterials has been highly desired for implantation without considerable adverse inflammatory and immune responses. Therefore, the present study was undertaken to acellularize the diaphragm of buffalo origin and to evaluate the efficacy of this prepared acellular diaphragm matrix (ADM) scaffolds for the repair of umbilical hernia in pigs. Buffalo diaphragms were acellularized with different concentrations of sodium deoxycholate over a range of periods. Produced ADM scaffolds were used during umbilical hernioplasty in 12 crossbred Landrace pigs. Harvested serum samples on post-implantation days (0, 15 and 30) were subjected to sodium dodecyl sulfate (SDS) polyacrylamide gel electrophoresis (PAGE) to observe serum protein distribution pattern. Treatment with 2 % sodium deoxycholate lead to complete acellularization of the bubaline diaphragm at 48 h. Microscopic examination of the detergent treated matrix confirmed complete extraction of stromal cells and orderly arranged collagen fibres. All the hernias repaired with ADM remained sound over a period of 3 months. The serum protein distribution on post-implantation day 15 was found different from day zero and becomes normal on day 30. All the hernias implanted with ADM healed completely without graft rejections. The present study suggested that 2 % sodium deoxycholate can be used for complete acellularization of bubaline diaphragm, and produced ADM may be used safely for umbilical hernioplasty in pigs.

Key words: acellular diaphragm matrix, buffalo, pigs, SDS-PAGE, umbilical hernia

Introduction

Umbilical hernia is one of the most common developmental defects in pigs (POLLICINO et al., 2007). The only effective treatment for this defect is reconstructive

*Corresponding author:

Dr. Vineet Kumar, Assist. Prof., Department of Veterinary Surgery and Radiology, College of Veterinary Science and Animal Husbandry, Junagadh-362001, Gujarat, India. Phone: +91 96 0135 4407; Fax: +91 285 2670 722; E-mail: bharadwaj374@gmail.com

surgery to restore integrity of the abdominal wall and prevent incarceration and strangulation of herniated contents (OBER et al., 2008). Tight suturing to approximate and close these defects may lead to wound dehiscence, recurrent hernias and even non-healing of the wound (MATTHEWS et al., 2003). The use of prosthetic material for hernioplasty is required when the hernial ring size exceeds 3 cm in diameter (VILAR et al., 2011). However, hernioplasty with nonabsorbable synthetic mesh prostheses has been associated with complications, such as: mesh extrusion, fistula formation, wound infections, seroma, and adhesions (MOLLOY et al., 1991). Recently, acellularized biomaterials, composed of an extracellular matrix (ECM), harvested from a variety of allogenic and xenogenic tissues, have been utilized in an effort to address some of the limitations associated with synthetic materials (FRANKLIN et al., 2008; KUMAR et al., 2012; KUMAR et al., 2013a,b,c,d). The potential benefits of biological materials include improved infection resistance, host tissue ingrowth, and less adhesion formation (GAERTNER et al., 2007). However, xenogeneic biologic materials are recognized as foreign by the host and result in an adverse inflammatory response or overt immune-mediated rejection of the tissue (ERDAG and MORGAN, 2004). Hence, xenogeneic biological materials are acellularized to minimize their immunogenicity (GILBERT et al., 2006). Sodium dodecyl sulfate polyacrylamide gel electrophoresis (SDS-PAGE) is a widely used technique for protein separation, based on their molecular weights (LAEMMLI, 1970). In this study, SDS-PAGE analysis was used to make a comparison between serum protein distribution patterns found before and after implantations. An acellular diaphragm matrix was used successfully for the repair of abdominal wall defects in rabbits (SINGH et al., 2008).

Although the results of the preclinical animal study have been promising, studies on the use of acellular diaphragm matrix grafts for the repair of hernias in clinical situations are not available. Therefore, the present study was undertaken to acellularize diaphragms of buffalo origin and to evaluate the efficacy of these prepared acellular diaphragm matrix (ADM) scaffolds for the repair of umbilical hernia in pigs.

Materials and methods

All the chemicals used in this study were purchased from Sigma (St Louis, MO, USA), unless otherwise indicated.

Harvest and preparation of the acellular diaphragm matrix (ADM). Fresh diaphragms of water buffalo (*Bubalus bubalis*) origin were collected from a local abattoir and immediately preserved in chilled (4 °C) sterile 1x phosphate buffered saline (PBS, pH 7.4) containing 0.1 % amikacin (Mikacin, Aristo Pharmaceuticals Private Limited, Mumbai, India), and 0.2025 % ethylenediaminetetraacetic acid. The tendinous portion of each diaphragm was excised and washed thoroughly with sterile PBS to remove all the adherent blood. After the initial washing, the diaphragm was cut into the desired size and

then placed in different concentrations of sodium deoxycholate solution (0.5 %, 1 %, 2 % and 4 %) at a constant temperature (37 °C) on an orbital shaker under physical agitation (180 rotations/minute). Representative tissue samples collected after different periods of detergent treatments (12, 24, 48 and 72 h) were fixed in 10 % neutral buffered formalin, serially dehydrated with ethanol, cleared in xylene and embedded in paraffin wax. Sections (5µm) were cut and stained with hematoxylin-eosin for histological analysis, to optimize the acellularization protocols (Fig. 1a and b). The resulting ADM was rinsed extensively (6 times of 2 h each) with PBS under constant agitation (180 rotations per minute) and temperature (37 °C) on an orbital shaker to remove the residual chemicals. Further, the prepared matrices were stored in a sterile PBS solution, containing 0.1 % amikacin and 0.1 % sodium azide at -20 °C until use. The present study was in full compliance with the Institutional Animal Ethics Committee, Indian Veterinary Research Institute, Izatnagar (IVRI), Uttar Pradesh, India.

Animals. Twelve crossbred Landrace pigs with congenital umbilical hernias (seven females and five males), weighing from 17 to 25 kg (mean mass, 19.33 ± 2.34 kg) and between 8 and 12 weeks of age (mean age, 9.33 ± 0.88 weeks), were used in this study. Between September 2009 and March 2012, these animals were presented to the Surgery Unit of the Referral Veterinary Polyclinics, IVRI from Piggery Unit, Livestock Production and Management Section, IVRI. On physical examination, a painless, reducible soft swelling was observed at the umbilicus (Fig. 2). Multiple loops of bowel could be palpated traversing the hernial ring. At the time of presentation the animals had normal temperature, respiration, and pulse rates. In each case, before implantation of the prepared ADM scaffolds, the Farm Manager of the Piggery Unit, Livestock Production and Management Section, IVRI was informed, and written consent was obtained.

Surgical procedure. Each pig received a pre-operative intramuscular injection of 25 µg/kg atropine sulfate (Atropine Sulphate, Morvel Laboratories Private Limited, Mehsana, India) and an intravenous injection of 4.0 mg/kg xylazine HCl (Xylaxin, Indian Immunologicals Limited, Hyderabad, India). An antibiotic, ceftriaxone (Intacef, Intas, Ahmedabad, India), at a dose of 20 mg/kg, was administered intravenously before and after surgery. General anesthesia was induced with an intravenous injection of 8 mg/kg ketamine HCl (Aneket, Neon Laboratories Limited, Thane, India) and maintained with repeated boluses of xylazine HCl and ketamine HCl, as needed. The animal was then positioned in dorsal recumbency, and the ventral abdomen was prepared for aseptic surgery. To expose the hernial sac, an elliptical skin incision was made that spanned the length of the hernia and extended 2 cm beyond the cranial and caudal margins of the hernial ring. Forcipressure was used to control subcutaneous hemorrhage, if any. The hernial sac was dissected from the overlying skin, and dissection was continued laterally to expose the hernial ring and the external sheath of the rectus abdominis muscle. The

hernial sac was opened and the contents were reduced. The ADM graft material, exceeding the defect by 2 cm in all directions, was adjusted for adequate closure of the hernial ring. An appropriately sized piece of ADM graft with a pre-placed horizontal mattress suture of number 2 surgical black braided silk (Ethicon, Aurangabad, India) with long ends, attached to its cranial, caudal, and mid-lateral edges, was introduced into the abdomen through the hernial ring. The ADM was oriented within the abdomen and the suture ends retrieved using a non traumatic needle. Each of the sutures was tied, with the knots resting on the external sheath of the rectus abdominis muscle, thus provisionally securing the ADM to the internal sheath of the rectus abdominis muscle (Fig. 3). While the graft was being implanted, the surgical site was lavaged periodically with physiological saline, containing 0.1 % amikacin. Excess skin was excised, and the subcutaneous tissues were closed using number 2-0 polyglactin 910 (Vicryl, Johnson and Johnson Limited, Ethicon, Aurangabad, India) placed in a simple continuous suture pattern. The skin incision was then closed using number 2 polyamide (Sterilon, Stericat Gutstrings (P) Limited, Delhi, India) in a horizontal mattress suture pattern.

Postoperative care. Postoperative analgesia was provided by an intramuscular injection of 0.2 mg/kg meloxicam (Melonex, Intas Pharmaceuticals Limited, Ahmedabad, India) for 3 days. Antibiotic therapy was continued for 5 days. The suture line was dressed daily with 0.1 % povidone iodine solution. Skin sutures were removed on postoperative day 12. To assess the integrity of the repair, clinical evaluation of each pig was performed for at least up to 3 months at 4-weekly intervals. The cosmetic appearance of the healed surgical site was graded according to the degree of visible or palpable scar tissue deposition or fibrosis, and the loss of a normal contour as either minimal, moderate, or marked.

SDS-PAGE analysis. From each pig, a 5 mL blood sample was collected from the anterior venacava before implantation and on days 15 and 30 post-implantation. Serum was harvested and stored at -20 °C until use. Briefly, serum samples were mixed with equal volumes of sample buffer (1×sample buffer: 62.5 mM Tris, 2 % SDS, 10 % glycerol, 0.0125 % bromophenol blue, pH 6.8). Samples were heat-denatured for 5 minutes at 90°C and were subjected to SDS-PAGE analysis, as described by Laemmli (LAEMMLI, 1970), using 4 % stacking gels and 10 % resolving gels in a Mini Protean II unit (Bio-Rad Laboratories, Hercules, CA, USA) at 50 mA/gel. After fractionation, the gel was stained in a staining solution (50 % methanol, 10 % glacial acetic acid, 0.25 % Coomassie Brilliant Blue R-250) for 10 minutes. Next, the gel was destained in a solution containing 250 mL methanol, 100 mL acetic acid, and 650 mL distilled water, until protein fractions appeared clear.

Data analysis. All data are presented as mean ± SEM and were analyzed by the Microsoft Excel program (Microsoft, Redmond, WA, USA).

Results

Harvest and preparation of acellular diaphragm matrix. A histological photograph of the tendinous portion of the diaphragm, with no treatment, showed cellularity (Fig. 1a). Treatment at lower concentrations (0.5 and 1 % sodium deoxycholate) and shorter incubation periods (12 and 24 h) resulted in retention of large numbers of whole cells, while a higher concentration (4 % sodium deoxycholate) and longer incubation period (72 h) resulted in extensive damage to the natural three-dimensional collagen structures within the prepared matrix. In comparisons to the aforementioned acellularization solutions and incubation periods, 2 % sodium deoxycholate, incubated for 48 h at 37 °C under physical agitation, is the most effective in preserving the distinctive, natural, three-dimensional collagen structures within the prepared matrix. Histological analysis of the acellular matrix showed that the cells had been completely removed and the collagen fibres were orderly arranged (Fig. 1b).

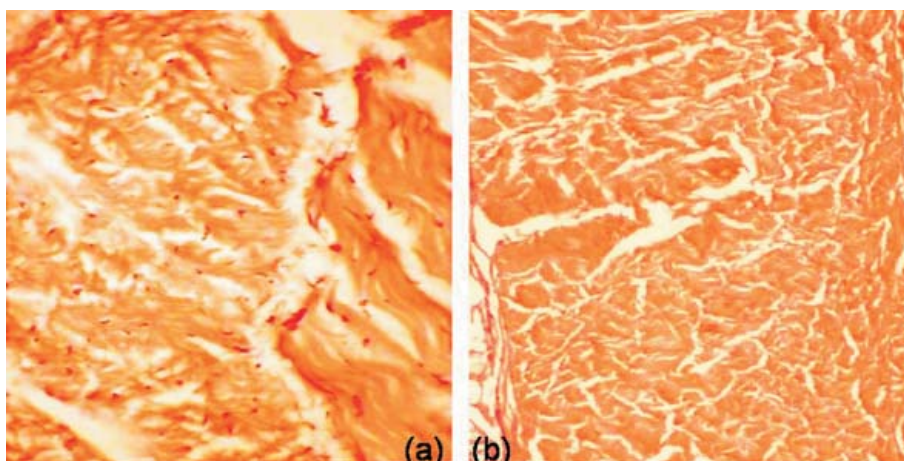


Fig. 1. (a) Histological photograph of untreated native buffalo diaphragm (H&E, $\times 40$); (b) Histological photograph of 2 % sodium deoxycholate treated buffalo diaphragm

Gross and clinical observations. The hernial ring size varied between 4 and 7.5 cm (mean size, 5.50 ± 0.50 cm) in diameter. All the cases were reducible hernias. Hernial contents were variable and consisted of the omentum or small intestine, and they were located within the hernial sac. Mean surgical time (skin incision to closure) was 60 ± 5.78 minutes (range, 50-70 minutes). Temperature, pulse and respiration rates were increased during the first 48 h post-implantation.

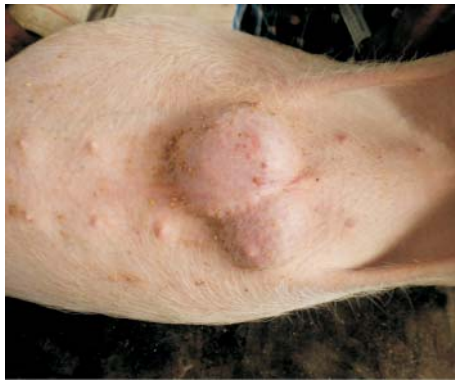

Fig. 2. Image showing an umbilical hernia in a female crossbred Landrace pig

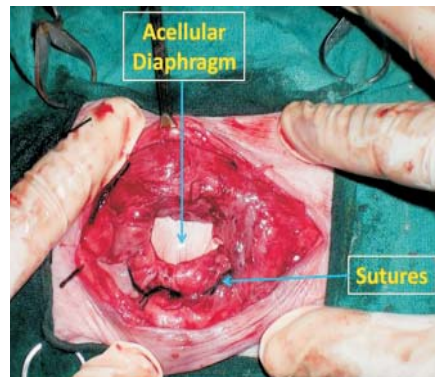


Fig. 3. Intraoperative image showing repair of an umbilical hernia in a female crossbred Landrace pig with an acellular diaphragm matrix as an inlay graft

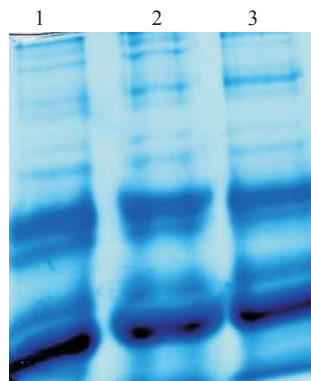


Fig. 4. SDS-PAGE of pig serum collected at intervals after implantation of acellular diaphragm matrix to repair an umbilical hernia. Lane 1-day 0; Lane 2-day 15; Lane 3-day 30.

These signs gradually subsided, and became normal within 4-5 days. Signs of mild somatic pain on palpation were observed in all the animals during the first 3 post-implantation days. These signs were satisfactorily managed with nonsteroidal anti-inflammatory drugs. Mild inflammatory oedema developed during the first 5 days after surgery. The oedema reduced gradually, until complete resolution in all cases between 7 and 12 days after surgery. The use of non-absorbable silk suture materials provided no complications. At the end of the first post-implantation week, a thick and slightly hard

mass of implanted ADM graft size was palpated at the site of the hernioplasty. The thick and hard mass of tissue at the site of implantation was palpable until the end of the second post-implantation week. These masses subsided by the end of the third post-implantation week. After the fourth post-implantation week the masses become thinner and fibrous, and were difficult to feel on palpation. The umbilical region looked normal on inspection. The skin over the graft adhered firmly to the underlying tissue and was healthy and non-painful on firm and deep palpation. All the animals recovered uneventfully without clinical signs of wound dehiscence, infections, or recurrence of hernia. All the animals were observed up to 3 months after hernioplasty and the xenogenic ADM graft was found to be healthy.

SDS-PAGE analysis. The serum protein distribution pattern on post-implantation day 15 was found different in all samples as compared to day zero and became normal on post-implantation day 30 (Fig. 4).

Discussion

Acellularization of xenogenic biomaterials is highly desirable for implantation without considerable adverse inflammatory and immune responses. In the present study the tendinous portion of diaphragms of buffalo origin was acellularized using an ionic biological detergent, sodium deoxycholate. The results of this study demonstrated that 2 % sodium deoxycholate incubated for 48 h at 37 °C under physical agitation was the most effective for acellularization of bubaline diaphragms, with retention of the distinctive, natural, three-dimensional collagen structures within the prepared matrix. Similar results were reported by KUMAR et al. (2013e) when bubaline small intestine was treated with 2 % sodium deoxycholate for 36 h at 37 °C under physical agitation. In another study, sodium deoxycholate was found to be effective for complete cell removal from native fish swim bladders, without causing disruption to the natural, three-dimensional collagen structures (KUMAR et al., 2013f). The results of this study also support the notion that sodium deoxycholate is a viable option for acellularization of the bubaline diaphragm.

In the present study, acellularized diaphragm matrices were used for umbilical hernioplasty in pigs using the aforementioned technique. The results of this study demonstrated the uncomplicated healing of the repaired area, without recurrence or graft rejection in any of the pigs. Similar results were reported in another study in which 6 goats with abdominal wall hernias underwent hernioplasty using an allogenic acellular dermal matrix (KUMAR et al., 2013b). The greater success rate might be due to the acellular nature of bubaline diaphragms, which are composed of collagen. Natural collagenous materials are used for surgical repair because of their inherent low antigenicity and their ability to integrate with surrounding tissue (VAN DER LAAN et al., 1991). Furthermore, acellular tissue matrices are biocompatible, slowly degrade upon implantation and are replaced and

remodelled by the extracellular matrix proteins, synthesized and secreted by ingrowing host cells (PARIENTE et al., 2001). The incidence of post-operative complications associated with retroperitoneal placement of a synthetic mesh material, such as tearing of the internal abdominal oblique muscle and incisional edema and drainage, is considerably high (ELCE et al., 2006). However, in the current study, no post-operative complications were observed after retroperitoneal placement of an ADM graft in any animals for at least up to 3-months after the hernioplasty. Similar results were reported in bubaline (KUMAR et al., 2012; KUMAR et al., 2014), bovine (KUMAR et al., 2013a), caprine (KUMAR et al., 2013b), and equine (KUMAR et al., 2013c,d) studies. The acellular matrix possesses the appropriate mechanical properties and induces appropriate interaction with the host cells that results in the regeneration of functional tissues (VOYTIK-HARBIN et al., 1998).

SDS-PAGE analysis of the serum of pigs with implants revealed changed protein distribution patterns on day 15 as compared to days 0 and 30. This may be attributed to an inflammatory reaction in response to the implants and surgical trauma. This may be due to the increased production of plasma proteins by the liver during inflammation, fibroblastic proliferation, neovascularization, and collagen synthesis in the graft (SCHREIBER et al., 1982).

Conclusion

The findings of the present study suggest that 2 % sodium deoxycholate at 48 h can be used for complete acellularization of bubaline diaphragms and the ADM produced may be used safely for umbilical hernioplasty in pigs. Nevertheless, further research is warranted in order to verify the immunogenic properties of this biomaterial after xenogenic transplantation into various (patho)physiological sites.

Acknowledgements

The authors acknowledge the financial assistance received from the Department of Biotechnology, Ministry of Science and Technology, New Delhi India (Grant no. BT/PR/5001/AAQ/01/192/2004), to carry out this research work.

Conflict of interest

The authors declare that they have no conflict of interest.

References

- ELCE, Y. ., B. M. KRAUS, J. A. ORSINI (2005): Mesh hernioplasty for repair of incisional hernias of the ventral body wall in large horses. *Equine Vet. Educ.* 17, 252-256.
- ERDAG, G., J. R. MORGAN (2004): Allogeneic versus xenogenic immune reaction to bioengineered skin grafts. *Cell Transplant.* 13, 701-712.
- FRANKLIN, M. E. Jr., J. M. TREVINO, G. PORTILLO, I. VELA, J. L. GLASS, J. J. GONZALEZ (2008): The use of porcine small intestinal submucosa as a prosthetic material for laparoscopic

- hernia repair in infected and potentially contaminated fields: long-term follow-up. *Surg. Endosc.* 22, 1941-1946.
- GAERTNER, W. B., M. E. BONSAK, J. P. DELANEY (2007): Experimental evaluation of four biologic prostheses for ventral hernia repair. *J. Gastrointest. Surg.* 11, 1275-1285.
- GILBERT, T. W., T. L. SELLAROA, S. F. BADYLAK (2006): Decellularization of tissues and organs. *Biomaterials* 27, 3675-3683.
- KUMAR, V., J. DEVARATHNAM, A. K. GANGWAR, N. KUMAR, A. K. SHARMA, A. M. PAWDE, H. SINGH (2012): Use of acellular aortic matrix for reconstruction of abdominal hernias in buffaloes. *Vet. Rec.* 170, 392.
- KUMAR, V., N. KUMAR, A. K. GANGWAR, A. C. SAXENA (2013a): Using acellular aortic matrix to repair umbilical hernias of calves. *Australian Vet. J.* 91, 251-253.
- KUMAR, V., N. KUMAR, D. D. MATHEW, A. K. GANGWAR, A. C. SAXENA, V. REMYA (2013b): Repair of abdominal wall hernias using acellular dermal matrix in goats. *J. Appl. Anim. Res.* 41, 117-120.
- KUMAR, V., A. K. GANGWAR, D. D. MATHEW, R. A. AHMAD, A. C. SAXENA, N. KUMAR (2013c): Acellular dermal matrix for surgical repair of ventral hernia in horses. *J. Equine Vet. Sci.* 33, 238-243.
- KUMAR, V., N. KUMAR, H. SINGH, D. D. MATHEW, K. SINGH, R. A. AHMAD (2013d): An acellular aortic matrix of buffalo origin crosslinked with 1-ethyl-3-(3-dimethylaminopropyl) carbodiimide hydrochloride for the repair of inguinal hernia in horses. *Equine Vet. Educ.* 25, 398-402.
- KUMAR, V., N. KUMAR, H. SINGH, A. K. GANGWAR, R. DEWANGAN, A. KUMAR, R. B. RAI (2013e): *In vitro* evaluation of bubaline acellular small intestinal matrix. *Int. J. Bioassays* 2, 581-587.
- KUMAR, V., N. KUMAR, H. SINGH, A. K. GANGWAR, R. DEWANGAN, A. KUMAR, R. B. RAI (2013f): Effects of crosslinking treatments on the physical properties of acellular fish swim bladder. *Trends Biomat. Artif. Organs* 27, 93-101.
- KUMAR, N., D. D. MATHEW, A. K. GANGWAR, V. REMYA, M. A. MUTHALAVI, S. K. MAITI, A. K. SHARMA (2014): Reconstruction of large ventro-lateral hernia in a buffalo with acellular dermal matrix: a method for treating large hernias in animals. *Vet. arhiv* 84, 691-699.
- LAEMMLI, U. K. (1970) Cleavage of structural proteins during the assembly of the head of bacteriophage T₄. *Nature* 227, 680-685.
- MATTHEWS, B. D., B. L. PRATT, H. S. POLLINGER, C. L. BACKUS, K. W. KERCHER, R. F. SING, B. T. HENIFORD (2003): Assessment of adhesion formation to intra-abdominal polypropylene mesh and polytetrafluoroethylene mesh. *J. Surgical Res.* 114, 126-132.
- MOLLOY, R. G., K. T. MORAN, R. P. WALDRON, M. P. BRADY, W. O. KIRWAN (1991): Massive incisional hernia: abdominal replacement with marlex mesh. *Br. J. Surg.* 78, 242-244.
- OBER, C., A. MUSTE, L. OANA, N. MATES, F. BETEG, S. VERES (2008): Using of prosthetic biomaterials in large animals: modern concepts about abdominal wall defects approach. *J. Central Eur. Agric.* 9, 575-580.

- PARIENTE, J. L., B. S. KIM, A. ATALA (2001): In vitro biocompatibility assessment of naturally derived and synthetic biomaterials using normal human urothelial cells. *J. Biomed. Mater. Res.* 55, 33-39.
- POLLICINO, P., M. GANDINI, G. PERONA, M. MATTONI, A. M. FARCA (2007): Use of Elastrator® rings to repair umbilical hernias in young swine. *J. Swine Health Prod.* 15, 92-95.
- SCHREIBER, G. S., G. HOWLETTE, M. NAGASHIMA, A. MILLERSHIP, H. MARTIN, J. URBAN, L. KOTLER (1982): The acute phase response of plasma proteins synthesis during experimental inflammation. *J. Biol. Chem.* 257, 10271-10277.
- SINGH, J., N. KUMAR, A. K. SHARMA, S. K. MAITI, T. K. GOSWAMI, A. K. SHARMA (2008): Acellular biomaterials of porcine origin for the reconstruction of abdominal defects in rabbits. *Trends Biomat. Artif. Organs* 22, 33-44.
- VAN DER LAAN, J. S., G. P. LOPEZ, P. B. VAN WACHEM, P. NIEUWENHUIS, B. D. RATNER, R. P. BLEICHRODT, J. M. SCHAKENRAAD (1991): TFE-plasma polymerized dermal sheep collagen for the repair of abdominal wall defects. *Int. J. Artif. Org.* 14, 661-666.
- VILAR, J. M., J. A. CORBERA, G. SPINELLA (2011): Double-layer mesh hernioplasty for repairing umbilical hernias in 10 goats. *Turk. J. Vet. Anim. Sci.* 35, 131-135.
- VOYTIK-HARBIN, S. L., A. O. BRIGHTMAN, B. Z. WAISNER, J. P. ROBINSON, C. H. LAMAR (1998): A tissue-derived extracellular matrix that promote tissue growth and differentiation of cells *in-vitro*. *Tissue Eng.* 4, 157-174.

Received: 29 November 2013

Accepted: 25 November 2014

KUMAR, V., A. K. GANGWAR, N. KUMAR, H. SINGH: Upotreba bezstanične matrice iz ošita bivola pri pupčanoj hernioplastici svinja. *Vet. arhiv* 85, 49-58, 2015.

SAŽETAK

Bezstanična struktura ksenogenih biomaterijala smatra se povoljnom jer pri implantaciji ne uzrokuje upalne i imunološke reakcije. U ovom je istraživanju proveden postupak dobivanja bezstanične matrice iz ošita (BMO) bivola koji je zatim bio rabljen kao podloga za obnavljanje tkiva pri operaciji pupčane hernije svinja. Gubitak stanične strukture bivoljih ošita proveden je uz pomoć različitih koncentracija natrijeva deoksikolata, primijenjenih u određenim vremenskim razmacima. Proizvedene bezstanične matrice ošita upotrijebljene su pri pupčanoj hernioplastici kod 12 svinja križanaca landras pasmine. Uzorci seruma, prikupljeni 0., 15. i 30. dana nakon implantacije, bili su podvrgnuti natrijev dodecil sulfat-poliakrilamid gel elektroforezi (SDS-PAGE) s ciljem promatranja razdiobe serumskih proteina. Obrada 2 %-tnim natrijevim deoksikolatom dovela je do potpunog gubitka stanične strukture bivoljeg ošita za 48 sati. Mikroskopskim pregledom matrice obrađene deterгентom potvrđeno je potpuno uklanjanje stanica strome te uredno raspoređena kolagena vlakna. Mjesta operacije svih hernija kod kojih je upotrijebljena bezstanična matrica ošita ostala su zdrava tijekom 3 mjeseca. Razdioba serumskih proteina 15 dana nakon implantacije bila je različita u odnosu na početni (0.) dan, a 30. dan nakon implantacije vratila se na normalu. Sve hernije operirane uz upotrebu BMO u potpunosti su zacijelile bez odbacivanja presatka. Pomoću 2 % natrijeva deoksikolata postiže se potpuni gubitak stanične strukture bivoljeg ošita koji se može sigurno primijeniti pri pupčanoj hernioplastici svinja.

Ključne riječi: bezstanična matrica, ošit, bivol, svinje, SDS-PAGE, pupčana hernija
