



Viable versus frozen meniscus allografts. A clinical and imaging short term evaluation

Viabilni i smrznuti transplantat meniska. Rana klinička i radiološka evaluacija

Jaap van der Maas¹, Pieter Vansintjan¹, Rene Verdonk^{2*}, Peter Verdonk³

Abstract. Aim: To perform a clinical and imaging short term evaluation of viable and frozen meniscus allografts. **Methods and materials:** Between 2005 and 2006, 12 meniscal allograft transplantations were performed in our institution. The study population consisted of 5 men and 7 women with a mean age of 36.4 years (range 17.1-42.5). Six patients received a viable allograft and six a deep-frozen one. All allografts were harvested from donors who died after a short disease. All patients were operated with an open surgical technique (medial or lateral arthrotomy) and soft tissue fixation with secure anterior and posterior horn fixation, performed by one senior surgeon. All patients were scored pre-operatively, at 6 weeks, 3 months, 6 months, 1 and 2 years postoperatively. Three questionnaires were used to score the patients clinically (KOOS, modified HSS and SF-36 questionnaire). Every patient received radiographs pre-operatively and at 6 months and 1 year. **Results:** Clinically, there was no difference in patient self-reported results through questionnaires or in a questionnaire based on clinical examination. There was no significant progress in joint space narrowing on weight bearing and Rosenberg view radiographs. **Conclusion:** Our results suggest that there are no clinical significant differences between the viable and the deep frozen subgroup after two years.

Key words: cartilage; frozen; menisci; transplantation; viable

Sažetak. Cilj: Učiniti ranu kliničku i radiološku evaluaciju vijabilnog i smrznutog transplantata meniska. **Metoda i materijali:** Tijekom 2005. i 2006. godine, u našoj ustanovi izvedeno je 12 alotransplantacija meniska. U studiju je bilo uključeno 5 muškaraca i 7 žena, s prosječnom dobi od 36,4 godina (raspon od 17,1 do 42,5). U šest pacijenata presađen je vijabilni transplantat, a u šest duboko smrznuti transplantat. Svi transplantati su dobiveni od davatelja koji su umrli nakon kratke bolesti. Svi pacijenti operirani su otvorenim kirurškim zahvatom (medijalna ili lateralna artrotomija), uz fiksaciju mekih tkiva i fiksaciju prednjeg i stražnjeg roga. Svi pacijenti su evaluirani preoperativno, te 6 tjedana, 3 mjeseca, 6 mjeseci, jednu i dvije godine nakon operacije. Za kliničku evaluaciju bolesnika korištena su tri upitnika (KOOS, adaptirani HSS i SF-36 upitnik). Svakom pacijentu je učinjena rendgenska slika preoperativno, nakon 6 mjeseci i nakon jedne godine. **Rezultati:** Klinički, nije bilo razlika između rezultata koje su bolesnici samostalno naveli u upitnicima i onih dobivenih temeljem kliničkog pregleda. Rendgenska slika po Rosenbergu nije pokazala značajni pomak u suženju zglobne pukotine pod opterećenjem. **Zaključak:** Naši rezultati ukazuju na to da nakon dvije godine ne postoje klinički značajne razlike između transplantacije vijabilnog i duboko smrznutog transplantata.

Ključne riječi: hrskavica; menisci; transplantat; vijabilni; zamrznuti

¹Department of Orthopaedic Surgery & Traumatology, University Hospital Ghent, Ghent, Belgium

²Department of Orthopaedic Surgery & Traumatology, Jan Palfijn Hospital, Ghent, Belgium

³Department of Orthopaedic Surgery & Traumatology Monica Ziekenhuizen, Antwerpen, Belgium

Received: 10.06.2014

Accepted: 15.09.2014

***Corresponding author:**

Rene Verdonk, MD
Department of Orthopaedic Surgery & Traumatology,
Jan Palfijn Hospital, Ghent, Belgium
e-mail: rene.verdonk@ugent.be

<http://hrcak.srce.hr/medicina>

INTRODUCTION

Ever since Fairbank described the radiographic degenerative evolution of the post-meniscectomized knee in 1948¹, the functional importance of the meniscus has been more appreciated. Loch et al. performed the first work in meniscal allograft transplantation in the beginning of the eighties with the transplantation of proximal tibial osteochondral grafts in combination with meniscal allograft². In 1948 it was Milachowski who performed

Meniscal allograft transplantation is a good option in a young, symptomatic, post-meniscectomized knee for pain relief and improvement of function.

the first meniscal allograft transplantation in a human being³. Now there is more and more growing evidence in literature that a meniscal allograft transplantation, given the right indications, results in significant improvements in knee function and pain relief, in the short- as well as in the long term⁴⁻⁹. Many variables contribute to the result, such as surgical technique and sizing of the allograft, but also the preservation technique of the allografts. The hypothesis was that by keeping the cells viable, they could maintain the extracellular matrix and so the mechanical integrity of the meniscus.

METHODS AND MATERIALS

Between 2005 and 2006, 12 meniscal allograft transplantations were performed in our institution. The indications for the surgery were: a young, active patient (< 50 years) who sustained a previous total meniscectomy, presenting with (medial or lateral) pain and swelling and unable to perform daily professional activities. The knee should be normally aligned and stable.

The contra-indications included progressed articular cartilage damage (> grade III ICRS), degenerative changes on radiographs, malalignment, instability, a history of septic arthritis in the knee and other inflammatory diseases.

In case of malalignment or focal cartilage damage, a concomitant procedure was performed (corrective valgus high tibial osteotomy or focal cartilage repair).

Study population

The study population consisted of 5 men and 7 women with a mean age of 36.4 years (range 17.1 to 42.5). Six patients received a viable and six a deep-frozen allograft. There were eight lateral allografts (5 deep-frozen and 3 viable) and four medial allografts (1 deep-frozen and 3 viable). Seven patients received a concomitant procedure with the meniscal transplantation (microfracture in 5, and a corrective valgus high tibial osteotomy in 3 patients).

Meniscal allograft preservation

All allografts were harvested from donors who died after a short disease. The maximum age for the donors was set at 45 years. None had received corticosteroids or cytostatic drugs. All grafts were obtained within 24 hours postmortem.

The deep-frozen allografts were obtained from the tissue bank of the University Hospital of Ghent after comparative sizing with the acceptor. Sizing was done through radiographs. After graft prelevation in the sterile operating room, it was immediately transported to the tissue bank and conserved at -80 °C. After screening for transmittable diseases, the grafts were released from the tissue bank for transplantation.

Viable allografts were harvested likewise and immediately conserved in a solution of Dulbecco's Modified Eagle Medium (D-MEM; Gibco Invitrogen, Merelbeke, Belgium) enriched with 20 % of autologous serum from the acceptor which had been obtained before and stored at min 80 °C. The graft stayed in this medium for a period of 14 days at 37 °C and the medium was replaced every three days in a sterile fashion. During this conservation time, the donor was screened for transmittable diseases¹⁰.

Surgical technique

All patients were operated with an open surgical technique (medial or lateral arthrotomy) and soft tissue fixation with secure anterior and posterior horn fixation by one senior surgeon (RV)¹¹. The lateral allograft transplantation was performed through a classic lateral parapatellar arthrotomy (Figure 1). Proximal insertion of the lateral collateral ligament and popliteus tendon were re-

leased by creating an osteotomy with a curved osteotome (Figure 2).

The bone block was fixated with a screw after the transplantation was performed. For the fixation of the graft, first the remaining rim and posterior and anterior horns were trimmed to fit the donor meniscus. This was fixed with non-resorbable Prolene 2/0 sutures every 3 mm from posterior to anterior, and extra horizontal sutures to fixate the posterior and anterior horns (Figure 3). Subsequently, the bone block from the osteotomy was fixated and the arthrotomy closed.

The medial allograft transplantation was performed through a classic medial parapatellar arthrotomy of approximately 8 cm (Figure 4). This incision can easily be extended if a concomitant

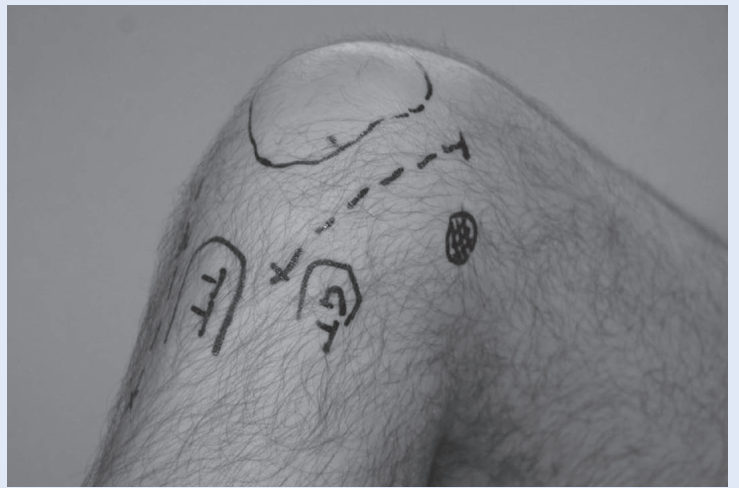

Figure 1. Lateral incision of approximately 8 cm is performed with the knee in 90° of flexion.

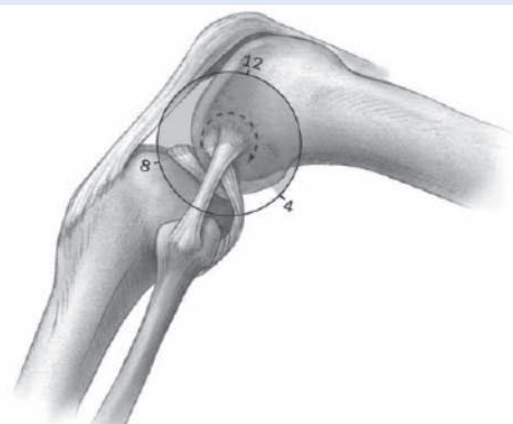
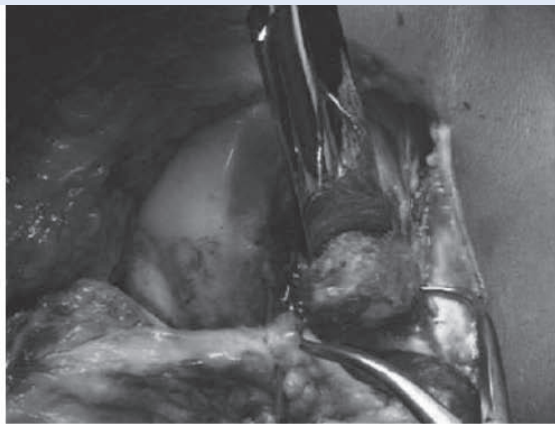


Figure 2. Curvilinear osteotomy of the proximal insertion of the lateral collateral ligament and popliteus tendon to get better access to the lateral compartment.

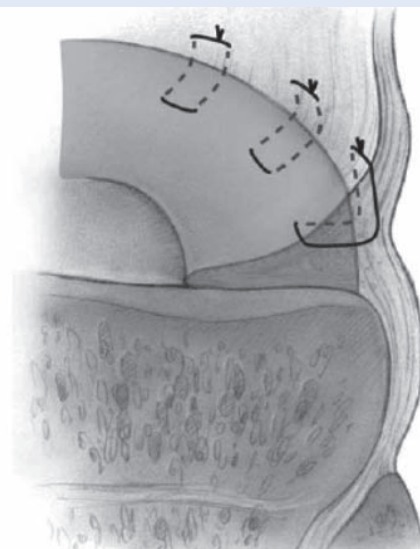
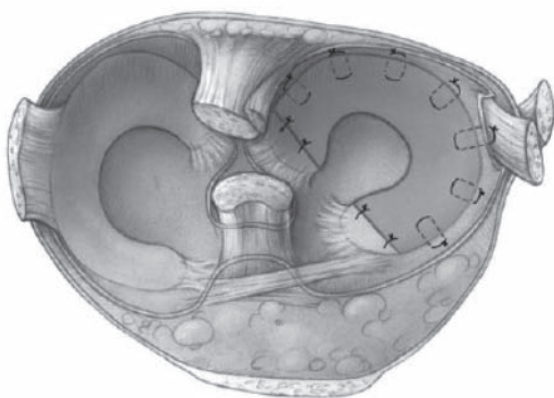


Figure 3. The allograft is tightly fixed with horizontal, non-resorbable sutures every 3 mm.

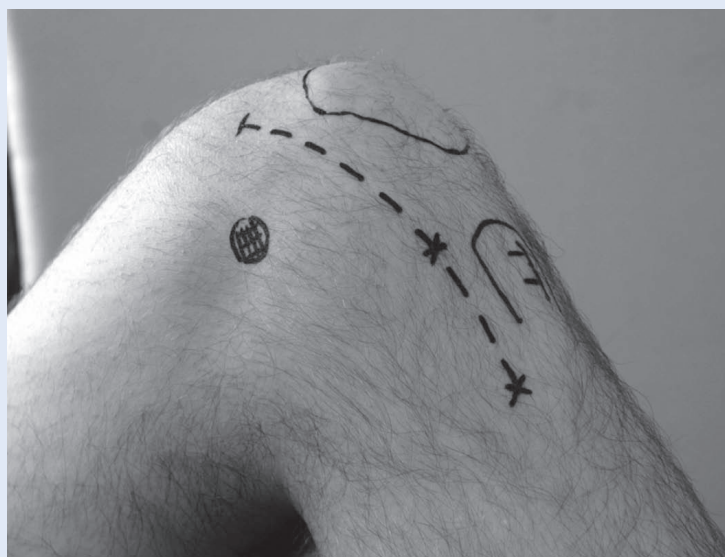

Figure 4. Medial parapatellar incision of approximately 8 cm, made with the knee in 90° flexion.

procedure has to be performed, such as a corrective valgus high tibial osteotomy or an ACL reconstruction. To further open the arthrotomy, a flake osteotomy of the femoral attachment of the medial collateral ligament was performed at the level of the medial femoral epicondyle. Fixation of the allograft was performed in the same fashion as described above for the lateral allograft.

The postoperative rehabilitation program consisted of a non-weight-bearing and restricted flexion until 60° for the first three weeks. After that, progressive weight bearing and flexion until 90° was allowed. After six weeks the crutches were progressively removed and full flexion was allowed.

Clinical evaluation and follow up

All patients were scored pre-operatively, at 6 weeks, 3 months, 6 months, 1 and 2 years post-operatively. Three questionnaires were used to score the patients clinically: the KOOS, the modified HSS and SF-36 questionnaire. The KOOS

questionnaire is validated in Dutch for the follow-up of meniscal allograft transplantation. KOOS and SF-36 were filled out by the patient and the modified HSS questionnaire was filled out by an independent orthopedic surgeon after conducting clinical examination in a standardized fashion.

Radiological evaluation

Every patient received radiographs (AP, PA and full leg) pre-operatively and at 6 months and 1 year. Joint-space narrowing was scored according to the IKDC-classification (Table 1).

Each patient also had consecutive MRI's on a 1.5T scanner (Magnetom Symphony or Avanto; Siemens Medical Solutions, Erlangen, Germany) at 6 weeks and 1 year.

All examinations were done in 3 mm sagittal slices with proton density and T2 weighted fast spin echo images, followed by 2 mm coronal slices and 3 mm axial slices according to a 3D dual echo steady state sequence for optimal visualization of the menisci and the articular cartilage.

Each allograft was scored according to following parameters: signal intensity, ruptures and extrusion¹². The articular cartilage of the femur condyle as well as on the tibial plateau was graded according to Yulish with minor adjustments (Table 2)¹³.

Statistical analysis

Statistical analysis was performed with SPSS v13.0 for Windows XP. First the population was checked with the Shapiro-Wilk test, but this showed no normal distribution. Therefore, further statistical analysis was performed using non-parametric tests. The Mann-Whitney U test was used to show significant differences between the deep frozen and viable group. Comparison of the pre-operative data and the post-operative data was performed using the Wilcoxon Signed Ranks test. Statistical significance was set at $P < 0.05$.

Table 1. IKDC classification of joint-space narrowing

IKDC classification	
Grade 0	No narrowing of the joint-space
Grade 1	< 50 % narrowing
Grade 2	> 50 % narrowing
Grade 3	Joint space obliteration

Table 2. Yulish MRI classification of articular cartilage damage

MRI Classification of articular cartilage	
Grade 0	Normal
Grade 1	Normal contour ± abnormal signal
Grade 2	Superficial fraying: erosion or ulceration of less than 50 %
Grade 3	Partial thickness defect of more than 50 % but less than 100 %
Grade 4	Full-thickness cartilage loss

RESULTS

Clinical outcome

At first, the deep-frozen and viable subgroup were compared for all the clinical parameters at 6 weeks, 3 months, 6 months, 1 and 2 year post-operatively. Out of a total of 82 parameters, there were 9 statistically significant differences between the two groups at different follow-up times. Because there was no obvious relation between the significantly different parameters, the

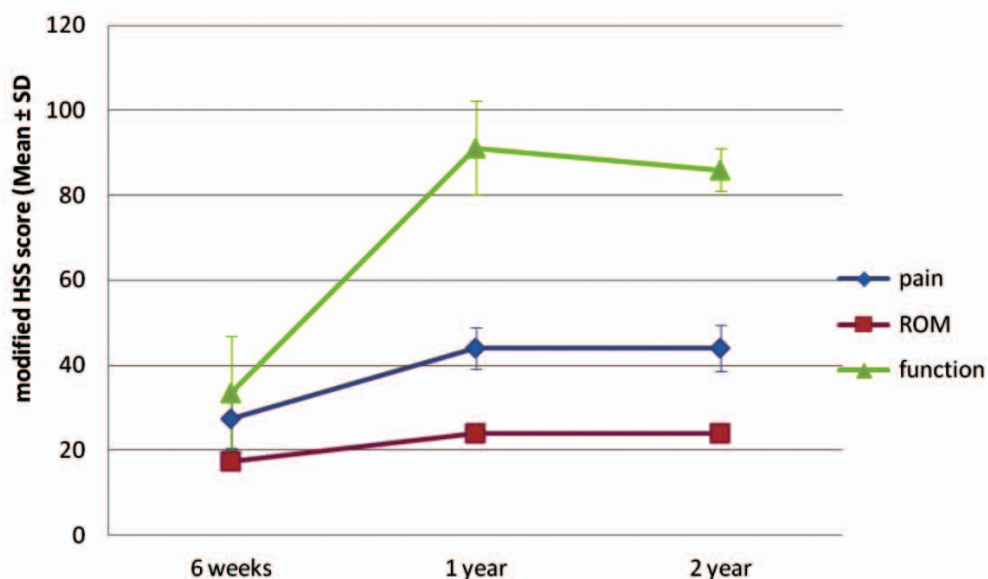
two groups were considered clinically equal, none of them being superior to the other.

Therefore, the entire population was studied as one group for further analysis.

The modified HSS score improved for pain, function and range of motion applied after 6 months gave results that were statistically significantly better compared to those at 6 weeks postoperatively. This continued to improve up to year 2, but there was no statistically significant improvement compared to 6 months postop (Table 3, Figure 5).

Table 3. Overview of modified HSS scores 6 weeks postoperative compared to 6 months postoperative

	Modified HSS score (Mean ± SD)		p-value
	6 weeks	1 year	
Pain	27.3 ± 13.3	44.0 ± 6.1	0.02
ROM	17.3 ± 3.7	24.0 ± 2.3	0.02
function	33.5 ± 27.0	91.1 ± 12.7	0.02

**Figure 5.** Evolution of modified HSS scores, comparing 6 weeks post-op to 2 years post-op.

In the KOOS questionnaire, there was also a statistically significant improvement in the 'pain' and 'function' subscores obtained at 6 months when compared to those measured preoperatively. After one year, the 'ADL', 'sport & recreation' and 'quality of life'-scores, also improved statistically

significantly. After another one year, there was no statistically significant improvement anymore in any of the subscores (Table 4, Figure 6).

The SF-36 parameters all improved over time but did not all reach statistically significant improved results after 2 years. There was a trend of declin-

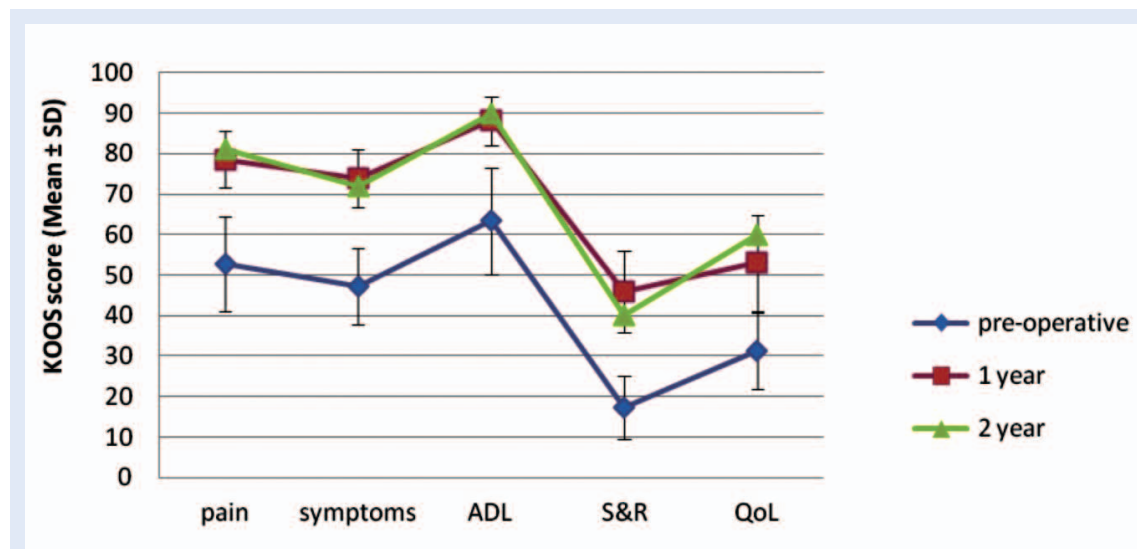


Figure 6. Evolution of modHSS scores, comparing pre-operative post-op to 1 and 2 years post-op. ADL = activities of daily live, S&R = sports and recreation, QoL = quality of life

Table 4. KOOS scores compared preoperative to 1 year post-op.

	KOOS score (Mean ± SD)		p-value
	pre-operative	1 year	
pain	52.8 ± 23.5	78.6 ± 13.8	0.02
symptoms	47.3 ± 18.9	73.8 ± 14.2	0.04
ADL	63.4 ± 26.4	88.1 ± 11.8	0.05
S&R	17.3 ± 15.9	45.9 ± 20.0	0.02
QoL	31.3 ± 19.0	53.0 ± 23.8	0.02

ADL = activities of daily live, S&R = sports and recreation, QoL = quality of life

Table 5. SF-36 scores compared preoperative to 1 year post-op.

	SF-36 scores (Mean±SD)		p-value
	pre-operative	1 year	
PF (physical functioning)	45.1 ± 28.6	64.5 ± 24.0	0.14
RP (role physical)	18.2 ± 33.7	59.1 ± 42.2	0.02
BP (bodily pain)	39.3 ± 23.3	60.1 ± 20.1	0.09
SF (social functioning)	67.2 ± 34.1	83.1 ± 20.2	0.20
MH (mental health)	67.6 ± 14.7	81.8 ± 14.0	0.03
RE (role emotional)	54.5 ± 52.2	94.0 ± 13.3	0.04
VT (vitality)	55.5 ± 22.2	70.9 ± 20.3	0.24
GH (general health)	68.6 ± 16.1	70.5 ± 15.1	0.57
HCLY (health compared to last year)	45.5 ± 24.5	63.6 ± 34.2	0.10

ing scores after 6 weeks, after which they improved (Table 5).

Radiological outcome

There was no significant decline in the grading of the joint space in all study subjects. In the short term, there was no progressive joint-space narrowing either in the viable or in the deep-frozen group.

The images from the MRI were also compared for the viable and deep-frozen subgroups. There was hardly any difference in the signal intensity of all menisci at six weeks post-op and one year post-op. There were more tears in the posterior root of the viable menisci (50 %), in contrast to no tears in the deep-frozen subgroup. Meniscal body extrusion was seen in all allografts after one year. After one year, five viable and four deep-frozen allografts presented complete extrusion, and one viable and two deep-frozen were partially extruded. The status of the articular cartilage remained constant over 1 year in both subgroups.

DISCUSSION

Since the first meniscal allograft transplantation in 1984 by Milachowski³, there have been numerous studies in search of the perfect conservation technique. At the end of the eighties, the philosophy to start using viable allografts emerged in the University Hospital of Ghent. The hypothesis was that by keeping the cells viable, they could maintain the extracellular matrix and so the mechanical integrity of the meniscus. Earlier studies showed that long-term survival of the viable meniscal allograft transplants was excellent with good results in 70 % of cases after 10 years⁵. This is comparable to other published data using deep-frozen and cryopreserved allografts^{4,7,8}.

This study was conducted to see if these results would be noticed also in the short term because this had not been investigated before.

After two years, no group proved to be superior to the other clinically or radiologically.

This was expected, given the small population and the short-term follow-up. Because there is not enough weight in this study, the results need to be interpreted with caution. A second remark refers to the interpretation of the incorporation

and survival of the graft with MRI. Evaluation with arthroscopy and biopsies with histological analysis of the cellularity and ingrowth would be more ideal, but are not easy to obtain.

In a recent study¹⁴ comparing both viable and fresh frozen meniscal allografts, evidence of both fibroblasts and fibrochondrocytes was found in all specimen types. Specifically, the main cell type seen was a fibrochondroblast in both allograft types. However, it has been noted that there is no unique cell-specific marker for meniscal cells.

In the short term, there are no statistical differences in clinical or radiological outcomes between viable or deep-frozen allografts.

Identifying the exact phenotype of the re-populating cells requires analysis of the RNA produced by these cells in comparison with the RNA produced by normal meniscal fibrochondrocytes¹⁵.

In the same study, when cell density is considered, the density seen in the central area of biopsies from deep-frozen allografts was significantly lower than that seen in viable allografts. This result is reflected in the data from previous reports on deep-frozen allografts, where repopulation was limited to the superficial zone, while the core of the transplant remained acellular¹⁶. This may relate to the processing of the deep frozen allografts, with the resulting loss of cells.

CONCLUSION

In conclusion, these results suggest that there are no clinical significant differences between the viable and the deep-frozen subgroups after two years.

Clinically, there was no difference between the results self-reported by patients in questionnaires and those based on clinical examination. The results for both groups after two years showed a statistically significant improvement in pain scores and function, as well as in the range of motion.

This finding is in positive contrast with microscopic evidence suggesting obvious depletion of viable cells in the core of the meniscal body in case of deep-freezing preservation.

However this does not seem to be illustrated in clinical findings in the short term (min 2 y FU).

There was no significant progress in the joint space narrowing on weight bearing or on Rosenberg view radiographs. MRI also showed some extrusion of all allografts after 2 years, but no difference between the two subgroups. Articular cartilage in the affected compartment minimally declined on MRI in both groups after two years. The higher tearing rate in the viable subgroup should be interpreted with caution because of the small size of the subgroups, and the fact that it was not reflected in the clinical outcome.

In the future, further studies with biopsies are needed to elucidate the biological histological fate of both viable and deep-frozen allografts. Standardized, longer-term follow-up is mandatory if clinical or radiological differences appear in the long term.

Conflicts of interest statement: The authors report no conflicts of interest.

REFERENCES

1. Fairbank TJ. Knee joint changes after meniscectomy. *J Bone Joint Surg Br* 1948;30B:664-70.
2. Lochter RC, Gross AE, Langer F. Late osteochondral resurfacing for tibial plateau fractures. *J Bone Joint Surg Am* 1984;66:328-35.
3. Wirth CJ, Milachowski KA, Weismeier K. Meniscus transplantation in animal experiments and initial clinical results. *Z Orthop Ihre Grenzgeb* 1986;124:508-12.
4. Saltzman BM, Bajaj S, Salata M, Daley EL, Strauss E, Verma N et al. Prospective long-term evaluation of meniscal allograft transplantation procedure: a minimum of 7-year follow-up. *J Knee Surg* 2012;25:165-75.
5. Verdonk PC, Demurie A, Almqvist KF, Veys EM, Verbruggen G, Verdonk R. Transplantation of viable meniscal allograft. Survivorship analysis and clinical outcome of one hundred cases. *J Bone Joint Surg Am* 2005;87:715-24.
6. Verdonk PC, Verstraete KL, Almqvist KF, De Cuyper K, Veys EM, Verbruggen G et al. Meniscal allograft transplantation: long-term clinical results with radiological and magnetic resonance imaging correlations. *Knee Surg Sports Traumatol Arthrosc* 2006;14:694-706.
7. von Lewinski G, Milachowski KA, Weismeier K, Kohn D, Wirth CJ. Twenty-year results of combined meniscal allograft transplantation, anterior cruciate ligament reconstruction and advancement of the medial collateral ligament. *Knee Surg Sports Traumatol Arthrosc* 2007;15:1072-82.
8. Vundelinckx B, Vanlauwe J, Bellemans J. Long-term Subjective, Clinical, and Radiographic Outcome Evaluation of Meniscal Allograft Transplantation in the Knee. *Am J Sports Med*. 2014;42:1592-9.
9. Wirth CJ, Peters G, Milachowski KA, Weismeier KG, Kohn D. Long-term results of meniscal allograft transplantation. *Am J Sports Med* 2002;30:174-81.
10. Verdonk R, Kohn D. Harvest and conservation of meniscal allografts. *Scand J Med Sci Sports* 1999;9:158-9.
11. Verdonk PC, Demurie A, Almqvist KF, Veys EM, Verbruggen G, Verdonk R. Transplantation of viable meniscal allograft. Surgical technique. *J Bone Joint Surg Am* 2006;88 Suppl 1 Pt 1:109-18. Verdonk P, Depaeppe Y, Desmyter S, De Muynck M, Almqvist KF, Verstraete K et al. Normal and transplanted lateral knee menisci: evaluation of extrusion using magnetic resonance imaging and ultrasound. *Knee Surg Sports Traumatol Arthrosc* 2004;12:411-9.
12. Yulish BS, Montanez J, Goodfellow DB, Bryan PJ, Mulopulos GP, Modic MT. Chondromalacia patellae: assessment with MR imaging. *Radiology* 1987;164:763-6.
13. Moran CJ, Atmaca S, Declercq HA, Cornelissen MJ, Verdonk PC. Cell distribution and regenerative activity following meniscus replacement. *Int Orthop* 2014;38:1937-44.
14. Rodeo SA, Seneviratne A, Suzuki K, Felker K, Wickiewicz TL, Warren RF. Histological analysis of human meniscal allografts. A preliminary report. *J Bone Joint Surg Am* 2000;82-A:1071-82.
15. Hutchinson ID, Moran CJ, Potter HG, Warren RF, Rodeo SA. Restoration of the meniscus: form and function. *Am J Sports Med* 2014;42:987-98.