

***In vivo* toxicity of a new antifungal agent 2,4-dithiophenoxy-1-iodo-4-bromo benzene: a follow up on our *in vitro* study**

Aysun Kılıç Süloğlu¹, Evrim Arzu Koçkaya², Elif Karacaoğlu¹, Güldeniz Selmanoğlu¹,
and Elif Loğoğlu³

Hacettepe University, Faculty of Science, Department of Biology, Beytepe¹, The Higher Vocational School of Health Services, Gazi University, Gölbaşı Campus², Gazi University, Faculty of Arts and Sciences, Department of Chemistry, Technical Schools³, Ankara, Turkey

[Received in April 2014; CrossChecked in April 2014; Accepted in February 2015]

Triazole fungicide fluconazole has become the most widely used antifungal agent in the world, mainly because of its ability to penetrate well into body fluids and tissues. However, it has been reported to interact with many drugs and because of its common use, the risk of resistance to fluconazole increases. This calls for new anti-fungal drugs that would be able to replace it. In 2006, a new thialo benzene derivative - 2,4-dithiophenoxy-1-iodo-4-bromo benzene (C₁₈H₁₂S₂I₂Br) - was synthesised with a carbon backbone similar to fluconazole, and, according to the early *in vitro* tests, much greater efficiency. Followed an *in vitro* test of its cytotoxicity, in which the new drug showed promising results as an alternative to fluconazole. The aim of this study was take the next step and test C₁₈H₁₂S₂I₂Br toxicity *in vivo*. We opted for a four-week test on Wistar rats, in which the new antifungal agent was orally applied at doses two and a half and five times lower than those of fluconazole. There were no changes in daily food and water consumption, but weight gain in female rats and relative organ weights changed in the treated groups, pointing to sex-related differences in drug metabolism and effects. Fluconazole significantly increased leukocytes and lowered neutrophils whereas C₁₈H₁₂S₂I₂Br did not, while other haematological changes in respect to the vehicle control were similar between the treated groups. Differences in cytochrome c in the liver and kidney suggested greater apoptotic effect of the new drug, but interpretation remains inconclusive, considering that other key indicators (biochemistry and histopathology) do not support greater toxicity. Considering that C₁₈H₁₂S₂I₂Br is more active at lower concentrations and has comparable toxic effects to fluconazole in rats, this new compound shows some promise in the treatment of fungal infections. Future, more detailed animal studies are needed, that will include drug interactions and molecular toxicity pathways. If the results are promising, clinical studies should follow.

KEY WORDS: *blood biochemistry; cytochrome c; fluconazole; histopathology; in vivo toxicity study*

Seventy percent of the people infected by bacteria and fungi develop resistance to one of the antifungal drugs (1). One such drug is the triazole fungicide fluconazole, and the risk of resistance is even greater, as fluconazole is the most widely used among antifungal compounds. This fungicide is designed to inhibit the fungal cytochrome P450 (CYP P450) enzyme but it can also affect the mammalian enzymes.

Apart from the risk of resistance to fluconazole, it has common side effects such as nausea, vomiting, headache, and toxicity issues through interactions with drugs that are metabolised by CYP3A4 (statins and cyclosporine). Therefore, it is still necessary to develop a broad-spectrum antifungal agent with minimal toxicity and risks for human health (2, 3).

In 2006, Loğoğlu et al. (4) synthesised a new thialo benzene derivative C₁₈H₁₂S₂I₂Br with the carbon backbone similar to fluconazole (Figure 1) and tested its biological activity.

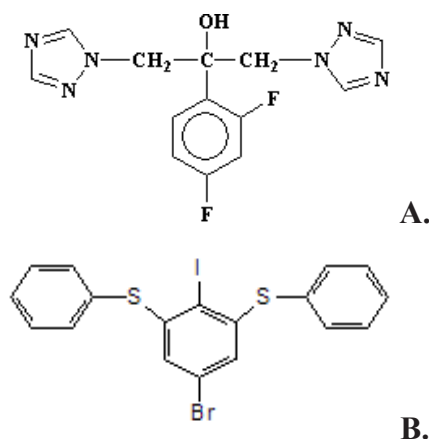


Figure 1 Chemical structure of **A.** Fluconazole, **B.** 2,4-dithiophenoxy-1-iodo-4-bromo benzene (C₁₈H₁₂S₂I₂Br)

Its minimum inhibition concentration for *Candida albicans* was four times lower than that of fluconazole. This compound was also more active against Gram-positive (*Staphylococcus aureus*, *Bacillus subtilis*) and Gram-negative bacteria (*Yersinia enterocolitica*, *Escherichia coli*, *Klebsiella pneumoniae*).

However, as no toxicity data on this new compound had been known, we tested its toxicity *in vitro* on L929 mouse fibroblast cell lines (5), using concentrations based on the FDA information for fluconazole (6), only to find that at 250 µg mL⁻¹ C₁₈H₁₂S₂IBr was not cytotoxic and did not induce metabolic changes.

The next logical step was to investigate the *in vivo* toxicity of the newly synthesised compound as a potential alternative to fluconazole. We therefore designed this study to determine the toxic effects of C₁₈H₁₂S₂IBr at subacute doses on the organ systems (7) of Wistar rats and compare them with fluconazole, considering that antifungal azoles have been reported to adversely affect the gastrointestinal, endocrinological, and liver systems (8).

MATERIALS AND METHODS

Animals and housing

The study included 50 adult Wistar male and 50 female rats weighing 150-200 g from the Lemali Animal Husbandry, Ankara, Turkey. Throughout the experiments we followed the National Academy of Sciences' *Guide for the Care and Use of Laboratory Animals* (9). The rats were housed in polycarbonate cages under a 12:12-hour light-and-dark cycle and controlled temperature (22±2 °C) and humidity (44±5 %), with free access to feed and water. Acclimatisation lasted 10 days. Before treatment, the rats were randomised to groups of 20 (10 female and 10 male), but we took care that the groups did not differ in body weight means. All rats were observed for general condition two times a day for the duration of the experiment.

Chemicals and treatment

2,4-dithiophenoxy-1-iodo-4-bromobenzene (C₁₈H₁₂S₂IBr) is one of thiohalo benzene derivatives synthesised by dissolving 1,2,3,5-tetrahalogene benzene in pyridine and adding thiophenole. This compound was prepared from 2,4,6-tribromo and triiodo anilines *de novo*, as described by Loğoğlu et al. (4).

Fluconazole (Fluzole® tablet, 150 mg) was purchased from Biofarma (Istanbul, Turkey). Fluconazole and C₁₈H₁₂S₂IBr were dissolved in ethanol (absolute alcohol: 0.145 mg kg⁻¹ of bw) and administered by oral gavage once a week for four weeks. The control group was receiving no treatment; the vehicle group was receiving 0.145 mg kg⁻¹ bw of ethanol, which served as the vehicle for active compounds, once a week; the fluconazole group was receiving 19.6 mg kg⁻¹ bw of fluconazole a week; the low-

dose C₁₈H₁₂S₂IBr group was receiving 3.92 mg kg⁻¹ bw of C₁₈H₁₂S₂IBr a week; and the high-dose C₁₈H₁₂S₂IBr group 7.84 mg kg⁻¹ bw of C₁₈H₁₂S₂IBr a week. The fluconazole dose corresponds to the 200 mg dose a 70-kg human receives every day during a 28-day treatment (10). The tested concentrations of C₁₈H₁₂S₂IBr were two and a half times and five times lower than that of fluconazole, based on earlier *in vitro* efficiency findings (4), as no *in vivo* efficiency has been studied yet.

Histopathology

The animals were sacrificed by cervical dislocation 24 h after the final dosing. Liver, kidney, thymus, spleen, and lymph nodes were removed immediately and weighed to calculate relative organ weights (organ:body weight). All tissue samples were fixed in Bouin's solution, embedded in paraffin, cut in 5-µm thick sections and stained with haematoxylin and eosin for histopathology. The slides were examined under the Olympus BX51 system light microscope (Tokyo, Japan) at 100x and 200x magnification. One hundred kidney glomeruli from 20 animals from each group were selected to measure the minimum (x-axis) and maximum (y-axis) diameter in serial sections using the Bs200pro image analysis program (BAB, Ankara, Turkey). The glomerular volume was calculated as described elsewhere (11).

Immunohistochemistry

For immunohistochemical tests liver and kidney samples were fixed in 10 % formaldehyde and embedded in paraffin, and 5-µm sections prepared for slides. Slides were stained with rabbit polyclonal primary cytochrome c (cyt-c) antibody and biotinylated secondary goat-anti rabbit IgG (BA-1000, Vector Laboratories Inc.) for cyt-c as described by Babu et al. (12), and examined under the light microscope (magnification: 200x).

Endogenous peroxidase activity was quenched using 0.3 % hydrogen peroxide in phosphate buffered saline (PBS) at room temperature for 30 min, as described by Koçkaya et al. (13). The slides were reviewed independently by three observers. Intensity was assessed by comparison with the positive and negative control sections. All slides were photographed with the Olympus BX51 system light microscope (Tokyo, Japan) and photographs analysed using the Bs200prop software.

Haematology and biochemistry

Twenty-four hours after the final dosing, 5 mL of blood was collected from the heart before cervical dislocation in order to make the complete blood count with a Shimadzu MS59 blood counting device (Kyoto, Japan).

Serum was separated from blood samples after centrifugation at 1800 g for 15 min and analysed for urea, low density lipoprotein (LDL), high density lipoprotein (HDL), cholesterol (Chol), aspartate aminotransferase

(AST), alanine aminotransferase (ALT), and lactate dehydrogenase (LDH) activities using commercial biochemical kits (Audit Diagnostics, Cork, Ireland) on a Shimadzu CL-770 clinical spectrophotometer (Kyoto, Japan) according to the manufacturer's instructions.

Statistical analyses

For statistical analyses we used the SPSS Statistics 22 for Windows (IBM, New York, USA). Data are expressed as mean±standard error (SE) and statistical significance was set at $P \leq 0.05$. All measured parameters were analysed separately for male and female rats using the two-way analysis of variance (ANOVA).

RESULTS AND DISCUSSION

As the control group and vehicle control group did not differ in any of the parameters measured, the control group data are not presented in this paper for the sake of space and readability. No clinical signs of adverse effects were seen in rats and none died before the end of the study. Food and water consumption did not vary significantly across the

groups (Table 1). The baseline mean body weights did not differ significantly between the groups or sexes. The final mean body weights were lower in the treated groups, but not significantly. However, body weight gain was significantly lower in the treated female rats than in the vehicle control females as opposed to the respective male groups, in which no significant differences in body weight gain were found. This may be because of hormone (gonadal hormone) or fat metabolism differences between the sexes.

Table 2 points to sex differences in variations in relative organ weights. Female rats in the fluconazole and low-dose $C_{18}H_{12}S_2IBr$ group showed a significant increase in relative liver weight compared to the vehicle control, while male rats did not. The females in the low-dose $C_{18}H_{12}S_2IBr$ group also had significantly higher relative liver weight than the fluconazole group. In contrast, males did not significantly vary in relative liver weights.

Waxman and Holloway (14) reported that the expression of CYP P450 and other liver-expressed genes is sexually dimorphic and regulated by the levels of growth hormone in plasma, which is pulsatile in male animals and more frequent in female animals. This may explain the sex-based

Table 1 Food and water consumption and body weight measurements in the vehicle control and treated rats (mean±SE)

	Vehicle control	Fluconazole	Low-dose $C_{18}H_{12}S_2IBr$	High-dose $C_{18}H_{12}S_2IBr$
Female				
Baseline body weight	112.38±6.0	124.62±5.29	124.12±4.30	121.12±5.05
Final body weight	145.37±6.11	143.12±4.12	140.37±4.18	137.5±5.50
Weight gain (%)	30.16±3.58	15.39±2.02 ^a	13.63±1.46 ^a	13.33±1.93 ^a
Food consumption (g day ⁻¹)	13.85±0.84	12.05±0.48	13.23±0.38	13.86±0.42
Water consumption (mL day ⁻¹)	35.36±2.27	33.10±2.50	36.13±1.61	34.08±2.32
Male				
Baseline body weight	192.12±9.86	174.87±7.35	173.87±11.29	157.5±11.79
Final body weight	236±9.57	206.37±7.69	213.5±6.57	198.25±10.53
Weight gain (%)	23.51±3.10	18.36±2.49	27.81±5.10	25.49±6.20
Food consumption (g day ⁻¹)	17.39±0.91	17.57±0.32	16.14±0.65	16.72±0.57
Water consumption (mL day ⁻¹)	37.68±3.17	35.39±1.19	36.67±2.99	37.44±3.63

^aStatistically significant difference from the vehicle control group ($P \leq 0.05$)

Table 2 Relative organ weights (mean±SE) in the vehicle control and treated rats

Relative organ weight	Vehicle control	Fluconazole	Low-dose $C_{18}H_{12}S_2IBr$	High-dose $C_{18}H_{12}S_2IBr$
Female				
Liver	3.22±0.10	3.70±0.06 ^a	4.10±0.13 ^{a,b}	3.59±0.20
Kidney	0.36±0.006	0.35±0.007	0.39±0.013	0.34±0.015 ^c
Thymus	0.23±0.011	0.19±0.012	0.25±0.014 ^b	0.22±0.013
Spleen	0.18±0.007	0.23±0.015 ^a	0.28±0.006 ^a	0.23±0.005 ^a
Male				
Liver	2.88±0.16	2.74±0.05	2.85±0.05	2.63±0.07
Kidney	0.32±0.018	0.32±0.005	0.34±0.008	0.31±0.007 ^c
Thymus	0.11±0.008	0.12±0.009	0.12±0.009	0.12±0.012
Spleen	0.15±0.007	0.17±0.011 ^a	0.20±0.012 ^a	0.19±0.010 ^a

^aStatistically significant difference from the vehicle control group ($P \leq 0.05$)

^bStatistically significant difference from the fluconazole group ($P \leq 0.05$)

^cStatistically significant difference from the low-dose $C_{18}H_{12}S_2IBr$ group ($P \leq 0.05$)

differences in drug metabolism and pharmacokinetics in the liver of the fluconazole and $C_{18}H_{12}S_2IBr$ -treated groups.

The lower relative kidney weight in the high-dose $C_{18}H_{12}S_2IBr$ group compared to vehicle control corresponds to the lower glomerular diameters and volume.

Relative spleen weights increased significantly in all treated groups compared to the vehicle control, regardless of sex. As, according to Sellers et al. (15), spleen and thymus weights tend to change naturally, we took into account histopathological changes in these organs and observed an increase in the number of megakaryocytes in the low-dose $C_{18}H_{12}S_2IBr$ group. A similar finding in mice was observed by Fortoul et al. (16). Our organ weight results were consistent with the histological findings, including megakaryocyte increase. Greater relative spleen weight may be attributed to fibrosis and increase in megakaryocyte count in the spleen, probably induced by fluconazole or $C_{18}H_{12}S_2IBr$ treatment.

Table 3 shows haematological variations between the groups. Fluconazole significantly increased leukocytes and lowered neutrophils whereas $C_{18}H_{12}S_2IBr$ did not. This may point to fluconazole's greater toxicity. Fluconazole is known to lower the expression of various cytokine genes because of its lipophilic character (17). The increased glomerular diameter and volume in the fluconazole group seem to confirm the migration of neutrophils (18). As for other haematological parameters, all treatments had similar effects, and we saw no differences between fluconazole and $C_{18}H_{12}S_2IBr$ in respect to the vehicle control. It may be interesting to note that the pattern of variations was similar between the sexes: the same values rose or dropped in the same groups, regardless of the sex even though the doses received may have resulted in higher drug concentrations

in female rats because of the lower clearance or small volume distribution in female tissues due to different body composition and organ mass.

Table 4 shows the results of the biochemical analysis in serum samples. Even though ALT and LDH differed between the fluconazole and $C_{18}H_{12}S_2IBr$ groups, which may indicate a moderate hepatic injury with leakage of liver enzymes, no significant changes were observed in other liver enzyme levels, and the new drug did not cause significant changes in respect to control, except for LDL.

Glomerular variations (Table 5) showed the opposite effects between fluconazole and $C_{18}H_{12}S_2IBr$. Glomerular hypertrophy may be associated with hyperfiltration and thickening of the glomerular basement membrane after fluconazole treatment. In the $C_{18}H_{12}S_2IBr$ groups, lower glomerular volume may reflect inadequate filtration, kidney failure, and chronic kidney disease. Both changes are not favourable for kidney function but other parameters such as relative weight, histopathology, and biochemistry did not point to significant changes in the kidney.

Histopathology showed that $C_{18}H_{12}S_2IBr$ and fluconazole did not cause any significant changes in the liver, lymph nodes, and kidney tissues (Figure 2). Minor histopathological changes in the thymus and spleen (Figures 3, 4) were comparable between the fluconazole and $C_{18}H_{12}S_2IBr$ -treated groups and may be explained as a mechanism for countering the toxic effects of fluconazole and $C_{18}H_{12}S_2IBr$.

Cyt-c as a marker of liver and kidney injury *in vivo* has been investigated by several studies and can be used to predict drug-induced hepatotoxicity (19, 20). Figure 5 shows more cyt-c positive hepatocytes in the $C_{18}H_{12}S_2IBr$ -treated groups than in the fluconazole group. The effect of the new drug seems dose-dependent and suggests an

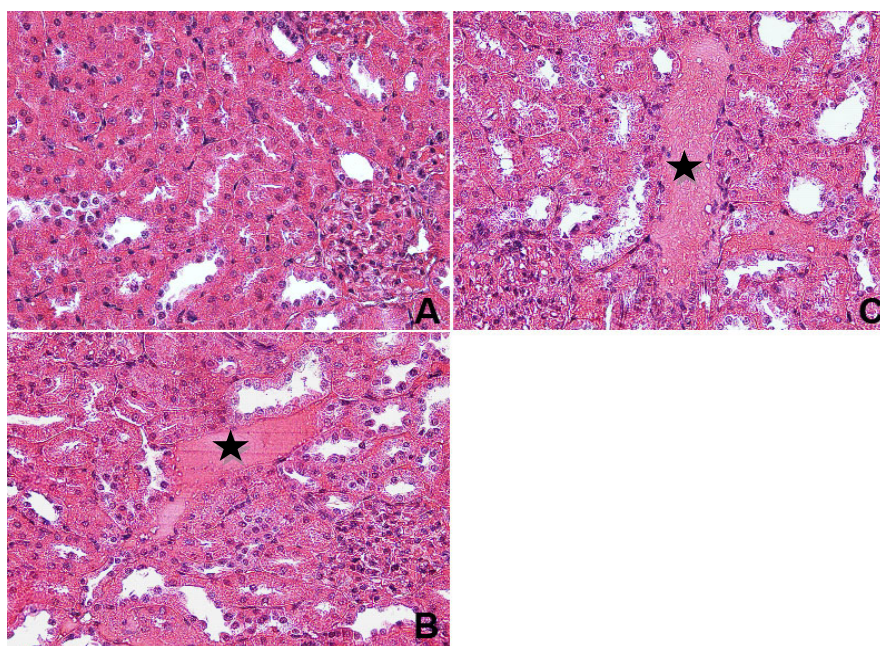


Figure 2 Kidney tissues stained with haematoxylin and eosin. **A.** Vehicle control group, **B.** Congestion in the low-dose $C_{18}H_{12}S_2IBr$ group (asterisk). **C.** Congestion in the high-dose $C_{18}H_{12}S_2IBr$ group (asterisk); magnification 200x

Table 3 Haematological findings in the vehicle control and treated rats (mean±SE)

	Vehicle control	Fluconazole	Low-dose C ₁₈ H ₁₂ S ₂ IBr	High-dose C ₁₈ H ₁₂ S ₂ IBr
Female				
Leukocytes				
White Blood Cell (mm ⁻³)	3.06±0.43	4.94±0.29 ^a	4.10±0.41	4.13±0.20 ^b
Lymphocyte %	74.48±1.60	85.67±1.38 ^a	85.06±1.24 ^a	81.15±2.21 ^a
Monocyte %	7.06±0.47	4.41±0.17	5.35±0.21	6.26±0.51
Neutrophil %	10.01±1.13	5.76±0.56 ^a	8.36±0.67	9.66±1.04
Eosinophil %	2.48±1.49	0.90±0.52	0.41±0.33	0.52±0.29
Basophil %	0.40±0.05	0.35±0.02	0.33±0.02	0.48±0.06
Erythrocytes				
Red Blood Cells (mm ⁻³)	7.42±0.23	6.56±0.29	7.02±0.08	6.35±0.30
MCV (Mean Corpuscular Volume)	47.91±0.90	54.92±0.52 ^a	56.47±0.94 ^a	58.16±0.24 ^a
HCT (Haematocrit)	35.47±0.87	36.48±1.37	39.60±0.94	38.62±0.53
MCH (Mean Corpuscular Haemoglobin)	18.98±0.40	17.02±0.14 ^a	16.45±0.12 ^a	17.57±0.34 ^a
MCHC (Mean Corpuscular Haemoglobin Concentration)	40.41±0.30	31.01±0.24 ^a	30.67±1.41 ^a	29.97±0.54 ^a
Hb (Haemoglobin)	35.08±0.40	11.20±0.51 ^a	11.35±0.30 ^a	11.46±0.21 ^a
RDW-SD (Red Cell Distribution Width-Standard deviation)	35.08±0.40	36.48±0.43 ^a	36.56±0.56 ^a	38.01±0.81 ^a
RDW-CV (Red Cell Distribution Width-Coefficient variation)	19.91±0.27	18.03±0.28 ^a	17.60±0.32 ^a	17.72±0.38 ^a
Thrombocytes				
Thrombocyte (mm ⁻³)	742.00±16.12	635.00±74.33	793.37±33.60	763.37±55.2
MPV (Mean Platelet Volume)	5.86±0.15	5.91±0.28	5.80±0.21	5.76±0.06
PDW (index of thrombocytes heterogeneity)	9.92±0.48	8.37±0.28	8.07±0.21	8.40±0.27
Male				
Leukocytes				
White Blood Cell (mm ⁻³)	3.86±0.34	5.04±0.38 ^a	3.50±0.27	3.54±0.20
Lymphocyte %	72.87±1.37	79.61±0.96 ^a	79.83±1.72 ^a	77.92±1.94 ^a
Monocyte %	6.18±0.45	6.41±0.23	6.57±0.37	6.80±0.21
Neutrophil %	13.65±0.93	9.65±0.69 ^a	11.33±1.13	11.41±0.74
Eosinophil %	1.15±0.39	1.08±0.44	0.51±0.34	1.10±0.60
Basophil %	0.35±0.05	0.43±0.04	0.45±0.06	0.33±0.03
Erythrocytes				
Red Blood Cell (mm ⁻³)	8.60±0.18	8.37±0.17	8.23±0.13	7.90±0.19
MCV (Mean Corpuscular Volume)	46.83±0.76	55.85±0.46 ^a	52.1±0.47 ^a	54.9±0.74 ^a
HCT (Haematocrit)	40.33±1.26	46.75±0.92	42.83±0.61	43.31±0.96
MCH (Mean Corpuscular Haemoglobin)	18.17±0.24	16.72±0.25 ^a	16.58±0.28 ^a	16.91±0.18 ^a
MCHC (Mean Corpuscular Haemoglobin Concentration)	38.42±0.53	29.93±0.45 ^a	31.85±0.37 ^a	30.48±0.23 ^a
Hb (Haemoglobin)	35.33±0.28	14.00±0.27 ^a	13.62±0.15 ^a	13.20±0.31 ^a
RDW-SD (Red Cell Distribution Width-Standard deviation)	35.33±0.28	39.26±0.11 ^a	37.75±0.23 ^a	39.28±0.28 ^a
RDW-CV (Red Cell Distribution Width-Coefficient variation)	20.52±0.31	17.41±1.16 ^a	19.67±0.10 ^a	19.43±0.15 ^a
Thrombocytes				
Thrombocyte (mm ⁻³)	607.00±78.07	732.12±29.35	711.50±32.62	806.37±24.96
MPV (Mean Platelet Volume)	7.21±0.41	5.86±0.05	5.76±0.11	6.06±0.30
PDW (index of thrombocyte heterogeneity)	11.31±0.31	8.61±0.10	8.76±0.17	8.75±0.39

^aStatistically significant difference from the vehicle control group (P≤0.05)

^bStatistically significant difference from the fluconazole group (P≤0.05)

Table 4 Blood biochemistry in the vehicle control and treated rats (mean±SE)

	Vehicle control	Fluconazole	Low-dose C ₁₈ H ₁₂ S ₂ I ₂ Br	High-dose C ₁₈ H ₁₂ S ₂ I ₂ Br
Female				
AST (IU L ⁻¹)	173.31±4.49	161.75±14.91	252.57±23.96	219.67±21.17
ALT (IU L ⁻¹)	57.25±2.82	57.03±3.43	75.41±1.30 ^b	68.18±4.11
LDL (mg dL ⁻¹)	33.52±3.94	33.28±1.10	39.98±1.71 ^{a,c}	30.90±0.96
HDL (mg dL ⁻¹)	53.04±1.95	46.70±2.77	48.53±2.38	44.08±1.56
Chol (mg dL ⁻¹)	64.55±4.35	64.20±7.00	58.98±7.13	49.96±5.34
LDH (IUL ⁻¹)	2817.83±344.21	1958.50±166.12 ^a	4858.12±325.06 ^b	3666.50±275.17 ^b
Urea (mg dL ⁻¹)	53.41±2.94	55.75±2.51	62.00±3.33	53.62±3.13
Male				
AST (IU L ⁻¹)	236.38±20.93	217.73±9.33	226.12±12.47	250.77±17.67
ALT (IU L ⁻¹)	59.48±3.55	51.36±3.59	62.07±3.42 ^b	57.76±5.15
LDL (mg dL ⁻¹)	30.90±0.20	38.80±1.67	42.91±2.63 ^{a,c}	37.20±0.63
HDL (mg dL ⁻¹)	44.00±2.31	45.44±3.57	50.26±3.68	41.38±4.28
Chol (mg dL ⁻¹)	55.91±3.12	66.52±5.74	51.46±7.26	64.35±7.80
LDH (IU L ⁻¹)	5419.37±432.95	3206.62±402.39 ^a	5419.00±590.95 ^b	5155.50±526.64 ^b
Urea (mg dL ⁻¹)	55.00±3.36	47.50±2.62	46.12±3.76	47.85±3.60

^aStatistically significant difference from the vehicle control group ($P \leq 0.05$)

^bStatistically significant difference from the fluconazole group ($P \leq 0.05$)

^cStatistically significant difference from the high-dose C₁₈H₁₂S₂I₂Br group ($P \leq 0.05$)

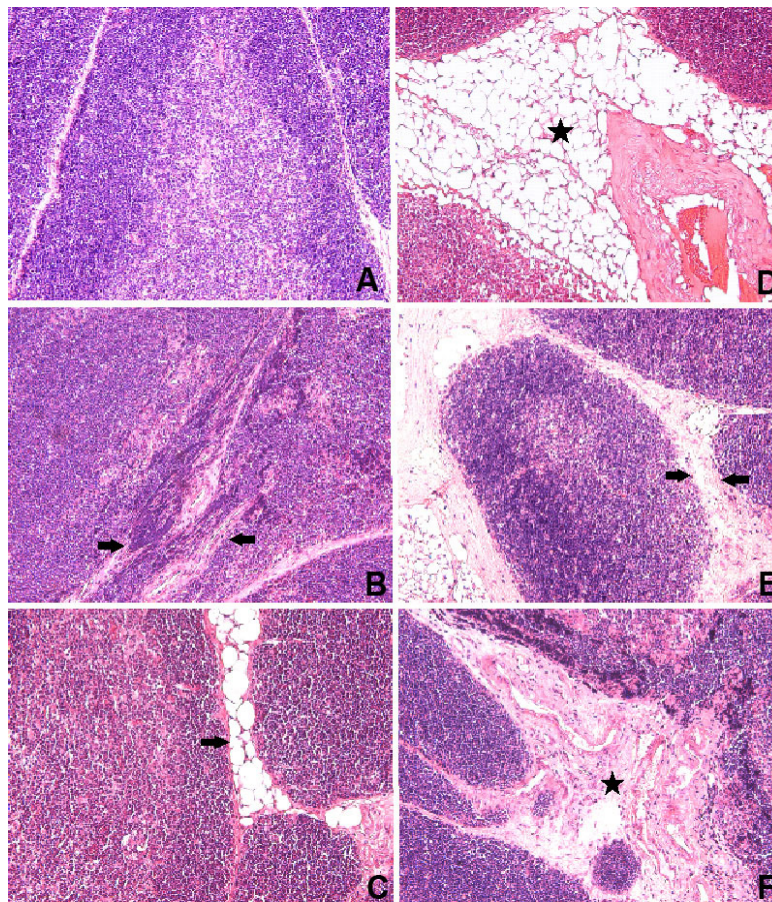


Figure 3 Thymus tissues stained with haematoxylin and eosin. **A.** Vehicle control group **B.** Fibrosis (arrow) in the fluconazole group, **C.** Increases in the fat cells of the connective tissue in the fluconazole group (arrow). **D.** Increases in the fat cells of the connective tissue (asterisk) in the low-dose C₁₈H₁₂S₂I₂Br group. **E.** Enlargement of the interstitial connective tissue in the low-dose C₁₈H₁₂S₂I₂Br group (arrow). **F.** Fibrosis in the high-dose C₁₈H₁₂S₂I₂Br group (asterisk); magnification 100x

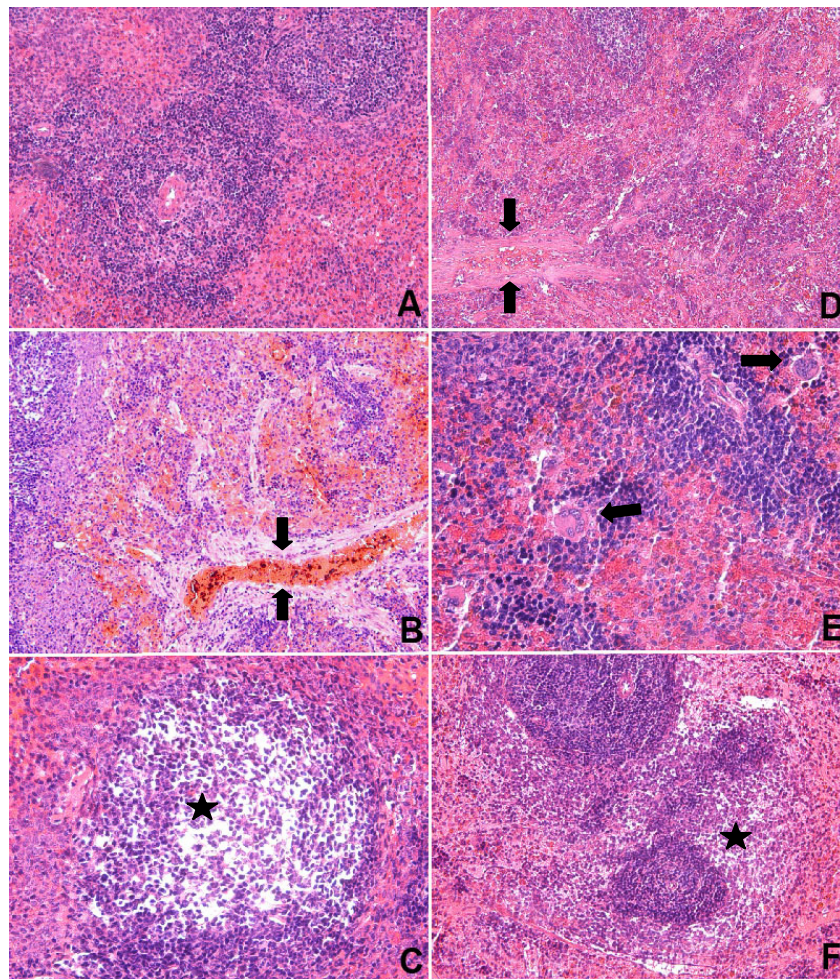


Figure 4 Spleen tissues stained with haematoxylin and eosin. **A.** Vehicle control group; magnification 100x. **B.** Fibrosis in the fluconazole group (arrow), **C.** Lymphocyte depletion in the white pulp in the fluconazole group (asterisk); magnification 200x. **D.** Fibrosis (arrow) in the low-dose $C_{18}H_{12}S_2IBr$ group, **E.** Increase in megakaryocyte count in the low-dose $C_{18}H_{12}S_2IBr$ group (arrow); magnification 200x. **F.** Lymphocyte depletion in the white pulp in the high-dose $C_{18}H_{12}S_2IBr$ group (asterisk); magnification 100x

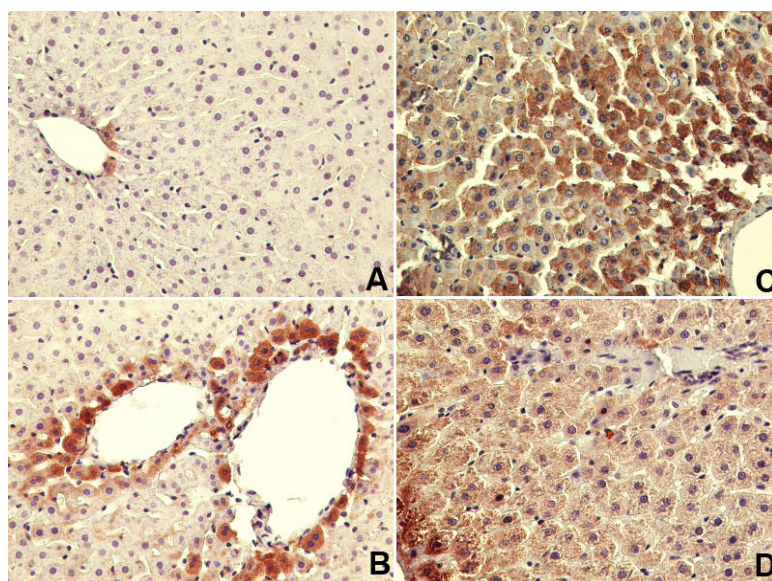
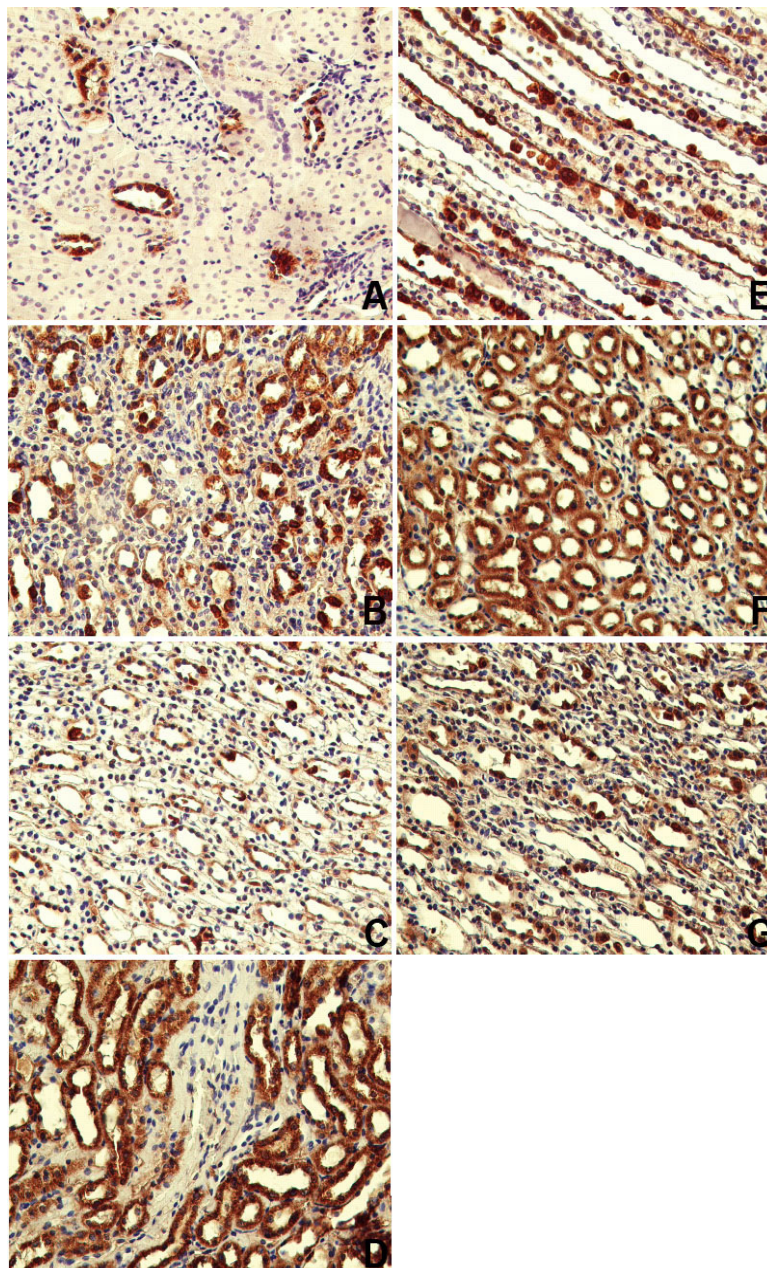


Figure 5 Immunolocalisation of cyt-c in perivenular, midzonal, or periportal hepatocytes in the liver sections. Cyt-c positive cells (brown) **A.** in the vehicle control group, **B.** in the fluconazole group (arrow), **C.** In the low-dose $C_{18}H_{12}S_2IBr$ group, **D.** in the high-dose $C_{18}H_{12}S_2IBr$ group; magnification 200x

Table 5 Glomerular measurements in the vehicle control and treated rats (mean±SE)

Groups	Diameter of glomerulus		Glomerular volume ($10^3 \mu\text{m}^3$)
	x axis	y axis	
Vehicle control	65.23±0.89	81.83±1.34	218.36±8.76
Fluconazole	69.58±0.94 ^a	86.64±1.37	262.26±11.06 ^a
Low-dose C ₁₈ H ₁₂ S ₂ IBr	62.43±1.0 ^b	75.92±1.23 ^{a,b}	184.17±7.88 ^{a,b}
High-dose C ₁₈ H ₁₂ S ₂ IBr	59.40±0.97 ^{a,b}	79.13±1.51 ^b	186.32±8.30 ^b

^aStatistically significant difference from the vehicle control group ($P \leq 0.05$)^bStatistically significant difference from the fluconazole group ($P \leq 0.05$)**Figure 6** Immunolocalisation of cyt-c in the kidney sections. Cyt-c positive cells (brown) **A.** in the proximal tubules and some distal tubules of the kidney cortex in the vehicle control group. **B.** Cortex, **C.** Medulla of the kidney in the fluconazole group. **D.** Cortex, **E.** Medulla of the kidney in the low-dose C₁₈H₁₂S₂IBr group. Greater cyt-c-positive cell staining (brown) **F.** Cortex, **G.** Medulla of the kidney in the high-dose C₁₈H₁₂S₂IBr group; magnification 200x

increase in the number of apoptotic cells. However, as these changes did not exactly match the biochemical and histopathological findings as the key indicators of liver injury, it is hard to claim that C₁₈H₁₂S₂IBr induced liver toxicity.

Figure 6 compares immunolocalisation of cyt-c in the kidney between the vehicle control and treatment groups. Greater staining in the C₁₈H₁₂S₂IBr-treated groups compared to fluconazole group points to greater apoptotic effect.

CONCLUSION

This study was the first to test the newly synthesised thialo benzene derivative C₁₈H₁₂S₂IBr in mammals *in vivo* and to compare it to the conventional anti-fungal drug fluconazole. Considering that C₁₈H₁₂S₂IBr is more active at lower concentrations and has comparable toxic effects to fluconazole in rats, this new compound shows some promise in the treatment of fungal infections. Future, more detailed animal studies are needed, that will include drug interactions and molecular toxicity pathways. If the results are promising, clinical studies should follow.

Conflict of interest

The authors declare no conflict of interest.

REFERENCES

- Infectious Diseases Society of America. Statement of the IDSA concerning Bioshield II: Responding to an ever-changing threat'. Alexandria, VA: IDSA; 2004.
- Sun QY, Zhang WN, Xu JM, Cao YB, Wu QY, Zhang DZ, Liu CM, Yu SC, Jiang YY. Synthesis and evaluation of novel 1-(1H-1,2,4-triazol-1-yl)-2-(2,4-difluorophenyl)-3-[(4-substitutedphenyl)-piperazin-1-yl]-propan-2-ols as antifungal agents. *Eur J Med Chem* 2007;42:1151-7. doi: 10.1016/j.ejmech.2006.11.003
- Hilley Vensel TD. Fluconazole: a valuable fungistatic. *Primary Care Update for OB/GYNs* 2002;9:181-3. doi: 10.1016/S1068-607X(02)00115-4
- Loğoğlu E, Arslan S, Öktemer A. *In vitro* biological activity studies of thioethoxy- and thiophenoxyhalobenzene derivatives. *Heterocycl Comm* 2006;12:219-24. doi: 10.1515/HC.2006.12.3-4.219
- Süloğlu AK, Karacaoğlu E, Koçkaya EA, Selmanoğlu G, Loğoğlu E. Cytotoxic effects of a novel thialo benzene derivative 2,4-dithiophenoxy-1-Iodo-4-bromo benzene (C₁₈H₁₂S₂IBr) in L929 cells. *Int J Toxicol* 2014;33:319-24. doi: 10.1177/1091581814530437
- Food and Drug Administration (FDA). DIFLUCAN® (Fluconazole Tablets) (Fluconazole for Oral Suspension) [displayed 2 March 2015]. Available at http://www.accessdata.fda.gov/drugsatfda_docs/label/2014/019949s060,020090s0441bl.pdf
- Park K, Williams DP, Naisbitt DJ, Kitteringham NR, Pirmohamed M. Investigation of toxic metabolites during drug development. *Toxicol Appl Pharmacol* 2005;207(Suppl 2):425-34. PMID: 15996699
- Joly V, Bolard J, Yeni P. *In vitro* models for studying toxicity of antifungal agents. *Antimicrob Agents Chemother* 1992;36:1799-804. PMC 192189
- National Research Council. Guide for the Care and Use of Laboratory Animals. Eighth edition, 2011 [displayed 13 February 2015]. Available at <http://grants.nih.gov/grants/olaw/Guide-for-the-care-and-use-of-laboratory-animals.pdf>
- Pappas PG, Rex JH, Sobel JD, Filler SG, Dismukes WE, Walsh TJ, Edwards JE. Guidelines for treatment of Candidiasis. *Clin Infect Dis* 2004;38:161-89. doi: 10.1086/380796
- Kılıç A, Akay MT. A three generation study with genetically modified Bt corn in rats: Biochemical and histopathological investigation. *Food Chem Toxicol* 2008;46:1164-70. doi: 10.1016/j.fct.2007.11.016
- Babu PP, Yoshida Y, Su M, Segura M, Kawamura S, Yasui N. Immunohistochemical expression of Bcl-2, Bax and cytochrome c following focal cerebral ischemia and effect of hypothermia in rat. *Neurosci Lett* 2000;291:196-200. PMID: 10984640
- Koçkaya EA, Kılıç Süloğlu A, Karacaoğlu E, Selmanoğlu G. Vinclozolin Exposure throughout pregnancy and its developmental toxicity. *Toxicol Res* 2014;3:375-83. doi: 10.1039/C4TX00037D
- Waxman DJ, Holloway MG. Sex differences in the expression of hepatic drug metabolizing enzymes. *Mol Pharmacol* 2009;76:215-28. doi: 10.1124/mol.109.056705
- Sellers RS, Morton D, Michael B, Roome N, Johnson J.K, Yano BL, Perry R, Schafer K. Society of Toxicologic Pathology Position Paper: Organ weight recommendations for toxicology studies. *Toxicol Pathol* 2007;35:751-5. PMID: 17849358
- Fortoul TI, Piñón-Zarate G, Diaz-Bech ME, González-Villalva A, Mussali-Galante P, Rodriguez-Lara V, Colin-Barenque L, Martinez-Pedraza M, Montaña LF. Spleen and bone marrow megakaryocytes as targets as targets for inhaled vanadium. *Histol Histopathol* 2008;23:1321-6. PMID: 18785114
- Benko I, Hernadi F, Megyeri A, Kiss A, Somogyi G, Tegyei Z, Kraicsovits F, Kovács P. Comparison of the toxicity of fluconazole and other azole antifungal drugs to murine and human granulocyte-macrophage progenitor cells *in vitro*. *J Antimicrob Chemother* 1999;43:675-81. doi: 10.1093/jac/43.5.675
- Feng L, Xia Y, Yoshimura T, Wilson CB. Modulation of neutrophil influx in glomerulonephritis in the rat with anti-macrophage inflammatory protein-2 (MIP-2) antibody. *J Clin Invest* 1995;95:1009-17. doi: 10.1172/JCI117745
- González-Flecha B, Cutrin JC, Boveris A. Time course and mechanism of oxidative stress and tissue damage in rat liver subjected to *in vivo* ischemia-reperfusion. *Clin Invest* 1993;91:456-64. doi: 10.1172/JCI116223
- Miller TJ, Knapton A, Adeyemo O, Noory L, Weaver J, Hanig JP. Cytochrome c: a non-invasive biomarker of drug-induced liver injury. *J Appl Toxicol* 2008;28:815-28. doi: 10.1002/jat.1347

***In vivo* toksičnost novoga antimikotika 2,4-ditiofenoksi-1-jodo-4-bromobenzena: proširenje *in vitro* istraživanja**

Triazolni antifungalni lijek flukonazol danas je najrašireniji antimikotik u svijetu, mahom zato što dobro prodire u tjelesne tekućine i tkiva. Primijećeno je međutim da ulazi u interakciju s drugim lijekovima, a zbog česte uporabe sve je veći i rizik od stvaranja rezistencije na njega. Stoga se traži njegova dostojna zamjena. Godine 2006. sintetiziran je novi derivat tialobenzena - 2,4-ditiofenoksi-1-jodo-4-bromobenzen ($C_{18}H_{12}S_2IBr$). Iako je ugljikova osnovica tog derivata slična onoj flukonazolu, u prvim *in vitro* istraživanjima pokazao se puno djelotvorniji. Uslijedilo je *in vitro* istraživanje njegove citotoksičnosti, u kojem se novi spoj pokazao obećavajućom zamjenom za flukonazol. Cilj je ovog istraživanja bio otići korak dalje i istražiti toksičnost $C_{18}H_{12}S_2IBr$ *in vivo*. Odlučili smo se za četverotjedno istraživanje na štakorima Wistar, kojima se je novi antimikotik davao na usta u dozama dva i pol i pet puta nižima od uobičajene doze flukonazola. U životinja nisu primijećene promjene u konzumiranju hrane i vode, ali je relativna težina organa u ženki bila drugačija u odnosu na kontrolnu skupinu, što upućuje na razlike između spolova u metabolizmu lijeka. Za razliku od $C_{18}H_{12}S_2IBr$, flukonazol je prouzročio značajno povišenje razine leukocita i smanjenje neutrofila. Ostale hematološke promjene u odnosu na kontrolnu skupinu bile su slične u skupina koje su primale bilo flukonazol bilo novi lijek. Razlike u imunolokalizaciji citokroma c u jetrima i bubrezima pokazatelj su snažnijeg apoptotičkog učinka novoga lijeka, ali se zbog drugih ključnih pokazatelja (biokemijskih i histopatoloških) ne može ništa zaključiti jer oni ne odgovaraju nalazima citokroma c. S obzirom na to da $C_{18}H_{12}S_2IBr$ snažnije djeluje od flukonazola pri nižim koncentracijama, uz podjednake toksične učinke u štakora, ovaj je novi spoj nesumnjivo obećavajuća alternativa liječenju gljivičnih infekcija. Potrebna su daljnja, detaljnija istraživanja u životinja, koja će obuhvatiti interakcije spojeva i molekularne putove toksičnosti. Bude li se lijek i u tim istraživanjima pokazao boljom alternativom, trebalo bi provesti klinička ispitivanja u ljudi.

KLJUČNE RIJEČI: *biokemija; citokrom-c; flukonazol; histopatologija; in vivo toksičnost; krv*