

Suresh K. Sachdeva

Kraniofacijalna fibrozna displazija kod starijih pacijenata: prikaz slučaja s pregledom literature

Craniofacial Fibrous Dysplasia in an Elderly Patient: A Case Report with a Review of Literature

Odjel za oralnu medicinu i radiologiju Stomatološkog fakulteta i Sveučilišne bolnice Vyas, Jodhpur - 342005, Rajasthan, Indija
Department of Oral Medicine and Radiology, Vyas Dental College & Hospital, Jodhpur-342005, Rajasthan, India

Sažetak

Fibrozna displazija benigni je fibrokoštani poremećaj, a obilježava ga fibrozno vezivno tkivo koje sadržava abnormalnu kost koja zamjenjuje normalnu. Predstavlja dva do pet posto svih koštanih tumora i sedam posto svih benignih novotvorina. Najčešće zahvaća mladu dobnu skupinu, s većom prevalencijom kod maksile negoli mandibule. To je lezija nepoznate etiologije, nesigurne patogenosti i različite histologije. Fibrozna displazija zahvaća višestruke (poliostotična) ili pojedinačne kosti (monostotična). Njezine lezije mogu se kirurški ukloniti i preoblikovati radi estetike ili funkcije. U tekstu se opisuje slučaj kraniofacijalne fibrozne displazije kod 83-godišnjeg pacijenta, a naglasak je na radiološkom nalazu.

Zaprimljen: 28. rujna 2014.

Prihvaćen: 31. siječnja 2015.

Adresa za dopisivanje

Dr. Suresh K. Sachdeva, M.D.S.,
13/573, Gali No.1, Khanna Colony,
Sirsa-125055, Haryana, India
tel.:+91 8764419775
drsureshsachdeva7184@gmail.com

Ključne riječi

fibrozna displazija kosti; tumori kosti; starije osobe; gornja čeljust

Uvod

Fibrozna displazija (FD) rijedak je poremećaj, a obilježava ga fibrozno vezivno tkivo koje sadržava abnormalnu kost koja zamjenjuje normalnu. Čini dva do pet posto svih koštanih tumora (1). Lichtenstein je 1938. prvi predložio naziv *fibrozna displazija* (2). Taj poremećaj može zahvatiti više kostiju (polistotični) ili pojedinu kost (monostotični). Monostotična fibrozna displazija manje je ozbiljna i češća je (70 %) negoli polistotični oblik (30 %) (3). Preostalih deset posto slučajeva povezano je sa sindromom poput McCune-Albrightova sindroma i kerubizmom 4. Poliostotični oblik dijeli se na tri podvrste: kraniofacijalnu (zahvaćene su samo kosti kraniofacijalnog područja), Lichtenstein-Jaffeov sindrom (zahvaća nekoliko skeletnih kostiju zajedno s pigmentacijom *café au lait* – bijela kava) i Albrightov sindrom (zahvaća više skeletnih kostiju, pigmentacija *café au lait*, multiple endokrinopatije) (5). U području glave i vrata češće je zahvaćena maksila od mandibule, posebice u stražnjim dijelovima čeljusti. Klinički je kraniofacijalni FD općenito u porastu, kao asimptomatska, koštano tvrda čvrsta oteklina s netaknutom površinom. Budući da je simptomatski, pacijenti traže pomoć kad uoče veće deformitete lica ili funkcionalne poremećaje (6).

Introduction

Fibrous dysplasia (FD) is a rare bone disorder, characterized by fibrous connective tissue containing abnormal bone which replaces normal bone. It accounts for 2% to 5% of bone tumors (1). Lichtenstein in 1938 was the first to suggest the term "fibrous dysplasia" (2). Fibrous dysplasia can involve multiple bones (polyostotic) or a single bone (monostotic). Monostotic fibrous dysplasia is less serious and more common (70%) than the polyostotic form (3). The remaining ten percent of cases are associated with syndromes such as McCune Albright syndrome and Cherubism (4). The polyostotic form is further divided into three subtypes: craniofacial (only the bones of craniofacial regions are involved); Lichtenstein-Jaffe (involvement of many skeletal bones along with café au lait pigmentations); Albright's Syndrome (by the involvement of many skeletal bones, café au lait pigmentations and multiple endocrinopathies) (5). In the head and neck region, maxilla is involved more frequently than the mandible, especially the posterior aspects of the jaws. Clinically, craniofacial FD generally presents as a gradually increasing, asymptomatic, bony hard and non-tender swelling with intact overlying surface. Since the condition is asymptomatic, patients seek treatment only when severe facial deformity or functional disturbance occur (6).

Prikaz slučaja

Pacijent se složio s objavljivanjem prikaza i slika o svojoj bolesti te je potpisao informiranu suglasnost.

Muškarac od 83 godine javio se liječniku zbog otekline na lijevoj strani lica. Prema povijesti bolesti, lezija je na početku bila mala, ali je tijekom godina postupno i progresivno narasla do opisane veličine. Nije imao vrućicu, traumu ili slične otekline nigdje na tijelu, a obiteljska i njegova dentalna anamneza bile su u redu. Pacijent je imao teškoća sa sluhom te se koristio slušnim aparatom. Nije bilo ni riječi o glavobolji, vizualnom poremećaju, bolovima u ušima, nosnim opstrukcijama ili iscjetu iz nosa. Opći pregled pokazao je da je normalne građe i visine, s očitom asimetrijom lica. Tijekom ekstraoralnog pregleda pronađena je difuzna koštana tvrda otekline na lijevoj strani srednje trećine lica. Bila je velika oko 5 x 6,5 centimetara. Lezija se prostirala centimetar lateralno od *alle nasi* do centimetar anteriorno od lijevoga periaurikularnog područja. Superiorno je sezala od donjeg ruba orbite oko dva centimetra ispod linije *ala – tragus* inferiorno. *Fossa canina* bila je izbočena, uočena je i prominencija zigomatičnog procesa, a koža iznad strukture bila je intaktna i normalna (slika 1.). Regionalni limfni čvorovi nisu se mogli palpirati. Intraoralno je uočena dobro ograničena otekline koja je zahvaćala lijevi alveolarni nastavak od 23 do 28 regija i širenje kortikalne ploče. Bukalna kortikalna ekspanzija obliterirala je maksilarni bukalni vestibulum i palatinalno se proširila prema središnjoj *rafe palati*. Sluznica je bila intaktna i normalne boje (slika 1.b). Na dodir je otekline bila čvrsta, tvrda i bezbolna. Ostatak usne šupljine bio je bez osobitosti, osim lošega paradontnog statusa zuba. Na osnovi podataka iz anamneze te kliničkoga nalaza postavljena je privremena dijagnoza – benigna koštana novotvorina, najvjerojatnije fibrokoštana lezija. Slijedio je standardni pregled koji je uključivao kompletnu krvnu sliku, određivanje serumskog kalcija, fosfata i alkalne fosfataze, no svi su nalazi bili unutar fizioloških granica. Na konvencionalnoj radiografskoj intraoralnoj periapikalnoj slici, okluzalnom i panoramskom radiogramu te Weterovu pogledu, bila je vidljiva difuzna homogena radioopakna masa lezije nalik na zdrobljeno staklo. Lezija je bila velika 4 x 5 centimetara, zahvaćala je maksilarni sinus i širila se na donji rub očne šupljine i lateralno graničila s *fossa nasale* i *arco zigomatico* (slika 2 a, b, c, i d). Aksijalna i koronarna kompjutorizirana tomografija (CT) pokazale su povećanu gustoću s povećanim maksilarnim alveolarnim nastavkom, deformitetom u koštanom rastu i miješanim koštanim izgledom poput smrvljenoga stakla, uključujući lijevu maksilu, maksilarni sinus, sfenoidno tijelo te malo i veliko krilo sfenoidne kosti (slika 3. a i b). Na temelju povijesti bolesti, trajanja asimptomatične lezije, kliničkih nalaza i tipičnoga izgleda poput zdrobljenog stakla te zahvaćenih susjednih kostiju, postavljena je privremena dijagnoza fibrozne displazije kraniofacijalnog tipa. Incizijska biopsija obavljena je pod lokalnom anestezijom, a bioptički materijal poslan je na histološku pretragu. Analiza je pokazala koštanu trabekularnu strukturu u obliku kineskoga slova isprepletenu s fibroznim vezivnim tkivom (slika 4.). Konačna dijagnoza fibrozne displazije (kraniofacijalnog tipa) postavljena je na temelju ma-

Case Report

Written informed consent was obtained from the patient for publication of this case report and accompanying images.

An 83-year-old male reported with a swelling on the left side of face. History of the presenting illness revealed that initially the swelling was small in size, but now gradually and slowly progressed over many years to attain the present size. There was no history of fever, trauma and similar swelling elsewhere in the body, with non-contributory past medical or dental and family history. Patient had difficulty in hearing, so he was using a hearing aid for the same. There was no history of headache, visual disturbance, earaches, nasal obstruction or nasal discharge.

On general examination, the patient was of normal built and height with mild obvious facial asymmetry. On extraoral examination, a diffuse, bony hard swelling was present on the left side of the middle third of face, measuring approximately 5cmX 6.5cm in size. The lesion extended laterally from the 1cm lateral to ala of nose up to the 1cm anterior to left preauricular region. Superiorly the lesion extended from the inferior border of the orbit to approximately 2cm below the ala tragus line, inferiorly. There was bulging of canine fossa and prominence of the zygomatic process, with normal and intact overlying skin, (Figure 1a). Regional lymph nodes were not palpable.

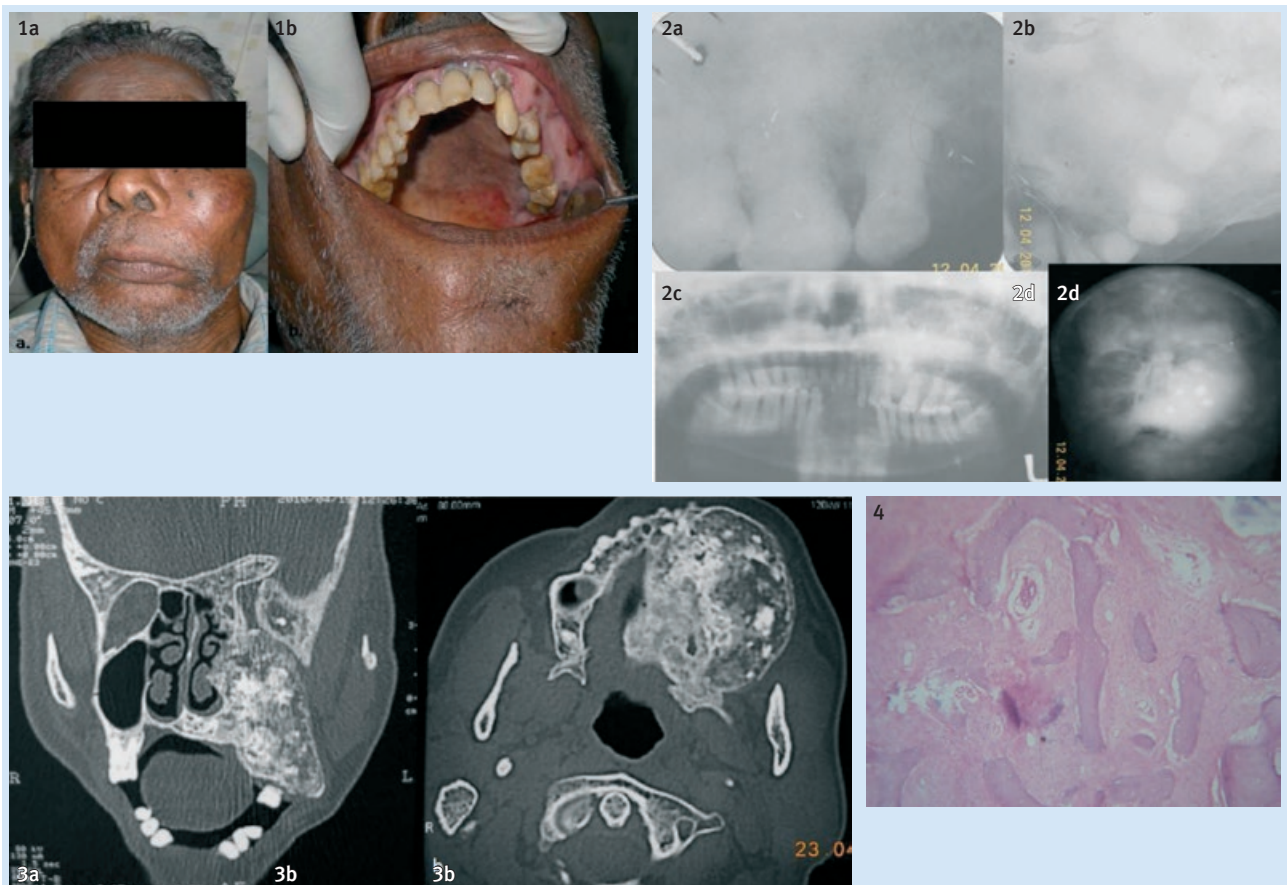
Intraorally, there was a single, ill-defined swelling involving left maxillary alveolar process from 23 to 28 region with expansion of cortical plate. The buccal cortical expansion obliterated the left maxillary buccal vestibule and palatally it extended towards mid palatine raphe. The overlying mucosa was normal in color and intact, (Figure 1b). On palpation, the swelling was firm to hard in consistency and was non-tender. Rest of the oral cavity appeared normal except the periodontal status of the teeth was poor.

On the basis of the history and clinical examination, a provisional diagnosis of benign osseous neoplasm was made, most probably fibro-osseous lesion. Routine investigations including complete blood count, serum calcium, phosphorus and alkaline phosphatase were all within normal limits.

On conventional radiography including intra oral periapical radiograph, cross-sectional occlusal radiograph, orthopantomogram and water's view, all revealed diffuse homogeneous radiopacity, giving a ground glass appearance to the lesion. The lesion was approximately 4cmX5cm in size involving the maxillary sinus and extending into the inferior border of the orbit, lateral border of the nasal fossa and zygomatic arch, (Figure 2 a-d).

Axial and coronal computed tomographic (CT) examination revealed increased density with enlarged maxillary alveolus, marked deformity with the osseous expansion and mixed osseous pattern with areas giving a ground glass appearance, and involving left maxilla, maxillary sinus, sphenoid body, lesser wing and greater wing of sphenoid bone, (Figure 3a, b).

Based on the history of long duration with asymptomatic nature of the lesion, clinical features and imaging features, showing typical ground-glass appearance with involvement



Slika 1. (a i b) Pojedinačna difuzna i tvrda koštana otekline na lijevoj strani lica s intaktnom pokrovnom kožom uzrokuje asimetriju lica. (1.a) Intraoralno je samostalna, unilateralna otekline koja zahvaća lijevu maksilu te odiže kortikalnu ploču i obliterirane obrazne vestibule. Sluznica iznad intaktna je i normalne boje (1.b).

Figure 1(a, b) Solitary diffuse, osseous hard swelling present on the left side of face with intact overlying skin, causing facial asymmetry (1a). Intraoral, single, unilateral swelling involving left maxilla with expansion of cortical plate, with obliterated buccal vestibule. The overlying mucosa was normal in color and intact (1b).

Figure 2 (a, b, c & d) Diffuse homogeneous radiopacity, giving a ground glass appearance to the lesion on left maxilla, expanded cortices and loss of lamina dura.

Slika 2. (a,b, c i d) Difuzni homogeni radiopacitet koji leziji na lijevoj maksili daje izgled *smrvljenoga stakla*; odvojena kortikalna ploča i gubitak lamine dure

Figure 3 (a & b) CT scan (both axial and coronal) showing heterogeneous, expansile lesion giving a ground glass appearance involving maxilla, maxillary sinus, sphenoid body, lesser wing and greater wing of sphenoid bone on left side.

Slika 3. (a i b) CT-snimka (aksijalna i koronarna) pokazuje heterogenu, ekspanzivnu leziju izgleda *smrvljenoga stakla* i uključuje maksilu, maksilarni sinus, sfenoidno tijelo te malo i veliko krilo sfenoidalne kosti na lijevoj strani

Figure 4 Chinese letter shape osseous trabecular interspersed between fibrous connective tissue (H & E, X40).

Slika 4. Koštana trabekula u obliku kineskoga slova ugurana između fibroznoga vezivnog tkiva (H i E, x 40)

kroskopskog izgleda te kliničkoga i mikroskopskog nalaza. S obzirom na asimptomatičnu prirodu lezije i dob, pacijent nije pristao na daljnju terapiju te su mu preporučene redovite kontrole.

of adjacent bones, a provisional diagnosis of fibrous dysplasia (craniofacial type) was made. Incisional biopsy of the lesion was taken under local anesthesia, and sent for histopathological examination, which showed Chinese letter shape osseous trabecular interspersed between fibrous connective tissue (Figure 4). Thus a final diagnosis of fibrous dysplasia (craniofacial type) was made, based upon clinical, imaging and microscopic features. Due to its asymptomatic nature and age factors, patient was not willing for further treatment, so a regular follow-up was advised.

Rasprava

Etiologija abnormalnog rasta u slučaju fibrozne displazije povezana je s mutacijom gena koji kodiraju podjedinicu stimulativnog G proteina (G-sa) smještenog na drugom kromosomu, a vodi prema zamjeni cisteina ili histadina u

Discussion

The etiology of abnormal growth process in fibrous dysplasia is related to a mutation in the gene that encodes the sub unit of a stimulatory G protein (Gsa) located on chromosome 2, which leads to substitution of the cysteine or the

genomskoj DNK osteoblastnih stanica drugom aminokise- linom – argininom, što rezultira razvojem fibrozno tkiva iz osteoblastnih stanica u koštanoj srži umjesto razvoja normal- ne kosti (7).

Patogeneza ove bolesti nedovoljno je opisana. Schlum- burger smatra da na taj poremećaj utječu infekcija ili trauma, iako je dokumentirana i genska predispozicija (8).

Fibrozna displazija koja obuhvaća prednju maksilu i ši- renje na antrum i zidove, može se očitovati i u tzv. *lavljem izgledu*. Uključivanje orbite uzrokuje proptozu. Baza lubanje najčešće je zahvaćena u slučaju kraniofacijalnog oblika fibro- zne displazije, i to uglavnom sfenoidna kost. Ako je zahvaće- na mandibula, to može uzrokovati pomak alveolarnog kana- la prema gore. Nenikli zubi rijetko se vide u slučaju fibrozne displazije jer se većina tih poremećaja razvija nakon nicanja, pri čemu se iznikli zubi mogu pomaknuti pa posljedično na- staje promjena okluzije. Najčešća lokalizacija u slučaju zahva- ćenosti dugih kostiju jest vrat femura. Povećana zahvaćenost gornjeg femura rezultira omekšavanjem i zaokruživanjem kosti, što je opisano kao tzv. *Shepherd's crook* deformitet (9).

Na klasičnim radiogramima su rubovi fibrozne displazi- je dobro ograničeni, uz gubitak *lamina durra* oko zuba zbog zamjene normalne kosti (10). Starenjem lezije pojavljuje se tendencija povećanja radioopaciteta i značajno homogeno povećanje koštane gustoće povezano s ekspanzijom kosti. To se ponekad opisuje kao izgled *smrvljenoga stakla*, što je vid- ljivo na CT-u. Cistične lezije podjednake veličine stanjuju i remodeliraju kortikalne kosti, ali rijetko uzrokuju perfora- ciju korteksa ili stvaranje nove periosealne kosti. Premda le- zija ponekad može prouzročiti resorpciju korijena niknutih zuba, to se rijetko događa. Prikazivanje kosti s pomoću Tc- 99 m MDP-om otkrilo je povećano primanje radioizotopa i leziju fibrozne displazije. Na prikazanoj magnetskoj rezon- anciji slike označene s T1 otkrivaju fibroznu displaziju kao hipointenzitet, a slike označene s T2 prikazuju fibroznu dis- plaziju kao hiperintenzitet ili hipointenzitet (11). Diferenci- jalna dijagnoza FD-a uključuje centralni osificirani fibrom (COF), osteomijelitis i Pagetovu bolest. COF se pojavljuje u dobi između trideset i pedeset godina i žene su češće pogođe- ne negoli muškarci, a FD se uglavnom otkriva u drugom de- setljeću života i podjednako pogađa i žene i muškarce. COF se uglavnom pojavljuje u prednjem dijelu mandibule, a FD je češći u stražnjim područjima maksile. Radiografski nalaz s dobro ograničenim rubovima govori u prilog COF-u za raz- liku od FD-a kod kojega rubovi imaju tendenciju spajanja s okolnom normalnom kosti (12). Razlikovanje ovih dviju lezija važno je jer se protokoli liječenja dosta razlikuju. FD može oponašati Pagetovu bolest kosti, ali se kod pacijenata s FD-om lezija pojavljuje poslije, kao u opisanom slučaju. Pa- getova bolest nastaje ponajprije kod starijih ljudi, a manife- stira se zadebljanjem korteksa, radiografski izgleda poput pa- mučne vate, a u serumu nalazimo povišenu razinu alkalne fosfataze. Najkorisnije kliničko svojstvo za razlikovanje FD- a od Pagetove bolesti jest da se kod Pagetove bolesti obično javlja obostrano u čeljustima. U opisanom slučaju zahvaće- na je bila samo lijeva čeljust, nije bilo izgleda pamučne vate na radiogramima, u serumu se nalazila normalna razina al- kalne fosfataze i nije bila uključena ni jedna druga kost (po-

histidine amino acids of the genomic DNA in the osteoblas- tic cells by another amino acid, arginine, resulting in fibrous tissue elaboration by osteoblastic cells in the bone marrow instead of normal bone (7).

The pathogenesis of this disease is poorly understood. Schlumberger suggested that infection or trauma might play a role, although genetic predisposition has also been docu- mented (8).

Fibrous dysplasia involving anterior maxilla with exten- sion into antrum and wall, can present a leonine appearance. Involvement of orbit will cause proptosis. Base of the skull is the most common site of involvement in craniofacial fi- brous dysplasia where sphenoid bone is most commonly af- fected. When mandible is involved, it can cause displace- ment of inferior alveolar canal superiorly. Unerupted teeth are rarely seen in fibrous dysplasia because most cases devel- op after tooth eruption; there can be displacement of erupt- ed teeth and subsequent alterations in occlusion. The most common location for long bones involvement is the neck of the femur. Increased involvement of upper femur results in softening and rounding of the bone, referred to as shepherd's crook deformity (9).

On a plain radiograph, the borders of fibrous dysplasia are known to be ill-defined, with loss of lamina dura around teeth due to replacement of normal bone (10). As the lesion matures, they tend to become more radiopaque with marked homogeneous increase in bone density associated with bone expansion. This is sometimes referred to as a ground-glass ap- pearance, which is more evident on CT. Cystic lesions of ap- preciable size cause thinning and remodeling of the cortex, but they rarely perforate the cortex or produce new perioste- al bone. Although the lesion may cause resorption of the roots of erupted teeth, this is rare. Bone imaging with Tc- 99m MDP revealed a high percentage of increased uptake of radioisotope in the lesions of fibrous dysplasia. On MRI, T1- weighted images reveal fibrous dysplasia as hypointense, and T2-weighted images reveal fibrous dysplasia as either hyper- intense or hypointense (11).

Differential diagnosis of fibrous dysplasia includes: cen- tral ossifying fibroma (COF), osteomyelitis, Paget's disease. COF occurs in the third and fourth decades of life, females affected more than males, whereas fibrous dysplasia is most often discovered in the second decade, males and females equally affected. COF tends to occur in the anterior region of the mandible, whereas fibrous dysplasia occurs in the pos- terior maxilla. Radiographically, a well-defined margin is consistent with COF in contrast to fibrous dysplasia which tends to merge with the surrounding normal bone (12). Dif- ferentiation of these two lesions is important as the treat- ment protocol is quite different for both the lesions. Fibrous dysplasia may also mimic Paget's disease of bone in a patient with fibrous dysplasia occurring later in life (as in the pres- ent case). Paget's disease predominantly occurs in older pop- ulation, showing a thickening of the cortices, cotton wool appearance radiographically and increased levels of serum alkaline phosphatase. The most useful clinical feature to dif- ferentiate fibrous dysplasia from Paget's disease is that the lat- ter tends to occur bilaterally in the jaws. In the present case,

tvrdeno punim pregledom skeleta), što je sve isključilo Page-tovu bolest (10).

Histopatološki nalazi mogu varirati, ovisno o relativnoj zrelosti lezije koja se sastoji od dobro prokrvljenog, stanica-ma bogatoga fibroznog vezivnog tkiva koje sadržava nepravilne trabekule nezrele kosti, što daje izgled kineskoga slova (13).

Terapija FD-a uključuje koštano preoblikovanje na pogodnom mjestu radi poboljšanja estetike i funkcije nakon prestanka rasta. Glavni čimbenici za pristup liječenju su težina simptoma, lokalizacija i dob pacijenta. Lezija može eksponencijalno rasti ako se kirurški ukloni tijekom aktivne faze rasta (10). Uzevši to u obzir, zatim dob pacijenta i samoograničavanje lezije, u opisanom slučaju preporučan je neoperativni pristup i redovite kontrole.

Ako se pacijenta ne može operirati, izbor su biofosfonati. Neki autori predlažu korištenje kalcitonina i operaciju (14). Ukupna prognoza je dobra, a radioterapija je kontraindicirana ne samo zato što je tumor radiorezistentan, nego i zbog moguće maligne transformacije.

only left jaw was involved, no cotton wool appearance on radiographs, normal serum alkaline phosphatase level and no involvement of any other bone (as confirmed by complete skeletal survey) helped in ruling out Page's disease (10).

Histopathological appearance can vary, based upon the relative maturity of the lesion. It consists of well vascularised, cellular fibrous connective tissue containing irregular trabeculae of immature bone, giving a Chinese character appearance (13).

Treatment of fibrous dysplasia usually involves osseous recontouring at the affected site to improve esthetics and function, after the active growth cessation. The main factors that guide the treatment approach are the presence and severity of the symptoms, location and the patient's age. The lesions can show exponential growth if they are surgically altered during their active growth phase (10). Considering this aspect, age factor and the self-limiting nature of the lesion, no treatment was done in this case. However, recall of patient at regular intervals was advised. In patients where surgery cannot be performed, bisphosphonates are used. Some authors suggest the use of calcitonin along with surgery (14). The overall prognosis is good. Radiotherapy is contra-indicated not only because the tumor is radio resistant but also because of increased probability of malignant transformation.

Abstract

Fibrous dysplasia is a benign fibro-osseous disorder, characterized by fibrous connective tissue containing abnormal bone which replaces normal bone. It represents 2 to 5% of all bone tumors and 7% of all benign tumors. Most commonly it affects younger age groups, with a higher prevalence in the maxilla than the mandible. It is a lesion of unknown etiology, uncertain pathogenesis, and diverse histopathology. Fibrous dysplasia can involve multiple bones (polyostotic) or a single bone (monostotic). The lesions of fibrous dysplasia can be surgically recontoured for esthetic or functional purposes once the growth ceases. Here we report a case of craniofacial fibrous dysplasia in an 83-year-old elderly male patient with emphasis on radiographic features.

Received: September 28, 2014

Accepted: January 31, 2015

Address for correspondence

Dr. Suresh K. Sachdeva, M.D.S.,
13/573, Gali No.1, Khanna Colony,
Sirsa-125055, Haryana, India
Ph.:+91 8764419775
drsureshsachdeva7184@gmail.com

Key words

Fibrous Dysplasia of Bone; Bone Neoplasms; Aged; Maxilla

References

- Pinsolle V, Rivel J, Michelet V, Majoufre C, Pinsolle J. Treatment of fibrous dysplasia of the cranio-facial bones. Report of 25 cases. *Ann Chir Plast Esthet.* 1998 Jun;43(3):234-9.
- Lichtenstein L. Polyostotic fibrous dysplasia. *Arch Surg.* 1938;36:874-98.
- Yeow VK, Chan YR. Orthognathic surgery in craniomaxillofacial fibrous dysplasia. *J Craniofac Surg.* 1999 Mar;10(2):155-9.
- Jones WA. Cherubism: A thumbnail sketch of its diagnosis and a conservative method of treatment. *Oral Surg Oral Med Oral Pathol.* 1965 Nov;20(5):648-53.
- Tinoco P, Pereira JCO, Filho RCL, Silva FBC, Ruela KP. Fibrous dysplasia of maxillary sinus. *Int Arch Otorhinolaryngol.* 2009;13:214-17.
- Akintoye SO, Otis LL, Atkinson JC, Brahim J, Kushner H, Robey PG, et al. Analyses of variable panoramic radiographic characteristics of maxillo-mandibular fibrous dysplasia in McCune-Albright syndrome. *Oral Dis.* 2004 Jan;10(1):36-43.
- Sargin H, Gozu H, Bircan R, Sargin M, Avsar M, Ekinci G, et al. A case of McCune-Albright syndrome associated with Gs alpha mutation in the bone tissue. *Endocr J.* 2006 Feb;53(1):35-44.
- Bhaskar SN, Cutright DE. Multiple enostosis: report of 16 cases. *J Oral Surg.* 1968 May;26(5):321-6.
- Nityasri V, Haris PS, Bose T, Balan A. Fibrous dysplasia--a 13-year retrospective radiographic analysis in a south Indian population. *Dentomaxillofac Radiol.* 2011 Jul;40(5):282-9.
- White, SC; Pharoah, MJ -editors. *Oral radiology. Principles and Interpretation.* 5th ed. St. Louis: Mosby Inc; 2004.
- MacDonald-Jankowski D. Fibrous dysplasia in the jaws of a Hong-Kong population: radiographic presentation and systematic review. *Dentomaxillofac Radiol.* 1999 Jul;28(4):195-202.
- Jayachandran S, Sachdeva S. Cemento-ossifying Fibroma of mandible: report of two cases. *J Indian Acad Oral Med Radiol.* 2010;22:53-56.
- Waldron CA. Fibro-osseous lesions of the jaws. *J Oral Maxillofac Surg.* 1985 Apr;43(4):249-62.
- Yasuoka T, Takagi N, Hatakeyama D, Yokoyama K. Fibrous dysplasia in the maxilla: possible mechanism of bone remodeling by calcitonin treatment. *Oral Oncol.* 2003 Apr;39(3):301-5.