

Hypercalciuria in a Child with Acral Peeling Skin Syndrome: A Case Report

Daiva Gorczyca¹, Jolanta Węglowska², Anna Prescha³, Zdzisław Woźniak⁴, Dominika Nesteruk⁵, Katarzyna Wertheim-Tysarowska⁵, Robert Śmigiel⁶

¹3rd Department and Clinic of Paediatrics, Immunology and Rheumatology of Developmental Age, Wrocław Medical University, Wrocław, Poland; ²Department of Dermatology, Regional Specialist Hospital, Wrocław, Poland; ³Department of Food Science and Dietetics, Wrocław Medical University, Wrocław, Poland; ⁴Department of Pathomorphology, Wrocław Medical University, Wrocław, Poland; ⁵Department of Medical Genetics, Institute of Mother and Child, Warsaw, Poland; ⁶Department of Social Paediatrics, Wrocław Medical University, Wrocław, Poland

Corresponding Author:

Daiva Gorczyca, MD
3rd Department and Clinic of Paediatrics,
Immunology and Rheumatology of
Developmental Age
Wrocław Medical University
ul. Koszarowa 5, 51-149
Wrocław
Poland
daiva.gorczyca@umed.wroc.pl

Received: February 20, 2014

Accepted: November 11, 2014

ABSTRACT We present a case of 3-year-old Caucasian boy who developed monthly cyclic attacks of skin peeling of the palms and soles over 1.5 years. The skin peeling was associated with hypercalciuria. No mutation was present in TGM5 and CSTA genes, but the typical clinical picture and the biopsy from flaccid blisters on the feet confirmed the acral peeling skin syndrome (APSS). The possible associations of rare genetic disorders and metabolic conditions in the course of APSS need to be investigated.

KEYWORDS: acral peeling skin syndrome, children, hypercalciuria

INTRODUCTION

The first description of peeling skin syndrome (PSS) in a 28-year-old woman was presented in 1921 by Fox (1). The cases of PSS are divided into two types: generalized PSS and acral PSS (APSS). The acral peeling skin syndrome (APSS) is characterized by a painless spontaneous exfoliation of a subcorneal or intracorneal level of the skin of the dorsal and volar surface of the hands (2). Previous studies reported that there are usually no systemic abnormalities asso-

ciated with this syndrome (2,3). However, recently the possible co-occurrence of PSS with some metabolic abnormalities was reported, such as aminoaciduria, lowered tryptophan levels, elevated serum copper, ceruloplasmin, and abnormal vitamin A metabolism (4,5,6).

Here we present a case report of boy with APSS associated with hypercalciuria.

CASE PRESENTATION

The patient, a 3-year-old Caucasian boy of healthy, unrelated parents was admitted because the parents had been noticing a reoccurrence of the following symptoms every 3-4 weeks for the last 1.5 years: erythema of the palms and soles followed by increased keratosis and then flaking of the epidermis. There was neither an associated pain nor pruritus. The patient presented with excessive sweating and foul smelling of feet. Polyuria with urine turbidity appeared on the same day, prior to skin lesions. Three months earlier, the child was diagnosed in the Clinic of Paediatric Nephrology with idiopathic hypercalciuria (calciuria greater than 4 mg/kg per 24 hours, elevated total calcium/creatinine ratio in a spot urine sample) with normal concentration values of serum calcium, phosphorus, alkaline phosphatase (ALP), parathyroid hormone (PTH), total thyroxine (T4), thyroid-stimulating hormone (TSH), and 1.25-dihydroxyvitamin D. The rest of his past medical and family history was unremarkable.

The physical examination of the boy at admission revealed a good general appearance with normal development. A bilateral and symmetrical peeling of the hands and the feet, worse on the palmar and plantar areas, was noted (Figure 1, Figure 2). The other areas of the skin were soft and pink. The teeth, the hair, and the nails were normal.

Hematological and biochemical investigations found normal values: complete blood count, erythrocyte sedimentation rate (ESR), C-reactive protein (CRP), serum calcium, magnesium, ALP, iron, total iron binding capacity (TIBC), ferritin, T4, TSH, PTH, 1.25-dihydroxyvitamin D, copper, ceruloplasmin, and total immunoglobulin E (IgE). Antinuclear antibodies

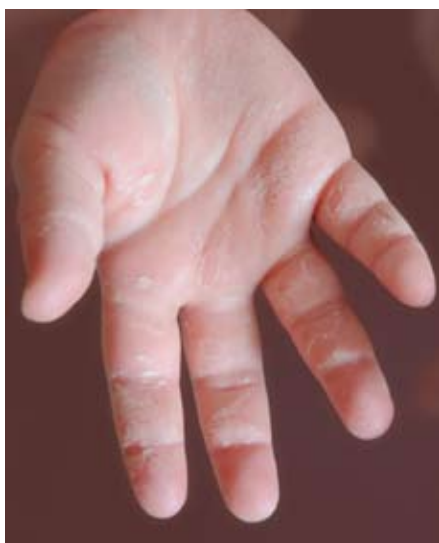

Figure 1. Acral peeling skin syndrome on the hand.

Table 1. Energy and selected nutrient intake of the patient (3-days record)

Energy and nutrients	Intake per day	% RDA*
Energy (kcal)	1320.9±187.1	132.1±18.7**
Water (g)	1622.4±105.4	124.8±8.1**
Total protein (g)	26.2±4.7	187.4±33.6
Fat (g)	42.2±13.1	108.2±33.7**
Total carbohydrates (g)	218.4±40.8	-
Sodium (mg)	1670.4±522.5	222.7±69.7***
Potassium (mg)	1595.6±548.4	66.5±22.9***
Calcium (mg)	243.6±88.2	48.7±17.6***
Phosphorus (mg)	539.6±57.2	117.3±12.4
Magnesium (mg)	173.4±34.9	216.8±43.6
Iron (mg)	5.7±2.4	81.4±34.8
Zinc (mg)	4.19±1.1	139.7±38.0
Cu (mg)	0.65±0.19	215.7±62.6
J (µg)	82.4±15.3	92.2±17.0
Vitamin A (µg)	1499.8±1153.3	374.9±288.3
Vitamin E (mg)	5.8±0.9	97.0±15.6**
Thiamin (mg)	0.50±0.16	100.8±33.0
Riboflavin (mg)	0.59±0.09	117.6±18.7
Niacin (mg)	5.2±2.2	87.8±37.3
Vitamin B6 (mg)	0.79±0.29	157.6±48.3
Vitamin C (mg)	48.3±32.8	120.7±82.0
Folic acid (µg)	126.9±48.7	105.8±40.6**
Vitamin B12 (µg)	1.19±0.77	169.6±109.7**
Vitamin D (µg)	0.91±0.11	18.2±2.1***

*Recommended dietary allowances (RDA) dependent on age and sex

**% of estimated average requirement (EAR) dependent on age and sex

***% of adequate intake (AI)

(ANA) test was negative. Urine test parameters were normal. Microbiological tests from the mouth, nose, and stool were negative. We did not find any abnormalities in the chest X-ray, electrocardiogram (ECG), or abdominal ultrasonography.

On the 3rd day after admission the boy's urine was clouded and the urine sediment showed crystals of calcium oxalate dehydrate. On the same day, peeling from the palms and soles started as well.

Skin biopsy revealed acanthosis and compact orthohyperkeratosis with separation of the stratum corneum from the underlying stratum granulosum and within the stratum corneum. In the dermis, sparse perivascular lymphocytes were present (Figure 3).

DNA analysis of TGM5 and CSTA genes were performed and revealed no mutation in the tested genes

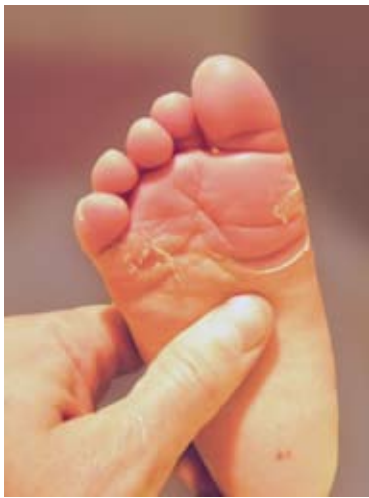

Figure 2. Acral peeling skin syndrome on the feet.

(Sanger sequencing of coding regions and exon-intron boundaries, primers sequences, and PCR conditions available on request).

Dietary intake was assessed during hospitalization using 3-day food records by a trained dietician and analyzed by the Dieta 5.0 computer program (National Food and Nutrition Institute, Poland) (Table 1). The diet analysis showed an excessive intake of protein (187% recommended dietary allowances, RDA), of which 36.4% was animal protein. Moreover, a high intake of sodium, magnesium, copper, and vitamin C was noted (223%, 217%, 216%, and 120% RDA, respectively). The intake of calcium, potassium (49%, 67% adequate intake (AI), respectively), and vitamin D (18% RDA) was insufficient.

Parents were instructed to minimize immersion in water and to use antiperspirants and emollients. Additionally, the parents were instructed to limit sodium and supplement potassium, calcium, and vitamin D in the diet. In result, the parent decided to introduce a lacto-ovo-vegetarian diet for the boy. Two-years follow up revealed normal development and adequate nutritional status of the child. The observations confirmed that after few month of regular application of the lacto-ovo-vegetarian diet, hypercalciuria disappeared and the signs of recurrent peeling were minimized.

DISCUSSION

Peeling skin syndrome (PSS) is a name for a heterogeneous group of dermatoses, which are all characterized by spontaneous, recurrent peeling of the outer layers of epidermis (7). Burns *et al* suggest the main pathological mechanisms in APSS are premature corneodesmolysis or changes in cornified envelope

cross-linking as a consequence of transglutaminase 5-coding genes (TGM5) localized on chromosome 15 (8). However, it has recently been proven that the genetic background of APSS is heterogenic. Mutations in at least one other gene – CSTA (3q21.1) encoding cystatin A, the cysteine proteinase inhibitor involved in epidermis cohesion, may cause APSS (9). Skin lesions in APSS have a predilection for the palms and feet. Casuistic reports point to possible other lesion locations such as the face (10) and skin appendages (5).

The prevalence of APSS in the general population is not known, and according to many authors it is an underrecognised dermatosis. APSS is present all over the world (7), while most of the reported APSS case series in the literature concern Middle Eastern patients (11,12). Some authors point out that the syndrome occurs more commonly in children of related parents (11-13).

Peeling pathognomonic for APSS is limited to the stratum corneum and can be associated with its complete or partial separation (7). The presence of lesions in deeper layers of the epidermis, including the surface area of stratum granulosum, excludes the diagnosis of APSS and makes it crucial to differential diagnosis from epidermolysis bullosa, ichthyosis, and autoimmune bullous dermatosis (2,7).

In the presented case, the diagnosis was made on the basis of the typical clinical picture, typical course of disease, and histopathological test results. Since Sanger sequencing-based molecular analysis of TGM5 and CSTA genes did not reveal any mutations,

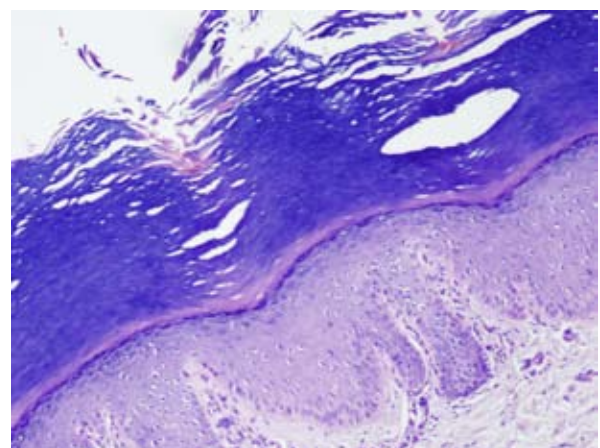


Figure 3. Orthohyperkeratosis, acanthosis, and separation of the stratum corneum from the underlying stratum granulosum, and within the stratum corneum (hematoxylin and eosin staining, 100× magnification).

it is highly probable that the case is a sporadic form of the APSS resulting from mutation in another gene, yet unlinked with the syndrome.

Due to the possible co-occurrence of metabolic disturbances, more diagnostic tests were carried out. In our case we observed that the occurrence of skin lesions is preceded by cloudy urine with hypercalciuria. Since both signs coincide, common pathogenesis should be considered, especially since the calcium metabolism disturbances are observed in skin conditions with abnormal keratinisation (14,15). Hypercalciuria is influenced significantly by diet (16). Analysis of the diet of our patient showed multiple risk factors that escalate hypercalciuria: insufficient intake of calcium and potassium and high intake of sodium, animal protein, and vitamin C. The use of a vegetarian diet and thereby the replacement of animal protein by plant, especially soy protein, and increase in the dietary potassium/sodium ratio resulted in improvement of hypercalciuria in our patient (17).

The proposed treatments of APSS encompass emollients, topical and systemic corticosteroids, methotrexate, systemic retinoids, and ultraviolet B (UVB) light treatment (4,11), but none of these methods proved satisfactory.

As far as we know, it is possible that we reported the first case of APSS associated with hypercalciuria.

CONSENT

Written informed consent was obtained from the mother of the patient for publication of this report and images.

References

1. Fox H. Skin shedding (keratolysis exfoliativa congenital): report of a case. *Arch Dermatol* 1921;3:202.
2. Hashimoto K, Hamzavi I, Tanaka K, Shwayder T. Acral peeling skin syndrome. *J Am Acad Dermatol* 2000;43:1112-9.
3. Aras N, Sutman K, Tastan HB, Baykal K, Can C. Peeling skin syndrome. *J Am Acad Dermatol* 1994;30:135-6.
4. Levy SB, Goldsmith LA. The peeling skin syndrome. *J Am Acad Dermatol* 1982;7:606-13.
5. Mevorah B, Orion E, de Viragh P, Bergman R, Gat A, Legume C, *et al.* Peeling skin syndrome with hair changes. *Dermatology* 1998;197:373-6.
6. Inamadar AC, Palit A. Peeling skin syndrome with aminoaciduria. *Pediatr Dermatol* 2005;22:314-6.
7. Burns T, Breathnach S, Cox N, Christopher G. *Rook's Textbook of Dermatology, Seventh Edition.* Oxford: Blackwell Publishing, Inc., 2004.
8. Pigors M, Kiritsi D, Cobzaru C, Schwieger-Briel A, Suárez J, Faletra F, *et al.* TGM5 mutations impact epidermal differentiation in acral peeling skin syndrome. *J Invest Dermatol* 2012;132:2422-9.
9. Kronic AL, Stone KL, Simpson MA, McGrath JA. Acral peeling skin syndrome resulting from a homozygous nonsense mutation in the CSTA gene encoding cystatin A. *Pediatr Dermatol* 2013;30:e87-8.
10. Janjua SA, Hussain I, Khachemoune A. Facial peeling skin syndrome: a case report and brief review. *Int J Dermatol* 2007;46:287-9.
11. Wakade O, Adams B, Shwayder T. Acral peeling skin syndrome: a case of two brothers. *Pediatr Dermatol* 2009;26:328-30.
12. Köse O, Safali M, Koç E, Arca E, Açıkgöz G, Özmen I, *et al.* Peeling skin diseases: 21 cases from Turkey and a review of the literature. *J Eur Acad Dermatol Venereol* 2012;26:844-8.
13. van der Velden JJ, Jonkman MF, McLean WH, Hamm H, Steijlen PM, van Steensel MA, *et al.* A recurrent mutation in the TGM5 gene in European patients with acral peeling skin syndrome. *J Dermatol Sci* 2012;65:74-6.
14. Assadi FK, Scott CI Jr, McKay CP, Nicholson L, Cafone M, Hopp L, *et al.* Hypercalciuria and urolithiasis in a case of Costello syndrome. *Pediatr Nephrol* 1999;13:57-9.
15. Numaga-Tomita T, Putney JW. Role of STIM1 and Orai1-mediated calcium entry in Ca²⁺-induced epidermal keratinocyte differentiation. *J Cell Sci* 2013;126:605-12.
16. Srivastava T, Schwaderer A. Diagnosis and management of hypercalciuria in children. *Curr Opin Pediatr* 2009;21:214-9.
17. Amit M. Vegetarian diets in children and adolescents. *Paediatr Child Health* 2010;15:303-14.