



Transfer of tibial tubercle (TT) (Fulkerson osteotomy)

BRANKO UHODA

Special Hospital for Orthopedics
Zadarska 62, 2310 Biograd na moru
E-mail: ortrav@email.t-com.h

INTRODUCTION

Located in the front of knee, it serves several functions the patella has always been an intriguing structure. As the largest sesamoid bone in the body, this structure, along with the supporting extensor mechanism, has been the source of chronic pain'

The human knee dates back 320 million years in the evolutionary scale to Eryops, the common ancestor of reptiles, birds, and mammals. The Eryops knee was bicondylar, with a femorofibular articulation, cruciate ligaments and asymmetric collateral ligaments. The patella was not yet present.

As evolution continued, the fibula migrated distally, away from the joint line. The bicondylar femur rotated internally and developed a medial offset, bringing the joint progression closer to the midline (1, 2).

The osseous patella developed separately in birds, some reptiles and in mammals about 70 million years ago. This was a late development compared with the cruciates or the condylar surfaces. The anterior femoral articular surface extended proximally beneath the patella to form the sulcus and completed the development of the patelofemoral joint.

FUNCTIONS OF THE PATELLA

The main biomechanical function of the patella is to improve the quadriceps efficiency by increasing the lever arm of the extensor mech-

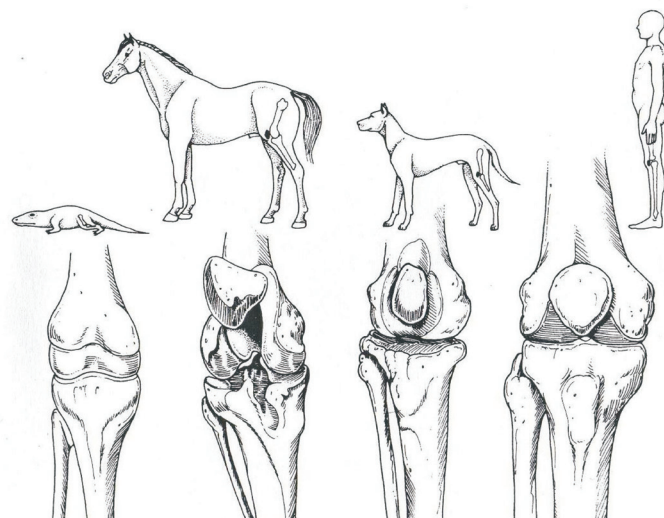


Figure 1. The development of the knee from Eryops to humans.

anism. The patella displaces the patellar tendon away from the femorotibial contact point throughout range of motion, therefore increasing the patellar tendon moment arm (1-3). The patella is necessary to centralize the divergent forces from the four heads of the quadriceps, and to transmit tension around the femur, in a frictionless way, to the patellar tendon and tibial tuberosity.

The hyaline articular cartilage provides an insensitive thick, avascular tissue that is specifically adapted to bearing high compressive loads (2, 3).

The patella also functions as a bony shield, not only for the trochlea, but also for the distal femoral condyles with the knee in flexion. The patella plays also an important role in the cosmetics of the knee.

PATELLAR INSTABILITY

Patellar instability is a common and complex problem that is both difficult to characterize and difficult to treat. There are many underlying predisposing factors that may lead to patellar instability. These factors include abnormalities in muscle origin and insertion and the dynamic forces created by them as well as significant anatomic malalignment of the femur, tibia, or patella. Additionally, deficiencies of passive restraints (e.g., medial patellofemoral ligament), patella alta, trochlear dysplasia, soft tissue dysplasia, abnormal foot/ankle alignment, genu valgum, and excessive lateral tibial torsion are thought to contribute to patellar instability. Due to its complexity, over 100 surgical methods have been described to treat this condition (6, 7, 8). It is clear that no single surgical option is appropriate for every patient with patellar instability and treatment decisions must be made based on the underlying pathology.

ANTEROMEDIAL TIBIAL TUBERCLE OSTEOTOMY

The tibial tubercle is the most distal anchor of the extensor mechanism and can serve as tool in altering patellofemoral (PF) mechanics.

Osteotomies of the tibial tubercle are a useful method to treat a variety of PF conditions by allowing coronal, axial, and sagittal plane adjustments of the patellofemoral articulation which redistribute patellar contract pressures and improve tracking.

Fulkerson designed a tubercle osteotomy known as the anteromedialization (AMZ) technique to address PF pain in conjunction with patellar maltracking. The oblique nature of the Fulkerson osteotomy allows for simultaneous anteriorization and medialization of the tibial tubercle. By varying the angle of the osteotomy, the tubercle can be biased to a more anterior or more medial position.

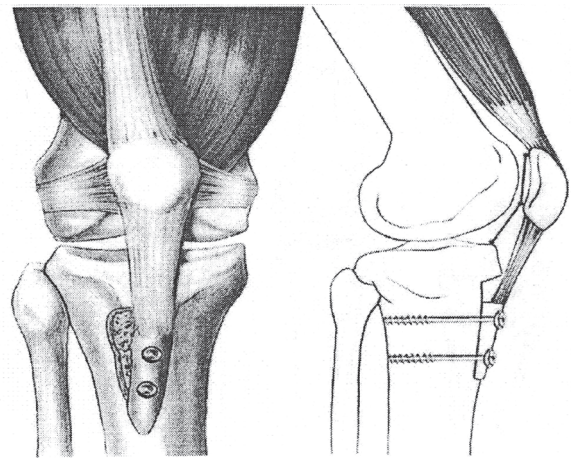


Figure 2. Medial and distal tibial tubercle transfer. This procedure is used to correct increased TT-TG distance and patella alta.

The tibial tuberosity to trochlear groove (TT-TG) distance, popularized by Dejour *et al.* (8). Serves as an objective measure of tuberosity position, has helped quantify abnormal tuberosity position and enhanced appropriate candidate identification for all tuberosity osteotomies including the AMZ. This becomes important because patellar contract pressures are very sensitive to distal realignment (6, 7, 8).

INDICATIONS

Indications for AMZ are primarily based upon mechanical and chondral pathologies specific to each individual knee.

Malalignment is a term that has different meanings to different experts.

A comprehensive review by Post *et al.* (11, 12, 13) demonstrated that the “Q” angle was inadequate to use as a measure of malalignment of the tibial tuberosity.

Using the objectively measured TT-TG, asymptomatic patients have distances averaging 13 mm and those with instability symptoms have average measurements of over 15 mm (9, 10, 11). A panel of patellofemoral experts agreed that TT-Tg distances of over 20 mm were definitely abnormal and would be potential candidates for moving the tibial tubercle (8, 9, 10). Patients with isolated chondrosis of the distal or lateral patella, who have excessive lateral patellar tilt and/or subluxation associated with an increased TT-TG distance and minimal trochlear chondrosis are optimal AMZ candidates based on a retrospective review of AMZ outcomes by Pidioriano (8).

It has been argued that rotational tuberosity abnormalities associated with subjective instability and pain may be sufficiently treated with straight medialization or

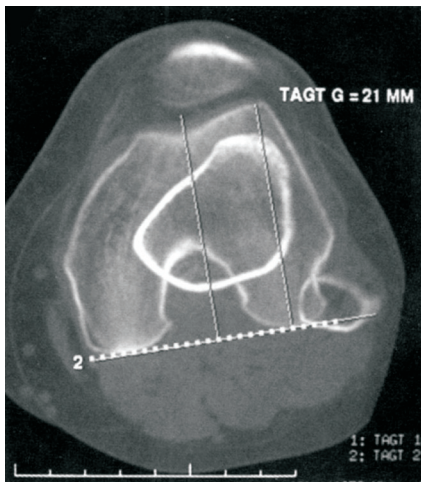


Figure 3. CT image of TT-TG distance.

derotation of the tibial tubercle (13), although Pritsch *et al.* (12, 13) found 80% of 66 patients undergoing tubercle transfer for patellar instability and pain associated with maltracking required anteriorization based on intraoperative examination. Patient who are undergoing PF cartilage restorative procedures have been shown to benefit from a combined AMZ procedure (9, 10, 11, 12), were optimization of the biomechanical environment and decreased stress across the restored cartilage is required.

In patients undergoing medial patellofemoral ligament, MPFL, repair or reconstruction for recurrent lateral patella instability, AMZ may be indicated only in the setting of a significantly increased TT-TG distance. There is no randomized study of AMZ plus MPFL surgery versus MPFL surgery alone published.

Therefore indications for anteromedialization AMZ are:

Lateral or distal patella chondrosis with an increased TT-TG distance and excessive lateral tilt / subluxation, and the absence of trochlea chondrosis.

METHODOLOGY

There were 173 knees (19 bilateral) in this series that had a history of recurrent lateral patellar dislocation. Patient age was 18 – 82 with an average age of 50, over 50 years 83 (percent 48).

All of the patients in this study were indicated for treatment based on a clinical history of recurrent dislocations and correlating examination findings. They all demonstrated excessive lateral patellofemoral laxity and a positive apprehension sign. All were also found to have signs of lateral maltracking including combinations of lateralization of the patella on Merchant view, abnormal Q-angle, and the apprehension test with active extension.

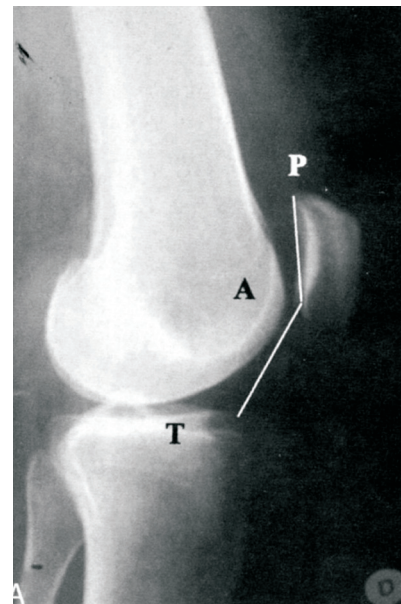


Figure 4. Radiology image of patellar height (Caton-Deschamps index).

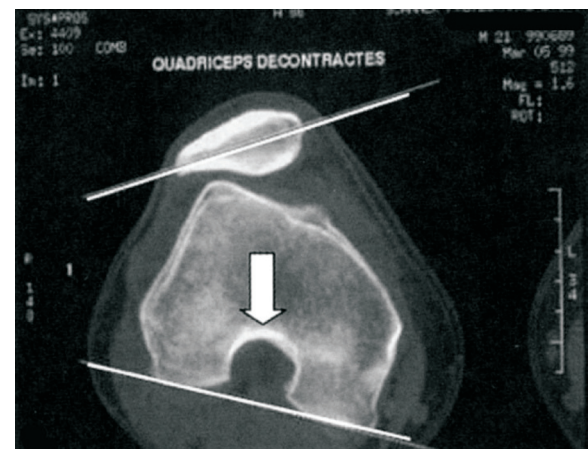


Figure 5. CT-Radiology image of patellar tilt.

Patients who received reconstruction of the medial patellofemoral ligament (MPFL) or lateral patellofemoral ligament (LPFL) were eliminated from this study.

Distribution of patients according to sex, age, and type of surgery

Patients	Number	Percent
MALES	83	48
FEMALES	90	52
TOTAL	173	100
BILLATERAL	19	11
OVER 50 YEARS	83	48

RESULTS

Result (post.op.grading – Ficat, Bandi) follow up 3-144 months	Number of patients	Percent
EXCELLENT	163	94
GOOD	10	6
FAIR / /		
POOR / /		
TOTAL	173	100

The 3 principal factors are following (if it possible!):

1. TT – TG distance of more than 20 mm on CT images
2. patellar height (Caton-Deschamps index) of more than 1.2 on the lateral radiograph
3. patellar tilt of more than 20 degrees on CT images

CONCLUSIONS

Multiple case series has reported of the AMZ procedures. Despite the heterogeneity in outcome measurements, results demonstrate high percentage of excellent good results and improvements in objective, subjective, and functional measures. Attention to details related to surgical planning and properly managing patient expectations is most likely to lead to good or excellent results.

REFERENCES

1. DYE S F 1987 An evolutionary perspective of the knee. *J Bone Joint Surg Am* 69A: 976–983.
2. GARDNER E, O'RAHLILLY R 1968 The early development of the knee joint in staged human embryos. *J Anat* 102: 289
3. FULKERSON J P, HUNGERFORD D S 1990 Biomechanics of the patellofemoral joint, in *Disorders of the patellofemoral joint*. The Williams & Wilkins Co, Baltimore, p 25–41
4. AGLIETTI P, BUZZI R, INSALL J N 1993 Disorders of the patellofemoral joint, in Insall JN (ed): *Surgery of the Knee*. Churchill Livingstone, New York, p 246–251
5. HUNGERFORD D S, BARRY N 1979 Biomechanics of the patellofemoral joint. *Clin Orthop* 144: 9–15
6. BUUCK D, FULKERSON J 2000 Anteromedialization of the tibial tubercle: A4-to 12-year follow-up. *Operative Techniques in Sports Medicine* (8): 131–137
7. FULKERSON J P 1983 Anteromedialization of the tibial tuberosity for patellofemoral malalignment. *Clin Orthop Relat Res* (177): 176–81 (PubMed)
8. PIDORIANO A J, WEINSTEIN R N, BUUCK D A, FULKERSON J P 1997 Correlation of patellar articular lesions with results from anteromedial tibial tubercle transfer. *Am J Sports Med* 25(4): 533–7(PubMed)
9. POST W R, FULKERSON J P 1992 Distal realignment of the patellofemoral joint. Indications, effects, results, and recommendations. *Orthop Clin North Am* 23(4): 631–43 (PubMed)
10. BOLLIER M, FULKERSON J P 2011 The role trochlear dysplasia in patellofemoral instability. *J Am Acad Orthop Surg* 19: 8–16
11. NTAGIPOULOS P G, DEJOUR D 2014 Current concepts on trochleoplasty procedures for the surgical treatment of trochlear dysplasia. *Knee Surg Sports Traumatol Arthrosc* 22: 2531–9
12. DEJOUR D, LE COULTRE B 2007 Osteotomies in patellofemoral instabilities. *Sports medicine and arthroscopy review* 15: 39–46
13. DEJOUR D, FERRUA P, NTAGIPOULOS P G, RADIER C, HULET C, REMY F *et al.* 2013 The introduction of a new MRI indeks to evaluate sagittal patellofemoral engagement. *Orthop Traumatol Surg Res* 99 (8Suppl): S391–8
14. BANDI W 1972 Chondromalatio patellae und femoropatellare Arthrose. *Helv chr Acta (Suppl.)* 11
15. FICAT R P, HUNGERFORD D S 1977 Disorders of the Patellofemoral joint. Williams and Wilkins, Baltimore.
16. PEĆINA M, MIHELČIĆ R 1981 Indikacije i operativna tehnika pri ventralizaciji patele, Zbornik XII. ortopedsko-traumatoloških dana, Novi Sad, str. 563–567
17. PEĆINA M, MIHELČIĆ R 1980 Ventralizacija patele kao sekundarno-preventivni zahvat u liječenju artroze koljena. Zbornik radova VI. kongresa ortopeda Mediterana i Bliskog istoka, Split, str. 123–128