

IMPLANT STABILITY COMPARISON OF IMMEDIATE AND DELAYED MAXILLARY IMPLANT PLACEMENT BY USE OF RESONANCE FREQUENCY ANALYSIS – A CLINICAL STUDY

Marko Granić¹, Davor Katanec¹, Vanja Vučićević Boras², Mato Sušić¹, Ivona Bago Jurič³
and Dragana Gabrić¹

¹Department of Oral Surgery, ²Department of Oral Medicine, ³Department of Endodontics and Restorative Dentistry, School of Dental Medicine, University of Zagreb, Zagreb, Croatia

SUMMARY – The purpose of this study was to objectively evaluate the stability of dental implants by use of resonance frequency analysis (RFA). In this study, 60 Nobel Replace Tapered Groovy implants were placed in the premolar region of the maxilla in 60 patients. Thirty implants were placed immediately after tooth extraction and 30 implants were placed in healed bone sites. Implant stability quotient (ISQ) was obtained by use of the Osstell Mentor device and was recorded at the time of implant placement (T1) and 20 weeks after placement, at the time of implant loading (T2). All implants were not functionally loaded during the follow up period. Data were analyzed using simple linear regression. No implant failures were reported in the 6-month follow up period. The mean ISQ value for immediate implant placement was 61.43 at T1 and 66.23 at T2. The implants placed in healed bone showed higher ISQ values compared to the immediately placed implants (mean ISQ value was 64.17 at T1 and 68.83 at T2). Differences in the mean ISQ values were statistically significant ($p < 0.001$). After the completed period of osseointegration, the mean ISQ value was 4.8 for immediately placed implants compared to 4.67 for implants placed in delayed sites.

Key words: *Dental implants, stability; Resonance frequency analysis (RFA)*

Introduction

The concept of immediate implant placement following tooth extraction has been studied extensively since its introduction in 1976 by Schulte and Heimke¹. Like all surgical techniques, immediate implant placement has its benefits and risks. Reduction in the number of surgical interventions, shortened treatment time, preservation of bone around the extraction socket, especially preservation of buccal bone, easier and more ideal orientation for implant placement, and

soft tissue aesthetics have been claimed as the potential advantages of this treatment approach²⁻⁷. The main drawbacks of immediate implant placement are lower primary stability of implants compared to implants placed at healed sites and the lack of soft tissue healing with frequent flap dehiscence over extraction sites⁸. The prerequisites for immediate implant placement include absence of active infections, intact buccal bone, and narrow alveolar bone to ensure adequate mechanical retention. Due to decreased primary stability following immediate implant placement, several authors have examined the validity of long-term success of these implants when compared to implant placed in healed sites^{3,9,10}. Primary stability is achieved through direct bone implant contact and it is defined as implant stability at the time of implant placement.

Correspondence to: *Asst. Prof. Dragana Gabrić, DMD, PhD*, Department of Oral Surgery, School of Dental Medicine, University of Zagreb, Gundulićeva 5, HR-10000 Zagreb, Croatia
E-mail: dgabric@sfzg.hr

Received February 9, 2015, accepted March 6, 2015

Primary stability has been applied as an indicator of future osseointegration and thus long-term success of implant therapy¹¹. If primary stability is not sufficient, the healing process will be disrupted and osseointegration will not occur, which will lead to implant failure¹¹. Primary stability of dental implants is most typically evaluated by percussion¹, reverse torque test⁴, radiograph analysis¹¹, Periotest (Siemens AG, Modautal, Germany)¹¹, Dental Fine Tester (Kyocera, Kyoto, Japan)^{11,15} and resonance frequency analysis (RFA)^{12,13,15}. For more than a decade, RFA has been used as a noninvasive, reliable, easily predictable and objective method for measurement of implant stability^{12,13}. RFA has been widely used to determine loading protocols or assess changes in implant stability over time^{14,15}.

The aim of this study was to compare the stability of 30 dental implants placed immediately after tooth extraction and 30 implants placed at healed sites using RFA.

Materials and Methods

All patients voluntarily agreed and gave their written consent to participate in the study, which was approved by Ethics Committee of the School of Dental Medicine, Zagreb, Croatia (201301). Inclusion criteria for this clinical study were subjects older than 20 years (completed bone growth of jaws), partially edentulous in premolar region, having at least 2 mm of attached keratinized gingiva on the buccal and palatal aspects of the bone, ready and ability to comply with pre- and postoperative diagnostic and clinical evaluation required for this study. Exclusion criteria were all local and general medical conditions known to interfere with bone healing (uncontrolled diabetes, detailed medical history of no drug therapy, radiation therapy

or chemotherapy), severe osteoporosis, pregnancy, patients with poor oral hygiene, lack of cooperation and severe periodontal disease.

In this retrospective study, data on 60 patients (age range 22-65, mean age 44.25) were collected and evaluated. In each patient, one Nobel Replace Tapered Groovy Implant (Nobel Biocare, Gothenburg, Sweden) was inserted in the premolar region of the maxilla. All implants were placed by the same experienced surgeon. The subjects were divided into two groups, depending on the indication. First group of patients, with strong clinical indication for immediate implant placement, had 30 implants placed immediately after tooth extraction. Second group of patients had 30 implants placed at the healed bone site of the premolar maxillary area, four months after tooth extraction. All implants were placed following the concept of two stages. After implant placement, healing period was 20 weeks and then implants were planned to be functionally loaded with a single metal-ceramic crown.

All study patients received the same surgical and follow up post-surgical protocol: patients were prescribed amoxicillin (500 mg every 8 hours) starting 1 day before surgery, which they continued to use for the next 7 days. Clindamycin (300 mg every 8 hours) was prescribed only for improved penicillin-sensitive patients. After surgery, patients received suitable analgesics and 0.12% chlorhexidine gluconate oral rinse until suture removal 1 week after surgery. Follow up visits were scheduled at 1, 2, 6, 12 and 20 weeks after surgery. Radiographic images were taken immediately after implant placement and the latest 20 weeks after surgery.

In this study, Osstell Mentor (Integration Diagnostics AB, Goteborg, Sweden) was used for recording Implant Stability Quotient (ISQ) measurement at

Table 1. Differences in the mean implant stability quotient (ISQ) values between two study groups

	Paired differences					t	df	Sig. (2-tailed)
	Mean	Standard deviation	Standard error of mean	95% Confidence interval of the difference				
				Lower	Upper			
Immediate	4.80	1.30	0.24	4.32	5.28	20.27	29	0.000
Healed site	4.67	0.88	0.16	4.34	5.00	28.91	29	0.000

the time of implant placement (T1) and before loading (T2) after 20 weeks of dental implant placement in both study groups.

Stability of the implants was measured based on the detection of vibration with SmartPeg (Integration Diagnostics AB, Goteborg, Sweden), the 1 cm high commercially manufactured resonance frequency probe that was screwed to the implant. SmartPeg has a magnetic material in the upper part, which forms a magnetic field with the Osstell Mentor and its values are expressed as ISQ, which may range from 1 to 100. ISQ values are derived from stiffness (N/μm) of the implant-bone connection and calibration parameters of the SmartPeg. A high ISQ value indicates high stability, whereas low value indicates low implant stability. The manufacturer's guidelines were followed on SmartPeg placement: interposition of no soft tissue, transducer tightening at 5-8 Ncm manually with specific screwdriver, none of the transducer parts in contact with neighboring teeth, and upon completion of each measurement, the transducer was completely removed from the implant. For more precise measurements, SmartPeg was replaced after every 10 measurements. Four different measurements were taken for each implant and averaged to yield the mean ISQ value.

Implant survival was evaluated according to Misch criteria (2008)¹⁶: implant remained in patient's mouth, no pain on function, no mobility, no history of peri-implantitis, and less than 1 mm of crestal radiographic bone loss.

The IBM SPSS Statistics 18 program was used on statistical analysis. A paired sample t-test was used

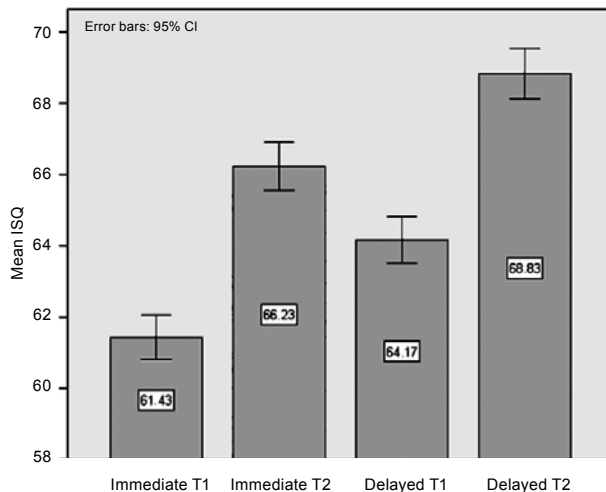


Fig. 1. Comparison of initial and final mean implant stability quotient (ISQ) values in immediate and delayed maxillary implant placement.

to determine whether ISQ values were statistically different between the two groups. The Kolmogorov-Smirnov test was used to determine distribution of variables.

Results

No implant failures were reported during the 6-month follow up. Results are presented in Figures 1 and 2. The mean ISQ value for immediate implant placement was 61.43 (standard deviation, SD 1.65; range ±7) at T1 and 66.23 (SD 1.81; range ±6) at T2. Implants placed at healed sites showed higher ISQ values compared to immediate implant placement.

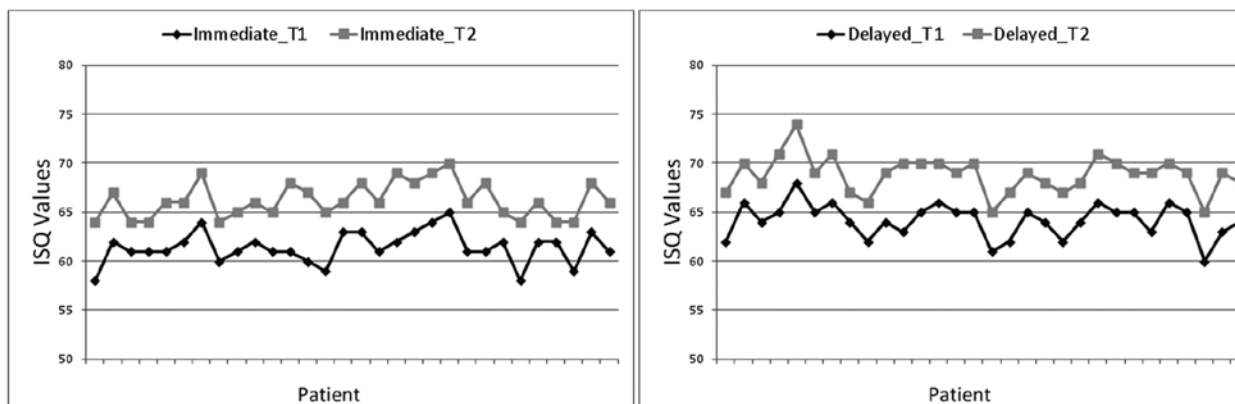


Fig. 2. Comparison of initial and final implant stability quotient (ISQ) values in each patient from both study groups.

These implants had mean ISQ of 64.17 (SD 1.74; range ± 8) at T1 and 68.83 (SD 1.89; range ± 9) at T2. These differences in the mean ISQ values were statistically significant ($p < 0.001$), as shown in Table 1. At 20-week follow up, the mean ISQ raised to 4.8 for immediate implant placement as compared to 4.67 for delayed sites.

Discussion

Primary stability is one of the crucial factors in determining long-term success of implant therapy. Lower primary stability is considered to be the major cause of implant failure, as well as inflammation, bone loss, traumatic injuries and biomechanical overloading¹⁷. As mentioned earlier, the main drawback of immediate implant placement compared to implants placed at healed sites is lower primary stability. Careful planning and case selection are needed to ensure implant success. Many authors report that quantity and quality of bone, implant design and surface treatment have a significant influence on increasing implant stability^{4,11,18}. Valente *et al.*¹⁹ showed that better primary stability was achieved using tapered implants in comparison to the cylindrically shaped implants. In this study, we used tapered shape of implants to enhance primary stability. In addition, primary stability is the basis for determination of loading protocols²⁰. Many studies have shown that implants whose ISQ values exceed 65 before functional loading have 99% survival rate and ISQ values of 57 to 82 have been used as threshold values for implant success^{11,21-24}. ISQ values less than 45 indicate failure of the implant²⁵. The ISQ values recorded in our study at T2 (66.23 for immediate compared to 68.83 for healed sites) support previous studies on the recommended ISQ values before functional loading and therefore long-term implant success. Turkyilmaz and McGlumphy²⁶ in their study showed that 170 successful implants had a mean ISQ value of 62.6 compared to 20 failed implants with the mean ISQ value of 54.9. In this study, all implants were functionally loaded 20 weeks after implant placement. Kim *et al.*²⁷ compared immediate loading with delayed loading in posterior maxilla following implant placement in healed sites, and their mean ISQ value for delayed implant loading was 66.2 compared to the value of 64.17 in our study. The same

authors²⁷ report on three implant failures, all seen in implants that were immediately loaded. Rowan *et al.*²⁸ also compared ISQ values between 41 implants placed immediately and 96 implants placed at healed site. All implants were also functionally loaded 20 weeks after initial implant placement. Their results showed the mean ISQ value of 68.56 at T1 and 71.23 at T2 for immediate placement, as well as the mean ISQ value of 70.14 at T1 and 77.31 at T2 for delayed placement. Compared to the mean ISQ in the present study, their values were higher because they evaluated both jaws, where the mean ISQ values are usually higher in the mandible. Although numerous reports in the literature^{19,21,25,28} indicate that successfully integrated implants show an increase of ISQ values and that RFA is suitable for prediction of implant success/failure, the results by Kim *et al.*²⁷ indicated that RFA measurement taken at the time of implant placement in posterior maxilla remained questionable to predict the risk of implant failure. In their study²⁷, 46 implants placed in the posterior region of the maxilla were evaluated and they report three implant failures. The mean baseline ISQ values for these implants were 62.7, 66 and 72, respectively, and all failures occurred within the first 6 weeks after implant placement and they were immediately non-functionally loaded with single unit restorations. These results are not comparable to the results of our study due to the posterior implant site in the upper jaw, where all implants in the present study were placed in the premolar area of the upper jaw, and the protocol of delayed implant loading was followed for each implant in both study groups.

Although the mean ISQ value of immediately placed implants was lower than the mean ISQ value of implants placed at the healed sites, all ISQ values raised to a clinically successful value throughout the osseointegration process, before implant loading. It seems that there are no significant differences between the stability of implants placed immediately compared to those placed at the healed sites. As there were no implant failures in the follow up period, results of this study support the concept of immediate implant placement following tooth extraction under favorable conditions with delayed implant loading. Future studies including more patients and longer follow up are needed to assess the long-term success of immediately placed implants.

References

1. Schulte W, Heimke G. The Tübinger immediate implant. *Quintessenz*. 1976;27(6):17-23. (in German)
2. Chen ST, Wilson TG, Hämmerle CH. Immediate or early placement of implants following tooth extraction: review of biologic basis, clinical procedures, and outcomes. *Int J Oral Maxillofac Implants*. 2004;19 Suppl:12-25.
3. Lazzara RJ. Immediate implant placement into extraction sites: surgical and restorative advantages. *Int J Periodontics Restorative Dent*. 1989;9(5):332-43.
4. Watzek G, Haider R, Mendsdorff-Pouilly N, Haas R. Immediate and delayed implantation for complete restoration of the jaw following extraction of all residual teeth: a retrospective study comparing different types of serial immediate implantation. *Int J Oral Maxillofac Implants*. 1995;10(5):561-7.
5. Van der Weijden F, Dell'acqua F, Slot DE. Alveolar bone dimensional changes of post-extraction sockets in humans: a systematic review. *J Clin Periodontol*. 2009;36(12):1048-58.
6. SCHULTZ AJ. Guided tissue regeneration (GTR) of non-submerged implants in immediate extraction sites. *Pract Periodontics Aesthet Dent*. 1993;5(2):59-65.
7. Werbitt MJ, Goldberg PV, Full CTF. The immediate implant: bone preservation and bone regeneration. *Int J Periodontics Restorative Dent*. 1992;12(3):206-17.
8. Wilson TG, Weber HP. Classification of and therapy for areas of deficient bony housing prior to dental implant placement. *Int J Periodontics Restorative Dent*. 1993;13(5):451-9.
9. Paolantonio M, Dolci M, Scarano A. Immediate implantation in fresh extraction sockets. A controlled clinical and histological study in man. *J Periodontol*. 2001;72(11):1560-71.
10. Rosenquist B, Grenthe B. Immediate placement of implants into extraction sockets: implant survival. *Int J Oral Maxillofac Implants*. 1996;11(2):205-9.
11. Gapski R, Wang HL, Mascarenhas P, Lang NP. Critical review of immediate implant loading. *Clin Oral Implants Res*. 2003;14(5):515-27.
12. O'Sullivan D, Sennerby L, Meredith M. Measurements comparing the initial stability of five designs of dental implants: a human cadaver study. *Clin Implant Dent Relat Res*. 2000;2(2):85-92.
13. Koh RU, Rudek I, Wang HL. Immediate implant placement: positives and negatives. *Implant Dent*. 2010;19(2):98-108.
14. Friberg B, Sennerby L, Meredith M, Lekholm U. A comparison between cutting torque and resonance frequency measurements of maxillary implants: a 20-month clinical study. *Int J Oral Maxillofac Surg*. 1999;28(4):297-303.
15. Javed F, Romanos GE. The role of primary stability for successful immediate loading of dental implants. A literature review. *J Dent*. 2010;38(8):612-20.
16. Misch C, Perel ML, Wang H, Sammartino G, Galindo-Moreno P, Trisi P, *et al.* Implant success, survival, and failure: International Congress of Oral Implantologists (ICOI) Pisa Consensus Conference. *Implant Dent*. 2008;17(1):5-15.
17. Tonetti MS, Schmid J. Pathogenesis of implant failures. *Periodontol* 2000. 1994;4:127-38.
18. Glauser R, Sennerby L, Meredith N, Rée A, Lundgren A, Gottlow J, *et al.* eonaf implants subjected to immediate or early functional occlusal loading. Successful *vs.* failing implants. *Clin Oral Implants Res*. 2004;15(4):428-34.
19. Valente ML, De Castro DT, Shimano AC, Lepri CP, Dos Reis AC. Analysis of the influence of implant shape on primary stability using the correlation of multiple methods. *Clin Oral Investig*. Epub 2015 Feb 14.
20. Seong WJ, Holte JE, Holtan JR, Olin PS, Hodges JS, Ko CC. Initial stability measurement of dental implants placed in different anatomical regions of fresh human cadaver jawbone. *J Prosthet Dent*. 2008;99(6):425-34.
21. Bornstein MM, Hart CN, Halbritter SA, Morton D, Buser D. Early loading of non-submerged titanium implants with a chemically modified sand-blasted and acid-etched surface: 6-month results of a prospective case series study in the posterior mandible focusing on peri-implant crestal bone changes and implant stability quotient (ISQ) values. *Clin Implant Dent Relat Res*. 2009;11(4):338-47.
22. Ostman PO, Hellman M, Sennerby L. Direct implant loading in the edentulous maxilla using a bone density-adapted surgical protocol and primary implant stability criteria for inclusion. *Clin Implant Dent Relat Res*. 2005;7 Suppl 1:S60-9.
23. Sennerby L, Meredith N. Implant stability measurements using resonance frequency analysis: biological and biomechanical aspects and clinical implications. *Periodontol* 2000. 2008;47(1):51-66.
24. Meredith N, Shagaldi F, Alleyne D, Sennerby L, Cawley P. The application of resonance frequency measurements to study the stability of titanium implants during healing in the rabbit tibia. *Clin Oral Implants Res*. 1997;8(3):234-43.
25. Sennerby L, Roos J. Surgical determinants of clinical success of osseointegrated oral implants: a review of the literature. *Int J Prosthodont*. 1998;11(5):408-20.
26. Turkyilmaz I, McGlumphy EA. Influence of bone density on implant stability parameters and implant success: a retrospective clinical study. *BMC Oral Health*. 2008;8:32. doi: 10.1186/1472-6831-8-32.
27. Kim SL, Ribeiro ALVL, Atlas AM, Saleh N, Royal J, Radvar M, *et al.* Resonance frequency analysis as a predictor of early implant failure in the partially edentulous posterior maxilla following immediate non-functional loading or delayed loading with single unit restorations. *Clin Oral Implants Res*. 2015;26(2):183-90.
28. Rowan M, Lee D, Pi-Anfruns J, Shiffler P, Aghaloo T, Moy PK. Mechanical *versus* biological stability of immediate and delayed implant placement using resonance frequency analysis. *J Oral Maxillofac Surg*. 2015;73(2):253-7.

Sažetak

USPOREDBA STABILNOSTI DENTALNIH IMPLANTATA UGRAĐENIH IMEDIJATNOM I ODGOĐENOM TEHNIKOM U GORNJOJ ČELJUSTI ANALIZOM REZONANTNE FREKVENCije – KLINIČKA STUDIJA

M. Granić, D. Katanec, V. Vučićević Boras, M. Sušić, I. Bago Jurić i D. Gabrić

Svrha ovoga rada bila je objektivno procijeniti stabilnost dentalnih implantata ugrađenih imedijatno nakon ekstrakcije zuba u odnosu na odgođenu tehniku ugradnje u formiranu alveolarnu kost pomoću analize rezonantne frekvencije. Praćeno je 60 pacijenata kojima je gubitak jednog zuba u premolarnoj regiji gornje čeljusti nadomješten ugradnjom dentalnog implantata Nobel Replace Tapered Groovy. Pacijenti su bili podijeljeni u dvije skupine: prvu skupinu činilo je 30 pacijenata odnosno 30 implantata ugrađenih imedijatno nakon ekstrakcije zuba, dok je drugu skupinu činilo 30 implantata ugrađenih odgođenom tehnikom u formiranu alveolarnu kost. Mjerenje stabilnosti implantata učinjeno je uređajem Osstell Mentor za mjerenje rezonantne frekvencije koji rezultate interpretira u vidu vrijednosti kvocijenta stabilnosti implantata (*implant stability quotient*, ISQ). Prvo mjerenje je učinjeno neposredno nakon ugradnje implantata, dok je drugo provedeno 20 tjedana nakon ugradnje, odnosno prije postavljanja konačne protetske suprastrukture. Implantati tijekom mjerenja nisu bili funkcionalno opterećeni. Nije zabilježen niti jedan gubitak implantata. Prosječne vrijednosti ISQ kod imedijatne tehnike su bile 61,43 za prvo te 66,23 za drugo mjerenje u usporedbi sa 64,17 za prvo i 68,83 za drugo mjerenje kod odgođene tehnike ugradnje dentalnih implantata. Srednji porast vrijednosti ISQ bio je 4,8 za imedijatnu i 4,67 za odgođenu tehniku.

Ključne riječi: *Dentalni implantati; Stabilnost implantata; Analiza rezonantne frekvencije (RFA)*