

# Perkutana koronarna intervencija balonom obloženim lijekom: hrvatsko iskustvo

## Percutaneous Coronary Interventions with Drug-eluting Balloons: Croatian Experience

Deiti Prvulović<sup>1\*</sup>,  
Vjekoslav Tomulić<sup>2</sup>,  
Maja Strozzi<sup>3</sup>,  
Lovel Junio<sup>4</sup>,  
Jozica Šikić<sup>5</sup>,  
Boris Starčević<sup>6</sup>,  
Ivo Vuković<sup>4</sup>

<sup>1</sup> Opća bolnica "Dr. Josip Benčević", Slavonski Brod, Hrvatska

General Hospital "Dr. Josip Benčević", Slavonski Brod, Croatia

<sup>2</sup> Klinički bolnički centar Rijeka, Rijeka, Hrvatska

University Hospital Centre Rijeka, Rijeka, Croatia

<sup>3</sup> Klinički bolnički centar Zagreb, Zagreb, Hrvatska

University Hospital Centre Zagreb, Zagreb, Croatia

<sup>4</sup> Klinički bolnički centar Split, Split, Hrvatska

University Hospital Centre Split, Split, Croatia

<sup>5</sup> Klinička bolnica Sveti Duh, Zagreb, Hrvatska

University Hospital Sveti Duh, Zagreb, Croatia

<sup>6</sup> Klinička bolnica Dubrava, Zagreb, Hrvatska

University Hospital Dubrava, Zagreb, Croatia

RECEIVED:  
July 29, 2014

UPDATED:  
July 31, 2014

ACCEPTED:  
August 2, 2014

### SAŽETAK:

**UVOD:** Lijekom obloženi baloni (DEB) predstavljaju novu tehnološku platformu u području perkutane koronarne intervencije. Jedina prihvaćena indikacija za njihovu uporabu je liječenje *in-stent* stenozе, a za sve ostale indikacije nema jasnog konsenzusa.

**CILJ:** Evaluirati upotrebu DEB-a u rutinskoj kliničkoj praksi u Republici Hrvatskoj.

**METODE:** Restrospektivni nerandomizirani multicentrični registar svih liječenih bolesnika u sedam hrvatskih centara između veljače 2011. i siječnja 2014. godine. Podatci su sakupljeni uvidom u dostupnu medicinsku dokumentaciju. Nije bilo kliničkih niti angiografskih isključivih kriterija, niti pisanog zajedničkog protokola za indikacije niti praćenje bolesnika. Praćena su velika nepovoljna događanja (MACE) definirana kao kombinacija srčane smrti, infarkta miokarda na tretiranoj krvnoj žili (MI) ili klinički indicirane reintervencije na tretiranoj krvnoj žili TLR za sve bolesnike tijekom iste hospitalizacije, nakon 6 mjeseci kliničkog praćenja te dostupni angiografski podatci.

**REZULTATI:** Kod 248 bolesnika tretirane su 284 lezije. Najčešća indikacija bila je *in-stent* restenoza u 31,4% bolesnika, u 21,4% bolesnika DEB je implantiran u žilama manjim od 2,75 mm, a ostale indikacije su bile: lezije veće od 2,8 mm, bifurkacije, ostijalne lezije, kronične totalne okluzije (redom: 11,3%; 11,3%; 7,3%; 1,6%). U 39 bolesnika (15,6%) nakon prethodne implantacije običnih metalnih stentova (BMS) rađena je postdilatacija DEB-om. MACE su se tijekom hospitalizacije javili u 1,6% bolesnika: 1 smrt (0,4%), 3 akutne tromboze (1,2%), 1 MI (0,4%). Nakon 6 mjeseci praćenja dostupni su podatci za 83 bolesnika (33%). U 6% bolesnika je rađena TLR, a nije bilo registriranih smrti niti akutnih infarkta miokarda. Angiografska kontrola nakon 6 mjeseci učinjena je u 55 bolesnika (22%). U 69% bolesnika nalaz je opisivan kao potpuno uredan, nesignifikantna stenozа opisana je u 20% bolesnika, a u 11% bolesnika je opisana stenozа u rasponu od >50% do potpune okluzije.

**ZAKLJUČAK:** Naše kliničko iskustvo u svakodnevnoj kliničkoj praksi pokazuje da se DEB u Hrvatskoj koristi u najvećem slučaju u prihvaćenim indikacijama *in-stent* restenoze, ali i u velikom postotku i za indikacije za koje ne postoji jasni konsenzus u literaturi. Akutni angiografski rezultati i rani klinički ishodi su odlični, a uporaba DEB-a je izrazito sigurna.

### SUMMARY:

**INTRODUCTION:** Drug-eluting balloons (DEB) represent a new technological platform in the area of percutaneous coronary interventions. The only accepted indication for their use is the treatment of *in-stent* stenosis, with no clear consensus for all other indications.

**AIM:** To evaluate the use of DEB in routine clinical practice in Croatia.

**METHODS:** Retrospective nonrandomized multicentric register of all treated patients in seven Croatian centers in the time frame from February 2011 to January 2014. The data were collected from available medical documents. There were no clinical or angiographic exclusion criteria, nor was there any written common protocol for indications or for the clinical follow up of patients. Major adverse cardiac events (MACE) were monitored. MACE were defined as the combination of cardiac death, development of myocardial infarction (MI) on treated vessel, and/or target lesion revascularization (TLR) for all patients during the same hospitalization, following a 6-month clinical observation and through available angiographic data.

**RESULTS:** 248 patients were treated for 284 lesions. The most common indication was the *in-stent* restenosis present in 31.4% of the patients, for 21.4% of the patients DEB was implanted in vessels smaller than 2.75 mm, and other indications were: lesions larger than 2.8 mm, bifurcations, ostial lesion, chronic total occlusions (11.3%; 11.3%; 7.3%; 1.6% respectively). On 39 patients (15.6%) following the previ-

ous implantation of bare metal stents (BMS), postdilatation with DEB was conducted. MACE during hospitalization appeared in 1.6% of the patients: 1 death (0.4%), 3 acute thromboses (1.3%), 1 MI (0.4%). Following the 6 month long observation, data is available for 83 patients (33%). TLR was performed on 6% of the patients, and there were no registered deaths or acute myocardial infarctions. Angiographic follow-up was performed on 55 patients (22%) after 6 months. In 69% of the patients the findings were described as completely clean, insignificant stenosis was described for 20% of the patients, and for 11% of the patients a stenosis to the amount of >50% of full occlusion was described.

**CONCLUSION:** Our clinical experience in everyday clinical practice shows that in Croatia DEB is mostly used in cases of accepted indications of in-stent re-stenosis, but also to a great percentage for indications for which no clear consensus exists in literature. Acute angiographic results and early clinical results are excellent, and the use of DEB is highly safe.

**KLJUČNE RIJEČI:** koronarna bolest srca, perkutana koronarna intervencija, lijekom obloženi balon.

**KEYWORDS:** coronary heart disease, percutaneous coronary intervention, drug-eluting balloon.

**CITATION:** *Cardiol Croat.* 2014;9(7-8):289-298.

**\*ADDRESS FOR CORRESPONDENCE:** Opća bolnica „Dr. Josip Benčević“, Štampareva 42, HR-35000 Slavonski Brod, Croatia. / Phone: +385-35-201-685 / E-mail: [deiti.prvulovic@sb.t-com.hr](mailto:deiti.prvulovic@sb.t-com.hr)

**ORCID:** Đeiti Prvulović, <http://orcid.org/0000-0002-8041-1197> • Vjekoslav Tomulić, <http://orcid.org/0000-0002-3749-5559> • Maja Strozzi, <http://orcid.org/0000-0003-4596-8261> • Lovel Junio, <http://orcid.org/0000-0002-1268-5698> • Jozica Šikić, <http://orcid.org/0000-0003-4488-0559> • Boris Starčević, <http://orcid.org/0000-0002-3090-2772> • Ivo Vuković, <http://orcid.org/0000-0003-2170-1327>



## Uvod

Lijekom obloženi baloni (eng. *drug eluting balloon*; DEB) predstavljaju novu tehnološku platformu u području perkutane koronarne intervencije koja je izazvala značajan interes među intervencijskim kardiologima.

Ideja primjene DEB-a i obećavajući rezultati koji su do sada postignuti leže u primjeni visoke doze antiproliferativnog lijeka i njegovu brзом otpuštanju u oboljelo arterijsko tkivo samo za vrijeme inflacije balona i njegova dodira s endotelom, bez primjene trajnog polimera i stenta.

Primjena DEB-a teoretski eliminira nedostatke koje nosi primjena stentova: **(A)** nepotrebno dugo ostajanje stenta i polimera u krvnoj žili s mogućom reakcijom na strano tijelo i time rizik restenoze; **(B)** eliminacija alergije, upale, vazospazma, disfunkcije endotela koje uzrokuje polimer; **(C)** zadržavanje postojeće anatomije krvne žile što omogućuje njegovu primjenu u anatomski zahtjevnim i kompleksnim lezijama, gdje je uporaba stenta ograničena ili daje nezadovoljavajuće rezultate (ostijalne lezije, bifurkacije, male krvne žile, distalne lezije, difuzna bolest, tortuoziteti, šećerna bolest); **(D)** izbjegavanje mogućnosti malpozicije te frakture stenta čime raste rizik od stent-tromboze; **(E)** smanjenje rizika od krvarenja zbog dugotrajne uporabe antitrombotične terapije koja je neophodna nakon primjene DES-a (eng. *drug-eluting stent*, DES); **(F)** homogena distribucija lijeka u stijenku krvne žile za razliku od DES-a gdje je distribucija lijeka inhomogena samo uz strut stenta; **(G)** brzo otpuštanje lijeka i u višoj koncentraciji nego

## Introduction

Drug-eluting balloons (DEB) represent a new technological platform in the area of percutaneous coronary interventions which has sparked significant interest among intervention cardiologists.

The idea of the use of DEB and the promising results which have been recorded so far are the result of the application of a high dose of antiproliferative drug and its quick release into the affected arterial tissue only during the inflation of the balloon and its contact with endothelium without the use of permanent polymers and stents.

The use of DEB theoretically eliminates the disadvantages of application of stents: **(A)** unnecessarily long placement of the stent and the polymer in the blood vessel with possible reaction to the foreign body and thus a present risk of re-stenosis; **(B)** elimination of allergic reactions, inflammation, vasospasm dysfunction of endothelium caused by the polymer; **(C)** preservation of the existing anatomy of the blood vessel which enables its use in anatomically demanding and complex lesions where the use of stent is limited or gives unsatisfactory results (ostial lesions, bifurcation, small blood vessels, distal lesions, diffuse disease, tortuosities, diabetes); **(D)** avoiding the possibility of malapposition and fracturing of the stent which increases the risk of thrombosis; **(E)** reducing the risk of bleeding due to long-term use of antithrombotic which is essential after the use of a drug-eluting stent (DES); **(F)** homogenous distribution of the drug into the wall of the blood vessel unlike with DES where the drug distribution is not homogenous and is localized only along the wall of the stent; **(G)** faster and higher

kod DES-a, kratko zadržavanje lijeka u stijenci krvne žile, dakle za vrijeme najizrazitijeg oštećenja endotela, nakon čega je zbog odsutnosti lijeka reendotelizacija brža tako da nema potrebe za dugotrajnom antitrombotičnom terapijom.<sup>1</sup>

Trenutno je na svjetskom tržištu dostupno osam vrsta DEB-a i zasad svi proizvođači DEB-ova koriste paclitaxel, citotoksični lijek koji inhibira proliferaciju stanica ograničavajući funkciju mikrotubula kontinuiranom blokadom mitoze u metafazi-anafazi staničnoga ciklusa. Taj se lijek koristi radi izrazite lipofilnosti i brzog prodiranja u tkiva i čvrstog vezanja za razne dijelove stanice.

Glavne razlike među dostupnim DEB-ovima su u supstanciji koja se koristi kao nosač paklitaksela. Koriste se šelak (prirodna smola), BTHC (butyryl-tri-hexyl-citrat), urea, a najviše ispitivani nosač lijeka je iopromid, kontrastno sredstvo za koji je dokazano da poboljšava topivost paklitaksela. Neki od proizvođača čak nisu ni objavili koje nosače koriste, iako je vjerojatno da su upravo karakteristike nosača presudne za uspješan prijenos lijeka u stanice endotela, te su mogući razlog uočenih različitih rezultata u kliničkoj efikasnosti DEB-ova dostupnih na tržištu.

Usprkos velikom interesu intervencijskih kardiologa za tu novu tehnologiju i navedenim teoretskim prednostima, trenutna znanja o DEB-u se temelje tek na nekoliko kliničkih istraživanja i registara u koje je do sada uključeno ukupno samo oko 3500 bolesnika te mjesto DEB-a u rutinskom radu nije precizno određeno.<sup>2</sup> U američkim smjernicama se DEB ne spominje i nema registriranog DEB-a u USA, a smjernice Europskog kardiološkog društva preporučaju razmatranje DEB-a u liječenju *in-stent* stenozе i daju mu indikaciju klase IIa.<sup>3</sup> Moguće indikacije za uporabu DEB-a koje su cilj budućih istraživanja i registara su intervencije na malim žilama (<2,75 mm), bifurkacijske lezije, akutni koronarni sindrom, kombinacija DEB-a i običnih metalnih stentova (BMS, engl. *bare metal stent*), intervencije na kroničnim totalnim okluzijama i venskim graftovima te intervencija u bolesnika kod kojih je poželjna kraća ili poštenija antitrombotična terapija (bolesnici s fibrilacijom atrija, s ranijim krvarenjem u anamnezi, skorom planiranom kirurškom intervencijom, ulkusnom bolešću ili teškim bubrežnim oštećenjem).

Za sve te indikacije nema jasnog konsenzusa. Nedavno su najavljene nove preporuke njemačke grupe<sup>4</sup> te stav Talijanskog društva za intervencijsku kardiologiju<sup>2</sup> sa željom za promicanjem razumijevanja i ispravnu uporabu DEB-a u svakodnevnoj kliničkoj praksi.

## Cilj

U svjetlu spomenutih činjenica, cilj ovog članka je bio evaluirati uporabu DEB-a u rutinskoj kliničkoj praksi u Republici Hrvatskoj.

## Metode

### DIZAJN REGISTRA I BOLESNICI

Radi se o restrospektivnom nerandimiziranom multicentričnom registru svih liječenih bolesnika u sedam hrvatskih cen-

traliziranih centara. Cilj ovog članka je bio evaluirati koncentraciju oslobađanja lijeka iz DEB-a u odnosu na koncentraciju oslobađanja lijeka iz DES-a, vrijeme zadržavanja lijeka u stijenci krvne žile, vrijeme reendotelizacije endotela nakon čega je zbog odsutnosti lijeka reendotelizacija brža tako da nema potrebe za dugotrajnom antitrombotičnom terapijom.<sup>1</sup>

Trenutno je na svjetskom tržištu dostupno osam vrsta DEB-a i zasad svi proizvođači DEB-ova koriste paclitaxel, citotoksični lijek koji inhibira proliferaciju stanica ograničavajući funkciju mikrotubula kontinuiranom blokadom mitoze u metafazi-anafazi staničnoga ciklusa. Taj se lijek koristi radi izrazite lipofilnosti i brzog prodiranja u tkiva i čvrstog vezanja za razne dijelove stanice.

Glavne razlike među dostupnim DEB-ovima su u supstanciji koja se koristi kao nosač paklitaksela. Koriste se šelak (prirodna smola), BTHC (butyryl-tri-hexyl-citrat), urea, a najviše ispitivani nosač lijeka je iopromid, kontrastno sredstvo za koji je dokazano da poboljšava topivost paklitaksela. Neki od proizvođača čak nisu ni objavili koje nosače koriste, iako je vjerojatno da su upravo karakteristike nosača presudne za uspješan prijenos lijeka u stanice endotela, te su mogući razlog uočenih različitih rezultata u kliničkoj efikasnosti DEB-ova dostupnih na tržištu.

Usprkos velikom interesu intervencijskih kardiologa za tu novu tehnologiju i navedenim teoretskim prednostima, trenutna znanja o DEB-u se temelje tek na nekoliko kliničkih istraživanja i registara u koje je do sada uključeno ukupno samo oko 3500 bolesnika te mjesto DEB-a u rutinskom radu nije precizno određeno.<sup>2</sup> U američkim smjernicama se DEB ne spominje i nema registriranog DEB-a u USA, a smjernice Europskog kardiološkog društva preporučaju razmatranje DEB-a u liječenju *in-stent* stenozе i daju mu indikaciju klase IIa.<sup>3</sup> Moguće indikacije za uporabu DEB-a koje su cilj budućih istraživanja i registara su intervencije na malim žilama (<2,75 mm), bifurkacijske lezije, akutni koronarni sindrom, kombinacija DEB-a i običnih metalnih stentova (BMS, engl. *bare metal stent*), intervencije na kroničnim totalnim okluzijama i venskim graftovima te intervencija u bolesnika kod kojih je poželjna kraća ili poštenija antitrombotična terapija (bolesnici s fibrilacijom atrija, s ranijim krvarenjem u anamnezi, skorom planiranom kirurškom intervencijom, ulkusnom bolešću ili teškim bubrežnim oštećenjem).

Za sve te indikacije nema jasnog konsenzusa. Nedavno su najavljene nove preporuke njemačke grupe<sup>4</sup> te stav Talijanskog društva za intervencijsku kardiologiju<sup>2</sup> sa željom za promicanjem razumijevanja i ispravnu uporabu DEB-a u svakodnevnoj kliničkoj praksi.

## Goal

In light of the aforementioned data, the goal of this article is to evaluate the use of DEB in routine clinical practice in Croatia.

## Methods

### DESIGN OF THE REGISTER AND PATIENTS

We are dealing with a retrospective nonrandomized multicentric register of all treated patients in seven Croatian centers for

tara intervencijske kardiologije između veljače 2011. i siječnja 2014. godine. Nije bilo kliničkih niti angiografskih isključujućih kriterija, a ni pisanog zajedničkog protokola za indikacije niti za praćenje bolesnika; svi bolesnici iz svakodnevne prakse s koronarnom bolesti srca pogodnom za perkutanu koronarnu intervenciju (PCI, engl. *percutaneous coronary intervention*) su bili potencijalni kandidati za uključivanje u registar, što uključuje i bolesnike s akutnim infarktom miokarda, kroničnom bubrežnom insuficijencijom, oštećenjem sistoličke funkcije lijeve klijetke, bifurkacijskim i ostijalnim lezijama, *in-stent* restenozom, intervencije na venskim graftovima, kroničnim totalnim okluzijama i deblu lijeve koronarne arterije. Vođenje registra nije bilo sponzorirano. Bolesnici su liječeni jednim ili više lijekovima obloženih balona ili kombinacijom sa DES-om ili BMS-om, ovisno o odluci vodećeg operatora.

## POSTUPAK PERKUTANE KORONARNE INTERVENCIJE I PRAĆENJE BOLESNIKA

Svi su postupci rađeni po trenutnim standardima PCI, s obveznom predilatacijom. Odluka o izboru terapijske strategije je ostavljena na izbor vodećem operatoru. Doza zasićenja acetilsalicilatne kiseline je bila 300 mg prije PCI, osim ukoliko bolesnik već nije bio na toj terapiji te trajno nastavljena u dozi od 100 mg. Doza zasićenja klopidogrela od 600 mg je primijenjena prije PCI i nastavljena u dozi održavanja od 75 mg tijekom 12 mjeseci. Uporaba IIb/IIIa inhibitora je bila prema odluci operatora.

Intrahospitalno praćenje kliničkoga tijeka za sve bolesnike napravljeno je uvidom u medicinsku dokumentaciju. Srčani enzimi, uključujući mjerenje kreatin-kinaze, kreatin-kinaze MB te troponina nisu rutinski kontrolirani, već su bili određeni samo u slučaju kliničke indikacije. Kasniji klinički tijek radi praćenja velikih kliničkih događanja, uključujući srčanu smrtnost, ukupnu smrtnost, srčani infarkt i ponovljenu revascularizaciju, rađen je prema protokolu specifičnom za svaki uključeni centar, a podatci su skupljeni uvidom u dostupnu medicinsku dokumentaciju putem bolničkih informatičkih sustava svakog od uključenih centara. Nije bilo specifičnog definiranog protokola praćenja bolesnika, obveznih kliničkih vizita niti telefonskih kontakata bolesnika ili njihovih liječnika opće medicine ili nadležnih kardiologa. Nije bilo neovisnoga ili vanjskoga praćenja podataka.

## KLINIČKI ISHODI I DEFINICIJE

Velika nepovoljna događanja (MACE, engl. *major adverse cardiac events*) su definirana kao kombinacija srčane smrti, infarkta miokarda na tretiranoj krvnoj žili (MI), ili klinički indicirane reintervencije na tretiranoj krvnoj žili (TLR, engl. *target lesion revascularization*). Smrt koja nije mogla biti objašnjena drugim uzrokom smatrana je srčanom smrću. Dijagnoza srčanog infarkta je postavljena po univerzalnoj definiciji<sup>5</sup>. Tromboza tretirane lezije te akutno zatvaranje krvne žile je klasificirana po *Academic Research Consortium* kriterijima<sup>6</sup>.

## Rezultati

### BOLESNICI

U razdoblju između veljače 2011. i siječnja 2014. godine u registar je uključeno ukupno 248 bolesnika liječenih postupkom PCI jedne ili više krvnih žila s uporabom DEB-a (u 209 bole-

intervention cardiology from February 2011 to January 2014. There were no clinical or exclusion criteria, nor was there any written common protocol for indications or for the clinical follow-up of the patients, all the patients from every day practice with coronary heart disease suitable for percutaneous coronary intervention (PCI) were potential candidates for being included in the register, which includes patients with acute myocardial infarction, chronic kidney insufficiency, left ventricle systolic dysfunction, bifurcation and other lesions, *in-stent* re-stenosis, interventions on vein grafts, chronic total occlusions, and the stem of the left coronary artery. The running of the register was not sponsored. The patients were treated with one or more drug-eluting balloons or in combination with DES or BMS was left to the physician's discretion.

## PROCEDURE OF THE PERCUTANEOUS CORONARY INTERVENTION AND OBSERVATION OF PATIENTS

All the procedures were conducted in accordance with the current PCI standards with obligatory predilatation. The decision regarding the therapeutic was left to the physician's discretion. The dose of the acetylsalicylic acid saturation was 300 mg before PCI, unless the patient has already been subjected to this therapy and was permanently continued with the dose of 100 mg. The dose of Clopidogrel saturation of 600 mg was applied before PCI and continued in the dosage of 75 mg over the period of 12 months. The usage of IIb/IIIa inhibitors was according to the decision of the physician.

Intrahospital observation of the clinical procedure for all the patients was done through insight into medical documents. Heart enzymes, including the measuring of the creatine kinase, creatine kinase-MB, and the troponins were not routinely controlled, but were determined only in cases of clinical indication. Subsequent clinical procedure for the purpose of observing major adverse cardiac events including cardiac mortality, total mortality, coronary infarction and repeated revascularization was done according to the protocol specific for each center included in the study, and the data were gathered by insight into available medical documents via hospital information systems for all participating centers. There was no specifically defined protocol for patient clinical follow-up, obligatory clinical rounds or telephone contact with the patients or their general practitioners or appropriate cardiologists. There was no independent or external data monitoring.

## CLINICAL RESULTS AND DEFINITIONS

Major adverse cardiac events (MACE) were defined as combinations of cardiac death, myocardial infarction (MI) on the treated blood vessel or clinically indicated re-intervention on the treated blood vessel TLR (target lesion revascularization). Death which could not be explained by any other cause was considered to be cardiac death. Diagnosis of MI was given according to the universal definition<sup>5</sup>. Thrombosis of the treated lesion and the acute blockage of a heart vessel were classified according to *Academic Research Consortium criteria*<sup>6</sup>.

## Results

### PATIENTS

In the time frame from February 2011 to January 2014, a total of 248 patients treated by the PCI procedure of one or more blood

snika *SeQuent Please*, Braun, DE; u 39 bolesnika *Elutax SC*, Aachen Resonance, DE). Uključeno je ukupno 76 bolesnika iz Kliničkog bolničkog centra Rijeka, 65 iz Kliničkog bolničkog centra Zagreb, 40 iz Kliničkog bolničkog centra Split Križine, 21 iz Opće bolnice „Dr. J. Benčević“ Slavonski Brod, 20 iz Kliničke bolnice „Sveti Duh“, 17 iz Kliničke bolnice Dubrava i 9 iz Kliničkog bolničkog centra Split Firule.

Ukupno su 284 lezije bile liječene primjenom DEB-a, odnosno 14,5% bolesnika je imalo multiple lezije. **Tablice 1. i 2.** objedinjuju osnovne demografske i kliničke karakteristike

vessels with the use of DEB (209 patients with *SeQuent Please*, Braun, DE; 39 patients with *Elutax SC*, Aachen Resonance, DE) were included in the register. 76 patients were from University Hospital Centre Rijeka, 65 from University Hospital Centre Zagreb, 45 from University Hospital Centre Split Križine, 21 from Dr. J. Benčević General Hospital Slavonski Brod, 20 from Sveti Duh University Hospital Centre, 17 from University Hospital Centre Dubrava and 9 from University Hospital Centre Split Firule.

The total of 284 lesions were treated with the use of DEB, namely 14.5% of the patients had multiple lesions. **Table 1 and 2**

**TABLE 1. Baseline demographics and clinical characteristics.**

<b>Number of patients</b>		248
<b>Number of lesions</b>		284 (in 14.5% multiple lesions)
<b>Demographics</b>	Age (years) median (range)	62 (29-82)
	Male gender	191 (77.0%)
<b>Medical history / risk factors</b>	Diabetes	99 (40.0%)
	Hypertension	207 (83.5%)
	Hyperlipidemia	206 (83.1%)
	Current smoker	71 (28.6%)
	Previous myocardial infarction	123 (49.6%)
<b>Clinical presentation / ischemic status</b>	Stable angina	141 (56.9%)
	Unstable angina	51 (20.6%)
	Non-ST-segment elevation myocardial infarction	39 (15.7%)
	ST-segment elevation myocardial infarction	17 (6.9%)

**TABLE 2. Lesion and procedural characteristics.**

<b>Target vessel location, n (%)</b>	Left anterior descending artery	113 (45.6%)	
	Circumflex coronary artery	70 (28.2%)	
<b>Indications, n (%)</b>	In-stent restenosis after bare-metal stent	68 (27.4%)	
	In-stent restenosis after drug-eluting stent	10 (4.0%)	
	Drug-eluting balloons - only small vessel < 2.75 mm	53 (21.4%)	
	Drug-eluting balloons - only non small vessel > 2.80 mm	28 (11.3%)	
	Bifurcation	28 (11.3%)	
<b>Drug-eluting balloon characteristics</b>		<b>mean ± SD</b>	<b>median, range</b>
	Length, mm	22.2 ± 6.05	20 (10 – 30)
	Diameter, mm	2.85 ± 0.44	3.00 (2.00-4.00)
	Inflation pressure, bar	9.67 ± 2.53	
	Inflation time, s	54.04 ± 24.33	

svih uključenih bolesnika te karakteristike tretiranih lezija. Prosječna dob bolesnika iznosila je 62 godine (29-82), a muškarci su činili 77% ukupne populacije. Šećernu bolest je imalo 40% bolesnika. Sa slikom stabilne angine pectoris liječeno je 56,9% bolesnika, a ostali su imali različite oblike akutnog koronarnog sindroma.

### KARAKTERISTIKE POSTUPKA

Ukupno su implantirana 284 DEB-a, prosječni broj lezija po bolesniku bio je 1,15. Predilatacija je učinjena na svim tretiranim lezijama. Prosječna dužina korištenih DEB-ova je  $22,2 \pm 6,05$  mm, a prosječni dijametar DEB-a je bio  $2,85 \pm 0,44$  mm, prosječni tlak inflacije balona je bio  $9,67 \pm 2,53$  bara, a dužina trajanja inflacije balona  $54,04 \pm 24,33$  sekunda. Uspjeh postupka, koji je bio definiran kao vizualno procijenjena rezidualna stenozna <30%, iznosio je 98%.

Najčešća indikacija za uporabu DEB-a bila je *in-stent* restenoza kod ukupno 31,4% bolesnika, od čega je u 27,4% bolesnika restenoza nastala u BMS-u, a kod 4% u DES-u. U 21,4% bolesnika DEB je implantiran u žilama manjim od 2,75 mm, a ostale indikacije su bile lezije veće od 2,8 mm, bifurkacije, ostijalne lezije, kronične totalne okluzije (redom: 11,3%; 11,3%; 7,3%; 1,6%). U 39 bolesnika (15,6%) nakon prethodne implantacije BMS-a rađena je postdilatacija s DEB-om. Ta podskupina bolesnika je rađena Elutax DEB-om i svi su pacijenti imali akutni koronarni sindrom.

### KLINIČKI ISHODI

Bolnički ishodi (za vrijeme iste hospitalizacije) su dostupni za sve bolesnike. Velika nepovoljna događanja (MACE) definirana kao razvoj srčanog infarkta i/ili revaskularizacija ciljane lezije i/ili smrt pojavili su se u 1,6% bolesnika. Jedan bolesnik je umro za vrijeme hospitalizacije (0,4% svih uključenih), u 3 bolesnika (1,2%) došlo je do akutne tromboze tretirane lezije, a jedan bolesnik (0,4%) je imao infarkt miokarda (dijagnoza je postavljena na temelju tipične kliničke slike i EKG promjena) (slika 1).

combine the baseline demographic and clinical characteristics of all participating patients and the characteristics of all treated lesions. The average age of the patients was 62 years of age (29-82); and men composed 77% of the total population. 40% of the patients suffered from diabetes. 56.9% of the patients had stable angina pectoris, and the rest of the patients had different forms of acute coronary syndrome.

### PROCEDURAL CHARACTERISTICS

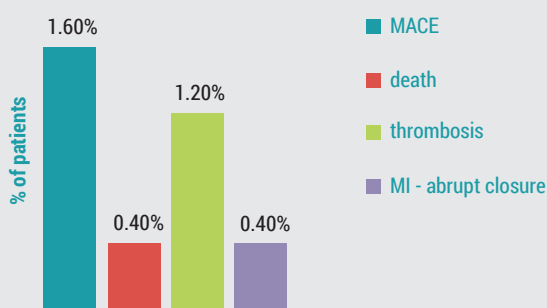
A total of 284 DEB were implanted, and the average number of lesions per patient was 1.15. Predilatation was performed on all treated lesions. The mean length of the used DEBs was  $22.2 \pm 6.05$  mm, and the mean diameter of the DEB was  $2.85 \pm 0.44$  mm, the mean pressure of balloon inflation was  $9.67 \pm 2.53$  bars and the time of inflation of the balloon was  $54.04 \pm 24.33$  seconds. The success of the procedure, which was defined as visually estimated residual stenosis <30%, was 98%.

The most common indication for the use of DEB was in-stent stenosis present in the total of 31.4% of the patients, in 27.4% of which restenosis was created in BMS, and in 4% in DES. In 21% of the patients DEB was implanted into blood vessels smaller than 2.75 mm, and other indications were lesions larger than 2.8 mm, bifurcations, ostial lesions, chronic total occlusions (11.3%, 11.3%, 7.3%, and 1.6% respectively). In the case of 39 patients (15.6%) following the previous BMS implantation a post-dilatation with DEB was performed. This subgroup of patients was performed with Elutax DEB and all the patients had acute coronary syndrome.

### CLINICAL RESULTS

Hospital outcomes (during the same hospitalization) were available for all patients. Major adverse cardiac events were defined as the development of MI and/or TLR and/or death were present in 1.6% of the patients. One patient died during the hospitalization (0.4% of all included), and 3 patients (1.2%) suffered from acute thrombosis of the treated lesion, and one patient (0.4%) suffered a myocardial infarction (diagnosis was given based on the typical clinical image and the ECG changes) (Figure 1).

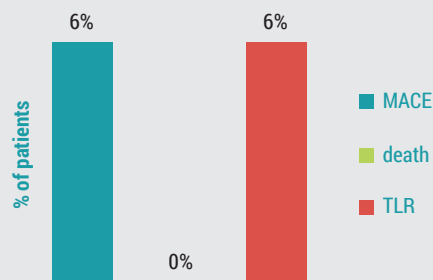
FIGURE 1. In-hospital outcomes (n=248).



Major adverse coronary events (MACE) = myocardial infarction (MI) and/or target lesion revascularisation (TLR) and/or death.

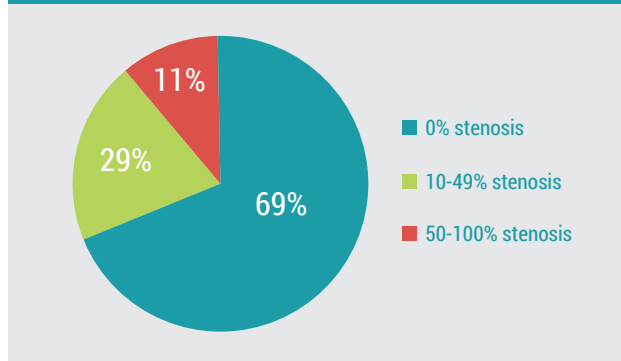
MI = chest pain and typical changes in ECG – no routinely CK, troponin.

FIGURE 2. Clinical follow-up outcomes at 6 months (n=83, in 33% patients).



Major adverse coronary events (MACE) = myocardial infarction (MI) and/or target lesion revascularisation (TLR) and/or death.

**FIGURE 3. Angiographic follow-up outcomes at 6 months (n=55, in 22% pts).**



Kliničko praćenje je do siječnja 2014. godine bilo dostupno u medijanu od 260 dana (interkvartilni raspon 181/807 dan), a nakon 6 mjeseci za ukupno 83 bolesnika (33%). U 6% bolesnika je rađena reintervencija na tretiranoj leziji, a nije bilo registriranih smrti niti akutnih infarkta miokarda (**slika 2**).

Angiografska kontrola nakon 6 mjeseci učinjena je u 55 bolesnika (22%). U 69% bolesnika nalaz je opisan kao potpuno uredan, nesignifikantna stenoza opisana je u 20% bolesnika, a u 11% bolesnika je opisana stenoza u rasponu od >50% do potpune okluzije (**slika 3**).

## Rasprava

U članku su prikazani rezultati primjene PCI s DEB-om iz sedam hrvatskih centara intervencijske kardiologije u razdoblju od gotovo tri godine. Rezultati predstavljaju stvarnu sliku uporabe DEB-a u rutinskoj svakodnevnoj praksi u Hrvatskoj.

Korišteni balon je *SeQuent Please, Braun*, osim za podgrupu od 39 bolesnika s akutnim koronarnim sindromom u kojih je nakon implantacije BMS-a postdilatacija rađena balonom *Elutax*. Liječeno je 248 bolesnika i 284 lezije, s prosječnom dužinom balona od  $22,2 \pm 6,05$  mm, prosječnim dijametrom od  $2,85 \pm 0,44$  mm, prosječnim tlakom od  $9,67 \pm 2,53$  bara te duljinom inflacije od  $54,04 \pm 24,33$  sekunde. Ti su podatci vrlo sukladni podacima iz najvećeg dosad objavljenog registra *SeQuent Please World Wide Registry* s uključenih 2095 bolesnika iz 75 centara<sup>7</sup>.

DEB je najčešće korišten u restenozu (31,4%), i to glavnom u BMS-u (27,4%) i rjeđe u restenozu u DES-u (4%). To je jedina indikacija za koju smjernice Europskog kardiološkog društva preporučuju razmatranje DEB-a i daju mu indikaciju klase IIa<sup>3</sup>. Učestalost bolesnika s tom indikacijom je znatno manja nego u *SeQuent Please World Wide Registry* u kojemu je DEB u toj indikaciji korišten u 72,7% svih indikacija<sup>7</sup>. U Hrvatskoj je DEB korišten u *de novo* lezijama u znatno većem postotku nego u ostatku svijeta (68,6% vs 27,3%), što se može smatrati primjenom izvan odobrene ("off-label") indikacije.

Među tim „off-label“ indikacijama na prvom mjestu je intervencija s uporabom DEB-a na malim žilama (<2,75 mm) koja je učinjena u 53 bolesnika (21,4% svih indikacija). Podatci iz literature pokazuju da je DEB dobra opcija u liječenju malih

Clinical observation conducted until January 2014 was available for a median of 260 days (inter-quartal span 181/807 days) and after 6 months for the total of 83 patients (33%). 6% of the patients underwent re-intervention on the treated lesion, and there were no registered deaths nor acute myocardial infarctions (**Figure 2**).

Angiographic follow-up was performed on 55 patients (22%) after 6 months. In 69% of the patients the findings were described as completely clean, insignificant stenosis was described for 20% of the patients, and for 11% of the patients a stenosis to the amount of >50% of full occlusion was described (**Figure 3**).

## Discussion

This article presents the mode of the application of PCI with DEB from 7 Croatian centers for intervention cardiology in the time span of almost three years. The results represent a real image of the use of DEB in routine everyday practice in Croatia.

The balloon used was *SeQuent Please, Braun*, except for the subgroup of 39 patients with acute coronary syndrome for which following the BMS implantation postdilatation was performed with *Elutax* balloon. 248 patients and 284 lesions were treated, with the mean length of the used DEBs was  $22.2 \pm 6.05$  mm, the mean diameter of the DEB was  $2.85 \pm 0.44$  mm, the mean pressure of balloon inflation was  $9.67 \pm 2.53$  bars, and the time of inflation of the balloon was  $54.04 \pm 24.33$  seconds. This results corresponds to the data of the up-to-date largest *SeQuent Please World Wide Registry* which includes 2095 patients from 75 centers<sup>7</sup>.

DEB was most commonly used in restenosis (31.4%) and this mainly in BMS (27.4%) and rarely in DES restenosis (4%). This is the only indication for which the European Society of Cardiology recommends DEB and give it indication class IIa<sup>3</sup>. Patient frequency with this indication is significantly lower than in *SeQuent Please World Wide Registry* in which DEB in this indication was used in 72.7% of all indications<sup>7</sup>. In Croatia DEB was used in *de novo* lesions in a significantly higher percentage than in the rest of the world (68.6% vs 27.3%) which can be considered a use for "off-label" indications.

Among these "off-label" indications the first place in the use is the DEB intervention on small blood vessels (<2.75 mm) which was performed on 53 patients (21.4% of all indications). The data from literature shows that DEB represents a good option in the treatment of small blood vessels. In PEPCAD I prospective register<sup>8</sup> in 118 patients long-term results after 36 months of observation shows that the patients treated only with DEB as compared to the group treated with DEB with the use of BMS have had significantly smaller numbers of acute myocardial infarctions (2.4% as compared to 6.3%), significantly less need for target lesion revascularization (4.9% compared to 34%) and MACE (7.3 compared to 40.6%). In patients treated only with DEB there was no thrombosis, while in the group where BMS was used it appeared in 6.3% of the patients. In the BELL0<sup>9</sup> study DEB was compared to DES in 182 patients with *de novo* lesions on small blood vessels (diameter <2.8 mm). DEB showed significantly less late lumen loss ( $0.08 \pm 0.38$  mm compared to  $0.29 \pm 0.44$  mm) and similar results in restenosis proved by angiography (8.9% compared to 14.1%;  $p=0.25$ ), target lesion revascularization

krvnih žila. U PEPCAD I prospektivnom registru<sup>8</sup> kod 118 bolesnika dugoročni rezultati nakon 36 mjeseci praćenja pokazali su da su bolesnici koji su liječeni samo DEB-om u usporedbi sa skupinom koja je liječena DEB-om uz primjenu BMS imali znatno manje akutni infarkt miokarda (2,4% naspram 6,3%), znatno manje potrebe za revaskularizacijom ciljane lezije (4,9% naspram 34%) te MACE (7,3% naspram 40,6%). U bolesnika liječenih samo DEB-om nije bilo tromboze, dok se u skupini gdje je korišten i BMS ona javila u 6,3% bolesnika. U studiji BELLO<sup>9</sup> DEB je uspoređivan s DES-om u 182 bolesnika s *de novo* lezijama na malim krvnim žilama (promjer <2,8 mm). DEB je imao značajno manje kasnoga gubitka lumena ( $0,08 \pm 0,38$  mm naspram  $0,29 \pm 0,44$  mm) te slične rezultate u angiografski dokazanoj restenozi (8,9% naspram 14,1%;  $p = 0,25$ ), revaskularizaciji ciljane lezije (4,4% naspram 7,6%;  $p=0,37$ ) te velikim nepovoljnim događanjima - MACE (7,8% naspram 13,2%;  $p=0,77$ ). *Bonavertura* na skupu Euro PCR 2012 u Parizu pokazuje rezultate na 85 bolesnika, koju su praćeni  $16,3 \pm 5,5$  mjeseci, koji su nakon predilatacije u slučaju da nije bilo veće disekcije ili ostatne stenozе liječeni samo DEB-om, naglašavajući da je metoda sigurna i da nije bilo niti jedne stent (balon) tromboze. Rezultati svih tih studija doveli su do razvoja "DEB only strategy" – uporaba DEB-a kao jedinog načina liječenja koronarnih arterija <2,75 mm, bez ugradnje stenta što je indikacija koja najviše obećava u budućoj uporabi DEB-a.

DEB je korišten u 28 bolesnika (11,3% svih indikacija) na krvnoj žili >2,8 mm. Pregledom literature, do sada je objavljeno jedno istraživanje na *de novo* lezijama  $\geq 2,5$  mm, bez ograničenja maksimalnoga promjera krvne žile u uključnim kriterijima – *The Valentines II trial*<sup>10</sup>. Rezultati na 103 bolesnika su pokazali da je postupak siguran (2% smrti i infarkta miokarda) te efikasan (6,9% revaskularizacije ciljane lezije i ciljane krvne žile) tijekom  $227 \pm 40$  dana praćenja.

U 46 hrvatskih bolesnika DEB je korišten u liječenju bifurkacijskih lezija, u čemu podgrupa s izoliranom ostijalnom stenozom postranične grane (medina 0,0,1) ima 18 bolesnika (7,3% svih indikacija). Od tih 46 bolesnika njih 38 je liječeno samo DEB-om, a 8 kombinacijom DEB-a i BMS-a. Podatci iz literature o DEB-u u toj indikaciji su oskudni. U PEPCAD V studiji<sup>11</sup> na malom broju od 28 bolesnika s bifurkacijskom lezijom prvo je učinjena dilatacija DEB-om i glavne i susedne grane, a potom implantiran BMS u glavnu granu s otvaranjem stenta prema postraničnoj grani jednim balonom. Angiografski rezultati nakon 9 mjeseci pokazali su vrlo mali kasni gubitak lumena u postraničnim granama liječenim uglavnom DEB-om bez ugradnje stenta, ali u 3 bolesnika je nakon 6, 8 i 30 mjeseci došlo do kasne i vrlo kasne tromboze BMS implantiranog u glavnu granu. Istraživanje DEBUI<sup>12</sup> je uspoređivalo tri skupine bolesnika. Bifurkacijske lezije su liječene DEB-om uz BMS, samo BMS-om te sa DES-om. Nakon 6 mjeseci nije bilo signifikantne razlike u kasnom gubitku lumena u bolesnika liječenih samo BMS-om u odnosu na BMS kombiniran s DEB-om. Uporaba DEB-a je bila sigurna i nije bilo tromboze lezija tretiranih DEB-om.

U tijeku je prospektivni registar s korištenjem „kissing“ tehnike s DEB-om (*KISSING DEBBIE study*, NCT01009996) te studija sa *SeQuent Please* DEB-om u postraničnoj grani i paclitaxel DES u glavnoj grani (*Study of the Paclitaxel-Coated*

(4.4% compared to 7.6%;  $p=0.37$ ), and in major adverse coronary events (MACE) (7.8% compared to 13.2%,  $p=0.77$ ). *Bonavertura* at the Euro PCR 2012 Paris convention presented results from 85 patients which were observed for  $16.3 \pm 5.5$  months which were, in case of no major dissection or ostial stenosis, treated only with DEB, emphasizing that the method was safe and that there was no stent (balloon) thrombosis. The results of these studies have brought on the development of the "DEB only strategy" – the use of DEB as the sole means of treating coronary arteries <2.75 mm, without the stent implantation which presents the most promising indication in the future use of DEB.

DEB was used on 28 patients (11.3% of all indications) on a blood vessel >2.8 mm. by reviewing the literature, up-to-date there has been one research conducted on *de novo* lesions  $\geq 2.5$  mm, without the limit on the maximum diameter of the blood vessel in the crucial criteria - *The Valentines II trial*<sup>10</sup>. The results on 103 patients have shown that the procedure is safe (2% of deaths and myocardial infarctions) and efficient (6.9% target lesion and target blood vessel revascularization) over the span of  $227 \pm 40$  days of observation.

In 46 of the Croatian patients DEB was used in treating bifurcation lesions, among which the group with isolated ostial stenosis of the side branch (Medina 0,0,1) has 18 patients (7.3% of all indications). Out of these 46 patients, 38 were treated only with DEB, and 8 were treated with a combination of DEB and BMS. The data from literature on DEB in this indication is very sparse. In PEPCAD V study<sup>11</sup> on a small number of 28 patients with bifurcation lesion first a dilatation with DEB of both the major and the side branches was performed, and following this BMS was implanted into the main branch with the stent opening towards the side branch with one balloon. Angiography results after 9 months have shown slight late lumen loss in side branches treated mostly with DEB without the stent implantation, and in 3 patients after 6, 8 and 10 months a late and very late thrombosis of the BMS implanted into the main branch was recorded. DEBUI<sup>12</sup> research compared three groups of patients. Bifurcation lesions were treated by DEB with BMS, only with BMS and only with DES. After 6 months there was no significant difference in the late lumen loss in the patients treated only with BMS in comparison to those treated with a combination of BMS and DEB. The use of DEB was safe and there was no thrombosis in the lesions treated with DEB.

Currently there are two studies which are being conducted: prospective register with the use of "kissing" technique with DEB (*KISSING DEBBIE study*, NCT01009996) and the study involving the *SeQuent Please* DEB in the side branch and paclitaxel DES in the main branch (*Study of the Paclitaxel-Coated Balloon Catheter in Bifurcated Coronary Lesions*, BABILON, NCT01278186).

Depending on the clinical presentation, or the ischemic status of the patients, in Croatian patients DEB was used on 141 patients (56.9%) with a stabile angina, on 51 patients (20.6%) with a unstable angina pectoris on 39 patients (15.7%) with acute infarction without ST elevation and on 17 patients (6.9%) with acute infarction with ST-segment elevation (STEMI). Out of these 17 patients with STEMI on 4 patients only DEB was used due to the intervention on a small blood vessel, on 6 with bifurcation lesion on 5 occasions only DEB was used and on one patient DEB was



*Balloon Catheter in Bifurcated Coronary Lesions*, BABILON, NCT01278186).

Ovisno o kliničkoj prezentaciji, odnosno o ishemijskom statusu bolesnika, kod hrvatskih je bolesnika DEB korišten u 141 (56,9%) bolesnika sa slikom stabilne angine, kod 51 (20,6%) bolesnika sa slikom nestabilne angine pektoris, 39 (15,7%) bolesnika s akutnim infarktom bez ST elevacije te u 17 (6,9%) bolesnika sa slikom akutnog infarkta s elevacijom ST-segmenta (STEMI). Od tih 17 bolesnika sa slikom STEMI, u 4 bolesnika je korišten samo DEB zbog intervencije na žili malog promjera, u 6 s bifurkacijskom lezijom u 5 navrata je korišten samo DEB, a u jednog bolesnika DEB u kombinaciji s BMS-om. U 3 bolesnika s izoliranom ostijalnom lezijom postranične grane, u jednog bolesnika samo DEB, a u 2 bolesnika u kombinaciji sa BMS-om. U 4 bolesnika sa žilom >2,8 mm, u 2 navrata je intervencija rađena u kombinaciji sa BMS-om. Dakle, samo u 2 bolesnika na žili >2,8mm i slikom STEMI, rađena je intervencija samo s DEB-om.

O uporabi DEB-a u STEMI postoji samo jedna objavljena studija, DEB-AMI<sup>13</sup>. U toj studiji je 149 bolesnika randomizirano na DEB+BMS, samo BMS i na DES. Skupina bolesnika liječenih DEB-om nije pokazala prednosti nad onom liječenom samo BMS-om, a rezultati su bili lošiji od skupine liječene DES-om. Tromboza i postojanje rezidualnoga tromba i nakon tromboaspiracije i predilatacije lezije te nepoznavanje farmakokinetike prodora lijeka u rupturirani plak uz prisutnost tromba opravdava stav da rutinska uporaba DEB-a u ovom kliničkom scenariju nije opravdana.

Uporaba DEB-a se pokazala sigurnom. Tijekom iste hospitalizacije među 248 bolesnika, samo je jedan bolesnik umro. Radilo se o bolesniku sa slikom STEMI, u kardiogenom šoku, a DEB je korišten u intervenciji na bifurkacijskoj leziji LAD-D1, te se taj smrtni ishod objašnjava težinom kliničke slike i nije povezan s primjenom DEB-a. Akutna tromboza registrirana je u 3 bolesnika sa slikom akutnog infarkta bez ST-elevacije. U jednog od tih bolesnika rađena je intervencija s BMS-om koji je postdilatan s DEB-om, a u 2 bolesnika DEB je korišten u bifurkacijskoj leziji. U jednog bolesnika je tijekom iste hospitalizacije postavljena dijagnoza akutnog infarkta miokarda na tretiranoj leziji, a i taj je bolesnik liječen kombinacijom BMS-a s postdilatacijom DEB-om. Analizirajući te podatke, niti jedan od registriranih velikih nepovoljnih događanja za vrijeme hospitalizacije nije vezan isključivo za intervenciju DEB-om.

Podatci o kliničkom praćenju bolesnika nakon 6 mjeseci su bili dostupni za 83 (33%) bolesnika i samo u 6% bolesnika je učinjena revaskularizacija lezije liječene DEB-om, što je sukladno podacima iz literature.

## Ograničenja

Očita ograničenja ovog registra su da je retrospektivan i da nije postojao zajednički protokol praćenja svih varijabli i zajednički protokol kasnijega standardiziranoga praćenja bolesnika. Zbog toga nedostaje cijeli niz podataka koji su od važnosti za sam tehnički dio izvođenja intervencije DEB-om, koji bi bio od važnosti u svakodnevnoj praksi: ukupni broj predilatacija i trajanje tih predilatacija na tretiranoj leziji, vrste korištenih balona u predilataciji, uspješnost predilatacije, postotak bole-

used in combination with BMS. In the case of 3 patients with an isolated ostial lesion of the side branch on one patient only DEB was used, and on 2 patients it was used in combination with BMS. In the case of 4 patients with the blood vessel >2.8 mm, in 2 occasions the intervention was performed in combination with BMS. Thus, intervention with DEB only was performed only in 2 patients with blood vessel >2.8 mm and STEMI image.

Only a single published study, DEB-AMI<sup>13</sup>, exists on the topic of the use of DEB in STEMI. In this study, 149 patients were randomly distributed into DEB+BMS, only BMS and only DES groups. The group of patients treated with DEB showed no advantage as compared to the group treated only with BMS, and the results were worse than those of the group treated with DES. Thrombosis and existence of residual thrombus even after thromboaspiration and lesion predilatation and the unknown facts about the pharmacokinetics of the penetration of the drug into the ruptured plaque with the presence of the thrombus justifies the opinion that the routine use of DEB in this clinical scenario is not justified.

The use of DEB has been shown to be safe. During the same hospitalization among 248 patients only one patient has died. This was the case of a patient with a STEMI, in cardiogenic shock, and DEB was used in the intervention on a bifurcation lesion LAD-D1 and this mortality is explained with the severity of the clinical picture and is not connected to the application of DEB. Acute thrombosis was registered in 3 patients with acute infarction without ST elevation. In the case of one of these patients BMS intervention was done which was postdiluted with DEB, and in the case of 2 patients DEB was used in bifurcation lesion. In the case of one patient during the same hospitalization, a diagnosis of acute myocardial infarction on the treated lesion was made and this patient was treated with a combination of BMS with DEB postdilataction. By analyzing these data, none of the registered major adverse events during hospitalization was exclusively connected to the DEB intervention.

Data on the clinical observation of the patients after 6 months was available for 83 patients (33%) and only in 6% of the patients DEB treated lesion revascularization was performed, which is in concordance with the data from literature.

## Limitations

Obvious limits of this register are that it is retrospective and that there was no common protocol for monitoring all variables or the common protocol for later standardized patient observation. Due to this there is a whole set of data that is missing and that is of great importance for the technical part of the performance of DEB intervention which would be valuable in everyday practice: total number of predilatations and the length of these predilatations on treated lesions, types of balloons used in predilatations, the success of the predilatation, the percentage of patients who required "bail out stenting" and the reasons for this procedure (dissections, acute "recoil", unsuccessful predilatation), data on the treated lesion (frequency and the maximum diameter of stenosis pre and post intervention, AHA classification, length of the lesion).

There was no standardized clinical patient follow-up thus there was a small number of patients who were clinically ob-

snika koji su trebali *bail out stenting* i razlozi za ovu proceduru (disekcija, akutni *recoil*, neuspješna predilatacija), podatci o tretiranoj leziji (učestalost i maksimalni promjer stenozе prije i poslije intervencije, AHA-klasifikacija, dužina lezije).

Nije bilo standardiziranog kliničkog praćenja bolesnika te je stoga premalen broj bolesnika koji su klinički praćeni nakon 6 mjeseci i zbog čega je upitna vjerodostojnost podataka o učestalosti praćenih velikih nepovoljnih kliničkih događanja. Broj angiografski kontroliranih bolesnika je također malen, nije postojao angiografski „core“ laboratorij te za te bolesnike nedostaju važni podatci (kasni gubitak lumena, precizan postotak restenozе).

## Zaključak

Lijekom obloženi baloni u intervenciji na koronarnim krvnim žilama u Hrvatskoj se koriste u najvećem slučaju u prihvaćenim indikacijama *in-stent* restenozе, ali i u velikom postotku i za indikacije u kojima za primjenu te tehnologije ne postoji jasni konsenzus u literaturi.

Naše kliničko iskustvo u svakodnevnoj kliničkoj praksi pokazuje da je primjena DEB-a efikasna, s odličnim akutnim angiografskim rezultatima te kliničkim ishodima nakon šest mjeseci sa samo 6% reintervencija na tretiranoj leziji. Uporaba DEB-a je izrazito sigurna, praktički bez registrirane tromboze u 6 mjeseci u bolesnika liječenih samo balonom obloženim lijekom u bolesnika sa slikom stabilne ishemijske koronarne bolesti srca.

served after 6 months, and due to this the credibility of the data on the frequency of the monitored major adverse clinical events is questioned. The number of patients for whom angiographic monitoring was performed is also small, there was no “core” angiographic laboratory and there are important data missing for these patients (late lumen loss, precise percentage of re-stenosis).

## Conclusion

Drug-eluting balloons are used in interventions on coronary blood vessels in Croatia mostly in cases of accepted indications of *in-stent* re-stenosis, but also in great percentage for indications which in literature have no clear consensus for application.

Our clinical experience in everyday clinical practice shows that the use of DEB is efficient, with excellent acute angiographic results and with clinical results after 6 months with only 6% of re-intervention on the treated lesion. The use of DEB is highly safe, with practically no registered thrombosis in 6 months in the patients with stable ischemic coronary heart disease treated on with the drug-eluting balloons.

## LITERATURE

1. Prvulović Đ. Razlike u koncentraciji topive adhezijske molekule žilne stijenke-1 u bolesnika liječenih perkutanom balonskom dilatacijom s ugradnjom stenta i bolesnika liječenih balonom obloženim paklitakselom (disertacija). Osijek: Medicinski fakultet; 2013.
2. Cortese B., Berti S, Biondi-Zoccai G, et al. Drug-coated balloon treatment of coronary artery disease: a position paper of the Italian Society of Interventional Cardiology. *Catheter Cardiovasc Interv.* 2014;83(3):427-35.
3. Task Force on Myocardial Revascularization of the European Society of Cardiology (ESC) and the European Association for Cardio-Thoracic Surgery (EACTS); European Association for Percutaneous Cardiovascular Interventions (EAPCI). Wijns W, Kolh P, Danchin N, et al. Guidelines on myocardial revascularization. *Eur Heart J.* 2010;31(20):2501-55.
4. Kleber FX, Rittger H, Bonaventura K, et al. Drug-coated balloons for treatment of coronary artery disease: updated recommendations from a consensus group. *Clin Res Cardiol.* 2013;102(11):785-97.
5. Taylor J. Third universal definition of myocardial infarction. *Eur Heart J.* 2012;33:2506-7.
6. Cutlip DE, Windecker S, Mehran R, et al; Academic Research Consortium. Clinical end points in coronary stent trials: a case for standardized definitions. *Circulation.* 2007;115:2344-51.
7. Wöhrle J., Zadura M, Möbius-Winkler S, et al. SeQuentPlease World Wide Registry: clinical results of SeQuent please paclitaxel-coated balloon angioplasty in a large-scale, prospective registry study. *J Am Coll Cardiol.* 2012;60:1733-8.
8. Unverdorben M, Kleber FX, Heuer H, et al. Treatment of small coronary arteries with a paclitaxel-coated balloon catheter. *Clin Res Cardiol.* 2010;99:165-74.
9. Latib A, Colombo A, Castriota F, et al. A randomized multicenter study comparing a paclitaxel drug-eluting balloon with a paclitaxel-eluting stent in small coronary vessels: The BELLO (Balloon Elution and Late Loss Optimization) Study. *J Am Coll Cardiol.* 2012;60:2473-80.
10. Waksman R, Serra A, Loh JP, et al. Drug-coated balloons for de novo coronary lesions: results from the Valentines II trial. *Eurointervention.* 2013;9:613-9.
11. Mathey DG, Wendig I, Boxberger M, Bonaventura K, Kleber FX. Treatment of bifurcation lesions with a drug-eluting balloon: the PEPCAD V (Paclitaxel Eluting PTCA Balloon in Coronary Artery Disease) trial. *Eurointervention.* 2011;7(Suppl. K):K61-5.
12. Stella PR, Belkacemi A, Dubois C, et al. A multicenter randomized comparison of drug-eluting balloon plus bare-metal stent versus bare-metal stent versus drug-eluting stent in bifurcation lesions treated with a single-stenting technique: six-month angiographic and 12-month clinical results of the drug-eluting balloon in bifurcations trial. *Catheter Cardiovasc Interv.* 2012;80:1138-46.
13. Belkacemi A, Agostoni P, Nathoe HM, et al. First results of the DEB-AMI (drug eluting balloon in acute ST-segment elevation myocardial infarction) trial: a multicenter randomized comparison of drug-eluting balloon plus bare-metal stent versus bare-metal stent versus drug-eluting stent in primary percutaneous coronary intervention with 6-month angiographic, intravascular, functional, and clinical outcomes. *J Am Coll Cardiol.* 2012;59:2327-37.