

## SENTINEL LYMPH NODE CONCEPT AND ITS ROLE IN THE MANAGEMENT OF MELANOMA PATIENTS

Sunčica Andreja Rogan, Ksenija Kovačić and Zvonko Kusić

University Department of Oncology and Nuclear Medicine, Sestre milosrdnice University Hospital, Zagreb, Croatia

**SUMMARY** – Melanoma is still one of the most life threatening tumors throughout the world. In the United States of America, its mortality rate has raised by 191% in men and 84% in women in the past forty years. It is mainly a cancer of light-pigmented persons like European populations. The incidence and mortality rates have increased substantially during the past decade, although there are extreme variations in the melanoma rates among different countries. Cutaneous melanoma can spread unpredictably and widely through the lymphatics. Identification of patients with occult melanoma metastases is important for accurate staging, treatment planning and prognosis. Based on the AJCC Melanoma Database, the most important prognostic factor in overall survival is melanoma thickness, however, the revised staging system recognizes the presence of metastases in regional lymph nodes as an independent powerful prognostic factor in the 5-year survival rate in stage II and III. Melanoma has a variable lymphatic drainage pathway, particularly those lesions located in the trunk, head and neck. In the past 15 years, a novel approach has been introduced in the management of skin melanoma. As the result of modern nuclear medicine techniques, identification of sentinel lymph node (SLN) by lymphoscintigraphy (LS) and sentinel lymph node biopsy (SLNB) using hand held gamma probe has become a standard procedure. In the early stage disease (AJCC I and II) and intermediate tumor thickness (1.2-3.5 mm), LS with SLNB is the method of choice for nodal staging and to define further surgical procedure, although in melanoma thinner than 1 mm surgical management of regional lymph nodes is still controversial. The overall conclusion from more than 1500 articles published during the last decade is that LS followed by SLNB with selective lymph node dissection in patients with cutaneous melanoma is still only of prognostic value, although it identifies patients with nodal metastases whose survival can be prolonged by immediate lymphadenectomy. Therefore, the AJCC staging system continues to consider micrometastases detected only by immunohistochemistry or polymerase chain reaction to be N0 disease. This article brings a review of current concepts and utility of LS and SLNB in cutaneous melanoma.

**Key words:** *Lymphatic metastasis – pathology; Melanoma secondary; Sentinel lymph node; Melanoma pathology; Skin neoplasms – pathology; Lymph neoplasms – radionuclide imaging; Biopsy – methods, classification*

### Introduction

In all Caucasian populations there has been a rapid increase in the incidence of malignant melanoma and an increase in the mortality rate in the last decade<sup>1</sup>. In the United States of America, the mortality rate has

raised by 191% in men and 84% in women in the past forty years<sup>1</sup>. The current incidence rates vary throughout European countries from 6.8 in France to 15.9 in Norway<sup>2</sup>.

Melanoma may spread locally, regionally, and to distant sites. The pattern of lymphatic drainage is not predictable because of great variability of drainage pathways, especially those located on the skin of the head, neck and trunk. Early diagnosis along with accurate staging of the disease is essential for appropriate treatment decision making and, in turn, may give patients with melanoma the best chances for prolonged survival<sup>3</sup>.

Correspondence to: *Sunčica Andreja Rogan, MD*, University Department of Oncology and Nuclear Medicine, Sestre milosrdnice University Hospital, Vinogradska c. 29, HR-10000 Zagreb, Croatia  
E-mail: snovosel@kbsm.hr

Received February 12, 2007, accepted in revised form June 11, 2007

Staging of melanoma can be divided into three categories: clinical, histological and radiological. Staging based on objective histological features of tumors should be known before definitive therapy choice is made. Surgical excision is the treatment of choice for primary lesion in all patients, and there is no doubt in performing complete lymph node dissection in those patients with clinically obvious regional lymph node metastases. Thus, thin melanomas (<1.00 mm) are associated with localized disease and a cure rate of more than 95%, so randomized prospective clinical trials have not demonstrated therapeutic benefit in such patients undergoing elective lymph node dissection (ELND) instead of observation after wide excision<sup>4</sup>.

Patients who have intermediate-thickness primary melanoma (1.2-3.5 mm) have a risk of 40% of occult regional metastases, but only 20% of these patients have a risk of distant metastases<sup>5,6</sup>. In these patients ELND would provide therapeutic benefit<sup>6</sup>, although prospective randomized trials have failed to show an overall survival benefit for this group of patients undergoing ELND<sup>3-6</sup>. On the other hand, the majority of patients who have these lesions might have tumor-free regional nodes and therefore will be unnecessarily put at a risk of acute wound problems, chronic lymph edema, nerve injury, and anesthetic complications of ELND.

Patients with thick melanomas (>4 mm) besides a higher risk of regional nodal metastases are also associated with a higher risk of occult distant metastases (up to 70%)<sup>3,5</sup>, so in most cases distant metastatic spread of melanoma negates the benefit of surgical lymph node excision. Based on this information, the American Joint Committee on Cancer (AJCC) considered that it was important to separate patients who have occult from those who have clinically apparent nodal metastases in the staging classification<sup>6</sup>.

Additional clinical information and improved staging of melanoma patients were achieved upon the introduction of the sentinel lymph node concept in the early 1990s. Although the sentinel lymph node (SLN) hypothesis was born more than 20 years ago, successful lymphatic mapping using blue dye as well as sentinel lymphadenectomy was introduced for the first time in 1992 by Donald Morton and his group at John Wayne Cancer Institute<sup>7</sup>. In 1993, Alex *et al.*<sup>8</sup> used radioisotope for the first time for SLN mapping. Nowadays, preoperative lymphoscintigraphy (LS) plays a key role in determining lymphatic drainage pathways, the number and position of SLNs inside of particular nodal basins, and

locating aberrant, unusually placed SLN. Moreover, LS allows prediction of the metastatic status of the regional lymph node group. Therefore, in our institution LS and sentinel lymph node biopsy (SLNB) were established five years ago<sup>8</sup> as a standard procedure in the management of cutaneous melanoma according to the AJCC staging system<sup>3,10</sup>.

Involvement of nuclear medicine in surgery and oncology has changed diagnostic and therapeutic approach to patients with malignant melanoma and other solid tumors that metastasize *via* the lymphatic system.

### The Sentinel Lymph Node Concept

The diagnosis of lymph node metastases is important in malignancies, both for the choice of therapy and for prediction of prognosis. The patients with high risk primary melanoma (intermediate melanoma thickness, 1-4 mm, with ulcerations and Clark level IV) who are likely to benefit from early ELND are those with limited nodal metastases (up to 40%) and absent or minimal systemic spread ( $\approx$ 20% have a risk of distant metastases)<sup>5,6,11</sup>. So, it is of critical importance that the node examined by the pathologist is truly SLN.

### What is sentinel node?

Sentinel node is the first tumor-draining lymph node (or nodes) on the way of tumor primary site directly to

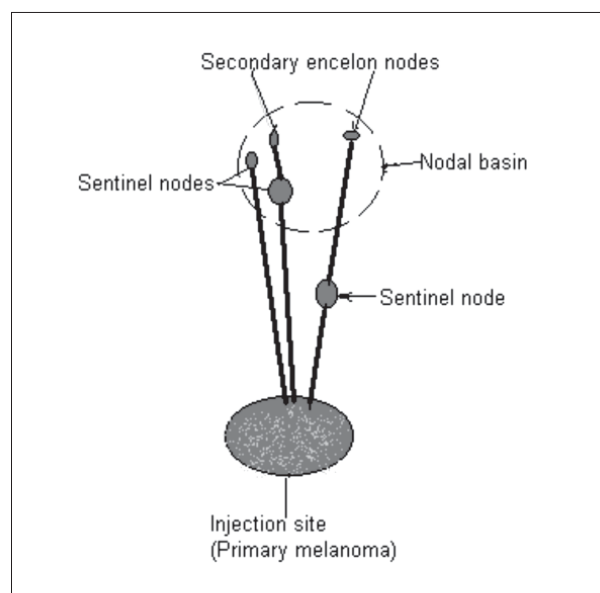


Fig. 1. Schematic presentation of injection site in relation to nodal basin and sentinel nodes.

its associated regional lymph node field(s) (Fig. 1). The sentinel node hypothesis also presumes that this particular node represents the status of the entire regional lymphatic basin. Thus, tumor negative SLN virtually excludes the presence of lymphatic metastases in all other lymph nodes inside of same lymph basin<sup>12,13</sup>.

## History

Lymphatic studies leading to the sentinel node hypothesis and selective lymphadenectomy were initiated over 20 years ago. In the mid-1970s, Cabanas<sup>14</sup> used the term 'sentinel node' in penile cancer to indicate a node detected by lymphangiography in a fixed anatomic location. Although Cabanas proposed sentinel node as the node most likely to contain tumor cells metastasizing from the primary lesion, the fixed anatomic site proposed by Cabanas contradicted Morton's<sup>15</sup> SLN concept introduced in 1977. This group described the use of cutaneous lymphatic mapping by using dyes to identify the lymph node basins at a risk of metastases from truncal primary melanoma. The 1980s brought improved techniques for pathological evaluation of regional lymph nodes: Cochran<sup>16</sup> introduced serial sectioning of lymph nodes and immunohistochemical staining using antibodies. Further investigation by Morton's group was done in 1990, when they started a multicenter trial to evaluate the clinical technique presented to the Society of Surgery and Oncology<sup>17</sup>. The technique included preoperative LS, intraoperative mapping by using gamma probe and blue dye, and SLNB. Despite good results demonstrated by this investigation, there were a lot of doubts about the accuracy and utility of the whole procedure. In 1992, after multiple revisions, this report was published<sup>7</sup>, and a new era in minimal invasive surgery has begun.

The SLN concept and success rate of SLNB lie on the multidisciplinary approach shown in Table 1, but the learning period is crucial in establishing LS and SLNB as a standard procedure.

## Lymphoscintigraphy

Because the SLN concept implies the orderly progression of metastases from primary tumor to a single draining node in the relevant lymph node basin, lymphoscintigraphy has become a standard preoperative procedure for functional identification of this node in melanoma patients<sup>18</sup>. Preoperative LS is used for navigation of the surgeon to the exact location of SLNs. It allows for identification of SLN in traditional nodal basins but also SLN lying outside the anatomically expected nodal basin or an aberrant SLN.

## Radiopharmaceuticals

<sup>99m</sup>Tc sulfur colloid and <sup>99m</sup>Tc antimony trisulfide colloid (19-23) have been used as primary radiopharmaceuticals (RF) for SLN visualization and mapping followed by application of human serum albumin<sup>22,24</sup>. In Europe, the predominant RF is <sup>99m</sup>Tc nanocolloid<sup>25-27</sup>. Although several of these agents have been used with variable success, there is no consensus agreement on the radiopharmaceutical of choice for LS<sup>28,29</sup>. Nowadays, all agents labeled with <sup>99m</sup>Tc could be used because of its physical characteristics, but a number of other agents are being developed for LS such as <sup>67</sup>Ga citrate, monoclonal antibodies labeled with <sup>111</sup>In, <sup>131</sup>I, and <sup>125</sup>I<sup>28</sup>.

The most important criteria for an RF are rapid flow from the injection site through the lymphatic vessels, and localization and retention within SLN with a radiation dose as low as possible.

Table 1. Multidisciplinary approach to the patient with skin melanoma

Specialty	Role
Dermatology	Screening and prevention Excision of primary melanoma
Surgery	Sentinel lymph node biopsy Management of local recurrences Management of distant metastases
Pathology	Prognostication including microstaging (H&E staining, immunohistochemistry) Molecular diagnosis of melanoma (microarray techniques, RT-PCR)
Nuclear medicine	Preoperative lymphoscintigraphy and SLN (in-transit node) identification
Oncology	Diagnosis, local and systemic treatment of metastases

The optimal particle size is still controversial: larger particles (500 nm) show a much slower rate of migration and significantly lower accumulation rate in the lymph node; they are also retained primarily at the injection site<sup>28-30</sup>. Smaller particles (<50 nm) pass rapidly through lymphatics and thereby many other lymph nodes are shown within the basin. The number of injected particles also influences the rate of outflow from the injection site and phagocytosis within the lymph nodes.

### The technique of lymphoscintigraphy

Radiopharmaceutical is injected intradermally around the melanoma or scar from local excision. Approximately 18.5-30 MBq of <sup>99m</sup>Tc nanocolloid in a total volume of 0.5-1.0 mL are divided into several injection sites (depending on the lesion size). The study should be performed at comfortable room temperature, not less than 20 °C, because of appropriate lymph flow. The patient should be warned not to move during each injection, to minimize the risk of isotope spill around the field of investigation. Also, the physician commencing the injection should be very careful during the tracer manipulation to reduce the possible contamination of the patient or gamma camera, which can give false results in the identification of SN.

Scintigraphic images are obtained with a large field of view, low energy, all-purpose collimated digital camera, with matrix size 128x128. The camera is positioned to image tumor site and contiguous nodal basins. Dynamic monitoring (10 frames/60 seconds) over the injection sites and node basins is crucial in SLN visualization in patients with melanoma<sup>31,32</sup>. Dynamic imaging is followed by static imaging (5 minutes/view) in different position. Dynamic and static images are analyzed to determine transit times to the SLN, lymph channel visualization, the exact position and number of SLNs, and an aberrant LN. Delayed scans, two or more hours after the injection of RF, detect unknown SN relatively seldomly, but in this case when a faint node is seen it is by definition an SLN<sup>19,21,31,33</sup>. However, these images give often more information about non-sentinel lymph node.

Once all the images are done, in order to assist the surgeons in locating the SN during biopsy, the exact position of the SLN is preoperatively marked on the overlaying skin using <sup>57</sup>Co pen and gamma camera guidance. All recorded SLNs could be checked again with a hand-held gamma probe (Fig. 2). For proper intraopera-

tive mapping of SLN using radionuclide, preoperative LS should not be done more than 24 hours before surgery<sup>33,34</sup>.

### Patterns of Lymphatic Drainage

The pattern of lymphatic drainage is sometimes clearly predictable, i.e. melanoma situated on the limb, but melanoma on the trunk, the head and neck has huge patient-to-patient lymphatic drainage variability<sup>12,13,19,33,35</sup>. Lymphoscintigraphy is therefore the only reliable method to define SLNs and the draining node field or fields, so that appropriate surgical intervention could be performed.

Apart from SLN, on LS interval nodes may be found that are lymph nodes draining a tumor site that lie between the tumor site and recognized node field. By definition these interval nodes are SLNs and they have the same likelihood of containing micrometastases as SLN that lie in standard lymphatic basin (36). In-transit lymph nodes also lie along the lymphatic drainage vessels, but they receive less radiocolloid than SLN in drainage basin, and SLNB should be performed on both SLN and in-transit or interval nodes.

Lymphatic "lakes" present localized dilatation of the lymphatic vessels that can occur at any point along the lymphatic pathways from the tumor to the lymph node basin. They should not be confused with in-transit or interval nodes that persist on early and delayed scan. On the contrary, lymphatic lakes disappear on the delayed scans.

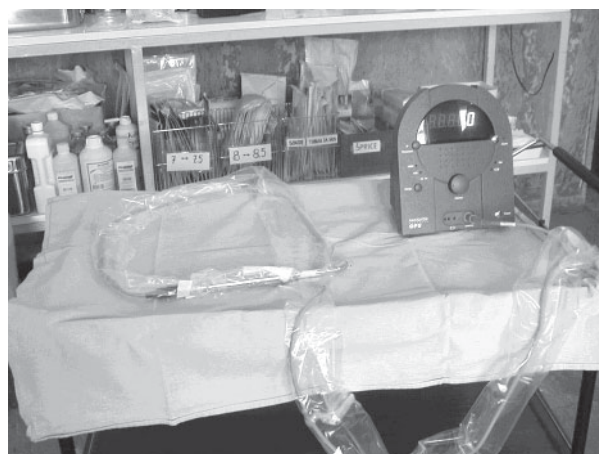

Fig. 2. Hand-held gamma probe with sterile intraoperative drape.



## Head and neck

In the past, guidelines have suggested that the main drainage pathways from the face and anterior scalp are to ipsilateral parotid and level I to III cervical nodes (Fig. 3A,B) and from posterior scalp to occipital and level II to V cervical nodes<sup>37</sup>. Drainage from the coronal midline is to parotid and cervical level I to V, from anterior upper neck lymph would be expected to drain to parotid and level I to IV, and from anterior lower neck lymph would be expected to drain to level III to V<sup>37</sup>.




Fig. 3. (A) Static scans of left supraorbital melanoma (large spot). One sentinel is seen in the left parotid (a smaller spot inside the circle); (B) Static scan of left lateral view 15 minutes after radiopharmaceutical injection: 1 – primary melanoma site; 2 – SLN in the left parotid; 3 – secondary lymph nodes – non-sentinel nodes, ipsilateral submental position; D – right of the head, L – left of the head, AP-D – anterior scan of the head and neck.

After the introduction of LS it was obvious that lymphatic drainage was discordant with clinical prediction, so unusual and aberrant lymph (Fig. 4) node fields with SLN could be expected for each melanoma on the head and neck<sup>38,39</sup>.

However, it should be stressed that SLN at the head and neck could lie very close to the injection site, which presents a problem for surgeon and SLN mapping. This is a field where LS should be performed very carefully

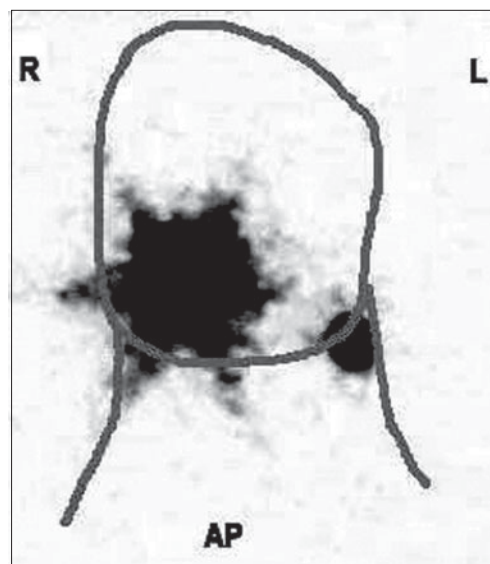


Fig. 4. Aberrant sentinel lymph node. Large spot represents radiopharmaceutical injection site around excision wound from the melanoma on the right cheek. Smaller spot represents the sentinel lymph node on the left part of the neck; D – right; L – left.

and dynamic imaging is crucial for identification of SLN because of rapid flow of RF to the secondary lymph node basin (Fig. 3A).

## Limbs

On LS, most skin melanomas have a predictive lymph node drainage basin, from upper limb to axilla, and from lower limb to groin<sup>4,6,35,40</sup>. Lymphatic drainage from forearm almost exclusively leads to the axilla<sup>5,6,35</sup>.

Sometimes, the SLN from the upper part of the arm could be epitrochlear node, cervical node, or an interval node that means one node along lymphatic pathway without SLN in nodal basin (19,20,41). Rarely, lymphatic drainage from the upper part could be directly to supraclavicular nodes. Some investigators found drainage from primary melanoma of the arm to an aberrant site like interpectoral or infraclavicular nodes<sup>3,42</sup>.

Drainage pathways from the lower limb usually progress up to the groin medially, laterally or on both sides of the leg<sup>23-25,40</sup>. The number of SLNs in the groin varies from one to several, as is the case with excessive number of secondary lymph nodes, so dynamic study should be monitored carefully in this case (25). Although almost all drainage from skin melanoma of the leg goes to the groin, delayed scan over popliteal fossa is needed to check for SLN or in-transit nodes (Fig 5).

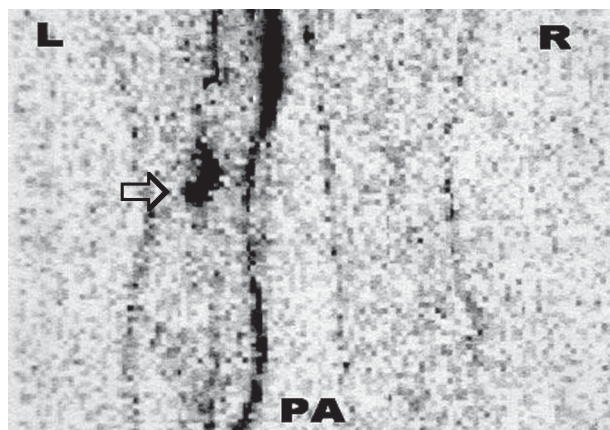


Fig. 5. Lymphoscintigraphy of the melanoma of the left calf. Lymphatic drainage passes to the left groin where one SLN was found, but in the left popliteal fossa two in-transit nodes (circle) were seen, which also represented SLNs in this case; L- left leg, R- right leg, PA - posterior view.

## Trunk

As in the head and neck melanomas, LS for tumors situated at the trunk, which are expected to have unpredictable or ambiguous lymphatic drainage, is most useful for determination of sentinel node and drainage field or fields. The drainage pattern from melanoma at the trunk depends on the primary tumor location<sup>35,42</sup>. It is important to keep in mind that melanoma from anterior or posterior trunk, above umbilicus or waist, and also below umbilicus or waist could have multiple node fields draining a single site melanoma (Fig. 6). Sometimes different camera views, collimation and transmission scans or marking the surface location are needed to clarify complex lymphatic drainage patterns. In our institution, a nuclear medicine physician and a surgeon discuss LS for each patient before operation, with a high identification rate of SLN as the result<sup>9</sup>. Drainage to an unusual field, i.e. in the triangular intermuscular space, subscapular, or to paravertebral nodes is not a rare occasion, therefore careful monitoring during dynamic phase is crucial for proper SLN identification<sup>8,11,18,42</sup>. Drainage pathways across the midline are quite frequent from the posterior trunk, although it can also be seen at anterior trunk<sup>35,43</sup>. Interval nodes or in-transit nodes are most common in the subcutaneous tissue at anterior trunk along the pass to the axilla, or on the posterior trunk on the lateral chest wall or on the upper back<sup>35,36</sup>.

## The Sentinel Lymph Node Biopsy Technique

### Patient selection criteria

Initially, patient selection criteria<sup>44,45</sup> for LS and SLNB included those patients whose melanomas were at least 1.0 mm thick or had Clark level IV depth of invasion<sup>10</sup>. The indications for the procedure have been expanded and include patients with thinner melanomas, especially those with evidence of regression, ulceration, or positive deep margins<sup>10,46,47</sup>. Contraindications to SLNB include histologically confirmed, clinically positive lymph nodes and previous extensive surgery at the primary site or in transit to the nodal basin, including prior rotational flaps, Z-plasties, or skin grafts, that would make SLNB inaccurate<sup>46</sup>. SLNB should not be undertaken if the prognostic information will not change the clinical management, as may be the case for extreme elderly patients or those with more significant comorbid conditions<sup>3</sup>.

### Technique

Initial SLN localization studies used an intraoperative injection of a lymphatic dye alone<sup>7</sup>. Later, several centers have modified the technique of SLN biopsy to include the use of <sup>99m</sup>Tc-labeled radiopharmaceuticals

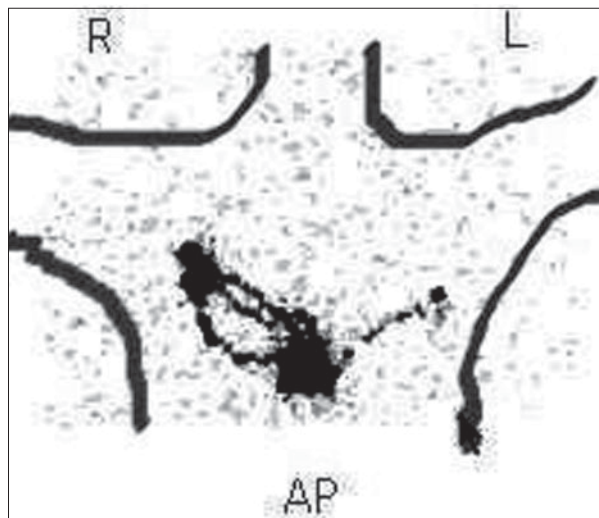


Fig. 6. Multiple drainage basins from melanoma of the chest. The largest spot is the injection place of radiopharmaceutical around primary melanoma. In the right axilla two sentinel nodes were found with three different lymphatic pathways, whereas in the left axilla one sentinel node is seen with its own pathway; R- right axilla, L- left axilla, AP - anterior-posterior view.

Table 2. Identification rate of sentinel lymph nodes by radiotracer and/or blue dyes

First author	Region	Cases	Percentage of patients with successfully detected SLN using blue dye/blue-dye and probe	Percentage of patients with metastases in SLN
Krag (48)	all	121	91-98	12.0
Bostic (50)	head/ neck	117	92-96	12.0
Kapteijin (51)	all	60	78-99.1	16.6
Alex (52)	head/ neck	23	75-96	12.0
Gogel (53)	all	68	100	9.0
Morton (54)	all	1140	95-97	15-26
Wagner (55)	all	275	99.4	19.6
Rasgon (38)	head/ neck	27	92.0	27.0
Jacobs (56)	all	103	99.1	10.0

SLN, sentinel lymph node

and intraoperative use of hand-held gamma probe. Such an approach permits the surgeon to identify transcutaneously with greater precision the localization of the SLN within the nodal basin. Thereby, it can reduce the size of the incision and extent of dissection necessary to identify SLNs<sup>48,49</sup>. Table 2 shows some of the results of intraoperative identification of the SLN with blue dye alone and/or in combination with hand-held gamma probe. Lymphatic mapping performed with blue dye plus gamma probe was more successful (92%-100%) than lymphatic mapping with blue dye alone (78%-95%)<sup>49-55</sup>. It is obvious that LS, blue dye and gamma probe detection of radioactive tracers in combination are most sensitive for intraoperative identification of SLNs. The results from the study performed in Croatian Melanoma Center (9) confirm the high accuracy of lymphatic mapping by isotope alone.

The recommended surgical procedure to achieve high accuracy of SLNB nowadays includes preoperative LS, lymphatic mapping using radiopharmaceutical and/or blue dye (0.5-1.0 mL) injection intradermally around the primary site or biopsy wound<sup>18,46,56-58</sup>.

Skin mark over a SLN should be verified with gamma probe before incision, and the number of counts should also be measured at other sites within the same lymph node basin to establish the background activity. A small incision of a few centimeters could be made and the blue stained lymphatic channels are searched and SLN traced with gamma probe on the basis of scin-

tigraphy. The SLN harvest is considered complete when radiotracer uptake in the draining nodal basin(s) is less than twice background. Also, all patients should undergo wide local excision of the primary melanoma site. After removing SLNs, wound should be scanned again, as well as extirpated SLN. Finally, the excised specimen is referred to a pathologist. Complete lymph node basin dissection should be performed when metastases or micrometastases are present. Patients in whom the SLN is histologically or immunohistologically negative undergoes no additional operation.

### Radiation Dosimetry

The risk of radiation exposure to the patient depends on the site of primary melanoma and the rate of clearance of radiocolloid from the points of injection. Namely, clearance of colloid particle from the interstitial space is quite slow, so there is a significant radiation dose delivered to the injection site, but this becomes irrelevant because of the excision of this tissue within the next 24 hours during the standard melanoma wide local excision technique<sup>59</sup>.

Using the protocol described, the surgeon or pathologist handling the specimens receives minimal radiation dose, especially when SLNB is performed the day after lymphoscintigraphy, when several physical half-lives for <sup>99m</sup>Tc have expired. In case when surgery is performed within 3-4 hours after isotope injection, the surgeon will receive a small dose of radiation. The cal-

culatation is made assuming the injection dose of 40 MBq (one procedure) and surgeon handling the injection site for 15 minutes. He will receive a radiation dose of 1850  $\mu\text{Sv}$  to the hand and up to 2  $\mu\text{Sv}$  to the torso<sup>60-63</sup>. This means that the surgeon could perform 270 procedures a year before the limit dose to the hand would be exceeded (64). Namely, some investigations<sup>60,61</sup> showed that surgeon's hand will be exposed to 0.2% of annual whole-body dose received by humans from the natural background and cosmic sources (approximately 4 to 6  $\mu\text{Sv}$ )<sup>64</sup>. Even the risk to pregnant staff is below the yearly recommended whole-body radiation dose of 2000  $\mu\text{Sv}$ <sup>64</sup>.

The SLN receives about 2% to 5% of the dose injected intradermally for lymphoscintigraphy, so the histopathologist performing frozen section examination would receive to one-sixteenth of the above doses calculated for the surgeons<sup>62</sup>.

## Conclusion

Many investigators have shown that LS and SLNB can be successfully learned and are safe procedures with a high accuracy (almost 100%) in early-stage melanoma. For an accurate identification of SLN, close collaboration of surgeons, nuclear medicine physicians, and pathologists is also mandatory.

A comparative survival and recurrence study has confirmed the method as an important part of the pathological classification of melanoma stage IIA, IIB and stage III in the AJCC staging system<sup>3</sup>. Lymphoscintigraphy and SLNB provide a safe and even cost-effective care for patients with early-stage melanoma.

Currently, indications for LS and SLNB include intermediate melanoma thickness (1.2-3.5 mm) without clinical evidence of regional or distant metastases. For thin melanoma (=1 mm, T1) SLNB should be considered because the incidence of positive SLNs in these patients is close to 5%<sup>46,47</sup>.

Problems with SLNB in melanoma patients were the false-negative rate of about 5%, the possibility of an increased risk of in-transit metastases in SLNB-positive patients, and minor postoperative complications in about 10% of cases<sup>65</sup>. These must be kept in mind when offering patients SLNB.

The final important issue regarding SLN concept involves the question of prognostic significance and survival advantage for this technique<sup>66,67</sup>. Morton *et al.*<sup>65</sup> report that to date, there is no difference in survival

between wide local excision (WLE) and observation group *versus* the WLE and SLNB group. Encouraging information is that the 5-year survival rate is about 90% for patients with tumor free SLN while this rate for patients with involved nodes is about 60%<sup>10,68,66</sup>.

Also, patients with SLNB followed by complete lymph node dissection for metastases had a better disease-free survival compared to patients with WLE and/or observation<sup>65</sup>.

Additionally, certain factors predicting tumor-containing lymph node have been identified (ulceration, age, sex, number of metastatic lymph nodes ...) but none of these factors could be 100% accurate<sup>47,68,69</sup>.

Recently published data support immediate lymphadenectomy in patients with nodal metastases according to the results of SLNB, while 18% experienced improvement in survival compared with patients who developed palpable adenopathy after treatment with excision of the primary tumor and nodal observation<sup>70,71</sup>.

Finally, for overall survival the most powerful factor is Breslow thickness whereas SLN status is an independent factor for disease-free survival, although longer follow up studies are needed for any definitive conclusions.

## References

1. American Cancer Society. ACS key statistics 2006. How many people get melanoma skin cancer? Available at: [http://www.cancer.org/docroot/stt/stt\\_0.asp](http://www.cancer.org/docroot/stt/stt_0.asp). Accessed April 24, 2006.
2. Available at: <http://www-dep.iarc.fr/globocan/globocan.html>
3. BALCH CM, SOONG SJ, GERSHENWALD JE, THOMPSON JF, REINTGEN DS, CASCINELLI N *et al.* Prognostic factor analyses of 17600 melanoma patients: validation of American Joint Committee on cancer melanoma staging system. *J Clin Oncol* 2001;19:3622.
4. VERONESI U, ADAMUS J, BANDIERA D. Inefficacy of immediate node dissection in stage I melanoma of the limbs. *N Engl J Med* 1997;297:627-30.
5. SIM F, TAYLOR W, IVINS J, PRITCHARD D, SOULE E. A prospective randomized study of the efficacy of the routine elective lymphadenectomy in management of malignant melanoma. Preliminary results. *Cancer* 1978;41:948-56.
6. BALCH CM, SOONG SJ, BARTOLUCCI AA, URIST MM, KARAKOUSIS CP, SMITE JJ *et al.* Efficacy of a regional lymph node dissection of 1 to 4 mm thick melanomas for patients 60 years of age and younger. *Ann Surg* 1996;224:225-63.
7. MORTON DL, WEN DR, WONG JH, ECONOMOW J, CAGLEL, STORM F. Technical details of intraoperative lymphatic mapping for early stage melanoma. *Arch Surg* 1992;127:392-9.
8. ALEX JC, WEAVER DL, FAIRBANK JT, RANKIN BS, KRAG DN. Gamma probe guided lymph node localisation in malignant melanoma. *Surg Onkol* 1993;2:303-8.
9. VUCETIC B, ROGAN SA, BALENOVIC A, IVKIC M, SITUM M, HUDOROVIC N, KUSIC Z. The role of preoperative lym-



- phoscintigraphy in surgery planning for sentinel lymph node biopsy in malignant melanoma. *Wien Klin Wochenschr* 2006;9-10:286-93.
10. BALCH CM, SOONG SJ, ATKINS MB, BUZAID AC, CASCINELLI N, COIT DG *et al.* An evidence-based staging system for cutaneous melanoma. *CA Cancer J Clin* 2004;54:131-49.
  11. SHEN J, WALLACE AM, BOUVET M. The role of sentinel node biopsy for melanoma. *Semin Oncol* 2002;29:341-52.
  12. BERK DR, JOHNSON DL, UZIEBLO A, KIERNAN M, SWETTER SM. Sentinel lymph node biopsy for cutaneous melanoma: the Stanford experience, 1997-2004. *Arch Dermatol* 2005;141:1016-22.
  13. MORTON DL, WEN DR, FOSHAG LJ, ESSNER R, COCHRAN A. Intraoperative lymphatic mapping and selective cervical lymphadenectomy for early stage melanoma of the head and neck. *J Clin Oncol* 1993;11:1751-6.
  14. CABANAS RM. An approach for the treatment of penile carcinoma. *Cancer* 1977;39:456-66.
  15. HOLMES EC, MOSELEY HS, MORTON DL, CLARK W, ROBINSON D, URIST MM. A rational approach to the surgical management of melanoma. *Ann Surg* 1977;186:481-90.
  16. COCHRAN AJ, WEN DR, HERSCHMAN JR. Occult melanoma in lymph nodes detected by antiserum S-100 proteins. *Int J Cancer* 1984;34:159-63.
  17. MORTON D, CAGLE L, WONG J. Intraoperative lymphatic mapping and selective lymphadenectomy: technical details of a new procedure for clinical stage I melanoma. Presented at the Annual Meeting of the Society of Surgical Oncology, Washington, DC, March 1990.
  18. CHEN SL, IDdings DM, RANDALL P, BILCHIK S, BILCHIK P. Lymphatic mapping and sentinel node analysis: current concepts and application. *CA Cancer J Clin* 2006;56:292-309.
  19. UREN RF, HOWMAN-GILES R, THOMPSON JF, SHAW HM, QUINN MJ, O'BRIEN CJ, McCARTHY WH. Lymphoscintigraphy to identify sentinel lymph node in patients with melanoma. *Melanoma Res* 1994;4:395-9.
  20. GLASS L, MESSINA J, CRUSE W *et al.* The use of intraoperative lymphoscintigraphy for sentinel node biopsy in patients with malignant melanoma. *Dermatol Surg* 1996;22:715-20.
  21. MEYER CM, LECKLITNER ML, LOGIC JR. <sup>99m</sup>Tc sulfur colloid cutaneous lymphoscintigraphy in the management of truncal melanoma. *Radiology* 1979;131:205-9.
  22. SADEK S, OWUNWANNE A, ABDEL-DAYEM HM. Preparation and evaluation of <sup>99m</sup>Tc hydroxyethyl starch as a potential radiopharmaceutical for lymphoscintigraphy: comparison with <sup>99m</sup>Tc human serum albumin, <sup>99m</sup>Tc dextran, and a sulfur microcolloid. *Lymphology* 1989;22:157-66.
  23. GERSHENWALD JE, TSENG C, THOMPSON W, MANSFIELD PF, LEE JE, BOUVET MM *et al.* Improved sentinel lymph node localization in patients with primary melanoma with the use of radiolabeled colloid. *Surgery* 1998; 124:203-10.
  24. BEDROSIAN I, SCHEFF AM, MICK R, MICK M, CALLANS LS, BUCKY LP *et al.* <sup>99m</sup>Tc-Human serum albumin: effective radiotracer for identifying sentinel nodes in melanoma. *J Nucl Med* 1999;40:1143-8.
  25. PIJPERS R, COLLET GJ, MEIJER S, HOEKSTRA OS. The impact of dynamic lymphoscintigraphy and gamma probe guidance on sentinel node biopsy in melanoma. *Eur J Nucl Med* 1995;22:1238-41.
  26. PIJPERS R, MEIJER S, HOEKSTRA OS. Impact of lymphoscintigraphy on sentinel node identification with <sup>99m</sup>Tc-colloidal albumin in breast cancer. *J Nucl Med* 1997;38:366-8.
  27. WILHELM AJ, MIJNHOUT GS, FRANSSSEN EJ. Radiopharmaceuticals in sentinel node detection – an overview. *Eur J Nucl Med* 1999;26(Suppl):S36-S42.
  28. ESHIMA D, FAUCONNIER T, ESHIMA L, THORNBACK JR. Radiopharmaceuticals for lymphoscintigraphy: including dosimetry and radiation considerations. *Semin Nucl Med* 2000;30:25-32.
  29. GLASS EC, ESSNER R, MORTON DL. Kinetics of three lymphoscintigraphic agents in patients with cutaneous melanoma. *J Nucl Med* 1998;39:1185-90.
  30. BERQUIST L, STRAND SE, PERSSON BR. Particle sizing and biokinetics of interstitial lymphoscintigraphic agents. *Semin Nucl Med* 1983;13:9-19.
  31. TAYLOR A, MURRAY D, HERDA S, VANSANT J, ALAZRAKI N. Dynamic lymphoscintigraphy to identify the sentinel and satellite nodes. *Clin Nucl Med* 1996;21:755-8.
  32. BERMAN C, CHOI J, HERSH MR, CLARK RA. Melanoma lymphoscintigraphy and lymphatic mapping. *Semin Nucl Med* 2000;30:49-55.
  33. CASCINELLI N, MORABITO A, SANTINAMI M, MacKIE RM, BELLI F. Immediate or delayed dissection of regional nodes in patients with melanoma of the trunk: a randomized trial. *WHO Melanoma Programme. Lancet* 1998;351:793-6.
  34. KROPP J, STEIN A, HACKERT I, SEBASTIAN G, MAURER M, GRUNING T, LIEPE K *et al.* Accuracy of the intraoperative radioguided localization of the sentinel lymph node (SNL) 24 hours after lymphoscintigraphy in patients with malignant melanoma. *Nuclearmedizin* 2001;40:86-90.
  35. UREN RF, HOWMAN-GILES R, THOMPSON JF, QUINN MJ. Direct lymphatic drainage from the skin of the forearm to a supraclavicular node. *Clin Nucl Med* 1996;21:387.
  36. UREN RF, HOWMAN-GILES R, THOMPSON JF, McCARTHY WH, QUINN MJ, ROBERTS JM, SHAW HM. Interval nodes: forgotten sentinel nodes in patients with melanoma. *Arch Surg* 2000;135:1168-72.
  37. O'BRIEN CJ, PETERSEN-SHAEFER K, RUARK D, COATES AS, MENZIE SJ, HARRISON RI. Radical, modified and selective neck dissection for cutaneous malignant melanoma. *Head Neck* 1995;17:232.
  38. RASGON BM. Use of low-dose <sup>99m</sup>Tc sulfur colloid to locate sentinel lymph nodes in melanoma of the head and neck: preliminary study. *Laryngoscope* 2001;111:1366-77.
  39. PATHAK I, O'BRIEN CJ, PETERSEN-SHAEFER K, McNEIL EB, McMACHON J, QUINN MJ *et al.* Do nodal metastases from cutaneous melanoma of the head and neck follow clinically predictable pattern. *Head Neck* 2001;23:785.
  40. LAI DTM, THOMPSON JF, QUINN MJ, INGVAR C, UREN R, HOWMAN-GILES R *et al.* New route for metastatic spread of melanoma. *Lancet* 1993;341:302.
  41. UREN RF, HOWMAN-GILES R, THOMPSON JF, QUINN MJ. Direct lymphatic drainage from the skin of the forearm to a supraclavicular node. *Clin Nucl Med* 1996;21:387.
  42. UREN RF, HOWMAN-GILES R, SHAW HM, THOMPSON JF, McCARTHY WH. Lymphoscintigraphy in high-risk melano-

- ma of the trunk. Predicting draining node groups, defining lymphatic channels and locating the sentinel node. *J Nucl Med* 1993;34:1435-40.
43. UREN RF, HOWMAN-GILES R, THOMPSON JF, QUINN MJ, O'BRIEN CJ, SHAW HM *et al.* Lymphatic drainage to triangular intermuscular space lymph nodes in melanoma on the back. *J Nucl Med* 1996;37:964-70.
  44. COCHRAN AJ, BALDA BR, STARZ H, BACHTER D, KRAG DN, CRUSE CW, PIJPERS R, MORTON DL. The Augsburg Consensus: Techniques of lymphatic mapping, sentinel lymphadenectomy, and completion lymphadenectomy in cutaneous malignances. *Cancer* 2000;89:236-41.
  45. MULLER MG, van LEEUWEN PA, van DIEST PJ, VUYL-STEKE RJ, PIJPERS J, MEIJER S. No indication for performing sentinel node biopsy in melanoma patients with a Breslow thickness of less than 0.9 mm. *Melanoma Res* 2001;11:303-7.
  46. MORTON DL, COCHRAN AJ, THOMPSON JF, ELASHOFF R, ESSNER R, GLASS EC *et al.* Sentinel node biopsy for early-stage melanoma. Accuracy and morbidity in MSLT-I, an international multicenter trial. *Ann Surg* 2005;242:302-13.
  47. NIEWEG OE, van RIJK MC, VALDES OLMOS RA, HOEF-NAGEL CA. Sentinel node biopsy and selective lymph node clearance – impact on regional control and survival in breast cancer and melanoma. *Eur J Nucl Med Mol Imaging* 2005;32:631-4.
  48. KRAG D, MEIJER S, WEAVER D, LOGGIE B, HARLOW S, TANABE K, LAUGHLIN E, ALEX J. Minimal-access surgery for staging of malignant melanoma. *Arch Surg* 1995;130:654-8.
  49. KAPTEIJN B, NIEWEG O, LIEM I, MOOI W, BALM A, MULLER S. Localisation of sentinel node in cutaneous melanoma: gamma probe detection *versus* blue dye. *Ann Surg Oncol* 1997;4:156-60.
  50. BOSTIC P, ESSNER R, SARANTOU T, KELLY M, GLASS E, FOSHAG L, STERN S, MORTON D. Intraoperative lymphatic mapping for early stage melanoma of the head and neck. *Am J Surg* 1997;174:536-9.
  51. KAPTEIJN B, NIEWEG O, MULLER S, LIEM I, HOEF-NAGEL C, RUTGERS E, KROON ???. Validation of gamma probe detection of the sentinel node in melanoma. *J Nucl Med* 1997;38:362-6.
  52. ALEX JC, KRAG DN, HARLOW SP, MEIJER S, LOGGIE BW, KUHN J, GADD M, WEAVER DL. Localisation of regional lymph nodes in melanomas of the head and neck. *Arch Otolaryngol Head Neck Surg* 1998;124:826-30.
  53. GOGEL B, KUHN J, FERRY K, FISHER T, PRESKITT J, O'BRIEN J, LIEBERMAN Z, STEPHENS J, KRAG D. Sentinel lymph node biopsy for melanoma. *Am J Surg* 1998;176:544-7.
  54. MORTON D, THOMPSON J, ESSNER R, ELASHOFF R, STERN S, NIEWEG O, ROSES D, KARAKOUSIS C, REINTGEN D, WANG H, GLASS E, COCHRAN A, and Multicenter Selective Lymphadenectomy Trial Group. Validation of the accuracy of intraoperative lymphatic mapping and sentinel lymphadenectomy for early stage melanoma. A multicenter study. *Ann Surg* 1999;230:453-65.
  55. WAGNER J, GORDON M, CHUANG T, COLEMAN III J, HAYES J, JUNG S, LOVE C. Predicting sentinel and residual lymph node basin disease after sentinel node biopsy for melanoma. *Cancer* 2000;89:453-62.
  56. JACOBS IA, CHEVINSKY AH, SWAYNE LC, MAGIDSON JG, BRITTO EJ, SMITH TJ. Gamma probe directed lymphatic mapping and sentinel lymphadenectomy in primary melanoma: reliability of the procedure and analysis of failures after long-term follow-up. *J Surg Oncol* 2001;77:157-64.
  57. MORTON D. Lymphatic mapping and sentinel lymphadenectomy for melanoma: past, present, and future. *Ann Surg Oncol* 2001;8:22-8.
  58. ESSNER R, BOSTIC PJ, GLASS EC, FOSHAG LJ, HAIGH PI, WANG HJ, MORTON DL. Standardized probe-directed sentinel node dissection in melanoma. *Surgery* 2000;127:26-31.
  59. BRONSKILL MJ. Radiation dose estimates for interstitial radiocolloid lymphoscintigraphy. *Semin Nucl Med* 1983;13:20.
  60. AZARAKI NP, STYBLO T, GRANT SF, COHEN C, LARSEN T, AARSVOLD JN. Sentinel node staging of early breast cancer using lymphoscintigraphy and the intraoperative gamma-detecting probe. *Semin Nucl Med* 2000;30:56-64.
  61. SERA T, MOHOS G, PAPOS M, OSVAY M, VARGA J, LAZAR M *et al.* Sentinel node detection in malignant melanoma patients: radiation safety considerations. *Dermatol Surg* 2003;29:141-5.
  62. KLAUSEN TL, CHAKERA AH, FRIIS E, RANK F, HESSE B, HOLM S. Radiation doses to staff involved in sentinel node operations for breast cancer. *Clin Physiol Funct Imaging* 2005;25:196-202.
  63. NEJC D, WRZESIEN M, PIEKARSKI J, OLSZEWSKI J, PLUTA P, KUSMIERK J, JEZIORSKI A. Sentinel node biopsy in skin melanoma patients – measurements of absorbed doses of radiation to the hands of medical staff. *J Surg Oncol* 2006;93:355-61.
  64. Council Directive 96/29/EURATOM. Laying down the basic safety standards for the protection of health workers and the general public against dangers from ionizing radiation. Official Journal of the European Communities No. L 159 of June 29, 1996; Luxembourg: Centre Wagner.
  65. MORTON DL, COCHRAN AJ, THOMPSON JF *et al.* 2005 ASCO Annual Meeting Proceedings. *J Clin Oncol* 2005;23:7500.
  66. ROKA F, KITTLER H, CAUZIG P, HOELLER C, WOLFF K, PEHAMBERGER H, DIEM E. Sentinel node status in melanoma patients is not predictive for overall survival upon multivariate analysis. *Br J Cancer* 2005;92:662-7.
  67. MORTON DL, WANER L, NIZZE JA *et al.* Improved long-term survival after lymphadenectomy of melanoma metastatic to regional nodes. Analysis of prognostic factors in 1134 patients from John Wayne Cancer Clinic. *Ann Surg* 1991;214:491-9.
  68. ZOGAKIS TG, ESSNER R, WANG H, TURNER RR, TAKASUMI YT, GAFFNEY RL, LEE JH, MORTON DL. Melanoma recurrence patterns after negative sentinel lymphadenectomy. *Arch Surg* 2005;140:865-8.
  69. van AKKOIJ ACJ, de WILT JHW, VERHOEF C, GRAVELAND WJ, van GEEL AN, KLIPPEN M, EGGERMONT AMM. Prognostic indicators of locoregional and systemic recurrences after sentinel lymph node biopsy in patients with cutaneous melanomas. The European Cancer Conference ECCO 13, Paris, France, November. Citation: *Eur J Cancer* 2005;Suppl 3:344.
  70. GERSHENWALD JE, ROSS MI. Is sentinel-node biopsy superior to nodal observation in melanoma? *Nature Clin Pract Oncol* 2007;4:278-9.

71. MORTON DL, THOMPSON JF, COCHRAN AJ, MOZZILLO N, ELASHOFF R, ESSNER R, NIEWEG OE *et al.* Sentinel-node biopsy or nodal observation in melanoma. *N Engl J Med* 2006;28:1307-17.

## Sažetak

## KONCEPT SENTINEL LIMFNOG ČVORA I NJEGOVA ULOGA U LIJEČENJU BOLESNIKA S MELANOMOM

S. A. Rogan, K. Kovačić i Z. Kusić

Melanom je još uvijek jedan od najpogubnijih tumora u čitavom svijetu. U Sjedinjenim Američkim Državama se je stopa smrtnosti povećala u prošlih 40 godina za 191% kod muškaraca i 84% kod žena. To je većinom rak svijetlo pigmentiranih osoba poput europskih populacija. U prošlom desetljeću bitno su se povećale stope incidencije i smrtnosti, no postoje veoma velike razlike u stopi melanoma među različitim zemljama. Kožni melanom može se nepredvidivo i u velikoj mjeri širiti limfnim sustavom. Utvrđivanje bolesnika s okultnim metastazama melanoma važno je radi točnog određivanja stadija, planiranja liječenja te za prognozu. Prema podacima iz AJCC Melanoma Database, debljina melanoma najvažniji je prognostički čimbenik u sveukupnom preživljenju, ali je revidirani sustav određivanja stadija prepoznao i prisutnost metastaza u regionalnim limfnim čvorovima kao snažan neovisan prognostički čimbenik u 5-godišnjoj stopi preživljenja u stadiji I. i II. Melanom ima različite limfne puteve u limfnoj drenaži, poglavito melanomi smješteni na trupu, glavi i vratu. U proteklih 15 godina uveden je nov pristup u liječenju kožnog melanoma. Zahvaljujući suvremenim tehnikama nuklearne medicine, identificiranje sentinel limfnog čvora (SLN) limfoscintigrafijom (LS) i biopsija sentinel limfnog čvora (SLNB) pomoću ručne gama sonde postali su standardnim postupkom. U bolesti ranog stadija (AJCC I i II) i srednje debljine tumora (1,2-3,5 mm) LS uz SLNB čine metodu izbora za određivanje stadija čvora i odluku o daljnjem kirurškom zahvatu, iako je kod melanoma tanjih od 1 mm kirurško liječenje regionalnih limfnih čvorova još uvijek proturječno. Prema više od 1500 članaka objavljenih tijekom prošlog desetljeća, sveukupni zaključak je kako LS sa SLNB uz selektivnu disekciju limfnih čvorova u bolesnika s kožnim melanomom još uvijek ima tek prognostičku vrijednost, iako ukazuje na one bolesnike s metastazama u čvorovima čije se preživljenje može produžiti hitnom limfadenektomijom. Tako sustav određivanja stadija prema AJCC i dalje smatra mikrometastaze otkrivene samo pomoću imunohistokemijskih metoda ili lančanom reakcijom polimeraze kao bolest stadija N0. Ovaj članak donosi pregled današnjih spoznaja i primjene LS i SLNB kod kožnog melanoma.

*Ključne riječi: Metastaze u limfnim čvorovima – patologija; Sekundarni melanom; Sentinel limfnog čvora; Kožne neoplazme – patologija; Neoplazme u limfnim čvorovima – radionuklidno snimanje; Biopsija – metode, klasifikacija*

