

Pigmented Bowen's Disease of the Genitalia Masquerading as Malignant Melanoma

Emel Öztürk Durmaz¹, Işın Doğan Ekici², Ferda Özkan², Sedef Şahin¹

¹Department of Dermatology, Acıbadem University School of Medicine, Istanbul, Turkey; ²Department of Pathology, Yeditepe University School of Medicine, Istanbul, Turkey

Corresponding author:

Emel Öztürk Durmaz, MD
Acıbadem Maslak Hospital
Büyükdere Caddesi 40
Maslak 34457
Istanbul
Turkey
emelerkek@yahoo.com

Received: December 15, 2014
Accepted: May 15, 2015

ABSTRACT Pigmented Bowen's disease is a rare subtype of in situ squamous cell carcinoma of the skin and mucosa, with a potential risk of invasion and metastasis. It is universally accepted that human papillomavirus (HPV) is the cause of genital Bowen's disease. Herein we report an unusual case of pigmented Bowen's disease of the genital area that clinically simulated malignant melanoma. Accurate diagnosis could only be established after histological examination. Polymerase chain reaction (PCR) analysis showed that the lesion harbored HPV 16 DNA. Although pigmented Bowen's disease is rare, it should be considered in the differential diagnosis of all pigmented lesions of the genitalia. This case report highlights the necessity of biopsy and histopathological examination for every suspicious cutaneous lesion.

KEY WORDS: pigmented Bowen's disease; human papillomavirus

INTRODUCTION

Pigmented Bowen's disease (BD) is an unusual variant of in situ squamous cell carcinoma of the skin and mucosa, with a slight impending risk of invasive malignant transformation (1,2). Herein we report an unusual case of pigmented BD of the genital area that clinically simulated malignant melanoma.

CASE REPORT

A 43 year-old Caucasian woman presented with a 2-year history of a new, gradually enlarging "mole" on the buttocks. She had no complaints apart from cosmetic appearance. Personal medical history included migraine and cervical disc hernia. The patient was married and denied sexual promiscuity. There was no previous history of genital warts, cutaneous and internal malignancy, or arsenic exposure. Her husband had no history of genital warts.

Dermatological examination revealed a solitary, brownish oval 3×2.5 cm plaque, confined to the uppermost part of the natal cleft (Figure 1). The surface of the plaque was studded with finger-like tumefactions, which precluded optimal dermatoscopic examination. Initial tentative clinical diagnosis was malignant melanoma in the vertical growth phase.

Routine laboratory tests including complete blood count as well as liver and renal function tests were within normal limits. Histopathological examination of three punch biopsy specimens revealed orthokeratotic hyperkeratosis, parakeratosis, papillomatosis, and full-thickness epidermal atypia (Figure 2). The atypical cells displayed prominent vacuolization, nuclear pleomorphism, and abnormal mitoses (Figure 3). Focal areas with koilocytotic change and pagetoid appearance were also noted. Melanin pig-

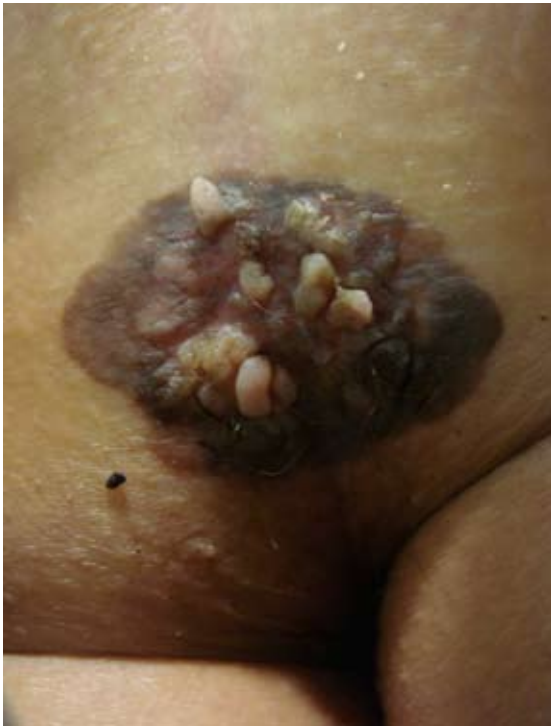

Figure 1. A solitary, brownish oval plaque confined to the uppermost part of the natal cleft, demonstrating finger-like prominences over the surface.

ment was irregularly distributed throughout the epidermis and in the papillary dermis. A pan-cytokeratin immunohistochemical stain yielded diffuse epidermal positivity (Figure 4). All layers of the epidermis showed positive nuclear staining for Ki 67. While epithelial membrane antigen (EMA) positivity was focally observed, immunohistochemical stains for HMB-45, melan-A, S-100, and carcinoembryonic antigen (CEA) were all negative. Using polymerase chain reaction (PCR) analysis, DNA specific to HPV 16 was amplified from a formalin-fixed, paraffin-embedded lesional biopsy sample.

These findings were consistent with genital pigmented Bowen's disease. The patient was referred to the Plastic Surgery Department for complete excision of the tumor within appropriate safety margins. There was no disease recurrence at the first year post-operative follow up.

DISCUSSION

BD preferentially affects the elderly and shows no gender predilection (1-3). Sunlight exposure, arsenic intake, gravity, chronic trauma, irradiation, immunosuppression, and human papillomavirus (HPV) have all been proposed as initiating or prompting factors (1,2,4-7). HPV is a potential cause in genital BD, although extragenital BD has also been documented

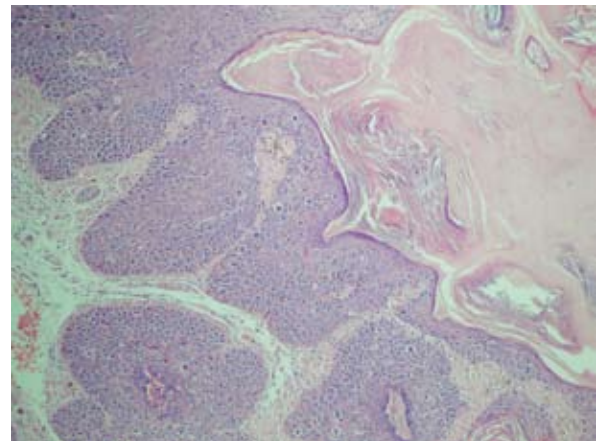


Figure 2. Orthokeratotic hyperkeratosis and full-thickness involvement of the epidermis by atypical keratinocytes (hematoxylin and eosin, $\times 40$).

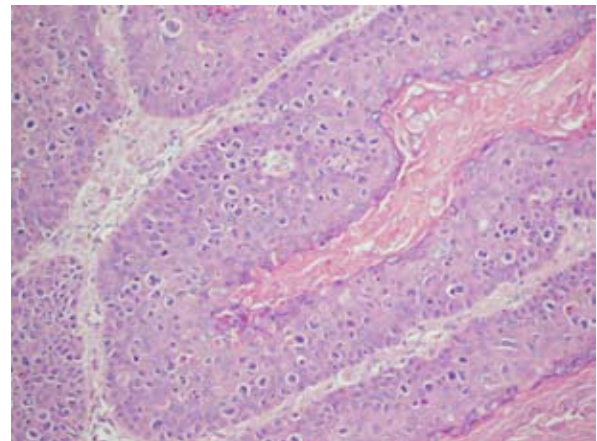


Figure 3. Prominent vacuolated atypical cells with nuclear pleomorphism, focally manifesting koilocytotic change, and pagetoid appearance (hematoxylin and eosin, $\times 100$).

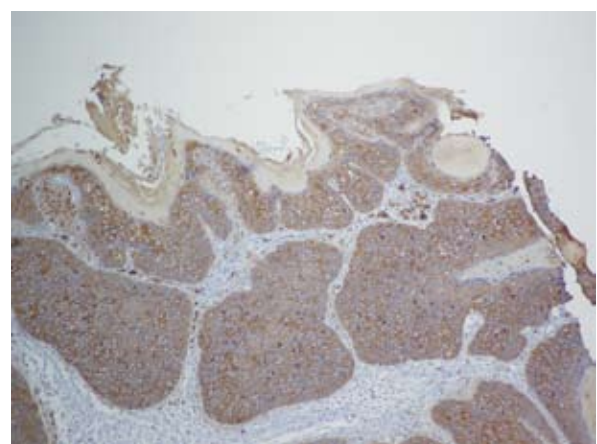


Figure 4. Pan-cytokeratin immunohistochemistry revealing diffuse positive staining (immunohistochemistry for cytokeratin, $\times 40$).

to harbor HPV DNA subtypes in up to 30 to 58% of cases (1,2,8). In our patient, HPV 16 represented the possible etiological trigger.

Pigmented BD constitutes less than 2 % of all cases of Bowen's disease (1,2,4,5,9,10). Traditionally, it is more frequent in patients with darker skin types (2,5). However, as in the present case, pigmented BD has also been found in patients with fair skin. The mechanism of pigmentation is elusive. One hypothesis suggests increased production of specific factors or cytokines by neoplastic cells, which promote melanocyte hyperplasia, melanin synthesis, and secretion (2,4,9). An alternative model proposes elevated temperature or extension of preexistent hyperpigmentation in the anogenital skin leading to pigmentation in BD (4,9). A final hypothesis proposes that BD originates from an already pigmented lesion such as a solar lentigo or seborrheic keratosis, which are known to appear with BD in 38.6 % and 13.6 % of cases, respectively (2,4-6).

Clinically, BD may present as a solitary, slowly growing, erythematous or pigmented, scaly, crusted, or verrucous plaque with irregular, albeit well-defined borders (1,4,11). The most common locations are the sun exposed regions of the head and neck in elderly patients with fair skin (1-3). The legs may be preferentially involved in women (1). Unexposed areas such as the trunk, palms, soles, and perianal area may also be afflicted (1,4,5,11,12). Multiple lesions occur in 10-20% of patients and tend to be located on sun-protected skin in 73% of cases (2,8). The lesions are generally asymptomatic; pruritus or burning pain is occasionally reported (9).

Dermatoscopy may assist in the diagnosis of pigmented BD. The most common dermatoscopic pattern of pigmented Bowen's disease is structureless brown and blue-gray peripheral pigmentation with keratosis and/or dots in chaotic arrangement. The most specific dermatoscopic clues are dotted and linear coiled (glomerular) vessels (5,6,9,11,13). Atypical pigmented pseudonetworks mimicking malignant melanoma have been attributed to irregular melanin deposition in the variably thickened epidermal rete pegs (11).

The histologic description of pigmented BD in previous reports includes full thickness keratinocyte dysplasia with loss of polarity, atypical pleomorphic squamous epithelial cells with disproportionately enlarged hyperchromatic nuclei, atypical mitotic figures, multinucleate keratinocytes, dyskeratotic cells, and vacuolization of the upper epidermal cells (1,2,11). Hyperkeratosis, parakeratosis, acanthosis and elongation of rete pegs, agranulosis, and fibrosis of the papillary dermis have also been reported

(1,4,7,11,13). Melanin is increased in the basal layer of the epidermis, in melanocytes, and in papillary dermal melanophages (2,4,11). The dermis may be populated by a dense infiltrate of lymphocytes or histiocytes (4,13).

BD evolves into invasive squamous cell carcinoma in 3-10% of cases (2-4). Furthermore, 13% of such patients develop metastasis and 10% eventually die (2). While erosion or ulceration of the lesion may herald the onset of invasion (1,3,9,10), pigmentation is not considered a risk factor for invasion or metastasis (2,4). Anogenital BD in the setting of cervix carcinoma and multicentric genital BD accompanying other genital tract tumors has been described (8).

Superficial spreading malignant melanoma represents the most important differential diagnosis of pigmented BD (1,2,4,11). Other considerations include seborrheic keratosis, pigmented actinic keratosis, benign lichenoid keratosis, solar lentigo, pigmented basal cell carcinoma, blue nevus, melanocytic nevi, bowenoid papulosis, keratoacanthoma, pigmented eccrine poroma, angioma, and angiokeratoma (1,2,4-6,11,13). Overall, the most striking features of the present case were its unusual clinical appearance simulating malignant melanoma and its location in the unexposed genital region.

The best treatment for BD is complete surgical excision of the lesion (1,7). Both standard excision and Mohs micrographic surgery may be employed (4). Alternative treatment modalities include topical 5-fluorouracil, topical imiquimod, cryotherapy, systemic acitretin, electrocauterization, radiotherapy, laser ablation, and photodynamic therapy (2-4,7,14). BD has a high recurrence rate of 10-15%, particularly in the multicentric type (2).

CONCLUSION

In our case, wide local excision accomplished effective tumor removal with no evidence of local recurrence at one year follow up.

References

1. Firooz A, Farsi N, Rashighi-Firoozabadi M, Gorouhi F. Pigmented Bowen's disease of the finger mimicking malignant melanoma. *Arch Iranian Med* 2007;10:255-7.
2. Gahalaut P, Rastogi MK, Mishra N, Chauhan S. Multiple pigmented Bowen's disease: A diagnostic and therapeutic dilemma. *Case Rep Oncol Med* 2012;2012:342030.
3. Pai VV, Hanumanthayya K, Naveen KN, Rao R, Dinsh US. Bowen's disease over the abdomen-a

- histological pigmented variety. *Indian J Cancer* 2011;48:121-2.
- Lee JW, Hur J, Yeo KY, Yu HJ, Kim JS. A case of pigmented Bowen's disease. *Ann Dermatol* 2009;21:197-9.
 - Gutiérrez-Mendoza D, Narro-Llorente R, Karam-Orantes M, Fonte-Avalos V, Martínez-Luna E, Toussaint-Caire S, *et al.* Dermoscopy clues in pigmented Bowen's disease. *Dermatol Res Pract* 2010;2010:464821.
 - Cameron A, Rosendahl C, Tschandl P, Riedl E, Kittler H. Dermatoscopy of pigmented Bowen's disease. *J Am Acad Dermatol* 2010;62:597-604.
 - El Fekih N, Hawiloo A, Remmah S, Zermani R, Fazaa B. Pigmented lesion in the inguinal region. *Dermatol Online J* 2011;17:12.
 - King CM, Yates VM, Dave VK. Multicentric pigmented Bowen's disease of the genitalia associated with carcinoma in situ of the cervix. *Br J Vener Dis* 1984;60:406-8.
 - Ishioka P, Yamada S, Michalany NS, Hirata SH. Dermoscopy of Bowen's disease: pigmented variant on the penis. *An Bras Dermatol* 2012;87:482-4.
 - Sardesai VR. Bowen's disease: an uncommon presentation. *Int J Dermatol* 2002;41:691.
 - Hayashi Y, Tanaka M, Suzaki R, Mori N, Konohana I. Dermoscopy of pigmented Bowen's disease mimicking early superficial spreading melanoma. *Case Rep Dermatol* 2009;1:11-5.
 - Cavicchini S, Tournalaki A, Ghislanzoni M, Alberizzi P, Alessi E. Pigmented Bowen disease of the palm: an atypical case diagnosed by dermoscopy. *J Am Acad Dermatol* 2010;62:356-7.
 - Inoue T, Kobayashi K, Sawada M, Ishizaki S, Ito H, Fujibayashi M, *et al.* Dermoscopic features of pigmented Bowen's disease in a Japanese female mimicking malignant melanoma. *Dermatol Res Pract* 2010;2010:543091.
 - Farrell AM, Dawber RP. Squamous cell carcinoma of the penis. *J Am Acad Dermatol* 1998;38:504-5.

