

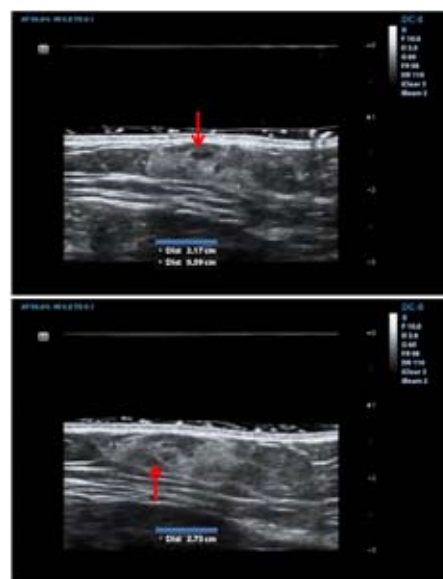## Subcutaneous Cavernous Angiolipoma: A New Soft-tissue Entity

Angiolipoma is a benign soft-tissue tumor which combines the morphological features of lipoma with those of hemangioma. The ratio of lipomatous and vascular components is variable, the latter reaching the highest percentage in the cellular variant of the tumor (1). It is important to distinguish this variant because cellular angiolipoma can have an infiltrative growth with a tendency toward local recurrence after a borderline surgical excision. Angiolipoma typically occurs in the subcutaneous tissue as a single nodule, rarely more than 2 cm in diameter, or as multiple nodules, especially in syndromic conditions, such as Cowden and Birt-Hogg-Dube syndromes (2,3). The tumor can cause pain if it compresses the adjacent peripheral nerves; the pain also correlates with the degree of vascularity (4). About the two-thirds of all angiolipomas appear in the forearm, followed in frequency by the upper arm and trunk. It is seldom localized at the level of the internal organs. The tumor is more common in men and its incidence is higher in the second decade of life, while only sporadic cases in children or in adults over the age of 50 years have been described. Microscopically, the tumor consists of mature adipocytes separated by a branching network of small vessels, which often contain fibrin thrombi (4,5), whereas the term "vascular caverns" has been used to refer to large vascular channels lined by flattened endothelium and engorged by blood, with a neoplastic or malformative nature. Here, we report the first case in the literature of subcutaneous cavernous angiolipoma, a new soft-tissue entity.

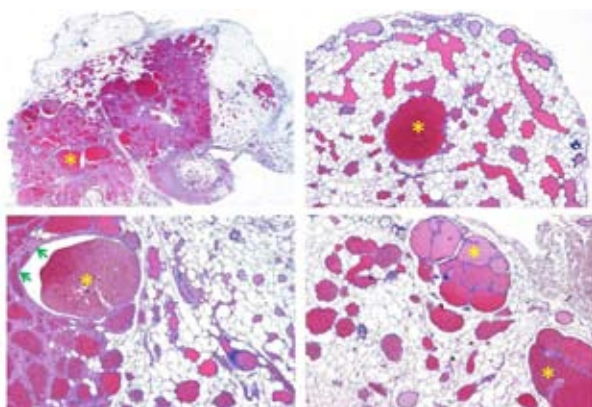
A 75-year-old man was admitted to the hospital ward for an ultrasound scan on the region of the left pectoralis major muscle, where a painful enlarging subcutaneous swelling had appeared about 6 months before. The echography revealed the presence of an extrafascial discoid neof ormation, measuring 2.17×0.59×2.73 cm. The lesion had an inhomogeneous sonographic appearance, with ill-defined margins (Figure 1).

Consequently, a surgical excision was performed; the excised tissue had a distinctive bluish color. From a histological point of view, the lesion was composed of a well-differentiated lipomatous component intermingled with large gaps, lined by vascular endothelium devoid of cytologic atypia. The extent of these gaps was such as to far exceed the vascular dilations that can be found in classic angiolipoma, forming real caverns. Therefore, a diagnosis of subcutaneous cavernous angiolipoma was formulated (Figure 2).

For the first time in the literature, we report a case of subcutaneous cavernous angiolipoma. This new soft-tissue entity should be reserved for subcutaneous angiolipoma with very large vascular gaps, haphazardly arranged and engorged by blood. The first and only description of a cavernous angiolipoma dates back to 2008, when Farooq and colleagues described



**Figure 1.** Ultrasound scan of subcutaneous cavernous angiolipoma: a non-homogeneous sonographic appearance due to vascular lacunae engorged by blood (red arrows), is noticeable.



**Figure 2.** Histological image of subcutaneous cavernous angioliipoma: large vascular channels, haphazardly arranged, are engorged by blood (yellow stars). They are lined by a single layer of endothelial cells (green arrows); the vascular component is mingled with the fat (hematoxylin and eosin, original magnifications  $\times 4$  and  $\times 10$ ).

its spinal occurrence (6). The differential diagnosis of this new entity depends on vascular density: the hypovascular tumor can be mistaken for a common lipoma, while the hypervascular lesion should be distinguished from cavernous hemangioma and related variants that include intramuscular hemangioma (also called infiltrating angioliipoma), spindle cell hemangioma, arteriovenous and venous malformations, and Kaposi's sarcoma. Histopathogenetic theories about subcutaneous cavernous angioliipoma include a possible differentiation from a pluripotent mesenchymal cell into both lipomatous and angiomatous counterparts due to inflammation or trauma, and a progressive development from a congenital malformation or benign hamartoma. In support of the latter thesis, we note that there is a 5-10% familial incidence in classic angioliipoma and the frequent presence of many mast cells inside the tumor. Moreover, about a third of all angioliipomas express androgen receptors which leads us to suspect a hormonal influence in the development of these subcutaneous tumors (7,8).

For the first time in the literature a subcutaneous cavernous angioliipoma has been described in its sonographic and histological presentation. A differential diagnostic algorithm and related histopathogenetic theories have been proposed. Currently, there is no evidence that subcutaneous cavernous angioliipoma can undergo malignant transformation.

## References

1. Hunt SJ, Santa Cruz DJ, Barr RJ. Cellular angioliipoma. *Am J Surg Pathol* 1990;14:75-81.

2. Chung JY, Ramos-Caro FA, Beers B, Ford MJ, Flowers F. Multiple lipomas, angioliipomas, and parathyroid adenomas in a patient with Birt-Hogg-Dube syndrome. *Int J Dermatol* 1996;35:365-7.
3. Levitt J, Lutfi Ali SA, Sapadin A. Multiple subcutaneous angioliipomas associated with new-onset diabetes mellitus. *Int J Dermatol* 2002;41:783-5.
4. Dixon AY, McGregor DH, Lee SH. Angioliipomas. An ultrastructural and clinicopathological study. *Hum Pathol* 1981;12:739-47.
5. Muthulakshmi R, Yesudian P, Kamalam A, Thambiah AS. Unusual clinical presentation of angioliipoma. *Int J Dermatol* 1981;20:608.
6. Farooq MU, Samaraweera R, Heilman T, Chang HT. Spinal cavernous angioliipoma. *Arch Neurol* 2008;65:981-2.
7. Jain R, Bitterman P, Lamzabi I, Reddy VB, Gattuso P. Androgen receptor expression in vascular neoplasms of the breast. *Appl Immunohistochem Mol Morphol* 2014;22:132-5.
8. Cesinaro AM, Roncati L, Maiorana A. Estrogen receptor alpha overexpression in multinucleate cell angiohistiocytoma: new insights into the pathogenesis of a reactive process. *Am J Dermatopathol* 2010;32:655-9.

**Luca Roncati<sup>1</sup>, Teresa Pusioli<sup>2</sup>,  
Francesco Pisciolli<sup>2</sup>, Antonio Maiorana<sup>1</sup>**

<sup>1</sup> Department of Diagnostic and Clinical Medicine and of Public Health, Section of Pathology, University of Modena and Reggio Emilia, Modena, Italy

<sup>2</sup> Company of Provincial Health Services, Institute of Pathology, Santa Maria del Carmine Hospital, Rovereto, Italy

## Corresponding author:

Luca Roncati, MD, PhD  
Struttura Complessa di Anatomia, Istologia e Citologia Patologica  
Policlinico Hospita  
Largo del Pozzo 71  
41124 Modena  
Italy  
emailmedical@gmail.com

Received: June 22, 2014

Accepted: March 15, 2015