

Acta Chir Croat 2015; 12: 51–54

ORBITAL CAVERNOUS HEMANGIOMA

Orbitalni kavernozi hemangiomi

Rade Škarica¹, Boris Zdilar², Domagoj Rašić², Mladen Harapin³, Tatjana Andabaka⁴, Jurica Fudurić⁵, Zvonko Zadro², Miran Martinac², Ana Šošćarić Zadro⁶, Mario Kordić⁷

Abstract

The aim of this case report was to present a patient with a benign orbital tumor, cavernous hemangioma, who presented with symptoms of compressive orbital mass: unilateral axial proptosis, with motility restriction and sudden vision loss in the left eye. Ophthalmologic examination (visual acuity, applanation tonometry, Goldmann tonometer, visual field) and radiologic examination diagnosed a benign, well circumscribed, vascular, intraconal tumor that compresses the optic nerve. Treatment was operative: lateral orbitectomy Krönlein procedure and the tumor was removed. Pathologic and pathohistologic examination confirmed the previous diagnosis. Follow up examination, visual field and MRI of the orbit showed considerable improvement. Surgical treatment was also the final treatment and no adjuvant therapy was necessary. Prognosis for visual acuity and life is excellent.

Keywords

vascular orbital lesion, cavernous hemangioma, orbitectomy

Sažetak

Cilj ovog rada bio je prikazati slučaj pacijentice s benignim tumorom orbite, kavernozi hemangiomom, koji se javlja sa simptomima kompresivne tvorbe u orbiti: unilateralnom proptozom, smetnjama motiliteta te naglim gubitkom vida lijevog oka. Oftalmološkom obradom (ispitivanje vidne oštine, aplanacijska tonometrija, ispitivanje vidnog polja po Goldmannu) te radiološkom obradom (MR, MSCT, MSCT angiografija) postavlja se dijagnoza benigne, dobro ograničene, vaskularne tvorbe u konusu koja

pritišće očni živac. Pristupilo se operativnom zahvatu, napravila se lateralna orbitektomija po Krönleinu i odstranio tumor u cijelosti. Patološka i patohistološka pretraga potvrđuju raniju dijagnozu. Postoperativni tijek protiče uredno te se na nalazu kontrolnog vidnog polja i kontrolnim snimkama MR-a utvrđuje značajno poboljšanje. Kod pacijentice je kirurško liječenje bilo i konačno te nije bila potrebna dodatna terapija. Prognoza za vidnu oštrinu i život je odlična.

Cljučne riječi

vaskularna orbitalna lezija, kavernozi hemangiomi, orbitektomija

Introduction

Vascular neoplasms make 4% of all orbital lesions. Cavernous hemangioma occurs in 50% of cases. Almost 75% are middle-aged patients (20–64), only 10% younger (0–20) and 15% older (over 65 years of age). Cavernous hemangioma is a benign, non-infiltrative, slowly progressive tumor, it is congenital, but it usually becomes symptomatic in middle-aged patients, when the tumor grows. Location is typically intraconal, rarely intraosseous. Unlike non-neoplastic vascular lesions which usually effect the hemodynamic functions of underlying structures, neoplastic vascular lesions typically manifest themselves with a mass effect. Symptoms of tumor are axial, unilateral proptosis and motility restriction. When the tumor is large it can indent the back of the eye causing choroidal folds and papilledema with decreased vision acuity. If the lesion is in the conal apex, it can compress the optic nerve without significant proptosis. The lesion may enlarge during pregnancy. Orbital imaging techniques confirm the diagnosis, which shows oval to round intraconal

¹ Department of Neurosurgery, General Hospital Zadar, Zadar, Croatia

² University Hospital Sveti Duh, University Department of Surgery, Zagreb, Croatia

³ Department of Radiology, General Hospital Zadar, Zadar, Croatia

⁴ Department of Anesthesiology, Reanimatology and Intensive Care, General Hospital Zadar, Zadar, Croatia

⁵ Department of Surgery, General Hospital Karlovac, Karlovac, Croatia

⁶ Department of Radiology, Special Hospital for Lung Diseases, Zagreb, Croatia

⁷ Department of Urology, University Hospital Mostar, Bosnia and Herzegovina

mass, well defined with slow contrast enhancement. Ultrasound of the eye and orbit shows a well defined, highly reflective tumor with regular acoustics. Prognosis is excellent, for visual acuity and life [1–4].

Case report

Patient, female, 67 years of age, with no previous significant medical history was admitted because of sudden vision loss in the left eye that occurred two days ago. Also in the past few weeks she had a temporary diplopia and left eye proptosis. Ophthalmologic examination showed a unilateral axial proptosis with motility restriction of the left bulbus, with regular palpebral closure.

Visual acuity examination results showed visus oculi dextri (VOD): 1.0 n.c., visus oculi sinistri (VOS): 0.2 n.c., applanation tonometry – T apl. o. u. 14 mmHg. Biomicroscope (BM) found bilateral incipient cataract, fundus o.u. papilla nervi optici (PNO) round regular colored with no papillar edema, blood vessels regular, incipient senile macular degeneration. Visual field examination (VF) on Goldmann perimeter showed narrowed VF, 20-o, only 14 isopter registered, blind spot in 14 (Figure 1).

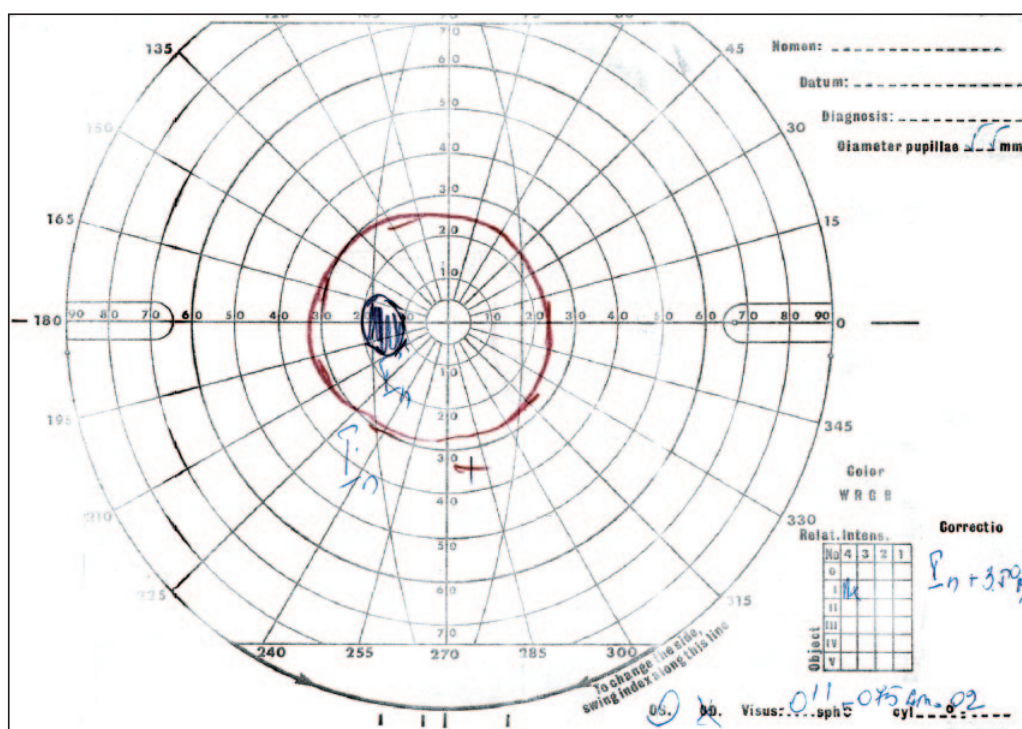
Radiology examination (magnetic resonance – MR, multi-slice computer tomography – MSCT, MSCT angiography) showed intraconal, expansive structure, with no infiltration, compressing the optic nerve, lateral rectus and bulbus causing axial proptosis (Figure 2). Angiography showed slow contrast enhancement. The diagnosis was a benign orbital vascular tumor,

cavernous hemangioma and therapy is surgical excision. We performed an operative procedure, as mentioned earlier, and intraoperatively we found a tumor under lateral rectus, we dissected it from the orbital fat tissue and its insertion on orbital fascia. We performed an intraoperative biopsy *ex tempore*. The tumor was cystic, 2x1.2x0.5 cm, well circumscribed and encapsulated, filled with dark red, thick fluid, pathohistological diagnosis (PHD) – cavernous hemangioma. By surgical treatment the dislocated bulbus, optic nerve and surrounding tissues were decompressed and the bulbus returned to its anatomical intraorbital position. Our patient was recovering well after the procedure and on the 7th postoperative day was released on home care, with subjective visual acuity improvement and residual diplopia. VOS: 0.6 c.c., significant visual field improvement (Goldmann perimeter), still compressed in upper parts 20-o, but all isopters registered a blind spot in 12 (Figure 3) and no tumor on control MRI of the left orbit (Figure 4).

Discussion and conclusion

Cavernous hemangioma is the most common benign vascular neoplasm of the orbit, occurring in middle-aged patients, 70% in women. It has a good prognosis for visual acuity and life, surgical removal is usually the only necessary treatment. Our patient had a unilateral, left-axial proptosis, diplopia and sudden-onset disorders of vision in the left eye. Ophthalmological examination, Goldmann visual field examination and

Figure 1. Visual field examination by Goldmann before surgical procedure.



radiological diagnosis showed vascular neoplastic lesions in the left orbit that presses on the optic nerve. Surgical procedure was performed and tumorous formation was removed in full. Pathological examination *ex tempore* and the subsequent histopathologic examination confirmed the diagnosis of cavernous hemangioma. Postoperative course ran properly and the patient was discharged home with significant improvement. Postoperative Goldman

visual field examination showed significant improvement and control MR of the left orbit did not show any residual tumor mass.

In conclusion, our patient had a benign tumor of the orbit, cavernous hemangioma, a well-limited, encapsulated tumor with a very good prognosis. Surgical procedure was performed and the tumor was removed completely with no further treatment needed [5–11].

Figure 2. MRI of the tumor, arrow shows intraconal, non-infiltrative mass with compression on the surrounding tissue.

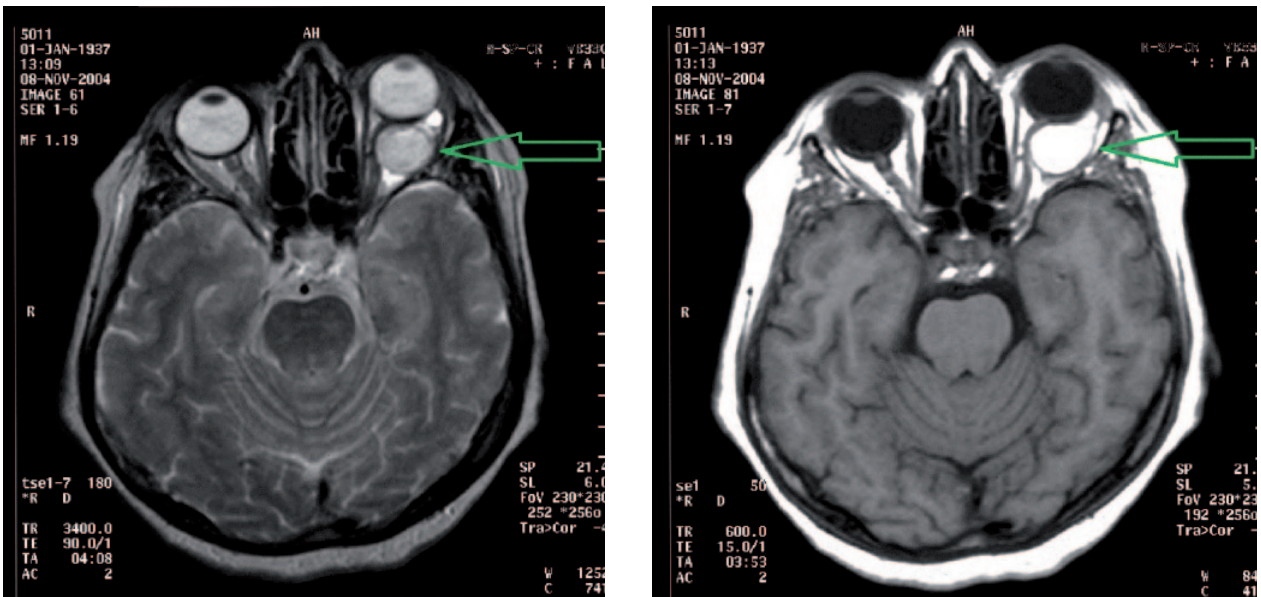


Figure 3. Visual field examination after operation, significant improvement.

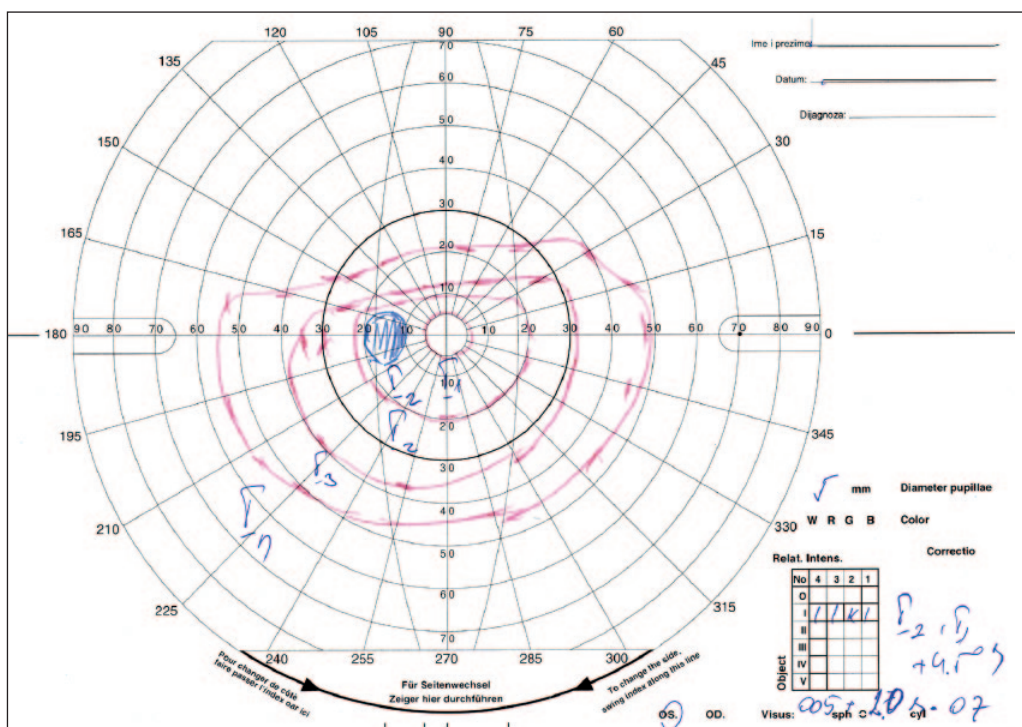
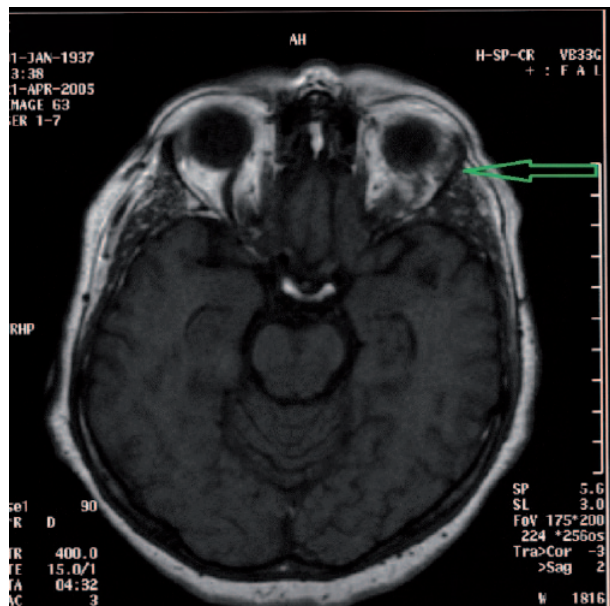


Figure 4. MRI after surgical removal of the hemangioma, arrow pointing to were the tumor was situated, no visible signs of tumor presence.



References

1. Dutton JJ. Orbital disease. In: Janoff M, Duker JS (eds) *Ophthalmology*. 3rd ed. St. Louis: Mosby; 2008. pp. 1450–1465.
2. Kuzmanović Elabjer B, Bušić M, Elabjer E, Bosnar D, Sekelj S, Kondža Krstonjivić E. Microincision aponeurotic ptosis surgery of upper lid. *Coll Antropol* 2009;33(3): 915–918.
3. Jakobiec FA, Jones IS. Vascular tumors, malformations and degeneration. In: Jones IS, Jakobiec FA (eds) *Diseases of the Orbit*. Hagerstown: Harper and Row; 1979. pp. 269–283.
4. Dutton JJ, Byrne SF, Proia A. *Diagnostic Atlas of Orbital Disease*. Philadelphia: WB Saunders; 2000. pp. 150–151.
5. Bohač M, Gabrić N, Antičić M, Drača N, Dekaris I. First results of intracorp procedure in Croatia. *Coll Antropol* 2011;35 (2): 161–166.
6. Dutton JJ. Radiographic evaluation of the orbit. In: Doxanas MT, Anderson RL (eds) *Clinical Orbital Anatomy*. Baltimore: Williams and Wilkins; 1984. pp. 35–56.
7. Henderson JW, Farrow GM, Devine KD, Miller RH. *Orbital Tumors*. Philadelphia: WB Saunders, 1973. pp. 136–137.
8. Krohel GB. Orbital surgery. In: Smith BC, Dellarocca RC, Nesi FA, Lisman RD (eds) *Ophthalmic Plastic and Reconstructive Surgery*. St Louis: Mosby; 1987. pp. 1084–1164.
9. Dutton JJ. *Atlas of Clinical and Surgical Orbital Anatomy*. Philadelphia: WB Saunders; 2011. pp. 175–227.
10. Levine RA. Orbital ultrasonography. *Radiol Clin North Am* 1987;25(3): 447–469.
11. Iveković R, Novak-Lauš K, Tadeschi-Reiner E, Masnec-Paškvalin S, Šarić D, Mandić Z. Full-thickness anterior blepharotomy and transpalpebral fat decompression in graves orbitopathy. *Coll Antropol* 2005;29(1): 33–36.