

ULTRASOUND GUIDED FOAM SCLEROTHERAPY – THE SIMPLEST, LEAST INVASIVE, AND CHEAPEST METHOD FOR VARICOSE VEIN TREATMENT

Anton Krnić

Department of Radiology, Sveti Duh University Hospital, Zagreb, Croatia

SUMMARY – The aim is to present our experience and observations regarding varicose vein treatment by means of ultrasound guided foam sclerotherapy (UGFS). The study included 81 patients, 54 with insufficient main stem superficial veins in one limb and 27 with both limbs affected. Great saphenous vein insufficiency was diagnosed in 68, small saphenous insufficiency in 18, anterior accessory saphenous vein insufficiency in 11, and Giacomini vein insufficiency in 3 limbs. Seven limbs had combined insufficiency of great saphenous vein and small saphenous vein, and 1 limb had combined insufficiency of Giacomini vein and small saphenous vein. UGFS was employed to treat main stem vein reflux and their tributaries. Within a month after treatment, all main stem veins were occluded and only small corrections were performed occasionally to treat residual varices. Regarding side effects, skin darkening and hard lumps at the sites of varicose veins were most commonly observed. We also recorded several episodes of thrombophlebitis. Few patients experienced dry cough, visual disturbances and headache following the treatment. After six months, repeat UGFS of main stem veins had to be performed in few patients. Very few patients expressed dissatisfaction a year after treatment, mainly because of residual skin darkening. In conclusion, UGFS proved to be the simplest, quickest and cheapest method of varicose vein treatment. According to our experience, it yielded satisfactory functional and cosmetic results. Side effects do occur, but are acceptable, in particular at long term.

Key words: *Sclerotherapy – methods; Varicose veins – therapy; Ultrasonography, interventional – methods; Lower extremity; Hyperpigmentation*

Introduction

Endovenous techniques for varicose vein treatment have been implemented since 1999. Although, at the beginning, they faced substantial resistance by those who were supporting standard methods of varicose vein treatment, such as high ligation and stripping, endovenous techniques have been gaining ever more popularity with time and nowadays endovenous

techniques are widely used and established among the methods of choice in treating persons with lower limb venous disease¹⁻⁶.

When speaking about endovenous methods, although thermal ablation techniques such as endovenous laser ablation and radiofrequency ablation are considered superior, i.e. more efficient at long term, to ultrasound guided foam sclerotherapy (UGFS) in treating varicose veins, foam sclerotherapy has some substantial advantages over these two methods, which make it a method of choice in numerous circumstances^{1,3,5,6}.

The aim of this article is to present our results in UGFS of lower limb varicose veins caused by main stem vein insufficiency and to discuss its advantages

Correspondence to: *Anton Krnić, MD, PhD*, Department of Radiology, Sveti Duh University Hospital, Sveti Duh 64, HR-10000 Zagreb, Croatia

E-mail: anton.krnic@gmail.com

Received October 27, 2014, accepted January 23, 2015

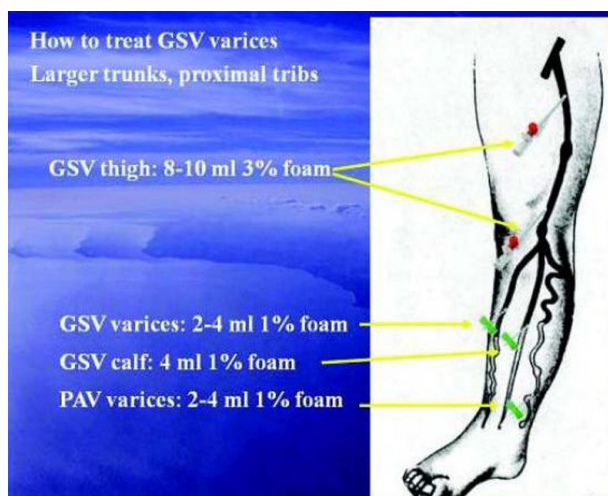


Fig. 1. Location of cannulas and amounts of foam for treatment of great saphenous vein reflux.

over other methods of varicose vein treatment, as well as its drawbacks.

Patients and Methods

From October 2011 until January 2013, we treated 108 lower limbs with varicose veins caused by main stem vein reflux by use of UGFS. Inclusion criteria were superficial venous insufficiency of lower limbs caused by main stem vein insufficiency, as confirmed on duplex scanning, with patent and competent deep veins, in patients who agreed to undergo UGFS and signed the informed consent form.

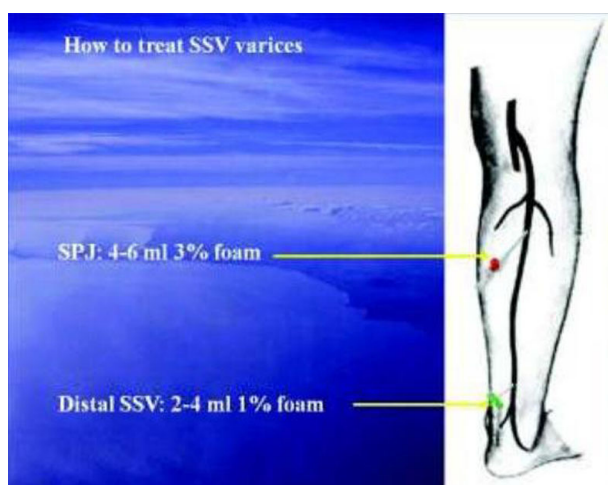


Fig. 2. Location of cannulas and amounts of foam for treatment of small saphenous vein reflux.

The informed consent form provided the following information: primary success rate in main stem vein closure of 95%-100%; 77% success rate after 3 years; and possible complications or side effects including deep venous thrombosis and pulmonary embolism, dry cough, visual disturbances, headaches, cerebral ischemic attacks, hard lumps which tend to withdraw with time, hyperpigmentation and discoloration which tend to fade with time, and thrombophlebitis episode⁷⁻¹⁰.

Exclusion criteria were patients with obstructed or incompetent deep veins, if confirmed on duplex scanning, patients on anticoagulation therapy which could not be ceased, hypercoagulable states, such as previous history of deep venous thrombosis and/or pulmonary embolism, severe thrombophilia, etc.⁷⁻¹⁰.

We also excluded from the study patients who had insufficient superficial veins, but other than main stem veins (i.e. other than great saphenous vein, small saphenous vein, anterior accessory saphenous vein, or Giacomini vein). These were, e.g., patients who suffered from varicose veins due to perforating vein reflux, patients who suffered from varicose veins or reticular veins without main stem vein insufficiency, patients with venous malformations, such as Klippel-Trénaunay syndrome, etc.

Based on duplex scanning, we included 81 patients in the study. Fifty-four of them had insufficient superficial veins in one limb, whereas 27 had both lower limbs affected with incompetent main stem superfi-

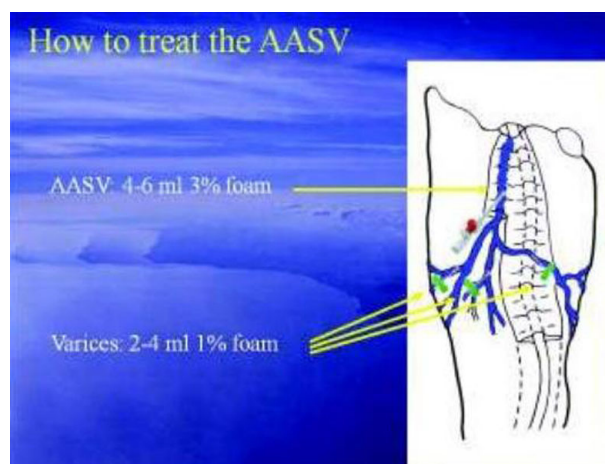


Fig. 3. Location of cannulas and amounts of foam for treatment of anterior accessory saphenous vein reflux.

cial veins. In 68 limbs, we diagnosed great saphenous insufficiency solely, in 18 limbs small saphenous insufficiency, in 11 limbs anterior accessory saphenous vein insufficiency, and in 3 limbs Giacomini vein insufficiency. Seven limbs had combined insufficiency of great saphenous vein and small saphenous vein, and 1 limb had combined insufficiency of Giacomini vein and small saphenous vein.

In all patients, both main stem veins and their tributaries were first cannulated under ultrasound guidance using intravenous cannulas (Figs. 1-3). Tributaries were first treated by injection of 1% or 2% polidocanol foam (Aethoxysklerol, Kreussler Pharma, Wiesbaden, Germany). After that, main stem vein was treated by administration of 3% Aethoxysklerol foam (Figs. 1-3). No anesthesia was applied⁷⁻¹⁰.

In all patients, foam was prepared by mixing liquid Aethoxysklerol with air at 1:4 ratio in 5 mL syringes, using 3-way stopcock, according to Tessari technique⁷⁻¹⁰. We did not administer more than 18 mL of foam *per session*⁷⁻¹⁰. If this amount could not solve the entire problem, e.g., in some of the patients who had varicose veins in both legs, or in some of the patients with more than one insufficient main stem vein in one leg, we stopped the treatment and continued a week

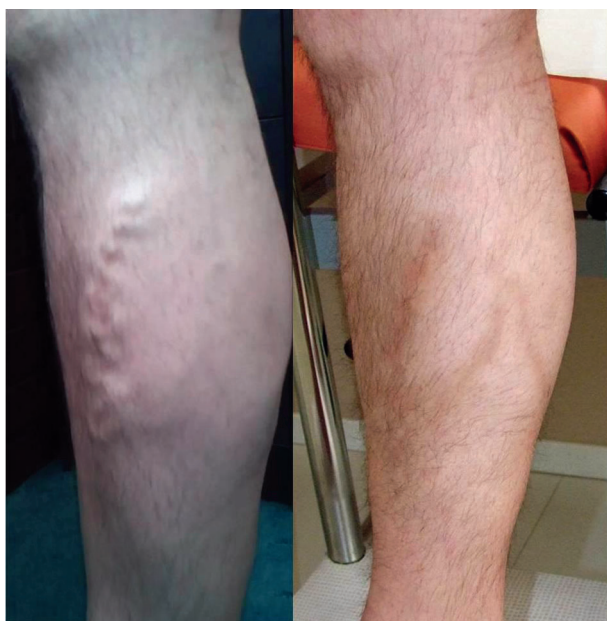


Fig. 4. Varicose veins caused by great saphenous vein insufficiency before and within a month after treatment. Some skin darkening is still present.

later. All patients were provided compression class 2 stockings and were asked to wear them for the first 3 days day and night, and, after that, for the next 4 weeks during the day solely. They were also asked to ambulate for half an hour after leaving the clinic, and for the next 2 days 3 times a day for 20-30 minutes. They were advised to treat possible tender or painful areas by local application of diclofenac gel or to take anti-inflammatory analgesic pills such as paracetamol, diclofenac, or ibuprofen.

All included patients underwent follow up within 2-4 weeks after the treatment by means of duplex scanning; they were examined at around day 19 of the procedure (17-21.25 interquartile range).

Results

At follow up, we reexamined venous system with duplex ultrasound: all patients had patent deep veins and closed treated main stem veins, as well as most of their tributaries (Figs. 4-7). However, in a great deal of patients, we performed some smaller corrections such as additional UGFS of the residual, un-obliter-

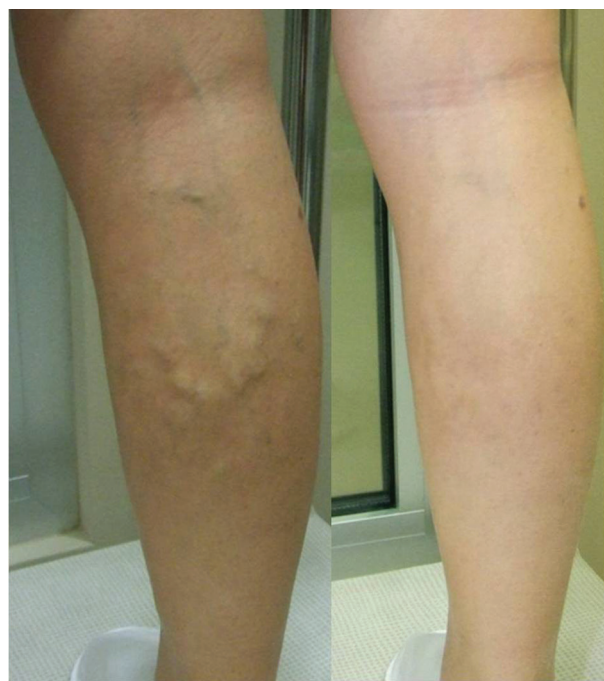

Fig. 5. Varicose veins caused by small saphenous vein insufficiency before and within a month after treatment. In this case, practically no side effects, such as skin darkening and hard lumps, were noticed.

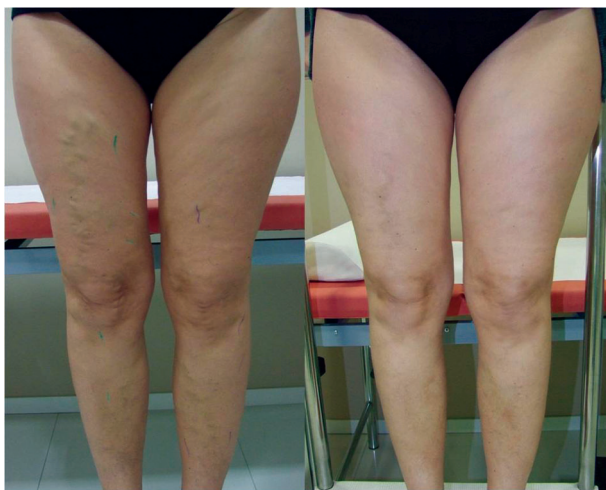


Fig. 6. Varicose veins caused by anterior accessory saphenous vein insufficiency on both legs before and within a month after treatment. In this case, we treated both legs in one session.

ated varicose tributaries with smaller or intermediate amounts of foam (up to 8 mL of 1% or 2% Aethoxysklerol foam) and/or aspiration of trapped blood from the treated veins using 18-19 G needle and 5 mL syringe. The latter was employed in cases where residual hard lumps were still bulging, painful and hypoechoic on ultrasound.

Since patients were not asked to present for further follow up unless they wanted to, we could not review the short and long term results systematically, but according to our observations, we did not have to undergo unpleasant events related to patient dissatisfaction

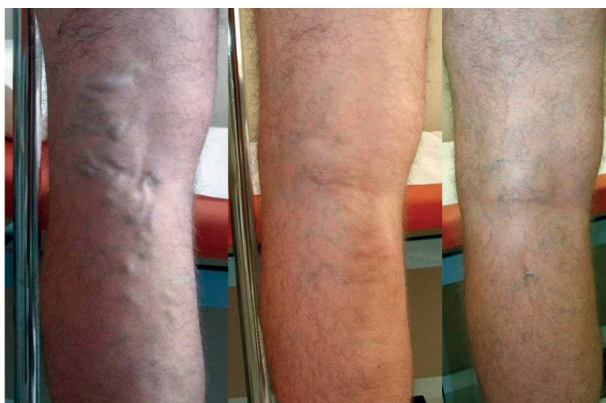

Fig. 7. Varicose veins caused by Giacomini vein insufficiency before, 1 month, and 12 months after treatment. It is obvious that residual skin darkening fades with time.

or disappointment in a year and a half period after the study had been conducted. Some patients visited us to do residual or recurrent varicose veins, but it could be easily managed by reemployment of UGFS. In such cases, we occasionally used sodium tetradecyl sulfate foam (Fibrovein, STD Pharmaceuticals, Hereford, United Kingdom), since it is considered a stronger detergent sclerosant than polidocanol (Aethoxysklerol). Such approach usually achieved permanent obliteration of veins⁸⁻¹⁰. We avoided using stronger detergent sclerosant (sodium tetradecyl sulfate) primarily in order to reduce possible complications. Philip Coleridge Smith, who employed a similar technique as we did, has reported an occlusion rate of 88% six months after the treatment of great saphenous vein reflux and 83% after the treatment of small saphenous vein reflux^{8,10}.

The only residual adverse events still present at ≥ 6 month follow up were skin pigmentation and palpable lumps (Figs. 4, 6 and 7). The skin pigmentation was almost always of a minor extent and continued to fade with the passage of time (Fig. 7). However, it was still occasionally seen even a year after the treatment, and there were some (although rather rare) patients who expressed dissatisfaction with treatment results.

Regarding other adverse effects, we noticed dry cough immediately after the treatment in three patients and visual disturbances in one patient, which both resolved within 20 minutes. One patient reported severe headache the day after the treatment and she was advised to use diclofenac pills for pain alleviation. Occasionally, patients complained of thrombophlebitic episodes, i.e. painful, tender and swollen treated veins and surrounding areas, usually within a week after the treatment; they were also advised to use anti-inflammatory pain killers (paracetamol, diclofenac, or ibuprofen) and to take a day or two off work in order to relax. Hot dressings were also advised to be applied on painful areas⁸⁻¹⁰.

Discussion

According to our results and the results reported in the literature⁸⁻¹⁰, foamed sclerosant ablation proved to be a safe and, at shorter/middle terms, very effective treatment for varicose veins, which resulted from the main stem vein reflux. At longer terms (3-year follow up), according to the literature, success rate for strip-

ping, foam sclerotherapy, radiofrequency ablation and laser therapy was 78%, 77%, 84% and 94%, respectively³.

Although thermal ablation with laser or radiofrequency currently competes successfully with foam for treatment of saphenous veins, and ambulatory phlebectomy competes with foam for treatment of tributary veins and localized varicosities, especially when these are large¹⁻⁶, the advantages of foam sclerotherapy over these procedures are as follows: there is no need for high-tech expensive equipment, such as laser, or radiofrequency; there is no need for any kind of anesthesia; it is simpler to perform since passing with laser or radiofrequency catheter through insufficient veins can be hard, especially if these are tortuous. Besides, superficial veins are prone to vasospasm, which can, in particular in inexperienced hands, bring up to complete impossibility to perform endovenous laser or radiofrequency ablation⁴. When compared with ambulatory phlebectomy, the advantage of foam is that there is no need to be trained in this microsurgical procedure, which, in particular in inexperienced hands, can bring to complications such as bleeding, scarring or pain during the procedure, or even infection. In contrast to traditional surgery, no scars, neurologic damage or lymphatic injuries can occur⁸⁻¹⁰.

Besides, the usage of foam is much cheaper than thermal ablation techniques and cheaper than traditional surgery; e.g., in Great Britain, the average cost *per* procedure for sclerosant agent, surgical stripper, laser optic fiber, and radiofrequency ablation catheter, according to Carrol *et al.*, would be £ 5-10, £ 10-20, £ 200-300 and £ 460-578, respectively¹¹. The cost of laser generator would be some £ 20,000, and the cost of radiofrequency generator some £ 10,000¹¹ (these costs in Croatia do not differ significantly from those in Britain). Additional savings with endovenous techniques in comparison with surgery are as follows: there is no need for patient hospitalization; it is sufficient to use solely local anesthesia or, in case of UGFS, one can work without any anesthesia; sick leaves are much shorter; there are savings in staff engagement, etc.¹¹.

Sclerotherapy is chemical ablation of abnormal veins. The goal of therapy is irreversible fibrotic occlusion, followed by reabsorption of the target vessel. Absence of endothelium and subendothelial edema are seen within 2 minutes of foam injection. At 15

minutes, necrosis of the vein wall into the tunica media is seen¹².

Sclerotherapy is an old technique that has been revolutionized by recent technological advances⁷⁻¹⁰. Foaming detergent sclerosants such as polidocanol (Aethoxysklerol) or sodium tetradecyl sulfate (Fibro vein) offer increased patency and could be visualized by means of ultrasonography. Ultrasound guidance allows for better anatomic visualization, greater hemodynamic understanding, more precise foam targeting and delivery, and monitoring for unwanted foam passage into deep veins in greater amounts. With these advances, sclerotherapy has now become a competitive treatment for any type or size of vein⁸⁻¹⁰.

However, possible complications, local and systemic, still have to alert the potential practitioner to be cautious. Systemic complications, such as brain ischemia or deep venous thrombosis represent the biggest threat. Although episodes of brain ischemia have been reported in the literature, we have not experienced any. Besides, all cases reported in the literature have successfully recovered, and, to our knowledge, no tragic cases with permanent neurologic deficit have been reported^{1,3,8-10}. According to the literature, deep venous thrombosis occasionally occurs, but it is usually of minor extent and resolves with anticoagulation therapy, compression stockings, and exercise⁸⁻¹⁰. Dry cough as a side effect occurring immediately after the treatment may be associated with the maximum volume of foam of 18 mL. According to the German Society of Phlebology, the volume of foam is limited to a maximum of 10 mL *per* session¹³, but according to British and American authors, larger amounts of foam (up to 20 mL *per* session) can be administered¹⁰. Besides, there is evidence that the use of carbon dioxide (CO₂) foam reduces the number of post-treatment episodes of visual disturbances and coughing¹⁰. CO₂ is much more soluble in blood and water than nitrogen (in air) and is less likely to travel to more distant organs¹⁰. However, it seems that the classic Tessari technique, i.e. mixing sclerosant with air, still prevails¹⁰. (These two side effects are probably due to the presence of foam in lungs and orbital vessels; it is believed that they might be avoided or diminished if the patient lies supine for some 20-30 minutes after treatment, ref. 10). Local complications such as hard tender lumps, or even thrombophlebitis pose a smaller

threat, but can still upset the patient in a great measure and bring the physician in an unfavorable position, i.e. in need to reassure the patient that everything is happening according to the pre-treatment plan. Patients sometimes can ask other practitioners for help, and these, in particular if not familiar with this method, may employ unnecessary anticoagulation therapy or antibiotics. The commonest side effect is skin darkening (ref. 8-10, Figs. 4, 6 and 7), which, in our experience, affects most of the treated patients to a smaller or greater extent. It does tend to fade and withdraw with time (ref. 8-10, Fig. 7), but in a smaller number of patients it can last for more than a year and some patients may finally express disappointment. Therefore, it is recommended to take photos of varicose vein status¹⁴ before treatment and at follow up sessions in order to be able to present them to the patients in case of complaints. Skin darkening itself also occurs after laser ablation and surgery, but is significantly more frequent after foam sclerotherapy and is likely to impair the patient quality of life¹⁵. According to Smith, it was seen in 115 of 457 limbs after 6 months and in 11 of 115 limbs after 1 year¹⁰.

To conclude, UGFS is easy to perform and is a patient and physician friendly, inexpensive, quick, simplest and least invasive method to solve lower limb superficial venous disease. It has clear advantages over other methods, such as endovenous laser and radiofrequency ablation, ambulatory phlebectomy, and classic surgery, i.e. stripping. However, this method has its disadvantages, i.e. side effects, which both the patient and the physician have to be aware of. Patients and physicians alike should be familiar with pros and cons regarding UGFS and other methods before making final decision on which method of varicose vein treatment to employ.

Since UGFS can also be performed to treat other vascular alterations¹⁶, such as bulging hand veins, vascular malformations, etc., further papers are welcome to clarify the possibilities and disadvantages of UGFS in such circumstances.

Acknowledgments

All patients were examined, treated, followed up, and photographed in Sinteza Clinic, Zagreb, Croatia. The procedures followed the Helsinki Declaration. We thank Dr. Philip Coleridge Smith from the UK

for providing us with Figures 1-3, which depict how to treat main stem vein reflux by means of UGFS.

References

1. Gloviczki P, Comerota AJ, Dalsing MC, Eklof BG, Gillespie DL, Gloviczki ML, *et al.* The care of patients with varicose veins and associated chronic venous diseases: clinical practice guidelines of the Society for Vascular Surgery and the American Venous Forum. *J Vasc Surg.* 2011;53 Suppl 5:S49-65.
2. Mauriello J. Endovenous laser ablation of varicose veins: where are we going? Proceedings of International Union of Angiology World Congress. 2010 Apr 21-25; Buenos Aires, Argentina. Milano: International Endovenous Laser Working Group; 2010. p. 77-82.
3. van den Bos R, Arends L, Kockaert M, Neumann M, Nijsen T. Endovenous therapies of lower extremity varicosities: a meta-analysis. *J Vasc Surg.* 2009;49:230-9.
4. Krnic A, Susic Z. Bipolar radiofrequency induced thermotherapy and 1064 nm Nd:Yag laser in endovenous occlusion of insufficient veins: short term follow up results. *Vasa.* 2011;40:235-40.
5. Luebke T, Brunkwall J. Systematic review and meta-analysis of endovenous radiofrequency obliteration, endovenous laser therapy, and foam sclerotherapy for primary varicosis. *J Cardiovasc Surg (Torino).* 2008;49:213-33.
6. Gonzalez-Zeh R, Armisen R, Barahona S Endovenous laser and echo-guided foam ablation in great saphenous vein reflux: one-year follow-up results. *J Vasc Surg.* 2008;48:940-6.
7. Tessari L, Cavezzi A, Frullini A. Preliminary experience with a new sclerosing foam in the treatment of varicose veins. *Dermatol Surg.* 2001;27:58-60.
8. Smith PC. Chronic venous disease treated by ultrasound guided foam sclerotherapy. *Eur J Vasc Endovasc Surg.* 2006;32:577-83.
9. Bergan J. Sclerotherapy: a truly minimally invasive technique. *Perspect Vasc Surg Endovasc Ther.* 2008;20:70-2.
10. Smith PC. A personal method for foam sclerotherapy: technique and results. In: Bergan J, Cheng VL, editors. *Foam Sclerotherapy, a Textbook.* London: Royal Society of Medicine Press Ltd; 2008. p. 69-79.
11. Carroll C, Hummel S, Leaviss J, Ren S, Stevens JW, Everson-Hock E, *et al.* Clinical effectiveness and cost-effectiveness of minimally invasive techniques to manage varicose veins: a systematic review and economic evaluation. *Health Technol Assess.* 2013 Oct;17(48):i-xvi,1-141.
12. Orsini C, Brotto M. Immediate pathologic effects on the vein wall of foam sclerotherapy. *Dermatol Surg.* 2007;33:1250-4.
13. Rabe E, Pannier F, Gerlach H, Xaver Breu F, Guggenbichler S, Wollmann JCGR. Sclerotherapy of varicose veins – Guidelines of the German Society of Phlebology. In: Bergan J, Cheng VL, editors. *Foam Sclerotherapy, a Textbook.* Lon-

- don: Royal Society of Medicine Press Ltd; 2008. p. 31-41.
14. Bašić R, Rosić D, Ledinsky I, Lovričević I. Orthostatics and chronic venous insufficiency in Croatian doctors of dental medicine. *Acta Clin Croat.* 2014;53:3-6.
 15. Brittenden J, Cotton SC, Elders A, Ramsay CR, Norrie J, Burr J, *et al.* A randomized trial comparing treatments for varicose veins. *N Engl J Med.* 2014;371:1218-27.
 16. Bergan J, Cheng VL. Treatment of venous malformations, Klippel-Trénaunay syndrome and other low-flow lesions with foamed sclerosants. In: Bergan J, Cheng VL, editors. *Foam Sclerotherapy, a Textbook.* London: Royal Society of Medicine Press Ltd; 2008. p. 219-224.

Sažetak

ULTRAZVUČNO VOĐENA SKLEROZACIJA PJENOM – NAJJEDNOSTAVNIJA, NAJMANJE INVAZIVNA I NAJJEFTINIJA METODA LIJEČENJA PROŠIRENIH VENA

A. Krnić

Cilj ovoga rada je prikazati naša iskustva i mišljenja vezano za liječenje proširenih vena upotrebom ultrazvučno vođene sklerozacije pjenom (engl. *ultrasound guided foam sclerotherapy*, UGFS). U studiju smo uključili 81 bolesnika: 54 s insuficijentnim površinskim venama glavnog stabla u jednoj nozi i 27 bolesnika kod kojih su bile zahvaćene obje noge. U 68 nogu dijagnosticirali smo insuficijenciju vene safene magne (lat. *vena saphena magna*), u 18 vene safene parve (lat. *vena saphena parva*), u 11 anteriorne akcesorne safenske vene, a u 3 noge insuficijenciju Giacominijeve vene. Sedam nogu imalo je kombiniranu insuficijenciju vene safene magne i vene safene parve, a 1 noga kombiniranu insuficijenciju Giacominijeve vene i vene safene parve. Koristili smo UGFS da bismo liječili insuficijenciju u venama glavnog stabla, kao i u njihovim pritocima. Unutar mjesec dana nakon tretmana sve vene glavnog stabla bile su okludirane te su bile potrebne samo povremene manje korekcije u smislu tretmana rezidualnih varikoziteta. Što se tiče nuspojava, najčešće smo znali uočiti zatamnjenja kože i tvrde grudice na mjestima varikoznih vena. Također smo uočili i nekoliko epizoda tromboflebitisa. Vrlo malo bolesnika imalo je suhi kašalj, smetnje vida i glavobolje nakon tretmana. Kod malog broja bolesnika trebalo je ponoviti UGFS na venama glavnog stabla nakon 6 mjeseci. Vrlo malo bolesnika iskazivalo je nezadovoljstvo godinu dana nakon tretmana, uglavnom zbog rezidualnih zatamnjenja kože. U zaključku, UGFS se pokazala kao najjednostavnija, najbrža i najjeftinija metoda liječenja proširenih vena. Prema našim iskustvima, ova metoda postiže zadovoljavajuće funkcionalne i kozmetičke rezultate. Nuspojave se mogu javiti, ali su prihvatljive, osobito gledajući dugoročno.

Ključne riječi: *Skleroterapija – metode; Varikozne vene – terapija; Ultrazvuk, intervencijski – metode; Donji ekstremitet; Hiperpigmentacija*