

PARTIAL TOPOGRAPHY-GUIDED PHOTOREFRACTIVE KERATECTOMY FOLLOWED BY CORNEAL CROSS LINKING IN THE MANAGEMENT OF PROGRESSIVE KERATOCONUS: OUR INITIAL TEN-MONTH RESULTS

Igor Knezović¹, Mirna Belovari Višnjić² and Hrvoje Raguž³

¹Department of Ophthalmology, Dubrava University Hospital, Zagreb; ²Department of Ophthalmology, Čakovec General Hospital, Čakovec; ³Knezović Vision Group Eye Center, Zagreb, Croatia

SUMMARY – The aim was to assess the results achieved in keratoconic corneas submitted to the combined partial topography-guided photorefractive keratectomy (TG-PRK) and corneal cross linking (CXL) procedure performed on the same day. Four patients underwent this treatment of one eye. Corneal epithelium removal was performed by 50-micron phototherapeutic keratectomy. Then, partial TG-PRK laser treatment was applied (Wavelight Allegretto, Eye Q, 400Hz), followed by corneal collagen cross-linking (CXL, 3 mW/cm²) for 30 minutes using 0.1% topical riboflavin solution. Outcome measurements included uncorrected distance visual acuity (UCDVA), best spectacle corrected distance visual acuity (BSCDVA), manifest refraction spherical equivalent, keratometry, corneal high order aberration values, and corneal tomography. At the end of 10-month follow up, all eyes showed improvement in BSCDVA of 1-5 lines on Snellen chart. All other investigated parameters showed significant improvement as well. One eye showed some topographic improvement, but no improvement in UCDVA. No corneal haze, prolonged epithelial healing or endothelial cell loss occurred. During 10-month follow up, the same-day combined TG-PRK and CXL appeared to offer tomographic improvement and better visual acuity in keratoconus patients.

Key words: *Keratoconus; Photorefractive keratectomy; Topography-guided photorefractive keratectomy; Corneal diseases – surgery; Corneal cross-linking*

Introduction

A number of treatments, for example, corneal collagen cross linking (CXL)¹, intrastromal corneal ring segment implantation², conductive keratoplasty³, and phakic intraocular lenses⁴ can be included in the management of keratoconus patients. In the last decade, corneal collagen cross linking has shown promising results in the treatment of keratoconus by slowing down or halting its progression⁵. This procedure is also useful in the treatment of postoperative LASIK

ectasia as a noninvasive treatment that delays the need of penetrating keratoplasty⁶. One of the latest therapeutic treatments includes the same-day simultaneous topography-guided photorefractive keratectomy (TG-PRK) and corneal collagen CXL procedure, also known as Athens protocol^{7,8}. This treatment, especially if done as a same-day procedure, achieves corneal biomechanical stability and better visual rehabilitation⁸. Results of this combined procedure are best evident in patients with highly irregular corneas who are not adapted to contact lens wear.

Correspondence to: *Igor Knezović, MD, PhD, Knezović Vision Group, Ulica grada Vukovara 269f, HR-10000 Zagreb, Croatia*
E-mail: igor@knezovic.com.hr

Received September 8, 2014, accepted January 19, 2015

Patients and Methods

The time span of this procedure, which was performed on one eye in four patients, lasted from August

2013 until May 2014. All study patients were male, mean age 31.16 ± 4.27 years. In each patient, the procedure consisted of partial TG-PRK followed by corneal CXL. Prior to the procedure, all study patients signed the informed consent form accepting the terms of the procedure. The criteria set out before the study were second and third stage keratoconus according to Amsler Krumeich classification, preoperative best spectacle corrected distance visual acuity (BSCDVA) of 0.4 on each eye, and corneal thickness more than 450 microns at the thinnest location. Exclusion criteria were first and fourth stage keratoconus, previous trauma or surgical procedure on the eye, and disease status that could delay the cornea healing process. During a 6-month period before the procedure evaluation, keratoconus progression was marked as one or more of the following changes: increase ≥ 0.5 D in manifest refraction spherical equivalent (MRSE) and increase ≥ 1 D in anterior sagittal curvature corneal topographic maps. All patients were intolerant to contact lens wear. Also, 3 weeks before the procedure and just before the surgery, eye examination was performed. The following measurements were performed to complete evaluation of keratoconic corneas: endothelial cell microscopy, axial length scans automated keratometry, anterior spectral domain optical coherence tomography and corneal tomography, providing the best treatment for each individual patient.

The Wavelight Allegro Oculyzer (Alcon Laboratories Inc., Fort Worth, Texas, USA) provides an accurate three-dimensional view of the cornea and separate approach to refractive surgery using a rotation Scheimpflug camera in all meridians. Objective determination of corneal topography, 3D analysis of anterior chamber, overall pachymetry, tomographic analysis, and lens density measurement are also included in this examination⁹. The Oculyzer software compares the measurements of corneal asymmetry indices with the mean and standard deviation of a normal population¹⁰. In our study, the following parameters were especially monitored: index of surface variance (ISV), index of vertical asymmetry (IVA), index of height asymmetry (IHA) and index of height decentration (IHD). ISV marks standard deviation of individual corneal sagittal radii from the mean curvature; normal value is less than 37¹⁰; IVA is the mean difference between superior and inferior corneal curvature ex-

pressed in mm^{10} ; a value greater than 0.32 is pathologic; IHA is the mean difference between height values superior minus height values inferior with horizontal meridian as mirror axis expressed in μm , and a value greater than 21 is pathologic¹⁰; IHD provides the degree of decentration in vertical direction, calculated on a ring with 3-mm radius; it is expressed in μm and pathologic value is greater than 0.016¹⁰.

Non-contact, high magnification image capture of the endothelium is enabled by a specular microscope CEM 530 (Nidek Co. Ltd. Japan), which provides observation of the shape and size of the cells. Also, apart from conventional central and peripheral specular microscopy, this microscope also has a unique function of capturing paracentral images, which automatically gives complete analysis in two seconds¹¹.

Measurement of the following six values in 10 seconds is enabled by the optical biometer axial length scan (AL scan, Nidek Co. Ltd., Japan): corneal curvature radius, pupil size, axial length, anterior chamber depth, white-to-white distance, and central corneal thickness¹².

Analysis of the anterior eye segment with a resolution of 3 microns is enabled by spectral-domain optical coherence tomography (SOCT Copernicus, Optopol Technology S.A., Zawiercie, Poland). The tomography records pachymetry maps and measures corneal epithelial thickness¹³.

Surgical technique

Wavelight Allegretto Eye Q 400 Hz excimer laser device was used for conducting phototherapeutic keratectomy (PTK) and TG-PRK. After these procedures, we conducted corneal collagen CXL using a CXL device, wavelength 370 nm (CSO VEGA CMB X Linker, Florence, Italy).

The first step to prepare the patient for this combined procedure was to apply the topical anesthetic oxybuprocaine hydrochloride 0.4% eye drops; then PTK was performed on the central 7.0 mm zone with 50 micron ablation depth for epithelium removal. Partial TG-PRK was performed on a 5.5 optical zone (OZ), desired refraction was settled to save the corneal tissue and keep residual stroma within a boundary of 380–400 microns before corneal CXL treatment¹⁴.

Corneal haze was prevented by applying mitomycin C 0.02% on the stromal surface for a period of

30 seconds. When applied on the cornea, this anti-neoplastic agent regulates fibroblast proliferation and myofibroblast formation, which is responsible for corneal haze after PRK^{15,16}.

Riboflavin solution 0.1% (Sooft, Italy) was applied over the corneal surface every 2 minutes during a 20 minute period to allow its absorption throughout the corneal stroma into the anterior chamber, which was confirmed by slit lamp biomicroscopy.

After corneal alignment, collagen CXL was applied on the corneal surface for 30 minutes (UVA 370 nm light at the irradiance of 3.0mW/cm²). Riboflavin was applied every 2 minutes during UVA exposure. Before the CXL and every 5 minutes during the pro-

cedure, ultrasound pachymetry measurement was performed. If the corneal thickness was reduced to less than 380 microns, a balanced salt solution was applied on its surface to swell the cornea. Postoperatively, a bandage soft contact lens was placed on the eye for 3-5 days and was removed after epithelium regeneration. Anti-inflammatory eye drops were administered after the procedure according to our protocol. The patients applied antibiotic eye drops five times a day for seven days and corticosteroid eye drops four times a day for the first two weeks. After the first two weeks, the patients gradually reduced the corticosteroid eye drops every fourteen days for the next few weeks.

Table 1. Descriptive statistics

	N	Mean	Std. Deviation	Minimum	Maximum	Percentiles		
						25th	50th (Median)	75th
UCDVA (decimal)	4	0.1625	0.09465	0.10	0.30	0.1000	0.1250	0.2625
BSCDVA (decimal)	4	0.6250	0.17078	0.40	0.80	0.4500	0.6500	0.7750
MRSE (D)	4	-3.2500	1.56791	-5.25	-2.00	-4.8750	-2.8750	-2.0000
MeanK (D)	4	49.3500	2.61087	46.20	52.30	46.7750	49.4500	51.8250
Kmax (D)	4	55.4000	4.70956	49.40	60.70	50.7250	55.7500	59.7250
ISV	4	83.5000	11.09054	70.00	97.00	73.0000	83.5000	94.0000
IVA (mm)	4	0.7050	0.30293	0.43	1.10	0.4500	0.6450	1.0200
IHA (µm)	4	34.5250	14.42460	17.50	49.90	20.2250	35.3500	48.0000
IHD (µm)	4	0.0600	0.02676	0.03	0.09	0.0325	0.0640	0.0835
Coma0	4	-0.1638	1.03782	-1.71	0.52	-1.2273	0.2670	0.4690
Coma90	4	-1.8920	1.02315	-2.91	-0.91	-2.8380	-1.8740	-0.9640
Spherical aberration	4	-0.5598	0.11697	-0.69	-0.42	-0.6715	-0.5625	-0.4453
ECC (cell/mm ²)	4	2708.0000	101.28179	2583.00	2820.00	2607.0000	2714.5000	2802.5000
UCDVA1 (decimal)	4	0.5250	0.22174	0.30	0.80	0.3250	0.5000	0.7500
BSCDVA1 (decimal)	4	0.8250	0.17078	0.60	1.00	0.6500	0.8500	0.9750
MRSE1 (D)	4	-1.7500	0.95743	-3.00	-1.00	-2.7500	-1.5000	-1.0000
MeanK1 (D)	4	46.9250	2.37960	44.00	49.40	44.5250	47.1500	49.1000
Kmax1 (D)	4	51.9621	2.0113	49.30	52.20	51.3020	50.6700	49.2600
ISV1	4	66.2500	11.98263	51.00	80.00	54.5000	67.0000	77.2500
IVA1 (mm)	4	0.4450	0.26715	0.19	0.80	0.2175	0.3950	0.7225
IHA1 (µm)	4	13.3500	13.05488	3.40	31.90	3.8250	9.0500	27.1750
IHD1 (µm)	4	0.0283	0.01650	0.00	0.04	0.0115	0.0340	0.0393
Coma01	4	-0.2940	0.79095	-1.48	0.18	-1.1063	0.0580	0.1663
Coma901	4	-1.3975	1.25194	-2.80	-0.04	-2.6100	-1.3775	-0.2050
Spherical aberration1	4	-0.1370	0.38632	-0.54	0.39	-0.4610	-0.1970	0.2470
ECC1 (cell/mm ²)	4	2693.5000	80.06039	2612.00	2802.00	2625.2500	2680.0000	2775.2500

Results

The patients were followed up and examined for a 10-month period during the study. Preoperative and postoperative visual and refractive data are summarized in Table 1.

Visual acuity and refraction

Both uncorrected distance visual acuity (UCDVA) and BSCDVA were significantly improved ten months after the procedure. The mean value of UCDVA increased from 0.1625 to 0.5250, while the values of BSCDVA improved from 0.6250 to 0.8250. MRSE decreased from -3.2500 to -1.7500.

Keratometric values

These values were monitored before the procedure and at the end of 10-month follow up as the mean keratometric value (Mean K) and maximal kerato-

metric value (K max). Comparison of the Mean K and K max before the procedure and at the end of follow up yielded statistically significant changes in both Mean K and K max toward normal keratometric values (Table 1).

Corneal indices

The corneal indices observed were ISV, IVA, IHA and IHD. All data on the corneal indices were taken by rotating Scheimpflug camera (Wavelight Allegro Oculyzer, Germany). The information displayed in Table 1 clearly shows that all measures changed and normalized during the period of observation. However, these changes were considerably more pronounced in the elevation based indices (IHA and IHD) as compared with the surface based indices.

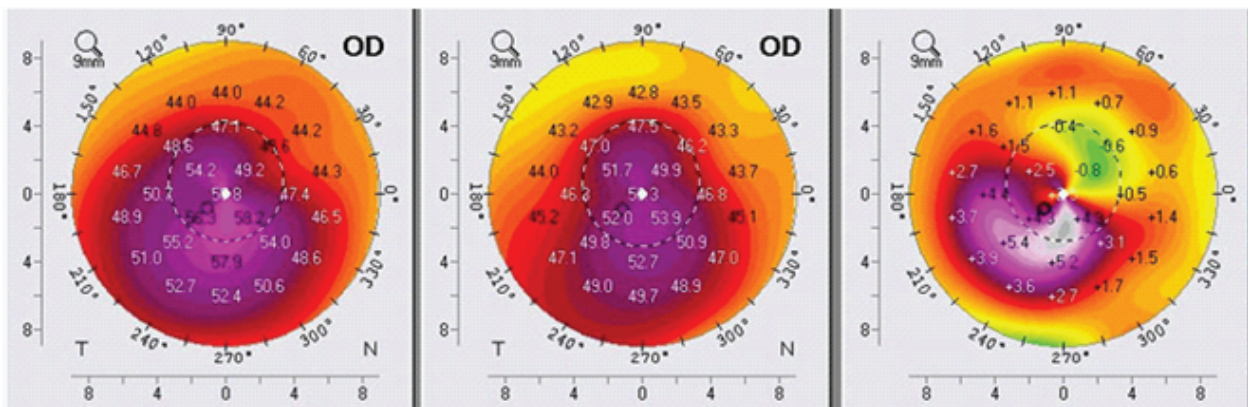


Fig. 1. Pre- and postoperative Scheimpflug tomography (anterior sagittal curvature map): right eye – patient 1.

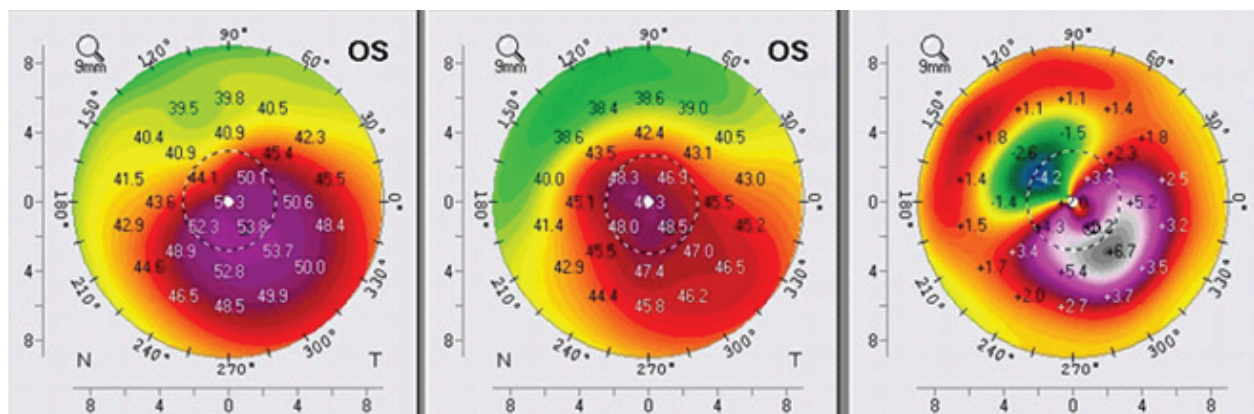


Fig. 2. Pre- and postoperative Scheimpflug tomography (anterior sagittal curvature map): left eye – patient 2.

Aberrometric results

The corneal high order aberrations (CHOA) presented as coma 0, coma 90, and spherical aberration. The results measured with the Wavelight Allegro Oculyzer showed improvement toward ideal corneal values according to Zernike analysis, except for coma 0^{17,18}.

Topographic results

Topographic improvement was analyzed in the anterior sagittal curvature topographic view using the Wavelight Allegro Oculyzer (Figs. 1, 2, 3 and 4). Each figure consists of three images: preoperative topography image on the left panel; postoperative image on the mid-panel, showing remarkable topographic normalization; and a difference map between preoperative and postoperative keratometric values on the right

panel. The profile of customized topography-guided excimer laser ablation is clearly visible.

Healing process and patient subjective satisfaction

No severe complications were reported after the treatment. All patients indicated some degree of pain during the first two days after the procedure and mild discomfort during the first month. Complete reepithelialization occurred within five days in all cases. No prolonged healing, corneal haze, infection or systemic adverse events were recorded.

Discussion

Modern diagnostic devices have enabled precise diagnosis and the opportunity for correction of irregular astigmatism, which is particularly pronounced

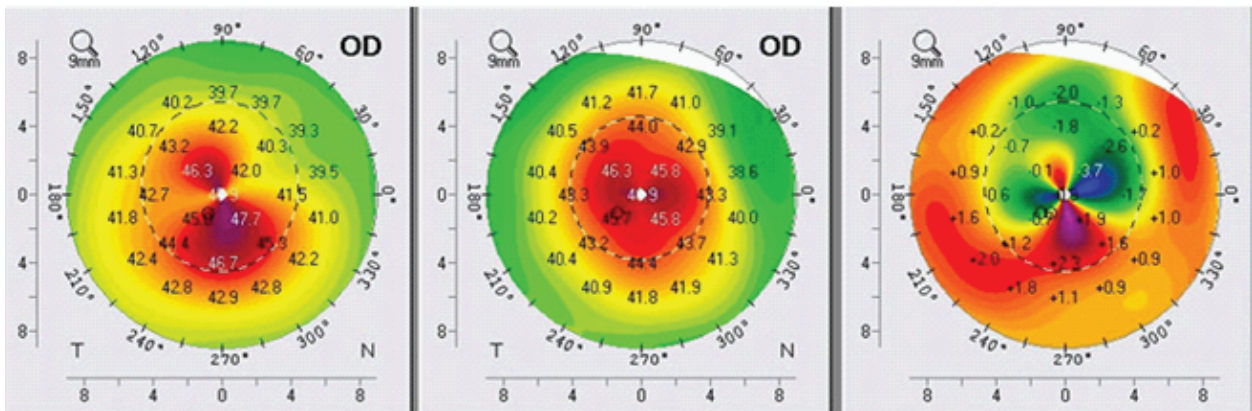


Fig. 3. Pre- and postoperative Scheimpflug tomography (anterior sagittal curvature map): right eye – patient 3.

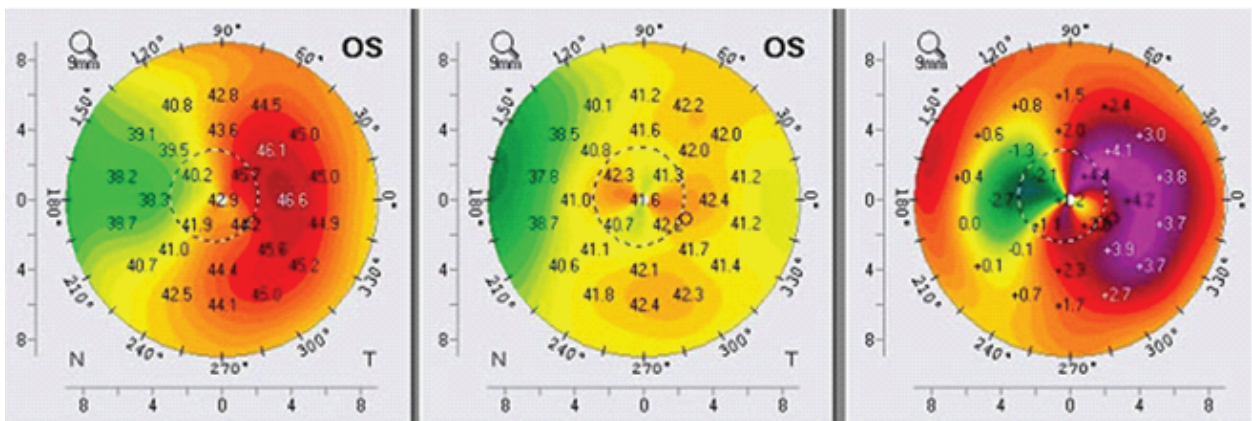


Fig. 4. Pre- and postoperative Scheimpflug tomography (anterior sagittal curvature map): left eye – patient 4.

in patients with keratoconus¹⁹. The main problems in keratoconus patients are corneal biomechanical instability and poor quality of vision, so the treatment of keratoconus represents a big challenge to many corneal surgeons worldwide. One of the first studies dealing with this topic, published by Kanellopoulos and Binder in 2007, presented CXL with sequential TG-PRK as an alternative to penetrating keratoplasty. Results showed significant clinical improvement and corneal stability over more than one-year of follow up. The following imperfections of this approach were observed: the central superficial part of the stiffened cross linked cornea was removed with PRK, thus reducing the benefits of CXL, and the corneal ablation rate after CXL was different in cross linked corneas with unpredictable refractive results compared to PRK in virgin corneas¹⁹. In 2009, Kanellopoulos published a study comparing sequential with same-day CXL and TG-PRK. This study found the same-day procedure to be superior to the sequential procedure in progression of keratoconus and better visual rehabilitation⁷. In the same year, Kymionis *et al.* reported on the results of TG-PRK immediately followed by CXL as an efficient treatment to manage this problem²¹. In 2012, Tuwairqui and Sinjab evaluated 1-year visual and refractive outcome and patient satisfaction after simultaneous CXL combined with TG-PRK in the eyes with low-grade keratoconus. Corneal topography showed improvement in all treated eyes and overall

better experience in visual outcome and rehabilitation¹⁴. In our study, we evaluated the results of partial TG-PRK immediately followed by CXL in the eyes with moderate grade (stage II-III) keratoconus. Partial TG-PRK was performed to provide better postoperative visual acuity, but also to spare the thinned corneal tissue. The role of CXL is to provide better corneal biomechanical stability and halt the progression of keratoconus. BSCDVA and corneal topography parameters were significantly improved ten months after the procedure in all eyes, however, with different degrees. After removal of the Bowman layer with PTK and partial TG-PRK, imbibition of the corneal tissue with riboflavin is faster and UVA irradiation is more homogeneous, so we believe that the CXL after TG-PRK can be more effective than usual. Corneal compressive forces are redistributed, resulting in decreased corneal power on the apex, which can be explained by topography normalization. In their study published in June 2014, Hammer *et al.* proved tightening of the corneal tissue by more than 100% and efficacy of more than 95% after CXL²². In our study, demarcation line visualized on the spectral-domain anterior segment optical coherence tomography was more pronounced centrally in comparison with the nasal and temporal depth, which is consistent with the study by Kymionis *et al.* published in 2013²³ (Fig. 5).

Combined, same-day partial topography-guided excimer laser treatment followed by corneal collagen CXL proved to be an effective, safe and increasingly predictable therapeutic option for keratoconic and highly aberrated corneas during 10-month follow up. This procedure provided significant improvement in UCDVA, BSCDVA, keratometric and topographic normalization, as compared to CXL alone.

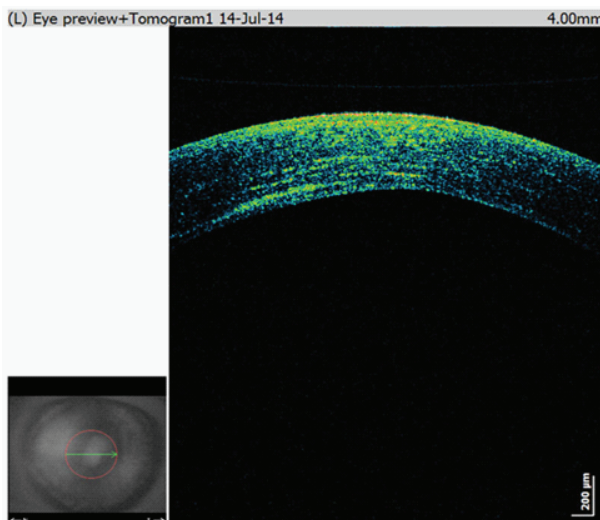


Fig. 5. Spectral domain anterior optical coherence tomography showing demarcation line.

References

1. Leccisotti A, Islam T. Transepithelial corneal collagen cross linking in keratoconus. *J Refract Surg.* 2010;26(12):942-8.
2. Alio JL, Toffaha BT, Pifero DP, Klonowski P, Javaloy J. Cross-linking in progressive keratoconus using an epithelial debridement or intrastromal pocket technique after previous corneal ring segment implantation. *J Refract Surg.* 2011;27(10):737-43.
3. Alio JL, Claramonte PJ, Caliz A, Ramzy MI. Corneal modelling of keratoconus by conductive keratoplasty. *J Cataract Refract Surg.* 2005;31(1):190-7.
4. Sedaghat M, Ansari-Astaneh MR, Zarei-Chanavati M,

- Davis SW, Sikder S. Artisan iris-supported phakic IOL implantation in patients with keratoconus: a review of 16 eyes. *J Refract Surg.* 2011;27(7):489-93.
5. Wollensack G, Spoerl E, Seiler T. Riboflavin/ultraviolet-A-induced collagen cross linking for the treatment of keratoconus. *Am J Ophthalmol.* 2003;135(5):620-7.
 6. Hafezi F, Kanellopoulos AJ, Wiltfang R, Seiler T. Corneal collagen cross linking with riboflavin and ultraviolet A to treat induced keratectasia after laser *in situ* keratomileusis. *J Cataract Refract Surg.* 2007;33(12):2035-40.
 7. Kanellopoulos AJ. Comparison of sequential *vs* same-day simultaneous collagen cross-linking and topography-guided PRK for treatment of keratoconus. *J Refract Surg.* 2009;25(9):S812-S818.
 8. Kanellopoulos AJ. Combining topography-guided PRK with CXL: The Athens Protocol. *Cataract & Refractive Surgery Today Europe*, May 2010.
 9. Cummings AB, Mascharka N. Outcomes after topography-based LASIK and LASEK with the wavelight oculyzer and topolyzer platforms. *J Refract Surg.* 2010 Jul;26(7):478-85.
 10. Kanellopoulos AJ, Asimellis G. Revisiting keratoconus diagnosis and progression classification based on evaluation of corneal asymmetry indices, derived from Scheimpflug imaging in keratoconic and suspect cases. *Clin Ophthalmol.* 2013;7:1539-48.
 11. McMonnies CW. Corneal endothelial assessment with special references to keratoconus. *Optom Vis Sci.* 2014 Jun;91(6):e124-34.
 12. Huang J, Savini G, Li J, Lu W, Wu F, Wang J, Li Y, Feng Y, Wang Q. Evaluation of a new optical biometry device for measurements of ocular components and its comparison with IOLMaster. *Br J Ophthalmol.* 2014 May 2. doi: 10.1136/bjophthalmol-2014-305150.
 13. Kaluzny BJ, Kaluzny JJ, Szkulmowska A, Gorczynska I, Szkulmowski M, Bajraszewski T, Wojtkowski M, Targowski P. Spectral optical coherence tomography: a novel technique for cornea imaging. *Cornea.* 2006;25:960-5.
 14. Tuwairqui WS, Sinjab MM. Safety and efficacy of simultaneous corneal collagen cross-linking with topography-guided PRK in managing low-grade keratoconus: 1 year follow up. *J Refract Surg.* 2012;28(5):341-5.
 15. Danshiitsoodol N, de Pinho CA, Matoba Y, Kumagai T, Sugiyama M. The mitomycin C (MMC)-binding protein from MMC-producing microorganisms protects from the lethal effect of bleomycin: crystallographic analysis to elucidate the binding mode of the antibiotic to the protein. *J Mol Biol.* 2006;360:398-408.
 16. Tomasz M. Mitomycin C: small, fast and deadly (but very selective). *Chem Biol.* 1995;2:575-9.
 17. Oliveira CM, Ferreira A, Franco S. Wavefront analysis and Zernike polynomial decomposition for evaluation of corneal optical quality. *J Cataract Refract Surg.* 2012 Feb;38(2):343-56.
 18. Jinabhai A, Radhakrishnan H, O'Donnell C. Repeatability of ocular aberration measurements in patients with keratoconus. *Ophthalmic Physiol Opt.* 2011 Nov;31(6):588-94.
 19. Višnjčić MB, Zrinščak O, Barišić F, Iveković R, Lauš KN, Mandić Z. Astigmatism and diagnostic procedures. *Acta Clin Croat.* 2012 Jun;51(2):285-8.
 20. Kanellopoulos AJ, Binder PS. Collagen cross-linking (CCL) with sequential topography-guided PRK: a temporizing alternative for keratoconus to penetrating keratoplasty. *Cornea.* 2007;26(7):891-5.
 21. Kymionis GD, Kontadakis GA, Kounis GA, *et al.* Simultaneous topography-guided PRK followed by corneal collagen cross-linking for keratoconus. *J Refract Surg.* 2009;25(9):S807-S811.
 22. Hammer A, Tabibian D, Richoz O, Hafezi F. Keratoconus treatment by corneal cross-linking (CLX). *Rev Med Suisse.* 2014 Jun 4;10(433):1263-5.
 23. Kymionis GD, Grentzelos MA, Plaka AD, Stojanovic N, Tsoulnaras KI, Mikropoulos DG, Rallis KI, Kankariya VP. Evaluation of the corneal collagen cross-linking demarcation line profile using anterior segment optical coherence tomography. *Cornea.* 2013 Jul;32(7):907-10.

Sažetak

PARCIJALNA TOPOGRAFSKI VOĐENA FOTOREFRAKTIVNA KERATEKTOMIJA I KORNEALNI
CROSS LINKING U LIJEČENJU PROGRESIVNOG KERATOKONUSA: NAŠI POČETNI
DESETOMJESEČNI REZULTATI*I. Knezović, M. Belovari Višnjić i H. Raguž*

Cilj je prikazati kliničke rezultate kod rožnica s keratokonusom liječenih parcijalnom topografski vođenom fotorefraktivnom keratektomijom (engl. *topography-guided photorefractive keratectomy*, TG-PRK) i rožničnim kolagenim "*cross linking*" (CXL) u kombiniranom istodnevnom postupku. U ovaj postupak na jednom oku su bila uključena četiri bolesnika. Za uklanjanje rožničnog epitela je primijenjena fototerapijska keratektomija, 50 mikrona. Nakon toga je primijenjena parcijalna TG-PRK (Wavelight Allegretto, Eye Q, 400 Hz) te rožnični kolageni CXL (3 mW/cm²) kroz 30 minuta uz primjenu 0,1% otopine riboflavina. Izlazna mjerenja su pratila nekorogiranu vidnu oštrinu na daljinu, najbolje korigiranu naočalnu vidnu oštrinu na daljinu, manifestni refrakcijski sferni ekvivalent, keratometriju, rožnične aberacije višeg reda i rožničnu tomografiju. Kod svih očiju je zabilježeno poboljšanje najbolje korigirane naočalne vidne oštrine na daljinu (1-5 redova na Snellenovim optotipima) tijekom i na kraju desetomjesečnog praćenja. Ostali istraživani parametri su također pokazali značajno poboljšanje. Na jednom oku je zamijećeno topografsko poboljšanje, bez poboljšanja nekorogirane vidne oštrine na daljinu. Nije zabilježeno zamučenje rožnice, produljeno cijeljenje epitela niti gubitak endotelne stanice. Kombinirani istodnevni postupak parcijalne TG-PRK i rožničnog kolagenog CXL rezultirao je topografskom normalizacijom i boljom vidnom oštrinom kod bolesnika s keratokonusom tijekom desetomjesečnog praćenja.

Ključne riječi: *Keratokonusus; Fotorefraktivna keratektomija; Topografski vođena fotorefraktivna keratektomija; Kornealne bolesti – kirurgija; Kornealni "cross linking"*