

## STROMAL REACTION IN SYNCHRONOUS *IN SITU* AND INVASIVE UROTHELIAL CARCINOMA OF THE BLADDER

Ante Reljić<sup>1</sup>, Davor Tomas<sup>2</sup>, Tereza Gabelić<sup>2</sup>, Jelena Zarubica<sup>3</sup>, Stela Bulimbašić<sup>4</sup>, Hana Fazlić<sup>2</sup>, Hrvoje Čupić<sup>2</sup> and Božo Krušlin<sup>2</sup>

<sup>1</sup>University Department of Urology and <sup>2</sup>Ljudevit Jurak University Department of Pathology, Sestre milosrdnice University Hospital, Zagreb; <sup>3</sup>Department of Pathology, Pula General Hospital, Pula; <sup>4</sup>Department of Pathology, Sveti Duh General Hospital, Zagreb, Croatia

**SUMMARY** – The aim was to investigate stromal reaction, including inflammation and stromal desmoplasia in *in situ* and invasive urothelial carcinoma of urinary bladder and to determine the possible value of reactive stromal changes in the diagnosis of lamina propria invasion. We analyzed specimens from 24 consecutive patients with synchronous *in situ* and invasive urothelial carcinoma in the same biopsy. Specimens were obtained by transurethral resection, fixed and routinely stained with H&E and Mallory method. Immunohistochemistry was performed by monoclonal antibodies to vimentin, smooth muscle actin and desmin. The intensity of immunostaining was graded semiquantitatively on a scale of 0-3, and expressed as 0 = 0%; 1 = up to 33%; 2 = more than 33% to 66%; and 3 = more than 66% of positive stromal cells. The intensity of inflammation was labeled as 0 = no inflammation, 1 = weak, 2 = moderate, and 3 = dense inflammatory reaction. Mallory trichrome method showed predominantly no staining or weak green staining in 14/24 invasive and 20/24 *in situ* urothelial carcinomas ( $p > 0.05$ ). There was statistically significantly increased vimentin and smooth muscle actin immunostaining in the stroma of invasive carcinoma as compared with *in situ* carcinoma ( $p < 0.05$ ). Inflammatory reaction was statistically stronger in invasive carcinoma ( $p < 0.05$ ). The immunohistochemical expression of myofibroblastic markers was significantly stronger in invasive urothelial carcinoma. This may aid in the diagnosis of lamina propria invasion in urothelial carcinoma of urinary bladder.

**Key words:** *Bladder neoplasms – pathology; Bladder neoplasms – diagnosis; Urothelium – pathology; Urologic neoplasms – classification; Stromal cells – pathology*

### Introduction

Morphological evidence of host participation in cancer invasion and metastasis is desmoplasia, consisting of fibroblast-like cells and extracellular matrix (ECM) remodeling, inflammation and immune response represented by lymphocytes, macrophages and dendritic cells, and angiogenesis with newly formed blood and lymph vessels<sup>1</sup>.

Studies of human breast, colon and prostatic carcinoma have identified activated stromal cell phenotypes, modified extracellular matrix composition, and increased microvessel density, exhibiting biological markers consistent with stroma at the site of wound repair<sup>1-7</sup>.

Myofibroblast seems to play a very important role in stromal reaction to invasion in different carcinomas, including urothelial carcinoma (UC) of the bladder<sup>2-7</sup>. Myofibroblasts are mesenchymal cells sharing characteristics with smooth muscle cells and fibroblasts, and have the ability to secrete large amounts of matrix molecules such as collagens and proteoglycans<sup>8,9</sup>. The origin of myofibroblasts remains controversial but some authors have shown that during migration towards can-

Correspondence to: Božo Krušlin, MD, PhD, Ljudevit Jurak University Department of Pathology, Sestre milosrdnice University Hospital, Vinogradska c. 29, HR-10000 Zagreb, Croatia  
E-mail: bkrušlin@kbsm.hr

Received April 28, 2006, accepted July 25, 2006

cer cells fibroblasts encounter a higher concentration of TGF- $\beta$ , leading to their transdifferentiation into myofibroblasts<sup>10</sup>. The appearance of myofibroblasts precedes the invasive stage of cancer<sup>8</sup>. Myofibroblasts not only stimulate cancer cell invasion but also angio- and lymphangiogenesis<sup>11</sup>.

Stromal response in *in situ* carcinomas is in the majority of cases associated with mononuclear inflammatory reaction in underlying lamina propria<sup>7</sup>. These inflammatory cells represent a class of host cells that are regulated by cytokine balance and perform counter-current invasion from the circulation into the tumor vicinity<sup>7</sup>.

One of the most important pathological features in bladder neoplasms is recognition of the presence and extent of lamina propria invasion<sup>12</sup>. Patients with grade 1 noninvasive papillary neoplasm would have about 90% chance for 20-year survival despite a number of recurrences<sup>13</sup>. On the contrary, patients with lamina propria invasion will survive 5 years in 75% of cases<sup>14</sup>.

Occasionally it is quite difficult to identify the foci of lamina propria invasion in urothelial carcinoma. The criteria for urothelial carcinoma invasion are isolated cells or small nests, larger cells and cell nuclei, and marked cytoplasmic eosinophilia relative to the surface epithelium. The foci of invasion are often single and solid but may be mixed with papillary carcinoma and other growth patterns<sup>13,15</sup>.

The aim of this study was to analyze stromal reaction in invasive and *in situ* UC, and to estimate their possible value in the diagnosis of lamina propria invasion.

## Materials and Methods

From the Urologic Pathology computer database at Ljudevit Jurak University Department of Pathology, all data regarding urothelial carcinoma of urinary bladder diagnosed in the period from January 1, 1998 to December 31, 2003 were retrieved. There were 1398 biopsies with the diagnosis of urinary bladder UC. In 814 cases these were first biopsies of primary urothelial carcinoma and 584 cases were recurrences. According to the 1973 WHO classification<sup>16</sup>, 256 patients were diagnosed with tumor grade 1, 331 patients with grade 2, and 227 patients with grade 3. Tumors were more common in males with a male to female ratio of 3.5:1.

For the purpose of this study, 24 consecutive patients (22 male and two female) with synchronous invasive and

*in situ* urothelial carcinoma in the same biopsy obtained by transurethral resection were analyzed. All relevant patient data including age, sex and tumor grade were analyzed. The age range of these patients was between 57 and 81 (median 71.0 $\pm$ 6.6) years. In all 24 cases tumors were diagnosed in first biopsy. These patients were not previously treated for urothelial carcinoma or other primary tumor.

Specimens were fixed in 10% buffered formalin, embedded in paraffin, cut at 5- $\mu$ m thickness and routinely stained with hematoxylin and eosin. For analysis of stromal components, whole mount thin sections were stained with Mallory trichrome method following the standard protocol. By this procedure discontinuous muscle layer in the lamina propria and muscularis propria smooth muscle cells stained red, and myofibroblasts, fibroblasts and collagen fibers stained green (400X). Analyzed regions were previously selected on low power magnification and marked on slides. Sections were scanned under low magnification and ten randomly selected areas in lamina propria beneath *in situ* carcinoma and invasive carcinoma were analyzed under high magnification (400X). The presence of myofibroblasts, fibroblasts and collagen fibers was graded semiquantitatively and expressed as negative 0 = no green staining, 1 = weak, 2 = moderate, and 3 = strong green staining.

Deparaffinization and immunohistochemical staining was performed following Microwave Streptavidin ImmunoPeroxidase (MSIP) protocol on a DAKO TechMate™ Horizon automated immunostainer. We used primary monoclonal antibodies to vimentin (M 0725),  $\alpha$ -smooth muscle actin ( $\alpha$ -SMA) (M 0851) and desmin (M 0760) (purchased from DAKO, Copenhagen, Denmark). Dilutions for all antibodies were 1:50.

The myofibroblastic immunohistochemical phenotype is characterized by coexpression of vimentin and  $\alpha$ -SMA without expression of desmin. The expression of vimentin without additional smooth muscle markers characterized fibroblast phenotype, and coexpression of  $\alpha$ -SMA and desmin without vimentin expression identified smooth muscle cells<sup>17</sup>. To evaluate the intensity of vimentin,  $\alpha$ -SMA, and desmin expression, the percentage of positive-staining stromal cells was examined in ten HPF (X400) for each antibody in previously marked areas. The staining intensity was graded on a scale of 0-3, and expressed as 0 = 0%; 1 = up to 33%; 2 = more than 33% to 66%; and 3 = more than 66% of positive stromal cells<sup>18</sup>.

Immunohistochemical slides were correlated with H&E stained slides for better identification of positive cells to avoid counting of endothelial and inflammatory cells as fibroblast (vimentin +, actin -, desmin -) phenotype.

The intensity of inflammation was also analyzed. Ten randomly selected areas in lamina propria beneath *in situ* carcinoma and invasive carcinoma were analyzed under high magnification (X400). Results were graded semi-quantitatively and labeled as 0 = no inflammation, 1 = weak, 2 = moderate, and 3 = dense inflammatory reaction.

For Mallory trichrome method, each marker (vimentin,  $\alpha$ -SMA, desmin) and intensity of inflammation, Fisher's exact test was used to compare 0/1 grading to 2/3 grading for invasive and *in situ* UC<sup>18</sup>. The level of statistical significance was set at  $p < 0.05$ .

## Results

Out of 24 invasive urothelial carcinomas, 4 (16.7%) tumors were well differentiated, 8 (33.3%) moderately and 12 (50.0%) poorly differentiated. According to pTNM classification, 18 (75%) tumors were pT1 and 6 (25%) tumors were pT2. At the time of diagnosis all patients were without lymph node or distant metastases. The tumors were reclassified according to WHO 2004 classification as follows: 10 (41.7%) low-grade invasive UC and 14 (58.3%) high-grade invasive UC<sup>19</sup>. Mallory trichrome method showed predominantly weak green staining in invasive and *in situ* UC, while statistical analysis revealed no significant between group-differences in the intensity of staining ( $p > 0.05$ ) (Table 1, Fig. 1 A, B).

The stroma from invasive UC showed a high level of vimentin and  $\alpha$ -SMA expression in most cases, while the expression of desmin was absent in 19 and low in 5 cases (Table 2, Fig. 1 C, E, G). In *in situ* carcinoma, the expression of vimentin and  $\alpha$ -SMA was predominantly low and moderate, whereas positive expression of desmin was observed in only one of the cases analyzed (Table 2, Fig. 1 D, F, H).

There was a statistically significantly increased vimentin and  $\alpha$ -SMA immunostaining in the stroma from invasive carcinoma as compared to *in situ* carcinoma ( $p < 0.05$ ). Desmin expression

Table 1. Mallory staining and inflammatory reaction in 24 synchronous *in situ* and invasive urothelial carcinomas of the bladder

Grade	<i>In situ</i> carcinoma		Invasive carcinoma	
	Inflammation	Mallory	Inflammation	Mallory
0	5	8	4	2
1	12	12	5	12
2	5	1	11	4
3	2	3	4	6

0=negative; 1=weak; 2=moderate; 3=strong

showed no statistically significant between-group differences ( $p > 0.05$ ).

In lamina propria of *in situ* carcinomas inflammation was predominantly weak, while the stroma from most invasive carcinomas showed a moderate amount of inflammatory cells (Table 1).

Inflammatory reaction was statistically stronger in invasive as compared to *in situ* carcinoma ( $p < 0.05$ ).

## Discussion

Results of our pilot study indicate that myofibroblasts and inflammatory host reaction may have an important role in urothelial carcinoma invasion and progression, and could also be useful in the differential diagnosis between *in situ* and invasive pT1 UC of urinary bladder.

An increased number of myofibroblasts in urinary bladder lamina propria could serve as a sign of invasion while dense inflammatory reaction does not exclude invasion because an increased number of immunocytes was observed in invasive carcinomas.

Myofibroblasts are large, mesenchymal, spindle-shaped cells with indented nuclei which appear in tu-

Table 2. Immunohistochemical analysis of 24 synchronous *in situ* and invasive urothelial carcinomas of the bladder

Grade	<i>In situ</i> carcinoma			Invasive carcinoma		
	Vimentin	Actin	Desmin	Vimentin	Actin	Desmin
0	2	3	23	1	0	19
1	5	14	1	0	0	5
2	12	5	0	4	10	0
3	5	2	0	19	14	0

0=0% of positive stromal cells; 1=up to 33% of positive stromal cells; 2=33%-66% of positive stromal cells; 3=more than 66% of positive stromal cells



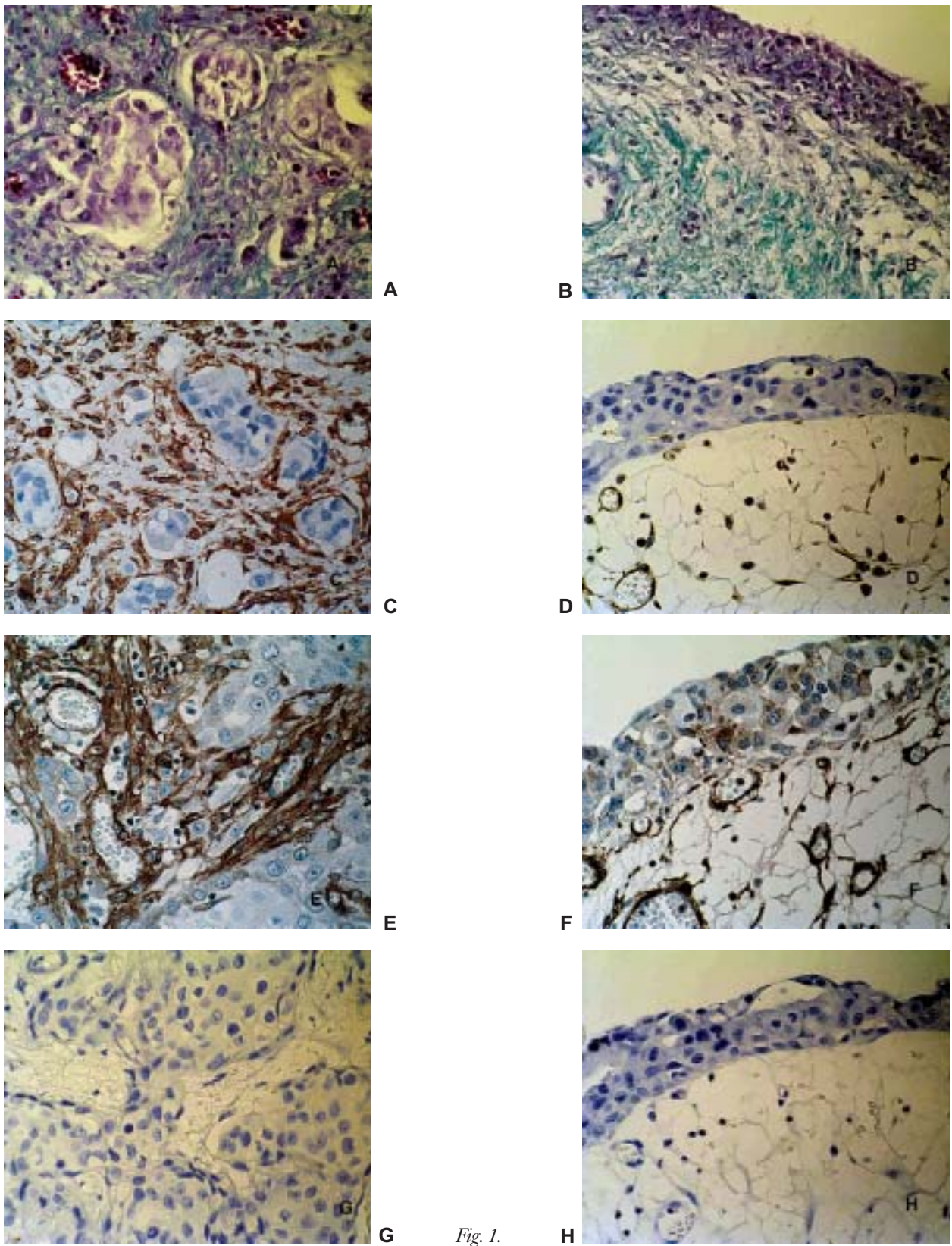


Fig. 1.

mor stroma and granulation tissue during wound healing<sup>19,20</sup>. Wiseman *et al.* have described a layer of cells with the ultrastructural characteristics of myofibroblasts within the human bladder lamina propria<sup>21</sup>. These cells have both an efferent and an afferent nerve supply, and possibly are functioning as a bladder stretch receptor or have similar function as interstitial cells of Cajal in the gut<sup>21</sup>.

Myofibroblasts have been shown to play a very important role in stromal reaction to invasion in different types of malignant epithelial tumors<sup>1-7</sup>. Our pilot investigation suggests that stromal changes occur during UC invasion<sup>22</sup>. The present study showed an increased number of cells with immunohistochemical phenotype characteristics of myofibroblasts in stroma of invasive cancers. Vimentin and  $\alpha$ -SMA expression was increased in invasive as compared to *in situ* carcinomas, whereas desmin showed no significant difference. Myofibroblastic cells observed in lamina propria in specimens with *in situ* carcinoma probably represented myofibroblasts, which normally exist in urinary bladder lamina propria<sup>21</sup>. Both studies analyzed synchronous *in situ* and invasive urothelial carcinoma in the same biopsy in order to minimize the possible influence of other factors such as previous surgical procedure or treatment.

The appearance and increased number of myofibroblasts precedes the invasive stage of cancer and probably leads to switching from noninvasive towards the invasive cancer phenotype<sup>10</sup>. Myofibroblasts are a common stromal element in the colon from patients that have developed familial adenomatous polyposis and large villous adenomas, which both frequently transform towards invasive carcinoma. In contrast, myofibroblasts are rare in tubular adenomas of the colon, which carry a minor risk of progression<sup>2</sup>.

In our study, inflammation was statistically stronger in invasive cancer stroma as compared to lamina propria adjacent to *in situ* carcinoma. These results were expect-

ed, because preserved basement membrane in *in situ* carcinoma prevents closer interaction between malignant epithelial cells and host, as well as stronger host reaction to malignantly transformed cells.

*In vitro* experiments indicate that the contractive properties and probably also the surrounding ECM of cancer-associated myofibroblasts prevent invasion of immune and inflammatory cells into tumors<sup>23</sup>. In this way cancer associated myofibroblasts block direct contact between cancer cells and immunocytes and prevent destruction of cancer cells by the host immune system<sup>10</sup>. On the other hand, tumor-infiltrating leukocytes are also capable to promote cancer progression because they produce proteinases, which are providing roads for cancer cell invasion<sup>24</sup>.

One of the major barriers to tumor cell extravasation and invasion is the basement membrane extracellular matrix<sup>25</sup>. Proteases specific for basement membrane are important in invasion since inhibitors of these proteases block metastases in experimental models<sup>26</sup>. The basement membrane degradation during tumor invasion into tissues and during new blood vessel formation is likely to release active molecules and active fragments of matrix components, which promote tumor cell growth, spread, and angiogenesis<sup>27</sup>.

We conclude that the immunohistochemical expression of myofibroblastic markers was significantly stronger in invasive urothelial carcinoma of urinary bladder, which may aid in the diagnosis of lamina propria invasion, whereas Mallory trichrome method showed no sensitivity in distinction between the two groups analyzed and could not be recommended for use in diagnostic purpose. However, it is obvious that a larger study to confirm our observation is needed.

#### Acknowledgment.

This work was supported by grant 0108001/02 (B.K.) from Ministry of Science and Technology, Republic of Croatia.

#### References

1. MAREEL M, LEROY A. Clinical, cellular, and molecular aspect of carcinoma invasion. *Physiol Rev* 2003;83:337-76.
2. MARTIN M, PUJUGUET P, MARTIN F. Role of stromal myofibroblasts infiltrating colon cancer in tumor invasion. *Pathol Res Pract* 1996;192:712-7.
3. NOELA, FOIDART JM. The role of stroma in breast carcinoma growth *in vivo*. *J Mammary Gland Biol Neoplasia* 1998;3:215-25.

← Fig. 1. Stromal cell phenotype in invasive and *in situ* urothelial carcinomas.

Mallory method showed no difference in the intensity of green staining between invasive (A) and *in situ* (B) urothelial carcinoma. Vimentin (C) and  $\alpha$ -SMA (E) expression was stronger in invasive carcinoma as compared to *in situ* carcinoma (D, F). The expression of desmin showed no significant difference between invasive (G) and *in situ* (H) carcinoma. (All microphotographs were made under high magnification, X400).

4. TOMAS D, KRUSHLIN B. The potential value of (myo)fibroblastic stromal reaction in the diagnosis of prostatic adenocarcinoma. *Prostate* 2004;61:324-31.
5. TÛTTA O, WAHLSTROM T, VIRTANEN I, GOULD VE. Tenascin in inflammatory conditions and neoplasms of the urinary bladder. *Virchows Arch B Cell Pathol Incl Mol Pathol* 1993;63:283-7.
6. TUXHORN JA, AYALA GE, ROWLEY DR. Reactive stroma in prostate cancer progression. *J Urol* 2001;166:2472-83.
7. ZIDAR N, GALE N, KAMBIĆ V, FISCHINGER J. Proliferation of myofibroblasts in the stroma of epithelial hyperplastic lesions and squamous carcinoma of the larynx. *Oncology* 2002;62:381-5.
8. ORIMO A, TOMIOKA Y, SHIMIZU Y, SATO M, OIGAWA S, KAMATO K *et al.* Cancer-associated myofibroblasts possess various factors to promote endometrial tumor progression. *Clin Cancer Res* 2001;7:3097-105.
9. Van Der LOOP FTL, SCHAART G, TIMMER EDJ, RAMAEKERS FCS, van EYS GJJM. Smoothelin, a novel cytoskeletal protein specific for smooth muscle cells. *J Cell Biol* 1996;134:401-11.
10. De WEVER O, MAREEL M. Role of tissue stroma in cancer cell invasion. *J Pathol* 2003;200:429-47.
11. ORLANDINI M, OLIVEIRO S. In fibroblasts *Vegf-D* expression is induced by cell-cell contact mediated by cadherin-11. *J Biol Chem* 2001;276:6576-81.
12. BOSTWICK DG, LOPEZ-BELTRAN A, editors. Bladder biopsy interpretation. New York: United Pathologists, 1999.
13. BOSTWICK DG, MIKUZ G. Urothelial papillary (exophytic) neoplasms. *Virchows Arch* 2002;441:109-16.
14. EPSTEIN JI, AMIN MB, REUTER V, MOSTOFI FK. The Bladder Consensus Conference Committee WHO/ISUP consensus classification of urothelial (transitional cell) lesion of the urinary bladder. *Am J Surg Pathol* 1998;22:1435-48.
15. AMIN MB, GOMEZ JA, YOUNG RH. Urothelial transitional cell carcinoma with endophytic growth patterns: a discussion of patterns of invasion and problems associated with assessment of invasion in 18 cases. *Am J Surg Pathol* 1997;21:1057-68.
16. MOSTOFI FK, SOBIN LH, TORLONI H, editors. Histological typing of urinary bladder tumours. International Classification of Tumours 19. Geneva: WHO, 1973.
17. SAPPINO AP, SCHURCH W, GABBIANI G. Differentiation repertoire of fibroblastic cells: expression of cytoskeletal proteins as marker of phenotypic modulations. *Lab Invest* 1990;63:144-61.
18. TUXHORN JA, AYALA GE, SMITH MJ, SMITH VC, DANG TD, ROWLEY DR. Reactive stroma in human prostate cancer: induction of myofibroblast phenotype and extracellular matrix remodeling. *Clin Cancer Res* 2002;8:2912-23.
19. EBLE JN, SAUTER G, EPSTEIN JI, SESTERHENN IA, editors. Pathology and genetics of tumors of the urinary system and male genital organs. Lyon: WHO, 2004.
20. DVORAK HF. Tumors: wounds that do not heal. *N Engl J Med* 1986;115:1650-9.
21. WISEMAN OJ, FOWLER CJ, LANDON DN. The role of the human bladder lamina propria myofibroblast. *B J U Int* 2003;91:89-93.
22. ZARUBICA J, GABELIĆ T, BULIMBAŠIĆ S, TURČIĆ M, TRNSKI D, KRUSHLIN B. Myofibroblasts in invasive and *in situ* urothelial carcinoma of the bladder. 14<sup>th</sup> Ljudevit Jurak International Symposium on Comparative Pathology, Zagreb, 2003: 47. (Abstract)
23. LIEUBEAU B, HEYMANN MF, HENRY F, BARBIEUX I, MEFLAH K, GRÉGORIE M. Immunomodulatory effects of tumor-associated fibroblasts in colorectal-tumor development. *Int J Cancer* 1999;81:629-36.
24. OPDENAKKER G, Van DAMME J. Chemotactic factors, passive invasion and metastasis cancer cells. *Immunol Today* 1992;13:463-4.
25. KLEINMAN HK, KOBLINSKI J, LEE S, ENGBRING J. Role of basement membrane in tumor growth and metastasis. *Surg Oncol Clin N Am* 2001;10:329-38.
26. MATRISIAN LM. Cancer biology: extracellular proteases in malignancy. *Curr Biol* 2001;9:776-8.
27. TIMPL R. Macromolecular organization of basement membranes. *Curr Opin Cell Biol* 1996;8:618-24.

## Sažetak

STROMALNA REAKCIJA U SINKRONOM *IN SITU* I INVAZIVNOM UROTELNOM KARCINOMU MOKRAČNOG MJEHURA

A. Reljić, D. Tomas, T. Gabelić, J. Zarubica, S. Bulimbašić, H. Fazlić, H. Čupić i B. Krušlin

Cilj istraživanja bio je analizirati stromalnu reakciju, uključujući upalu i dezmozplaziju strome, u *in situ* i invazivnim urotelnim karcinomima mokraćnog mjehura te odrediti moguću vrijednost reaktivnih stromalnih promjena u dijagnostici invazije lamine proprije. Analiza je provedena na 24 uzorka tumora s istodobnom *in situ* i invazivnom sastavnicom urotelnog karcinoma u istoj biopsiji. Uzorci su dobiveni transuretralnom resekcijom, fiksirani i bojeni standardnom metodom hemalaun-eozinom te metodom po Malloryju. Imunohistokemija je učinjena pomoću monoklonskih protutijela protiv vimentina, glatkomišićnog aktina i dezmina. Intenzitet imunohistokemijskih reakcija je određen semikvantitativno i označen kao 0 = negativna reakcija, 1 = do 33% pozitivnih stanica u stromi, 2 = više od 33% do 66% pozitivnih stromalnih stanica i 3 = više od 66% pozitivnih stromalnih stanica. Intenzitet upale označen je kao 0 = nema upale, 1 = slaba upalna reakcija, 2 = umjerena upalna reakcija i 3 = jaka upalna reakcija. Metoda po Malloryju je pokazala negativnu odnosno slabu reakciju zelenog bojenja u 14/24 invazivna i 20/24 *in situ* urotelna karcinoma ( $p > 0,05$ ). Utvrđena je statistički značajno jača reakcija na vimentin i glatkomišićni aktin u stromi invazivnih karcinoma u odnosu na karcinom *in situ* ( $p < 0,05$ ). Upalna reakcija je bila statistički značajno jača u invazivnim karcinomima ( $p < 0,05$ ). Imunohistokemijska izraženost miofibroblastičnih biljega bila je statistički značajno jača u invazivnim urotelnim karcinomima. Ovakvi rezultati mogu pomoći u dijagnozi invazije lamine proprije u invazivnom karcinomu mokraćnog mjehura.

Ključne riječi: *Neoplazme mokraćnog mjehura – patologija; Neoplazme mokraćnog mjehura – dijagnostika; Urotel – patologija; Urološke neoplazme – klasifikacija; Stromalne stanice – patologija*