

CEREBRAL VASOMOTOR REACTIVITY AND CAROTID OCCLUSIVE DISEASE

Natan M. Bornstein and Alexander Y. Gur

Stroke Unit, Department of Neurology, Tel Aviv Sourasky Medical Center, Sackler Faculty of Medicine, Tel Aviv University, Tel Aviv, Israel

SUMMARY – Cerebral autoregulation is a mechanism that enables relatively constant cerebral blood flow during variations of cerebral perfusion pressure. The differences between cerebral blood flow at rest and after administration of a potent vasodilatory stimulus test such as hypercapnia reflect cerebral vasomotor reactivity defined as the vasodilation capacity of cerebral arterioles to external stimuli, providing important information about the cerebral hemodynamic status. Cerebral vasomotor reactivity provides important information about the cerebral hemodynamic status. In this article, cerebral vasomotor reactivity assessment tests are presented, with emphasis on transcranial Doppler, as well as the use of transcranial Doppler in assessing cerebral vasomotor reactivity in carotid stenosis, occlusion, and the importance of cerebral vasomotor reactivity for carotid surgery.

Key words: *Cerebrovascular circulation – ultrasonography; Vasomotor system – physiopathology; Carotid artery diseases – physiopathology; Arterial occlusive diseases – diagnosis*

Introduction

The cerebral vasculature has a unique ability to dilate during hypercapnia and to constrict during hypocapnia. These effects of carbon dioxide (CO₂) on the cerebral circulation are mostly demonstrated in resistance brain arterioles and play an important role in cerebral autoregulation that enables relatively constant cerebral blood flow (CBF) during variations of cerebral perfusion pressure. Thus, the differences between CBF at rest and after the induction of hypercapnia reflect the state of cerebral vasomotor reactivity (VMR) and hence cerebrovascular reserve capacity. VMR is defined as the vasodilation capacity of cerebral arterioles to external stimuli, such as increasing extracellular pCO₂ and decreasing extracellular pH. Indeed, VMR can be considered a shift between CBF and cerebral blood flow velocity (BFV) before and after the administration of a potent

vasodilatory stimulus test. As an indirect parameter of cerebral autoregulation and collateral circulation, VMR provides important information about the cerebral hemodynamic status. VMR can be assessed by measuring regional CBF using single photon emission computer tomography (SPECT) or positron emission tomography (PET), and by measuring BFV using transcranial Doppler ultrasonography (TCD).

Vasomotor Reactivity Assessment Tests

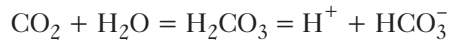
At least four vasodilatory tests are currently used for VMR assessment: the breath-holding or apnea test, CO₂ inhalation, Diamox (acetazolamide) test, and L-arginine test. The breath-holding maneuver enables assessment of VMR by means of calculating the breath-holding index (BHI)¹. The apnea test can be replaced by inhalation of 5% CO₂.

During the measurement of CO₂ reactivity, hypercapnia is induced by inhaling a mixture of 2%-5% CO₂ in 95%-98% oxygen. Measurement of CBF can be performed after stabilization of the end-tidal CO₂ concentration (as determined by a capnograph)^{2,3}. Diamox

Correspondence to: *Natan M. Bornstein, MD*, Chairmen, Department of Neurology, Tel Aviv Sourasky Medical Center, 6 Weizmann Street, Tel Aviv 64239, Israel
E-mail: strokeun@tasmc.health.gov.il

Received September 15, 2006, accepted November 30, 2006

(acetazolamide), a potent, reversible inhibitor of carbonic anhydrase, is widely used as a vasodilatory stimulus for evaluating VMR. The enzyme catalyzes the following reaction:



Although the exact mechanisms by which Diamox acts as a vasodilatory agent and increases the CBF remain controversial, it is most probable that these effects are stimulated by metabolic acidosis and by the direct effect of intravenous administration of 1000 mg acetazolamide on cerebral vessels. Dahl *et al.*⁴ noted that a dose of at least 15 mg/kg body weight (corresponding to 1200 mg in a patient weighing 80 kg) was needed to obtain the maximal vasodilatory effect. In 1999, Micieli *et al.*⁵ used L-arginine as a vasodilatory agent for pre- and postoperative evaluation of VMR in patients with severe carotid stenosis undergoing carotid endarterectomy (CEA). L-arginine induces vasodilation of resistance vessels, a process which is mediated by nitric oxide (NO) at the endothelial level. Intravenous infusion of L-arginine at a dose of 500 mg/kg/30 min significantly increases BFV as measured by TCD. Vasodilatory response can be calculated as:

BFV(CBF) after – BFV(CBF) before/BFV(CBF) before X 100 = VMR%, where

BFV(CBF) after = BFV(CBF) after the administration of a vasodilatory agent, and

BFV(CBF) before = BFV(CBF) before the administration of a vasodilatory agent.

Although BFV does not reflect CBF quantitatively, a direct proportion between these two values has been established, assuming that the diameter of the artery remains unchanged⁶. This is due to the fact that volume flow (**Q**) in a vessel is related to BFV (**V**) according to the equation $\mathbf{Q} = \mathbf{V}\pi\mathbf{R}^2$, where **R** is the vessel radius. Thus, BFV measurements can theoretically provide information regarding changes in volume flow in a supply artery and its perfusion territory if both the diameter of the artery and the size of the perfusion territory remain constant after a vasodilatory stimulus^{7,8}. Several studies were performed to compare the relationship between CBF alterations after vasodilatory tests measured by SPECT, PET and changes in BFV after the same stimulus using the TCD technique⁸⁻¹¹. A good correlation between the methods was found, and this

opened a new era of cerebral hemodynamic investigations without requiring invasive and expensive procedures, such as SPECT or PET. The disadvantages of TCD-based methods are that they lack the regional specificity of other methods of CBF measurement, and are not possible in individuals who have no acoustic window.

Comparative investigations have also shown a good correlation when comparing CO₂ inhalation and acetazolamide test results, indicating a strong similarity between the vasodilatory effects of CO₂ and acetazolamide on cerebral arteries^{3,8}.

The advantages and disadvantages of the two tests are as follows: CO₂ is a more physiologic stimulus and allows CBF measurements using different concentrations. On the other hand, CO₂ inhalation methods require patient cooperation during the investigation (“respiratory work”).

CO₂ inhalation is not performed in patients suffering from obstructive respiratory diseases. CO₂ inhalation may cause gasping and fear of death. As for acetazolamide, intravenous administration of 1000 mg achieves a supramaximal dilative effect on resistance arteries, and permits investigation of the time course of the vasodilatory response. Moreover, a 20-min vasodilatory effect of acetazolamide is ideal for hemodynamic studies, and no patient cooperation is required during the investigation. Some contraindications for acetazolamide administration are sulfonamide allergy, raised intracranial pressure, and severe hepatic or renal failure. The side effects of acetazolamide are mild (paresthesias of the extremities and of the face especially around the mouth and tongue, lightheadedness, and a short lasting, mild diuretic effect), transient and well tolerated by the majority of patients¹².

VMR can be rated as being either good or impaired. An approximately 40% increase in BFV in the cerebral arteries and 20%-30% increase in CBF after the administration of acetazolamide is indicative of good VMR, based on studies in healthy subjects¹³. Ringelstein¹⁴ found an average of 50% increase in BFV in normal volunteers after CO₂ inhalation. Markus and Cullinane¹⁵ used a predetermined cut-off value of 20% for 8% CO₂ VMR. Silvestrini *et al.*¹⁶ suggested a cut-off of 0.69 for the BHI for distinguishing between an impaired and a normal VMR. Although these thresholds have not been validated and only approximately demonstrate the exact state of VMR, this demarcation appears to adequately describe the extent of impairment.

Vasomotor Reactivity and Carotid Stenosis

The majority of the published VMR studies were performed in patients with carotid occlusive disease. Carotid bifurcation is an important site of the developing atherosclerotic lesion, and the landmark clinical trials, the North American Symptomatic Carotid Endarterectomy Trial (NASCET, 1991), European Carotid Surgery Trial (1991), and Asymptomatic Carotid Atherosclerosis Study (ACAS, 1995), have conclusively demonstrated the etiologic importance of carotid atherosclerosis in ischemic stroke¹⁷⁻¹⁹. In the Harvard Stroke Registry, 24% of ischemic strokes were due to carotid artery disease²⁰. Ischemic stroke is assumed to be caused by several mechanisms, either embolic or hemodynamic. This is especially applicable in patients with severe carotid stenosis, for whom both mechanisms should be considered as being potential etiologies for focal cerebral ischemia^{21,22}. Although the majority of cerebral ischemic events are thromboembolic, hemodynamic factors may play a significant role, and recognition of a hemodynamic high-risk subgroup has important implications for evaluation and management²³. Impairment of brain hemisphere perfusion begins with an approximately 60% diameter stenosis of the carotid artery²⁴. Thus, in certain situations (e.g., carotid occlusive disease), the presence and the state of intracranial collateral blood supply and cerebral autoregulation are clearly very important, and intracranial hemodynamic features might have prognostic value for the symptomatic or asymptomatic course of carotid occlusive disease and stroke recurrence²⁵. Significantly reduced VMR has been demonstrated in patients with high-grade stenosis or occlusion of the internal carotid artery (ICA)²⁶⁻²⁹. Only Nighoghossian *et al.*³⁰ failed to show any significant difference in post-acetazolamide CBF between the patients with ICA high-grade stenosis and control subjects. Fujioka³¹ suggests that dilatation of the cerebral resistance vessels occurs in an attempt to maintain stable levels of CBF in these two conditions. This can ultimately lead to the abolition or reduction in the extent to which the cerebral resistance vessels can further dilate in response to additional reduction in flow, whereby VMR is reduced. In spite of unilateral or even bilateral ICA stenosis or occlusion, however, some patients maintain a well-preserved VMR, and this may indicate a sufficient collateral capacity of the circle of Willis and satisfactory cerebral autoregulation. Thus, the intracerebral hemodynamic status of patients with carotid stenosis plays a significant role in stroke incidence and outcome.

Several authors have reported a higher stroke risk in patients with an impaired VMR in carotid occlusive disease. Kleiser and Widder² investigated 85 patients with CO₂ inhalation and found a 55% risk for cerebral ischemic events during a follow-up of 38±15 months in the group with an impaired VMR. Powers *et al.*³² found a 29% stroke rate in 1-year follow-up of patients with ICA occlusion revealed by a PET study. Acetazolamide tests assessing VMR provided similar results: 27% of the patients with impaired and 3% with normal VMR suffered from stroke during 18-month follow-up³³. Yonas *et al.*³⁴ found a 36% stroke risk in an impaired VMR group. Their study was conducted only in symptomatic patients and the authors report that a compromised VMR increased their risk of stroke³⁴. There is an important difference between asymptomatic and symptomatic patients in terms of their natural history: therefore, the only conclusion that can be drawn from that study is that VMR can serve as a predictor for stroke recurrence but not about the likelihood of stroke occurrence in asymptomatic patients. Kleiser and Widder² performed their cerebral hemodynamic investigations in a combined group of symptomatic and asymptomatic patients. Although they also found a positive relationship between stroke incidence and diminished or impaired cerebrovascular reserve capacity, these results are not necessarily applicable when asymptomatic patients are considered as an independent group.

We assessed VMR in 44 asymptomatic patients with severe unilateral carotid stenosis and followed them in order to evaluate its role in stroke occurrence³⁵. During the follow-up period, the overall annual rate was 7.9% for all ischemic cerebral events and 2.3% for ipsilateral strokes. No strokes or transient ischemic attacks (TIA) occurred in the group with good VMR, but there were 7 cerebral ischemic events (2 strokes [1 fatal] and 5 TIAs) in the impaired VMR group. There was a statistically significant correlation between cerebral ischemic events and impaired VMR ($p < 0.02$). These findings were confirmed in two subsequent larger prospective, blinded longitudinal studies. In the first, Silvestrini *et al.*¹⁶ investigated 94 asymptomatic patients with ICA stenosis of at least 70%. They used BHI values and found an annual ipsilateral ischemic event risk of 4.1% in patients with normal BHI values and 13.9% in those with impaired BHI values. Markus and Cullinane¹⁵ studied and followed 107 asymptomatic patients with carotid stenosis and occlusion using TCD and 8% CO₂ inhalation for VMR assessment. There were 11 ipsilateral ischemic events during the follow-up (6 strokes and 5 TIAs), and

the authors concluded that impaired VMR of the ipsilateral middle cerebral artery (MCA) predicted ipsilateral stroke and TIA risk. Moreover, impaired VMR remained an independent predictor of ipsilateral stroke or TIA after adjustment for age, sex, hypertension, diabetes, smoking, ipsilateral infarct and degree of contralateral stenosis. Nicolaides³⁶ suggests that a high-risk subgroup of asymptomatic patients could be arbitrarily defined as a group that has an annual rate of at least 4% of ipsilateral ischemic cerebrovascular events. Identification of a high-risk group was the main goal of the Asymptomatic Carotid Stenosis and Risk of Stroke Study (ACSRS), with special attention paid to parameters such as plaque morphology, vascular risk factors, silent brain infarcts, progression of stenosis, and VMR³⁷. The results of the ACSRS have not yet been published, but those of the other above-cited studies strongly support the value of VMR assessment for identifying asymptomatic patients with carotid stenosis who belong to a high-risk subgroup for whom carotid surgery is justified to prevent ischemic cerebrovascular events.

Vasomotor Reactivity and Carotid Surgery

The measurements of VMR parameters before and after vascular or endovascular surgery are valuable for examining the effects of revascularization procedures on cerebral hemodynamics in patients with carotid occlusive disease. Recent studies confirmed that a revascularization procedure leads to improved VMR in patients with severe carotid stenosis³⁸⁻⁴². In our study⁴², we assessed and compared the effect of carotid endarterectomy (CEA) on VMR in symptomatic and asymptomatic patients. TCD and the Diamox test were performed before and 3 months after CEA in 42 patients (21 symptomatic and 21 asymptomatic) with severe (70%-99%) carotid stenosis. Our data suggest that CEA improves cerebral hemodynamics solely in asymptomatic patients. Others found contradictory results. For instance, Russel *et al.*³⁸ used SPECT to evaluate VMR in a symptomatic study cohort and showed that impaired VMR may be improved by surgery in patients with severe carotid stenosis. The same results were achieved by Hartl *et al.*⁴⁰, who used TCD and CO₂ inhalation, but they did not differentiate between asymptomatic and symptomatic patients. Barzü *et al.*⁴¹ demonstrated normalized VMR following CEA even in the early postoperative period in both asymptomatic and symptomatic patients. Finally, Soinne *et al.*⁴³ found improved VMR using BHI after CEA only in the symptomatic carotid stenosis patients.

Vasomotor Reactivity and Carotid Artery Total Occlusion

The annual risk of stroke in patients with symptomatic carotid artery total occlusion and impaired VMR is reportedly ~10%-14% versus 4%-6% in those with preserved VMR^{44,45}. Occlusion of the ICA is associated with a high mortality rate and frequent disability in survivors. In the past, extracranial to intracranial (EC/IC) arterial anastomosis was performed in this category of patients with carotid occlusive disease. The international randomized EC/IC Bypass Study (1985), however, failed to confirm the benefit of this treatment when compared to appropriate medical care and the EC/IC bypass operation has been largely abandoned worldwide since then⁴⁶. The EC/IC bypass results were recently re-evaluated subsequent to the significant progress of surgical techniques and the availability of more advanced tools to identify patients with carotid occlusion and hemodynamic compromise. Karnik *et al.*⁴⁷ and Neff *et al.*⁴⁸ found that EC/IC bypass surgery improved VMR and total brain blood supply in selected patients with unilateral ICA occlusion and insufficient collateralization. In a review on this issue, Herzig *et al.*⁴⁹ analyzed related data and suggested further studies on the subject of VMR testing in patients with ICA occlusion for possible selection of those who would benefit from EC/IC bypass.

In contrast to the important selective role played by VMR assessment in association with carotid surgery, the attempts to use TCD prior to CEA in order to prevent complications during surgery or to assist preoperative planning (e.g., performing CEA with or without a shunt) were less successful. Lucertini *et al.*⁵⁰ evaluated VMR using TCD and the Diamox test as a preoperative tool in predicting cerebral tolerance to carotid clamping in a consecutive series of 115 CEAs. There was no significant difference between the VMR in the shunted subgroup and the non-shunted one. The positive results of prediction of cerebral ischemia during CEA and the indications for clamping were obtained only in one preoperative TCD and CO₂-reactivity study by Lam *et al.*⁵¹.

Vasomotor Reactivity and Bilateral Carotid Occlusive Disease

The importance of intracranial hemodynamics increases significantly among subjects with bilateral high-grade ICA stenosis. Bilateral severe ICA stenosis accounts for approximately 10% of carotid occlusive disease^{52,53}. This group represents a high-risk population

for ischemic stroke as well as for any perioperative vascular complications after heart, carotid and general surgery^{54,55}. Bilateral severe carotid stenosis can result in persistent low-flow states in the cerebral vasculature due to the loss of cerebral autoregulatory mechanisms in chronically dilated intracerebral vessels^{56,57}. Data on the intracranial hemodynamic features of bilateral severe carotid stenosis are still scanty. Liu *et al.*⁵⁸ investigated VMR using Xenon-CBF measurements and an acetazolamide challenge test in patients with bilateral high-grade ICA stenosis and found no significant differences in the VMR measurements between the territories of bilateral high-grade ICA stenosis. Only four asymptomatic patients with bilateral severe stenosis were studied and a significant increase of CBF after acetazolamide was found in one of them. Another six patients in this study were diagnosed as having unilateral ICA occlusion with high-grade stenosis in the contralateral side. Based on these limited data, the authors did not recommend performing the acetazolamide test to assess VMR.

Vernieri *et al.*⁵⁹ measured cerebral hemodynamics in patients with carotid artery occlusion and contralateral moderate or severe ICA stenosis. VMR in the MCA was evaluated by calculating the BHI. Their data demonstrated the cerebral hemodynamic status of patients with occlusive ICA disease to be influenced by individual anatomical and functional characteristics, with particular attention on collateral pathways. Matteis *et al.*⁶⁰ used TCD and BHI to evaluate VMR patterns in asymptomatic and symptomatic patients with carotid occlusion and severe contralateral stenosis. A significant decrease of VMR on the occluded side was observed in symptomatic patients compared to asymptomatic ones. Moreover, VMR on the stenotic side was significantly higher in the asymptomatic but not in the symptomatic patients. In that study, the patterns of VMR in patients with severe bilateral carotid occlusive disease were strictly dependent on the presence of previous symptoms. Similar results were obtained by Reinhard *et al.*⁶¹ in whose study VMR was assessed as part of the analysis of dynamic cerebral autoregulation and collateral flow patterns in patients with bilateral severe carotid artery stenosis or occlusion.

We evaluated the cerebral hemodynamic features of patients with severe bilateral carotid stenosis by assessing and comparing VMR in the MCA and vertebral arteries by TCD and Diamox test⁶². We found that VMR of the MCA in symptomatic patients with bilateral severe carotid stenosis was significantly lower than in

asymptomatic ones and, in contrast, that VMR of the posterior circulation remained similar in patients with an either symptomatic or asymptomatic course of bilateral carotid stenosis. These data are in accordance with our previous study in which we assessed VMR of the posterior circulation in patients with carotid occlusive disease⁶³. Our findings suggest an independent cerebrovascular reserve capacity of posterior circulation in the presence of carotid occlusive disease, and a key role of the circle of Willis in the intracerebral hemodynamics.

In conclusion, VMR assessment is useful for detecting the altered cerebral hemodynamics in the different categories of carotid occlusive disease and selecting candidates for revascularization procedures. We strongly recommend the implementation of VMR testing in routine clinical practice and believe that this method will be an indispensable tool of vascular neurology in the future.

References

1. SILVESTRINI M, TROISI E, MATTEIS M *et al.* Transcranial Doppler assessment of cerebrovascular reactivity in symptomatic and asymptomatic severe carotid stenosis. *Stroke* 1996; 27:1970-3.
2. KLEISER B, WIDDER B. Course of carotid artery occlusions with impaired cerebrovascular reactivity. *Stroke* 1992;23:171-4.
3. RINGELSTEIN EB, Van-EYCK S, MERTENS I. Evaluation of cerebral vasomotor reactivity by various vasodilating stimuli: comparison of CO₂ to acetazolamide. *J Cereb Blood Flow Metab* 1992;12:162-8.
4. DAHL A, RUSSELL D, ROOTWELT K *et al.* Cerebral vasoreactivity assessed with transcranial Doppler and regional cerebral blood flow measurements: dose, serum concentration, and time of the response to acetazolamide. *Stroke* 1995;26: 2302-6.
5. MICIELI G, BOSONE D, ZAPPOLI F *et al.* Vasomotor response to CO₂ and L-arginine in patients with severe internal carotid artery stenosis; pre- and post-surgical evaluation with transcranial Doppler. *J Neurol Sci* 1999;163:153-8.
6. AASLID R, LINDEGAARD K-F, SORTEBERG W *et al.* Cerebral autoregulation dynamics in humans. *Stroke* 1989;20:45-52.
7. GILLER CA, BOWMAN G, DYER H *et al.* Cerebral arterial diameters during changes in blood pressure and carbon dioxide during craniotomy. *Neurosurgery* 1993;32:737-41.
8. DAHL A, RUSSEL D, NYBERG-HANSEN R *et al.* Cerebral vasoreactivity in unilateral carotid artery disease. A comparison of blood flow velocity and regional cerebral blood flow measurements. *Stroke* 1994;25:621-6.
9. DAHL A, LINDEGAARD K-F, RUSSEL D *et al.* A comparison of transcranial Doppler and cerebral blood flow studies to assess cerebral vasoreactivity. *Stroke* 1992;23:15-9.

10. ROSENKRANZ K, HIERHOLZER J, LANGER R *et al.* Acetazolamide stimulation test in patients with unilateral internal carotid artery obstructions using transcranial Doppler and ^{99m}Tc -HMPAO-SPECT. *Neurol Res* 1992;14:135-8.
11. VORSTRUP S, BRUN B, LASSEN NA. Evaluation by the acetazolamide test before EC-IC bypass surgery in patients with occlusion of the internal carotid artery. *Stroke* 1986;17:1291-8.
12. SETTAKIS G, MOLNAR C, KERENYI L *et al.* Acetazolamide as a vasodilatory stimulus in cerebrovascular diseases and in conditions affecting the cerebral vasculature. *Eur J Neurol* 2003;10:609-20.
13. SORTEBERG W, LINDEGAARD KF, ROOTWELT K *et al.* Effect of acetazolamide on cerebral artery blood velocity and regional cerebral blood flow in normal subjects. *Acta Neurochir Wien* 1989;97:139-45.
14. RINGELSTEIN EB. CO₂-reactivity: dependence from collateral circulation and significance in symptomatic and asymptomatic patients. In: CAPLAN LR, SHIFRIN EG, NICOLAIDES AN, MOORE WS, eds. *Cerebrovascular ischemia. Investigation and management*. Nicosia: Med-Orion Publishing Company, 1996;149-54.
15. MARKUS H, CULLINANE M. Severely impaired cerebrovascular reactivity predicts stroke and TIA risk in patients with carotid artery stenosis and occlusion. *Brain* 2001;124:457-67.
16. SILVESTRINI M, VERNIERI F, PASQUALETTI P *et al.* Impaired cerebral vasoreactivity and risk of stroke in patients with asymptomatic carotid artery stenosis. *JAMA* 2000;283:2122-7.
17. North American Symptomatic Carotid Endarterectomy Trial Collaboration. Beneficial effect of carotid endarterectomy in asymptomatic patients with high-grade carotid stenosis. *N Engl J Med* 1991;325:445-53.
18. European Carotid Surgery Trialists' Collaborative Group. MRC European Carotid Surgery Trial: interim results for symptomatic patients with severe (70-99%) or mild (0-29%) carotid stenosis. *Lancet* 1991;337:1235-43.
19. Asymptomatic Carotid Atherosclerosis Study (ACAS). Executive Committee for the Asymptomatic Carotid Atherosclerosis Study. Endarterectomy for asymptomatic carotid stenosis. *JAMA* 1995;273:1421-8.
20. MOHR JR, CAPLAN LR, MELSKI JW *et al.* The Harvard Cooperative Stroke Registry: a prospective registry. *Neurology* 1978;28:754-62.
21. PIEPGRAS A, SCHMIEDEK P, LEINSINGER G *et al.* A simple test to assess cerebrovascular reserve capacity using transcranial Doppler sonography and acetazolamide. *Stroke* 1990;21:1306-11.
22. CHIMOWITZ MB, FURLAN AJ, JONES SC *et al.* Transcranial Doppler assessment of cerebral perfusion reserve in patients with carotid occlusive disease and no evidence of cerebral infarction. *Neurology* 1993;43:353-7.
23. BLADIN CF, CHAMBERS BR. Frequency and pathogenesis of hemodynamic stroke. *Stroke* 1994;25:2179-82.
24. ARCHIE JP, FELDMAN RW. Critical stenosis of the internal carotid artery. *Surgery* 1981;89:67-72.
25. DERDEYN CP, GRUBB RL, POWERS WJ. Cerebral hemodynamic impairment. Methods of measurement and association with stroke risk. *Neurology* 1999;53:251-9.
26. BISHOP CCR, POWELL S, INSALL M *et al.* Effect of internal carotid artery occlusion on middle cerebral artery blood flow at rest and in response to hypercapnia. *Lancet* 1986;29:710-2.
27. RINGELSTEIN EB, SIEVERS C, ECKER S *et al.* Noninvasive assessment of CO₂-induced cerebral vasomotor response in normal individuals and patients with internal carotid artery occlusions. *Stroke* 1988;19:963-9.
28. NORRIS JM, KRAJEWSKI A, BORNSTEIN NM. The clinical role of the cerebral collateral circulation in carotid occlusion. *J Vasc Surg* 1990;12:113-8.
29. PROVINCIALI L, CERAVOLO MG, MINCIOTTI P. A transcranial Doppler study of vasomotor reactivity in symptomatic carotid occlusion. *Cerebrovas Dis* 1993;3:27-32.
30. NIGHOGHOSSIAN N, TROUILLAS P, PHILIPPON B *et al.* Cerebral blood flow reserve assessment in symptomatic *versus* asymptomatic high-grade internal carotid artery stenosis. *Stroke* 1994;25:1010-3.
31. FUJIOKA KA. Transcranial Doppler sonography in extracranial arterial occlusive disease. Symposium and Tutorials on Cerebral Hemodynamics, 1995:57-60.
32. POWERS WJ, TEMPEL LW, GRUBB RL. Influence of cerebral hemodynamics on stroke risk: one-year follow-up of 30 medically treated patients. *Ann Neurol* 1989;25:325-31.
33. DURHAM SR, SMITH HA, RUTIGLIANO MJ. Assessment of cerebral vasoreactivity and stroke risk using Xe-CT acetazolamide challenge. *Stroke* 1991;22:138.
34. YONAS H, SMITH HA, DURHAM SR *et al.* Increased stroke risk predicted by compromised cerebral blood flow reactivity. *J Neurosurg* 1993;79:483-9.
35. GUR AY, BOVA I, BORNSTEIN NM. Is impaired cerebral vasomotor reactivity a predictive factor of stroke in asymptomatic patients. *Stroke* 1996;27:2188-90.
36. NICOLAIDES AN. Asymptomatic carotid stenosis. The "doctor's dilemma". *Int Angiol* 1995;14:1-4.
37. NICOLAIDES AN. Asymptomatic Carotid Stenosis and the Risk of Stroke (The ACSRS Study): Identification of a high risk group. In: CAPLAN LR, SHIFRIN EG, NICOLAIDES AN, MOORE WS, eds. *Cerebrovascular ischemia. Investigation and management*. Nicosia: Med-Orion Publishing Company, 1996:435-41.
38. RUSSEL D, DYBEVOLD S, KJARTANSSON O *et al.* Cerebral vasoreactivity and blood flow before and 3 months after carotid endarterectomy. *Stroke* 1990;21:1029-32.
39. DEMARIN V, RUNDEK T, DESPOT I *et al.* Importance of the evaluation of cerebral vasoreactive capacity in the indication for carotid endarterectomy. *Angiologia* 1993;45:10-5.
40. HARTL WH, JANSSEN I, FÜRST H. Effect of carotid endarterectomy on patterns of cerebrovascular reactivity in patients with unilateral carotid artery stenosis. *Stroke* 1994;25:1952-7.

41. BARZÜ P, VÖRÖS E, BODOSI M. Use of transcranial Doppler sonography and acetazolamide test to demonstrate changes in cerebrovascular reserve capacity following carotid endarterectomy. *Eur J Vasc Endovasc Surg* 1996;11:83-9.
42. BORNSTEIN N, GUR A, SHIFRIN E, MORAG B. Does carotid endarterectomy modify cerebral vasomotor reactivity? *Cerebrovasc Dis* 1997;7:201-4.
43. SOINNE L, HELENIUS J, TATLISUMAK T *et al.* Cerebral hemodynamics in asymptomatic and symptomatic patients with high-grade carotid stenosis undergoing carotid endarterectomy. *Stroke* 2003;34:1655-61.
44. KLIJN CJ, KAPPELLE LJ, TULLEKEN CA *et al.* Symptomatic carotid artery occlusion. A reappraisal of hemodynamic factors. *Stroke* 1997;28:2084-93.
45. VERNIERI F, PASQUALETTI P, PASSARELI F *et al.* Outcome of carotid artery occlusion is predicted by cerebrovascular reactivity. *Stroke* 1990;30:593-8.
46. The EC-IC Bypass Study Group. Failure of extracranial-intracranial bypass to reduce the risk of ischemic stroke. *N Engl J Med* 1985;313:1191-200.
47. KARNIK R, VALENTIN A, AMMERER H-P *et al.* Elevation of vasomotor reactivity by transcranial Doppler and acetazolamide test before and after extracranial-intracranial bypass in patients with internal carotid artery occlusion. *Stroke* 1992;23:812-7.
48. NEFF KW, HORN P, DINTER D *et al.* Extracranial-intracranial arterial bypass surgery improves total brain blood supply in selected symptomatic patients with unilateral internal carotid artery occlusion and insufficient collateralization. *Neuroradiology* 2004;46:730-7.
49. HERZIG R, HLUSTIK P, URBANEK K *et al.* Can we identify patients with carotid occlusion who would benefit from EC/IC bypass? Review. *Biomed Papers* 2004;148:119-22.
50. LUCERTINI G, CARIATI P, ERMIRIO D *et al.* Can cerebral vasoreactivity predict cerebral tolerance to carotid clamping during carotid endarterectomy? *Cardiovasc Surg* 2002;10:123-7.
51. LAM JM, SMIELEWSKI P, al-RAWI P *et al.* Prediction of cerebral ischaemia during carotid endarterectomy with pre-operative CO₂-reactivity studies and angiography. *Br J Neurosurg* 2000;14:441-8.
52. FRAUNHOFER S, KIOSSIS D, HELMBERGER H, Von SOMMOGGY S, MAURER P. High-degree bilateral carotid stenoses. *Vasa* 1994;23:125-30.
53. ROBLESS P, EMSON M, THOMAS D *et al.* Are we detecting and operating on high risk patients in the asymptomatic carotid surgery trial? The Asymptomatic Carotid Surgery Trial Collaborators. *Eur J Vasc Endovasc Surg* 1998;16:59-64.
54. FRAUNHOFER S, KIOSSIS D, HELMBERGER H, Von SOMMOGGY S, MAURER P. Severe bilateral carotid stenosis. *J Mal Vasc* 1993;18:225-8.
55. EVANS BA, WIJDICKS EF. High-grade carotid stenosis detected before general surgery: is endarterectomy indicated? *Neurology* 2001;57:1328-30.
56. FURST H, HARTL WH, JANSSEN I. Patterns of cerebrovascular reactivity in patients with unilateral asymptomatic carotid artery stenosis. *Stroke* 1994;25:1193-200.
57. WHITE RP, MARKUS HS. Impaired dynamic cerebral autoregulation in carotid artery stenosis. *Stroke* 1997;28:1340-4.
58. LIU H-M, TU Y-K, YIP P-K, SU C-T. Cerebral blood flow and cerebrovascular reactivity capacity in patients with bilateral high-grade stenosis. *Acta Neurol Scand* 1996;166:90-2.
59. VERNIERI F, PASQUALETTI P, DIOMEDI M *et al.* Cerebral hemodynamics in patients with carotid artery occlusion and contralateral moderate or severe internal carotid artery stenosis. *J Neurosurg* 2001;94:559-64.
60. MATTEIS M, VERNIERI F, CALTAGIRONE C *et al.* Patterns of cerebrovascular reactivity in patients with carotid artery occlusion and severe contralateral stenosis. *J Neurol Sci* 1999;168:47-51.
61. REINHARD M, MULLER T, ROTH M *et al.* Bilateral severe carotid artery stenosis or occlusion-cerebral autoregulation dynamics and collateral flow patterns. *Acta Neurochir (Wien)* 2003;145:1053-9.
62. GUR AY, BORNSTEIN NM. Cerebral vasomotor reactivity of bilateral severe carotid stenosis: is stroke unavoidable? *Eur J Neurol* 2006;13(12):183-6.
63. GUR AY, BORNSTEIN NM. Cerebral vasomotor reactivity of the posterior circulation in patients with carotid occlusive disease. *Eur J Neurol* 2003;10:75-8.

Sažetak

MOŽDANA VAZOMOTORNA REAKTIVNOST I OKLUZIVNA BOLEST KAROTIDNIH ARTERIJA

N.M. Bornstein i A.Y. Gur

Moždana autoregulacija je mehanizam koji omogućava relativno ustaljeni moždani protok krvi za vrijeme promjena tlaka prokrvljenosti mozga. Razlike između moždanog protoka krvi u mirovanju i nakon testa snažne vazodilacijske stimulacije poput hiperkapnije odražavaju moždanu vazomotornu reaktivnost definiranu kao vazodilacijski kapacitet moždanih arteriola za vanjske poticaje, pružajući važne podatke o moždanom hemodinamskom statusu. Moždana vazomotorna reaktivnost daje važne informacije o statusu moždane hemodinamike. U članku se prikazuju testovi za procjenu moždane vazomotorne reaktivnosti s naglaskom na transkranijски Doppler, te primjena transkranijskog Dopplera u procjeni moždane vazomotorne reaktivnosti kod karotidne stenoze, okluzije, kao i važnost moždane vazomotorne reaktivnosti za kirurgiju karotidnih arterija.

Ključne riječi: Cerebrovaskularna cirkulacija – ultrazvuk; Vazomotorni sustav – fiziopatologija; Bolesti karotidnih arterija – fiziopatologija; Okluzivne arterijske bolesti – dijagnostika