

Nodular Prurigo Associated with Mycosis Fungoides – Case Report

Sandra Jerković Gulin¹, Romana Čeović², Davorin Lončarić², Ivana Ilić³, Ivo Radman⁴

¹Department of Dermatology and Venereology, Šibenik General Hospital, Šibenik, Croatia; ²Department of Dermatology and Venereology, University Hospital Center Zagreb, University of Zagreb, School of Medicine, Zagreb, Croatia; ³Department of Pathology, University Hospital Center Zagreb, University of Zagreb School of Medicine, Zagreb, Croatia; ⁴Division of Hematology, Department of Internal Medicine, University Hospital Center Zagreb, University of Zagreb School of Medicine, Zagreb, Croatia

Corresponding author:

Assist. Prof. Romana Čeović, MD, PhD
Department of Dermatology and Venereology
University Hospital Center Zagreb
University of Zagreb School of Medicine
Šalata 4
10000 Zagreb
Croatia
romana.ceovic@zg.htnet.hr

Received: February 25, 2015

Accepted: July 5, 2015

ABSTRACT Mycosis fungoides (MF) is the most common type of cutaneous lymphoma and accounts for approximately 50% of all lymphomas arising primarily in the skin. The three types of MF lesions are patches, plaques, and tumors, according to which the disease is traditionally divided into three clinical stages. The clinical course can be protracted and take years or decades. In the final stage, MF evolves to a systemic form of the disease. Nodular prurigo (NP) is still a condition of unknown etiology characterized by papulonodular eruption and intense pruritus. Multiple diseases, including dermatological, systemic, and psychiatric diseases, have been assumed to cause NP. Pruritic skin lesions have been known to precede clinically evident B and T cell lymphomas for years. In the literature, pruritus and NP have been reported in patients affected by systemic Hodgkin and non-Hodgkin lymphomas. Only two cases of cutaneous lymphoma as underlying disease in patients with PN have been reported in the literature. We report a rare case of a patient with concomitant non-Hodgkin skin lymphoma – MF and NP. Our female patient with a 10-year history of MF stage IIb during the last three years had been presenting for regular check-up with itchy, newly formed, rarely disseminated nodules 5-8 mm in diameter on the forearms and lower legs. Sharply limited erythematous, slightly infiltrated foci (as part of MF as the underlying disease) were visible on the trunk and extremities. Extracutaneous involvement of MF was excluded. We performed a biopsy on a nodule from the lower leg to rule out tumor stage MF; the biopsy confirmed NP. We conclude that prurigo nodules should not be confused with tumor stage MF. NP is a therapeutic challenge for any dermatologist. Any underlying diseases should be treated first.

KEY WORDS: mycosis fungoides; nodular prurigo; pruritus

INTRODUCTION

Pruritic skin lesions have long been known to precede clinically evident B and T cell lymphomas. In the literature, pruritus and nodular prurigo (NP) have

been reported in association with systemic Hodgkin lymphoma (HL) and non-Hodgkin lymphomas (NHLs) (1,2). Mycosis fungoides (MF) is the most common

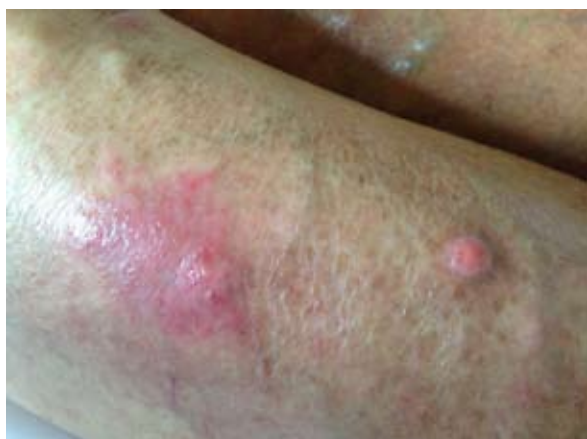

Figure 1. Erythematous, slightly infiltrated lesion as part of mycosis fungoides (MF) as the underlying disease and prurigo nodule, on the lower leg.

type of cutaneous T cell lymphoma (CTCL) and accounts for approximately 50% of all CTCL. Moreover, population-based studies have shown an increasing incidence of MF (3). The cause of MF remains unknown. Typically, MF starts as an indolent disease progressing from a patch stage through confluent plaques to the development of skin tumors. Finally, it evolves to a systemic form of the disease. The average time of transition from stage I to III is around 12 years. One of the hallmarks of MF and Sézary syndrome (SS) is pruritus that rarely responds to treatment. Pruritus affects a large proportion of patients with CTCL and is significantly more severe in late- than in early-stage disease and in SS than in MF (4). Recent study showed that chemokine (C-C motif) ligand 1 (CCL1), chemokine (C-C motif) ligand 26 (CCL26), lactate dehydrogenase (LDH), and immunoglobulin E (IgE) are associated with pruritus in patients with CTCL, while nerve growth factor (NGF) is associated with SS. Increased dermal nerve fibers, probably induced by enhanced NGF expression, may explain the severe pruritus frequently seen in patients with SS (5). If there are isolated tumors that were not preceded by a patch or plaque, other types of T cell lymphomas should be taken into consideration. The recommended diagnostic schemes require histological examination extended by immunohistochemistry for immunophenotyping of neoplastic cells. The therapeutic approach in skin lymphomas is based on histological diagnosis and the disease stage evaluated according to tumor-node-metastasis-blood (TNMB) classification (6).

NP is a chronic inflammatory dermatosis of unknown etiology. It causes a papulonodular eruption that generates an intense itch. The incidence and prevalence of NP are not known. Although the cause

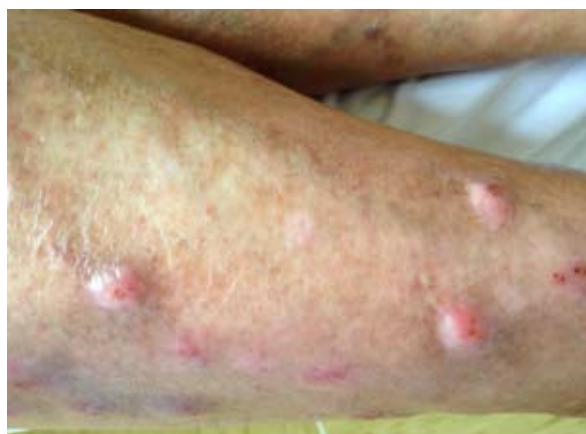

Figure 2. Multiple prurigo nodules on the lower leg.

of NP is unknown, various conditions such as internal malignancies, liver and renal failure, and dermatological and psychiatric illnesses may induce NP. A broad variety of diseases have been reported to underlie NP, including nummular eczema, cutaneous mycobacterial infection in NP nodules, atopic dermatitis, HIV infection, anemia, gastric *Helicobacter pylori* infection, depression, anxiety, lactase deficiency, sorbitol intolerance, etc. (7). Several variants of bullous pemphigoid, including nodular pemphigoid, and linear immunoglobulin A (IgA) disease may mimic or evolve from or into NP (8,9). NP is a challenging condition to treat. Current first-line agents are topical antipruritics, oral antihistamines, and topical, oral, and intralesional glucocorticoids. Second-line agents are narrowband ultraviolet B (UVB) light therapy (NB-UVB), psoralen combined with ultraviolet A (UVA) treatment (PUVA), cryotherapy, topical vitamin D3, capsaicin, and thalidomide (10). Except for case reports and case series, there are no randomized clinical studies on the treatment of NP.

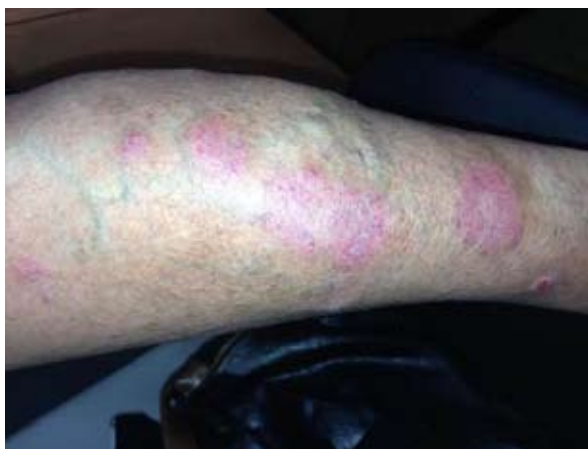

Figure 3. Varicose veins and erythematous, slightly infiltrated lesions as part of mycosis fungoides (MF) as the underlying disease, on the lower leg

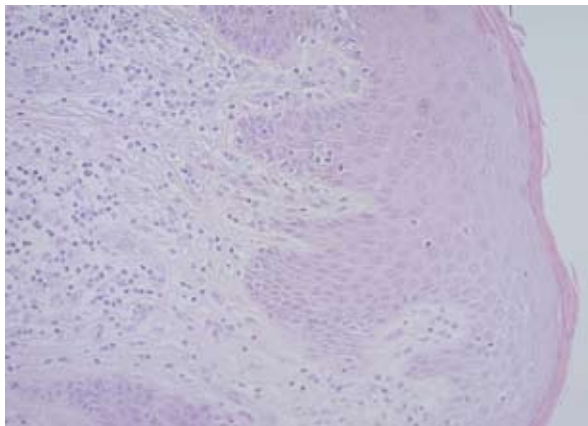


Figure 4. Mycosis fungoides: The epidermis has a psoriasiform appearance with acanthosis and is infiltrated, particularly in the basal layer, by the atypical lymphoid cells. The upper dermis contained mostly lichenoid infiltrate and minimal perivascular infiltrate of atypical lymphocytes (hematoxylin and eosin (HE) $\times 200$).

CASE REPORT

We report a rare case of non-Hodgkin skin lymphoma -- MF associated with NP. A 59-year-old Caucasian woman with a 10-year history of MF stage IIb during the last three years had been presenting for regular check-up with itchy, newly formed, rarely disseminated nodules of 5-8 mm in diameter on the forearms and lower legs (Figure 1, 2). Our patient had also had varicose veins of the lower limbs for many years (Figure 3). This was unusual, since with varicose veins only a single small nodule may be expected. Sharply limited erythematous, slightly infil-

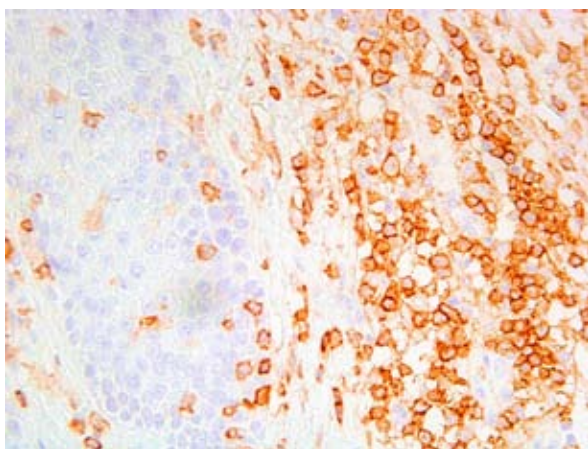


Figure 5. Mycosis fungoides: many dermal lymphocytes are atypical, of larger size and nuclear irregularity, and almost all of them are CD4 positive. There are a few atypical larger CD4+ lymphocytes in the epidermis (immunohistochemistry, CD4 $\times 400$).

trated foci (as part of MF as the underlying disease) were visible on the trunk and extremities (Figure 1, 3, 4, 5). Over the last three years, she had been treated for MF with local and oral corticosteroid therapy and PUVA therapy (once a year). In order to exclude tumor stage MF, a biopsy was obtained from the nodule on the lower leg, and a new diagnosis of NP was established (Figure 6). Standard diagnostic procedures confirmed that there was no extracutaneous involvement of MF. Although the patient was treated for MF with oral corticosteroid and PUVA, which was the therapy of choice for both diseases, along with potent topical glucocorticoid ointment and antihistamines, on a follow-up visit she presented with progression and multiple new prurigo nodules. At the same time, the patient had achieved almost complete regression of lesions of the primary disease, MF. We then started to treat prurigo nodules with intralesional corticosteroids; an almost complete regression of prurigo nodules and clinical improvement in terms of reduced itching were achieved after two applications.

DISCUSSION

Many conditions have been reported to induce NP. The latest retrospective study investigated the distribution of coexisting diseases in a large representative consecutive cohort of 108 patients with NP. In 87% of patients, diseases underlying NP could be established. Monofactorial NP is rare, and the majority of patients in this study were classified in the mixed-origin group with a combination of two or three co-factors (more than one disease was found to be related to induction and maintenance of pruritus). Nearly half of all patients with NP had an atopic predisposition. The majority of co-factors in the NP group of mixed origin were systemic factors, followed by dermatologi-

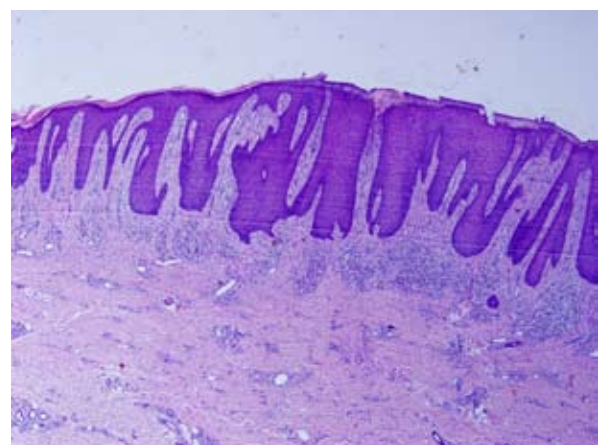


Figure 6. Nodular prurigo: irregular acanthosis, dermal fibrosis, and mononuclear infiltrate in upper dermis (hematoxylin and eosin (HE) $\times 100$)

cal, neurological, and psychological factors. Atopic diathesis, stasis dermatitis, cutaneous lymphoma, allergic contact dermatitis, dermatitis herpetiformis, Grover's disease, and lichen planus were reported as underlying dermatological factors in this NP group of multifactorial etiology (7). The role of these illnesses as precipitants or comorbidities is unclear. They may just be a range of conditions that induce a propensity to skin irritation and unmask a tendency to localized itchiness of the skin. NP can precede clinically evident lymphomas by several years (2).

Systemic NHLs are often accompanied by cutaneous manifestations that, according to the study conducted by Carlesimo *et al.*, can be divided into specific (macules, papules, nodules, plaques, erythema) and non-specific (paraneoplastic pemphigus, generalized eczematous-like eruption, acquired ichthyosis, insect bite-like reactions, pruritus, erythroderma, granuloma annulare, granuloma annulare centrifugum, vascular lesions, prurigo nodularis, palmar hyperkeratosis, urticarial vasculitis, Sweets syndrome, Bazex syndrome). In this study, only two patients affected by systemic NHL had prurigo nodularis as cutaneous manifestation (11). The diversity of the clinical manifestations could be explained by the associated alteration in immune regulation that is typical of patients affected by systemic lymphomas because lymphocytes are the main effectors of our immune response (12). In our patient, NP developed some ten years after establishment of the diagnosis of MF. Although these are common diagnoses, a case of MF associated with NP was, to our knowledge, not reported in the literature to date. NP is a benign condition. However, it can cause severe functional impairment and morbidity due to poor control of the itching/scratching and psychological symptoms. Symptoms of itching and the typical skin lesions are usually enough to establish the diagnosis of NP, but in our patient skin biopsy was performed to exclude MF progression. One of the hallmarks of MF and NP is pruritus that rarely responds to treatment. The itching of NP was very distressing for our patient, much worse than that of MF and severe enough to disturb both sleep at night and daytime activities. In our patient, NP predominantly affected the extensor aspects of the lower limbs. It is known that calcitonin gene-related peptide and substance P immunoreactive nerves are markedly increased in number and activity in the skin of patients with NP, compared with normal skin (13). Whether this represents a causative etiology or arises as a result of chronic scratching and skin irritation is not known. One study found hypoplasia of epidermal sensory nerves in the skin of patients with NP even in areas where pruritus was not a problem (14).

Often, combinations of several medications or physical modalities may be used in an attempt to control this process. Although our patient was treated for MF with oral corticosteroid and PUVA along with potent topical glucocorticoid ointment and antihistamines, there was no improvement in the itchiness caused by NP and in attempts to soften and smooth out the firm nodules. In spite of the therapy our patient presented with progression and multiple new prurigo nodules on the arms and legs, but almost complete regression of MF lesions. We used an intralesional corticosteroid, triamcinolone acetonide, in concentrations of 2.5 mg/mL every 3 weeks and achieved almost complete regression of prurigo nodules and reduced itching after two applications.

CONCLUSION

We conclude that prurigo nodules should not be confused with cutaneous lymphoma or MF progression. Skin biopsy may be performed to rule out malignant process. NP is difficult to manage, posing a challenge for any dermatologist. Any underlying diseases should be treated first.

References

1. Zappasodi P, Forno C, Corso A, Lazzarino M. Mucocutaneous paraneoplastic syndromes in hematologic malignancies. *Int J Dermatol* 2006;45:14-22.
2. Seshadri P, Rajan SJ, George IA, George R. A sinister itch: prurigo nodularis in Hodgkin lymphoma. *Assoc Physicians India* 2009;57:715-6.
3. Saunes M, Nilsen TIL, Johannesen TB. Incidence of primary cutaneous T-cell lymphoma in Norway. *Br J Dermatol* 2009;160:376-9.
4. Vij A, Duvic M. Prevalence and severity of pruritus in cutaneous T cell lymphoma. *Int J Dermatol* 2012;51:930-4.
5. Suga H, Sugaya M, Miyagaki T, Ohmatsu H, Fujita H, Kagami S, *et al.* Association of nerve growth factor, chemokine (C-C motif) ligands and immunoglobulin E with pruritus in cutaneous T-cell lymphoma. *Acta Derm Venereol* 2013;93:144-9.
6. Hwang ST, Janik JE, Jaffe ES, Wilson WH. Mycosis fungoides and Sezary syndrome. *Lancet* 2008;371:945-57.
7. Iking A, Grundmann S, Chatzigeorgakidis E, Phan NQ, Klein D, Ständer S. Prurigo as a symptom of atopic and non-atopic diseases: aetiological survey in a consecutive cohort of 108 patients. *J EADV* 2013;27:550-7.
8. Roenigk RK, Dahl MV. Bullous pemphigoid and pru-

- rigo nodularis. *J Am Acad Dermatol* 1986;14:944-7.
9. Torchia D, Caproni M, Del Bianco E, Cozzani E, Kebabchi S, Fabbri P. Linear IgA disease presenting as prurigo nodularis. *Br J Dermatol* 2006;155:479-80.
 10. Eigelshoven S, Homey B. Prurigo nodularis. *CME Dermatol* 2009;4:140-55.
 11. Carlesimo M, Narcisi A, Rossi A, Saredi I, Orsini D, Pelliccia S, *et al.* Cutaneous manifestations of systemic non-Hodgkin lymphomas (NHL): study and review of the literature. *J EADV* 2014;28:133-41.
 12. Hagler KT, Lynch JW. Paraneoplastic manifestations of lymphoma. *Clin Lymphoma* 2004;5:29-36.
 13. Haas S, Capellino S, Phan NQ, Böhm M, Luger TA, Straub RH, *et al.* Low density of sympathetic nerve fibers relative to substance P-positive nerve. *J Dermatol Sci* 2010;58:193-7.
 14. Schuhknecht B, Marziniak M, Wissel A, Phan NQ, Pappai D, Dangelmaier J, *et al.* Reduced intraepidermal nerve fibre density in lesional and nonlesional prurigo. *Br J Dermatol* 2011;165:85-91.

