

## Advanced Pyoderma Gangrenosum Previously Treated as Squamous Cell Carcinoma

Tamara Čuk Radović<sup>1</sup>, Krešimir Kostović<sup>2</sup>, Jaka Radoš<sup>2</sup>, Zrinjka Paštar<sup>3</sup>, Gordana Pavliša<sup>4</sup>, Branka Marinović<sup>2</sup>

<sup>1</sup>Petar Nola Polyclinic, Zagreb, Croatia; <sup>2</sup>Department of Dermatology and Venereology, University Hospital Center Zagreb, University of Zagreb, School of Medicine, Zagreb, Croatia; <sup>3</sup>Health Department, Ministry of Defense, Zagreb, Croatia; <sup>4</sup>Jordanovac Department for Chest Diseases, University Hospital Center Zagreb, Zagreb, Croatia

### Corresponding author:

Assist. Prof. Krešimir Kostović, MD, PhD  
Department of Dermatology and Venereology  
University Hospital Center Zagreb  
University of Zagreb, School of Medicine  
Šalata 4  
10000 Zagreb  
Croatia  
kreso.kostovic@zg.t-com.hr

Received: February 25, 2015

Accepted: July 5, 2015

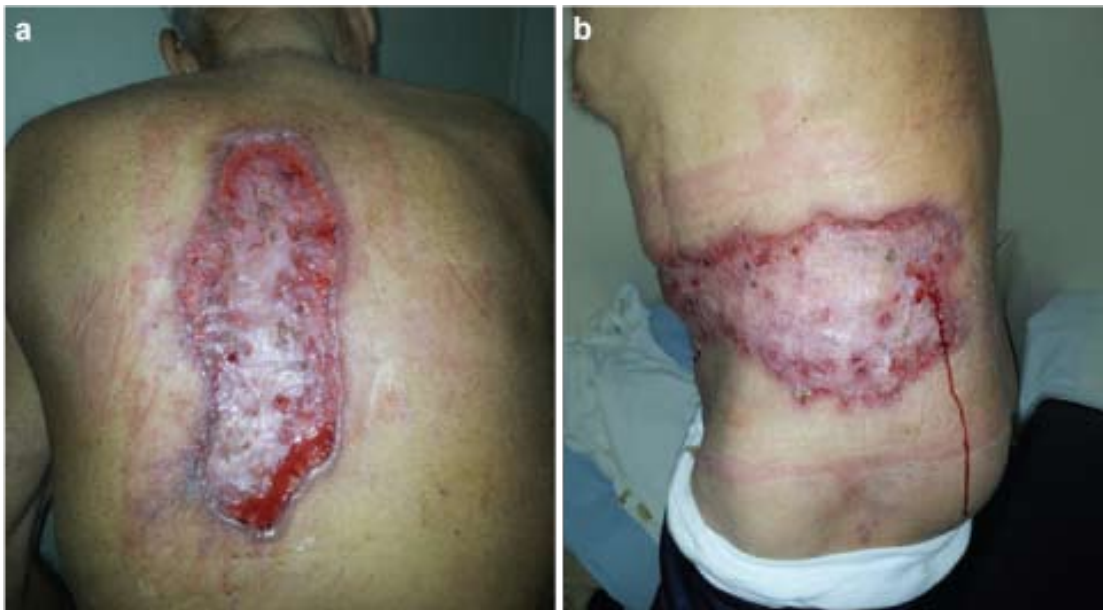**ABSTRACT** Pyoderma gangrenosum is a rare, neutrophilic ulcerative skin disease of unknown etiology often associated with an underlying systemic disease. We present a case of a pyoderma gangrenosum that was initially misdiagnosed and treated as squamous cell carcinoma in another hospital. Multiple surgical treatments triggered post-operative exacerbations and further rapid progression of the lesions. History of pathergy, clinical findings, and histopathological features examined at our Department indicated pyoderma gangrenosum. The diagnosis was confirmed by excluding other diseases that could cause similar-appearing cutaneous lesions. No associated underlying disease was determined. After the diagnosis was confirmed, corticosteroid therapy was initiated until complete remission of ulcerations.

**KEY WORDS:** pyoderma gangrenosum; squamous cell carcinoma; pathergy

### INTRODUCTION

Pyoderma gangrenosum (PG) is an uncommon neutrophilic inflammatory skin disease that presents as rapidly spreading, sterile ulceration on the skin (1,2). The etiology is unknown, and the primary factors considered to contribute to the pathogenesis of PG are neutrophil dysfunction, genetic factors, and dysregulation of the immune system (3,4). It can appear spontaneously or as a result of pathergy after minor trauma or surgery (1). When triggered by pathergy it is easily mistaken for a postoperative infection (3). Clinically and histologically PG is classified into four main types: ulcerative (classic), bullous (atypical), pustular, and vegetative (also known as superficial granulomatous pyoderma) (1,5). The most

common presentation of pyoderma gangrenosum is an inflammatory papule, sterile pustule, or nodule that rapidly progresses to a painful ulcer with a violaceous undermined border and a necrotic, purulent base (1,6). More than 50% of patients with PG develop an associated systemic disease, most commonly inflammatory bowel disease, arthritis, or hematologic disorders (1,3,6,7). Clinical, histopathological and laboratory findings are nonspecific. The diagnosis is made based on the history of an underlying disease, typical clinical presentation, clinical history, and histopathological findings after excluding other ulcerative cutaneous disorders (3). The differential diagnosis includes infectious disease, malignancy, vasculitis,



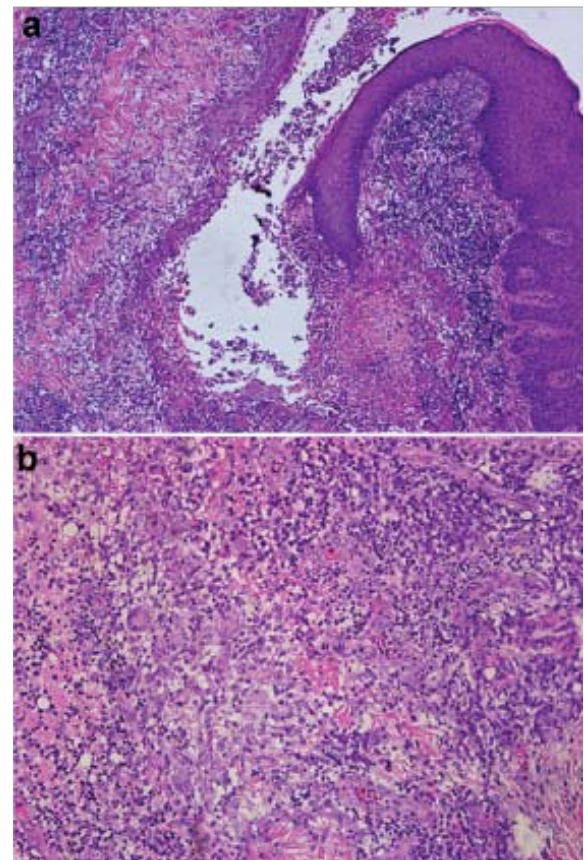
**Figure 1.** Clinical findings in our patient at admission: two extensive, necrotic ulcerations with irregular, violaceous, undermined borders; one presented on the back (a), the other over the lower left abdomen (b).

necrobiosis lipidica, arterial or venous insufficiency, antiphospholipid-antibody syndrome, gangrenous thrombophlebitis, systemic lupus erythematosus, Behçet disease, Wegener's granulomatosis, and polyarteritis nodosa (1,3,8). The first line of treatment includes systemic corticosteroids or immunosuppressive drugs together with treatment of the associated systemic disease (7,9,10).

### CASE REPORT

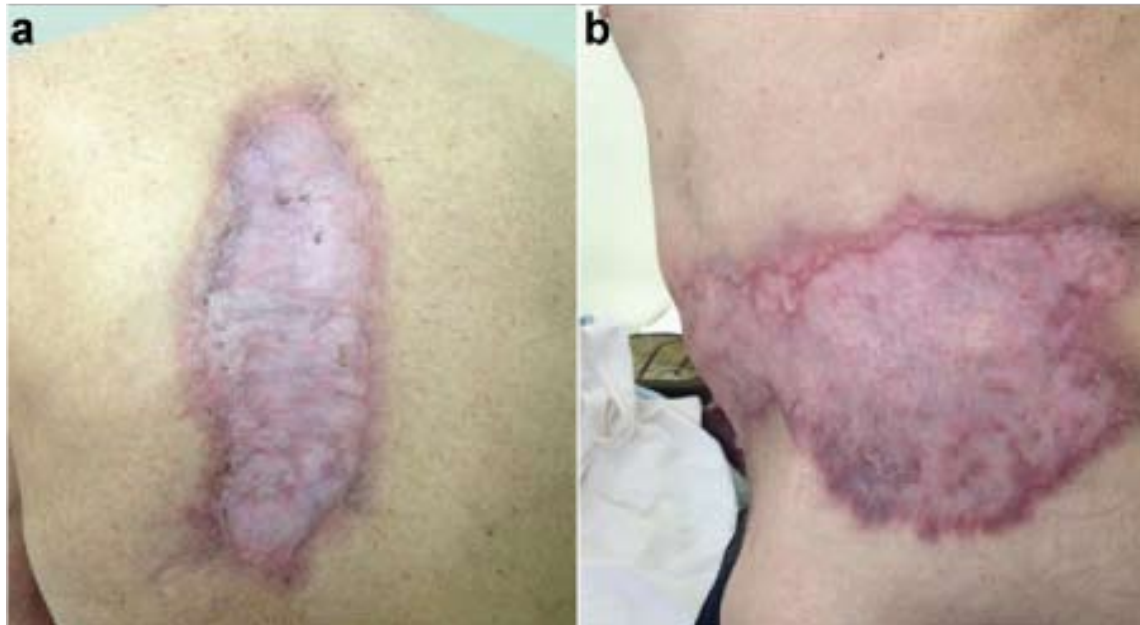
A 76-year-old male patient with a 3-year history of two painful, extensive ulcers on the trunk was referred to our Department for evaluation and treatment of skin lesions. Initially presenting as inflammatory nodules, the lesions were treated as chronic infection. Repeated surgical debridement procedures resulted in a rapid progression of necrotic, sterile ulcerations on the skin which were histopathologically verified as squamous cell carcinomas (SCC) in another hospital. Additionally, wide local excisions were made several times and were followed by rapid development of recurrence at the edges of the scars and further progression of ulcerations.

On admission, clinical examination revealed two extensive, necrotic ulcerations with irregular, violaceous, undermined borders; one on the back (Figure 1, a) and the other one over the lower left abdomen (Figure 1, b). Other than fatigue and pain in the lesions, the patient did not complain of other systemic symptoms such as fever, malaise, arthralgia, or gastrointestinal symptoms.



**Figure 2.** Extensive suppuration around a ruptured follicle with dense infiltrate of neutrophils (hematoxylin and eosin (H&E);  $\times 40$ ) (a). The conspicuous giant cells were noted along with neutrophils on the higher magnification (H&E;  $\times 100$ ) (b).





**Figure 3.** After 12 weeks of corticosteroid therapy: complete re-epithelialization of the lesions with cribriform scarring.

Histopathological examination at our Department showed perifollicular inflammation (Figure 2, a), pseudoepitheliomatous hyperplasia, dermal neutrophilic abscesses, palisading neutrophilic granulomas, and epithelioid granulomas in superficial dermis (Figure 2, b) that indicated pyoderma gangrenosum. Laboratory findings revealed elevation of the erythrocyte sedimentation rate (45 mm/h), elevation of C-reactive protein level (13.1 mg/L), elevated anti-neutrophil cytoplasmic antibodies (c-ANCA) (1:40), and low levels of red blood cell count ( $3.97 \times 10^{12}/L$ ), hemoglobin (114 g/L), hematocrit (0.341 L/L), and serum iron (7  $\mu\text{mol}/L$ ). C3 complement was slightly below normal (0.86 g/L). Microbiological culture was positive for *Staphylococcus aureus*. Therefore, ciprofloxacin 500 mg twice daily was prescribed for two weeks, which resulted in mild improvement. Mycological and mycobacterial cultures of intraoperative samples were negative. Other laboratory tests, including a comprehensive metabolic panel, anti-nuclear antibody titer, total hemolytic complement (CH50), C4 complement, immunofixation, Angiotensin-converting enzyme (ACE) inhibitors, circulating anti-cyclic citrullinated peptid antibodies, electrophoresis of proteins, immunoelectrophoresis, human immunodeficiency virus (HIV) test, venereal disease research laboratory (VDRL) test, Tteponema pallidum hemagglutination (TPHA) test, purified protein derivative (PPD) test, immune cell function test, and tumor markers were within normal ranges. Based on

the above, the diagnosis of pyoderma gangrenosum was made. Additionally, the patient was evaluated for the presence of an associated underlying disease. Multi-slice computer tomography (MSCT) of the neck, chest, abdomen, and pelvis showed normal findings, and colonoscopy did not reveal an underlying inflammatory bowel disease. Interferon-gamma release assay (performed by using QuantiFERON-TB<sup>®</sup>-Gold In tube test) was positive. Further tests, including a chest X-ray, spirometry, and arterial blood gas analysis were normal. Results of three sequential sputum smears and culture testing were negative for acid-fast bacilli and *Mycobacterium tuberculosis*.

After the diagnosis of PG was established with no associated underlying disease, therapy with 70 mg prednisone (1 mg/kg/d) orally was introduced. After 7 days the dose was reduced by 5 mg every seven days to the dose of 5 mg which was continued for the next three months. Complete re-epithelialization of the lesions with cribriform scarring was achieved after 12 weeks of corticosteroid therapy (Figure 3), followed by normalization of red blood cell count and serum iron level.

## DISCUSSION

Pyoderma gangrenosum was first described by Brocq in 1916 as 'phagédénisme géoméétrique' (1,11). Believing that streptococcal infection was the main cause leading to secondary cutaneous gangrene,



it was named pyoderma gangrenosum in 1930 by Brunsting, Goeckerman, and O'Leary (1,12). Today, we know that despite its name it is neither an infectious nor a gangrenous disease and its etiology is still unknown. The diagnosis is made by exclusion of other similar cutaneous lesions.

Since there are no pathognomonic clinical, histological, or laboratory findings, some authors have proposed diagnostic criteria for ulcerative PG (7,13). Two major criteria of which both need to be fulfilled are rapid progression of a painful, necrotic ulceration with an irregular, violaceous, and undermined border along with exclusion of other causes of cutaneous ulcerations. Four minor criteria of which at least two have to be fulfilled are a patient history suggestive of pathergy or clinical presence of cribriform scarring, presence of a systemic disease associated with PG, histopathological findings, and rapid response to systemic corticosteroid treatment.

In our patient, after excluding other dermatoses that might present with similar clinical findings and based on pathohistological elements, rapid progression of extensive ulcerations, typical clinical presentation, and history of pathergy, the diagnosis of pyoderma gangrenosum was established. Positive bacterial culture for *Staphylococcus aureus* was highly suggestive of secondary infection since cultures from early lesions were sterile. Histopathology demonstrated necrosis of the superficial dermis and epidermis with an underlying mixed inflammatory cell infiltrate and abscess formation, which are typical elements in the histopathology of ulcerative PG (14). The primary objective in obtaining a biopsy specimen is to exclude other causes of ulcerations such as infection, malignancy, or vasculitis (1,13). In our case, the exclusion of a malignant disease was the most important aspect of the differential diagnosis. Although the clinical findings were partially suggestive of squamous cell carcinoma, multiple biopsies did not reveal any evidence of malignancy. Pseudoepitheliomatous hyperplasia that was detected could have had imitated squamous cell carcinoma at an early stage in the disease evolution and led to histological misdiagnosis of SCC (15). Being characterized by pathergy, exacerbations and further progression of ulcerations which were triggered by multiple surgeries were mistaken for a relapse of SCC. As with histopathology, there are no pathognomonic laboratory findings that provide definitive diagnosis of PG. Nonspecific findings such as leukocytosis, elevation of the erythrocyte sedimentation rate, and elevation of C-reactive protein levels may be present (16). Laboratory tests are most useful for excluding the differential diagnosis

and identifying the presence of the diseases associated with PG. In our case, high erythrocyte sedimentation rate and low levels of red blood cell count were a result of an inflammatory response to a chronic disease. Elevation of c-ANCA titer does not necessarily indicate Wegener's granulomatosis. According to Weedon, positive c-ANCA and vascular changes suggestive for lymphocytic or leukocytoclastic vasculitis in histopathology do not exclude the diagnosis of PG as previously thought (14). Vasculitis in PG is a secondary event resulting from the deposition of C3, immunoglobulin M (IgM), and fibrin in blood vessels (3). Pulmonary assessment did not confirm active or latent pulmonary tuberculosis. In our case, the positive QuantiFERON test was a result of immune response to the past infection with *Mycobacterium tuberculosis*. It is important to consider tuberculosis as a possible infectious disease associated with PG, especially when the decision on treatment for pyoderma gangrenosum with immunosuppressive drugs must be made, since tuberculosis can be reactivated after intense immunosuppressive therapy (17).

There is no golden standard for treatment of pyoderma gangrenosum (10). The first line of treatment includes systemic corticosteroids (prednisone 0.5-1 mg/kg/d) or cyclosporine (4-5 mg/kg/d), together with treatment of the associated systemic disease (9,18). The rapid response to prednisone and clinical finding of cribriform scarring confirmed the diagnosis in our patient.

In our case, all the criteria for diagnosing pyoderma gangrenosum were met except for the presence of underlying diseases of which inflammatory bowel disease, arthropathies, and hematologic disease or hematologic malignancy are the most common (7). It is important to identify PG-associated comorbidities since successful treatment of them may lead to improvement or complete remission of pyoderma gangrenosum.

## CONCLUSION

Pyoderma gangrenosum is commonly misdiagnosed and treated surgically, which can lead to development of a rapidly spreading ulceration due to pathergy. In our case, awareness of the possible histological misdiagnosis of SCC at an early stage of the disease could have prevented unnecessary surgical procedures. If there is further progression instead of improvement of the skin lesion after surgical treatments, the diagnosis of pyoderma gangrenosum should be considered, and such patients should be evaluated for the presence of associated systemic diseases.

## References

1. Ruocco E, Sangiuliano S, Gravina AG, Miranda A, Nicoletti G. Pyoderma gangrenosum: an updated review. *J Eur Acad Dermatol Venereol* 2009;23:1008.
2. Wollina U. Pyoderma gangrenosum-a review. *Orphanet J Rare Dis* 2007;2:19.
3. Ahronowitz I, Harp J, Shinkai K. Etiology and management of pyoderma gangrenosum: a comprehensive review. *Am J Clin Dermatol* 2012;13:191.
4. Adachi Y, Kindzelskii AL, Cookingham G, Shaya S, Moore EC, Todd III RF, *et al.* Aberrant neutrophil trafficking and metabolic oscillations in severe pyoderma gangrenosum. *J Invest Dermatol* 1998;111:259.
5. Powell FC, Hackett BC, Wallach D. Pyoderma gangrenosum. In: Goldsmith LA, Katz SI, Gilchrist BA, Paller AS, Leffell DJ, Wolff K, editors. *Fitzpatrick's Dermatology in General Medicine*, 8th edition. New York City: McGraw-Hill Companies, Inc., 2012. Vol 1, pp. 371.
6. Hasselmann DO, Bens G, Tilgen W, Reichrath J. Pyoderma gangrenosum: clinical presentation and outcome in 18 cases and review of the literature. *J Dtsch Dermatol Ges* 2007;5:560-4.
7. Binus AM, Qureshi AA, Li VW, Winterfield LS. Pyoderma gangrenosum: a retrospective review of patient characteristics, comorbidities and therapy in 103 patients. *Br J Dermatol* 2011;165:1244.
8. Weenig RH, Davis MD, Dahl PR, Su WP. Skin ulcers misdiagnosed as pyoderma gangrenosum. *N Engl J Med* 2002;347:1412.
9. Reichrath J, Bens G, Bonowitz A, Tilgen W. Treatment recommendations for pyoderma gangrenosum: an evidence-based review of the literature based on more than 350 patients. *J Am Acad Dermatol* 2005;53:273.
10. Miller J, Yentzer BA, Clark A, Jorizzo JL, Feldman SR. Pyoderma gangrenosum: a review and update on new therapies. *J Am Acad Dermatol* 2010;62:646-54.
11. Brocq L. Nouvelle contribution a l'étude du phagédénisme géométrique. *Ann Dermatol Syphiligr* 1916;6: 1-39.
12. Brunsting AL, Goeckerman WH, O'Leary PA. Pyoderma gangrenosum: clinical and experimental observation in five cases occurring in adults. *Arch Dermatol Syphilol* 1930;22:655-80.
13. Su WP, Davis MD, Weenig RH, Powell FC, Perry HO. Pyoderma gangrenosum: clinicopathologic correlation and proposed diagnostic criteria. *Int J Dermatol* 2004;43:790.
14. Weedon D. The vasculopathic reaction pattern. In: *Weedon's Skin Pathology*, 3rd ed. London: Elsevier Limited, 2010. pp.195.
15. Wolfe CM, Green WH, Cognetta AB Jr, Baniahmad O, Hatfield HK. Atypical pyoderma gangrenosum of the dorsal hand mimicking squamous cell carcinoma. *J Hand Surg* 2012;37A:1835-8.
16. Wong WW, Machado GR, Hill ME. Pyoderma gangrenosum: the great pretender and a challenging diagnosis. *J Cutan Med Surg* 2011;15:322.
17. Haghighi S, Karimi S, Dokouhaki P, Shahidi Rad M. Lymph node tuberculosis associated with pyoderma gangrenosum. *Infect Med* 2005;22:76-8.
18. Callen JP, Jackson JM. Pyoderma gangrenosum: an update. *Rheum Dis Clin North Am* 2007;33:787.