

Movements of Temporomandibular Condyles during Swallowing

Samir Čimić¹, Sonja Kraljević Šimunković¹, Renata Kevilj Gospić², Tomislav Badel¹, Nikša Dulčić¹ and Amir Čatić³

¹ University of Zagreb, School of Dental Medicine, Department of Removable Prosthodontics, Zagreb, Croatia

² Dental Clinic Zagreb, Department of Orthodontics, Zagreb, Croatia

³ University of Zagreb, School of Dental Medicine, Department of Fixed Prosthodontics, Zagreb, Croatia

ABSTRACT

There have been studies that investigated mandibular movements and positioning during swallowing, but the results were inconsistent, and still the exact position of the condyles during swallowing is unknown. The purpose of this investigation was to study the kinematics of the mandible and the condyles, and to determine the actual movement paths and position of mandible and condyles during the process of swallowing. The study was performed on a sample of 44 dental students. Measurements were done with an electronic axiograph. After non-occluding attachment was fixed in the mouth, every subject swallowed for five times from the rest position. The final swallowing position of the left and the right condyles was measured in the sagittal plane. The final swallowing position of the sagittal incisal point was measured in sagittal, frontal and horizontal plane, and data was statistically analyzed. The condyles showed average movement toward posterior (left 0.17 mm, SD 0.28, right 0.16 mm, SD 0.25) and superior (left 0.14 mm, SD 0.20, right 0.14 mm, SD 0.23). Anterior and/or inferior position had 20% of participants. The average sagittal incisal point movement during swallowing was toward anterior (0.30 mm, SD 0.53) and superior (0.81 mm, SD 0.84). The mean mandibular lateral movement was 0.1 mm (SD 0.1). The results of the study suggest that retrusion during swallowing is not the rule, although on average there is a slight tendency of condylar movement toward posterior. Swallowing can be used as auxiliary method for determining vertical dimension of occlusion.

Key words: axiography, condylar movement, deglutition, kinematics of the mandible, temporomandibular joint.

Introduction

Swallowing is an integral part of the masticatory sequence¹. In awake subjects usually occurs at a rate of one per minute² while during sleeping it nearly ceases, which adds up to about 1000 swallows daily³. Most of the studies that investigated deglutition used videofluorography^{4–8} as the golden standard. Although those kind of investigations had practical use in understanding dysphagia and food aspiration as well as understanding deglutition itself (oral, esophageal and pharyngeal stage of swallow), there has not been enough information about exact positions of the mandible, mandibular incisal point and condyles during the process of swallowing.

Swallowing occurs with interposition of the tongue, where tongue-palate contact stabilizes the jaw^{9,10}. That physiologic stabilization could give basis for practical use of swallowing in determination of vertical dimension of occlusion, and sagittal maxilomandibular relationship.

Niswonger¹¹ stated that during swallowing, the mandible travels from the rest position to the centric relation position and back to the rest position again. Relatively little attention has since been given to the mechanisms involved in the movement of the temporomandibular condyles during swallowing. From the literature it cannot be understood if there are standard movement trajectories of condyles during swallowing. Shanahan¹² first in 1955 introduced swallowing movement as method for determining the centric relation position and the vertical dimension of occlusion («physiologic approach»). The main advantages of the swallowing method according to Millet et al¹³ were as follows: (i) it is possible to determine vertical dimension of occlusion and centric relation at the same time, and (ii) intermaxillary position is obtained functionally. After Shanahan¹² some authors also stated that during swallowing occurred position of centric relation^{14,15}, while other authors disagreed with this statement^{16–18}.

Kobayashi et al.¹⁶ found that linear distance between the most retruded tooth contact position during swallowing saliva and intercuspal position was on the average 0.13 mm, measured at sagittal incisal point, which was significantly less than the average linear distance between the intercuspal position and the retruded contact position-1.35 mm. Abdel-Hakim¹⁹ used tracing device with a tracing pin connected to the lower jaw, and with a central bearing plate at the upper jaw, for studying mandibular swallowing positions. Compared to intercuspal position, results of mandibular swallowing position were both in anterior and posterior direction. In Ferrario et al.¹⁷ investigation with a mandibular kinesiograph, antero-posterior displacement of mandibular interincisal point during swallowing coincided with intercuspal position in 30% to 35% of subjects, and in 60% the position nearly coincided. Although providing contradictory results, all mentioned investigations compared the intercuspal position with the occlusal position during swallowing. In contemporary studies^{9,17,20} a consensus seem to be reached that in most cases teeth are not in contact during swallowing²⁰. Therefore, the position of temporomandibular condyles during swallowing and condylar movement distance should be compared with the rest position, independent of the maximal intercuspal or other occlusal positions. Studies suggested that mandibular rest position was reliable and reproducible position if recorded during one session^{21,22}.

Although the literature agrees that the swallowing is an inconsistent method for determining the centric relation position^{13,23}, the question arises if there is retrusion of condyles during swallowing at all, and if so, what are the values. The purpose of this investigation is to determine the actual position of the condyle within the temporomandibular joint during the process of swallowing compared to the rest position.

Material and Methods

Subjects

Forty-four healthy young adults, dental students (21–28 years, 13 males, 31 females, mean 24.8 years), without previous orthodontic treatment nor signs and symptoms of TMD, participated in this study. All participants were in excellent health, with no history of any problems related to deglutition. They also were fully dentate (till second molar) with a stabile intercuspal position. Each subject gave written informed consent, which was approved by the Ethical Committee of the School of Dentistry, University of Zagreb.

Procedure

Recordings were obtained using six degrees of freedom ultrasonic measuring device (Arcus Digma II, Kavo, Biberach, Germany) following the manufacturer's recommendations using kinematic axis as posterior reference point. First, irreversible hydrocolloid impressions (Aroma Fine Plus, GC, Tokyo, Japan), were made for each subject, and

on stone casts non-occluding attachment was made for each subject from light cured acrylic resin (Unitray, Polident, Volcja Draga, Slovenia), following the manufacturer's recommendations. On next appointment electronic axiography recordings were performed. Each subject was seated comfortably in a chair (upright posture). Non-occluding attachment was fixed in the lower jaw using acrylic resin for temporary restoration (Structur, Voco, Cuxhaven, Germany). Non-occluding attachment was not in contact with upper teeth in intercuspal position or eccentric movements, and it was firmly fixed to the lower dental arch. In the Module »Motion Analysis« of the device, recordings were made. Subjects made protrusive and opening movements, and infraorbital point was measured, so the device could calculate kinematic axis. After calibration, each subject were asked to perform five dry swallows from the rest position. As all subjects were students of dentistry, they were familiar with the term of rest position. Still, the term of rest position was explained in detail to them immediately before performing swallowing. Subjects were instructed to swallow from the rest position in their usual manner. After each swallow, subjects raised hand as the sign of completion of the swallow. After recordings were made, all data was transferred to a computer (software program KID-Kavo Integrated Desktop, Kavo, Biberach, Germany), so the position of left and right condyles, and sagittal incisal point could be measured. The final swallowing position was measured for left and right condyles, and the sagittal incisal point, excluding any previous movements of points of interest during swallowing. All recordings and ratings were performed by a single experienced investigator in electronic axiography to eliminate problems with interexaminer reliability.

Condyle positions were measured in the sagittal plane. The positions were vertical position of the left and right condyle, and antero-posterior position of the left and right condyle. The sagittal incisal point was measured in sagittal, frontal and horizontal plane. The positions were sagittal vertical position, sagittal antero-posterior position, frontal vertical position, frontal lateral position, horizontal antero-posterior position and horizontal lateral position.

Average values of five swallows for condyles and sagittal incisal point movements were calculated, and used in this study. Presample size calculation showed that less than 40 participants would satisfy all demands for justified statistics. Male and female samples were compared using Levene's and Student T-test. The interaction of gender, side and gender and side on obtained values was compared using multivariate ANOVA. Descriptive statistics were calculated (SPSS Statistics 17.0), and levels below 0.05 were considered significant.

Results

Figure 1 shows the final swallowing position of left and right condyles in 44 participants. Levene's and Student T-test showed no significant difference ($\alpha=0.05$) between male and female samples, for any point of interest in any plane of

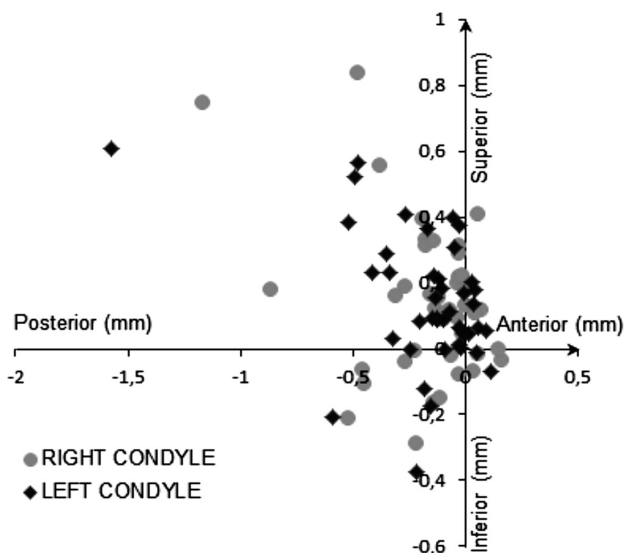


Fig. 1. Distance from the rest position of right and left condyles during swallowing for 44 participants (in mm).

reference. In order to clarify possible effects of side, gender and the interaction between side and gender, multivariate ANOVA was performed (Table 1). The effect of side, gender and side*gender interaction were not significant, therefore male and female samples were considered as one sample. Descriptive statistics (range, mean, SD, Std error, 95% Confidence interval) for the average positions of left and right condyles, and the sagittal incisal point during swallowing is presented in Table 2. For the antero-posterior and vertical movements, negative values represent inferior or posterior movement, respectively. Antero-posterior movement differed between condyles and sagittal incisal point in direction and value. For the condyles average movement was toward posterior (left 0.17 mm, SD 0.28, right 0.16 mm, SD 0.25), and for the sagittal incisal point average movement

TABLE 1
MULTIVARIATE ANOVA FOR THE EFFECT OF GENDER, SIDE, AND GENDER AND SIDE ON THE OBTAINED VALUES ($\alpha=0.05$)

Effect modifiers	Variable	F	Sig.	
Gender	VC	2.18	0.14	
	AC	2.44	0.12	
	VIS	0.60	0.44	
	APIS	3.46	0.07	
	VIF	0.65	0.43	
	LIF	1.67	0.20	
	APIH	3.40	0.07	
	LIH	2.12	0.15	
	Side	VC	0.05	0.83
		AC	0.23	0.63
Gender and side	VC	0.08	0.79	
	AC	0.48	0.49	

* VC – vertical movement of condyles; AC – antero-posterior movement of condyles; VIS – vertical movement of incisal point in sagittal plane; APIS – antero-posterior movement of incisal point in sagittal plane; VIF – vertical movement of incisal point in frontal plane; LIF – lateral movement of incisal point in frontal plane; APIH – antero-posterior movement of incisal point in horizontal plane; LIH – lateral movement of incisal point in horizontal plane

was toward anterior (0.3 mm, SD 0.53) (Figure 2). Condyles and the sagittal incisal point during swallowing procedure on the average showed movement toward superior in the sagittal plane (left condyle 0.14 mm, SD 0.20, right condyle 0.14 mm, SD 0.23, sagittal incisal point 0.81 mm, SD 0.84) (Figures 2 and 3). Levene’s and Student T-test of the sagittal incisal point movement demonstrated no significant differ-

TABLE 2
DESCRIPTIVE STATISTICS FOR THE AVERAGE MOVEMENT OF LEFT AND RIGHT CONDYLES, AND THE SAGITTAL INCISAL POINT FROM THE REST POSITION DURING SWALLOWING

Variable	Range (mm)	Min (mm)	Max (mm)	\bar{X} (mm)	SD	Std. Error	95% confidence interval
Right condyle mean vertical movement	1.13	-0.29	0.84	0.14	0.23	0.03	0.14±0.07
Right condyle mean antero-posterior movement	1.33	-1.17	0.16	-0.16	0.25	0.04	-0.16±0.07
Left condyle mean vertical movement	0.98	-0.37	0.61	0.14	0.20	0.03	0.14±0.06
Left condyle mean antero-posterior movement	1.68	-1.57	0.11	-0.17	0.28	0.04	-0.17±0.08
Incisal point mean vertical movement in sagittal plane	4.17	-0.81	3.36	0.81	0.84	0.13	0.81±0.25
Incisal point mean antero-posterior movement in sagittal plane	2.63	-0.88	1.75	0.30	0.53	0.08	0.30±0.16
Incisal point mean vertical movement in frontal plane	4.21	-0.86	3.36	0.81	0.84	0.13	0.81±0.25
Incisal point mean lateral movement in frontal plane	0.48	0.00	0.48	0.10	0.11	0.02	0.10±0.03
Incisal point mean antero-posterior movement in horizontal plane	2.67	-0.90	1.77	0.32	0.53	0.08	0.32±0.16
Incisal point mean lateral movement in horizontal plane	0.46	0.00	0.46	0.11	0.10	0.01	0.11±0.03

*In the vertical direction minus values mean inferior, and in antero-posterior direction minus values mean posterior

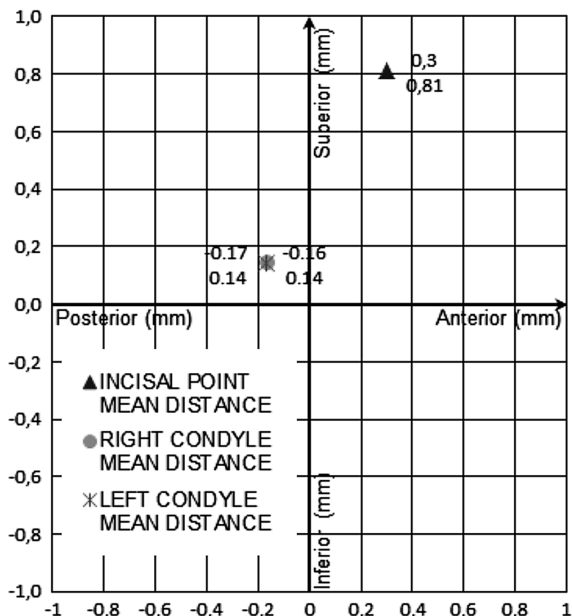


Fig. 2. Mean distance from the rest position during swallowing for right and left condyles and the sagittal incisal point in the sagittal plane (in mm).

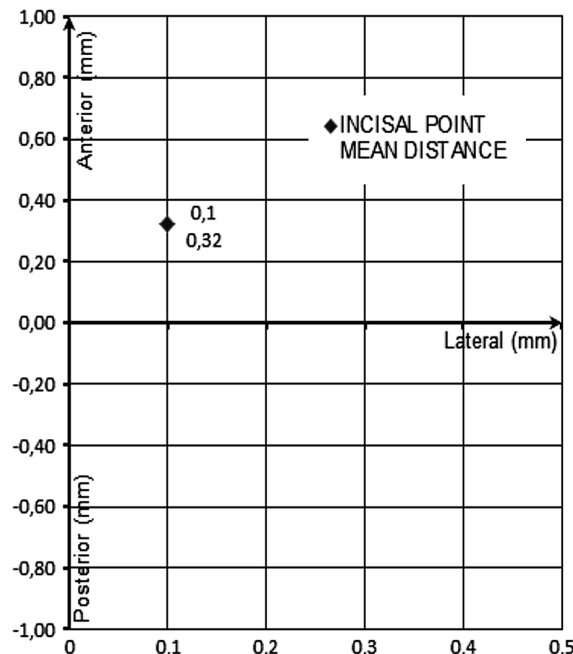


Fig. 4. Mean lateral movement/distance of the sagittal incisal point during swallowing, compared to antero-posterior direction (in mm).

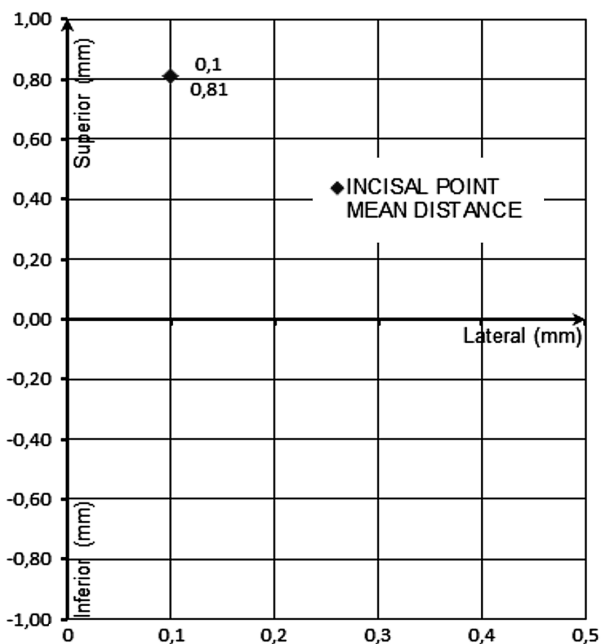


Fig. 3. Mean lateral movement/distance of the sagittal incisal point during swallowing, compared to vertical direction (in mm).

ences sidewise, so left and right movements were treated as one lateral movement. Average lateral movement was 0.1 mm (SD 0.1) (Figures 3 and 4). Direction of movement of condyles and the sagittal incisal point during swallowing is shown in Table 3. Intrasubject standard deviation for repeated measurements of five swallows ranged from 0.0–1.66 mm.

TABLE 3
DIRECTION OF MOVEMENTS OF CONDYLES AND THE SAGITTAL INCISAL POINT (NUMBER OF PARTICIPANTS)

	Superior	Inferior	0.0 mm
Left condyle	36 (81.8%)	6 (13.6%)	2 (4.5%)
Right condyle	32 (72.7%)	11(25.0%)	1 (2.3%)
Sagittal incisal point	37 (84.1%)	7 (15.9%)	0
	Anterior	Posterior	0.0 mm
Left condyle	8 (18.2%)	36 (81.8%)	0
Right condyle	8 (18.2%)	35 (79.5%)	1 (2.3%)
Sagittal incisal point	35 (79.5%)	9 (20.4%)	0

Discussion

In this study were investigated movements of temporomandibular condyles and the sagittal incisal point during swallowing. The results showed that retrusion of condyles during swallowing is not the rule, never the less suggesting a slight tendency of condylar movement toward posterior. The results demonstrated wide variability among participants.

Antero-posterior movement

Kobayashi et al.¹⁶ found that the mean linear distance between the most retruded tooth contact position during swallowing saliva and the intercuspal position was 0.13 mm, measured at the sagittal incisal point. Kydd et

al.²⁴ investigated posterior mandibular movements, where all subjects during swallowing demonstrated posterior movement from their intercuspal occlusal position (the retrusion measured at sagittal incisal point varied from 0.2 to 1.8 mm). Results of both those studies are contradictory to the results of the present study, where average difference in antero-posterior direction between the rest position and the final swallowing position at the sagittal incisal point was 0.3 mm towards anterior. Anterior movement of the sagittal incisal point was determined in 79.5% of participants (Table 3). Different results from Kobayashi¹⁶ and Kydd²⁴ studies could do to different materials and methods, and mostly to different choice of the reference point²⁵, because in those studies the intercuspal position was used as a reference, and not the rest position.

Results of the condylar movement in antero-posterior direction showed different results from the sagittal incisal point movement. Average movement of the right condyle was 0.16 mm (SD 0.25), and of the left 0.17 mm (SD 0.28) toward posterior. Posterior position was determined in 79.5% of the right and 81.8% of the left condyles. Those results suggest that the posterior condylar movement (retrusion) from the rest position during swallowing is not a rule, although on the average there is a slight tendency of condyles toward the posterior.

Studies showed that average maximal intercuspal-retruded contact position slide is around 1.5 mm^{26,27}. The results of our and other studies^{10,16–18} suggest that the use of swallowing as auxiliary method in a clinical procedure of determining centric relation will likely position condyles anteriorly from the centric relation position, rather than setting condyles in optimal antero-superior position. Campos et al.²⁸ proposed clinical use of a modified swallowing technique, which showed in their investigation reproducibility as chin point guidance technique. That modified swallowing technique used jig, patient was instructed to attempt to bring the posterior teeth together, swallow and hold. In upright position modified swallowing technique positioned the condyles 0.28 mm anterior and 0.26 mm superior to the chin point guidance technique. Alvarez et al.²⁹ found similar results. Those results are not supported by the present study, but it should be kept in mind that in Campos²⁸ and Alvarez²⁹ studies a jig was used. Although results of our study suggest a small range of condylar movements both in anterior and posterior directions, it could be possible with the use of a jig to set condyles in optimal antero-superior position (centric relation) as suggested by Campos et al.²⁸. In this way, additional stabilization through contact of the jig and mandibular incisors could be achieved, and correct antero-superior positioning of condyles in temporomandibular fossa.

Vertical movement

In vertical dimension average movement of the sagittal incisal point during swallowing was 0.81 mm (SD 0.84) superior to the rest position. Those results are in accordance with the results of previous studies^{13,30}. The present results also demonstrated significant intersubject (Table 2) and intrasubject variability. In regard to that variabil-

ity the swallowing method cannot be recommended as a main method for determining vertical dimension of occlusion. Most widespread clinical technique for determining vertical dimension uses vertical dimension of rest. Since vertical dimension of rest represents dynamic equilibrium influenced by various endogenous and exogenous factors, and can be changeable³⁰, the swallowing method could be adequate auxiliary method, as proposed by de Sadalla et al.²⁰. Based on our results the vertical intermaxillary distance of occlusion was on the average 1 mm less than the vertical distance determined by the swallowing technique.

The average condylar movement in vertical dimension during swallowing was 0.14 mm (for the left condyle SD 0.20 and for the right condyle SD 0.23) superior to condyle in the rest position. The results were not in accordance with results of movements of the sagittal incisal point. Movements of one point of mandible cannot be applied to the mandible itself.

Lateral movement

Ferrario et al.¹⁷ investigated mandibular movements where 70% of participants showed minimal lateral deviation during swallowing (≤ 0.5 mm). De Sadalla et al.²⁰ found that a 85% of participants had lateral deviations (mean 0.3 mm). Our results (mean lateral movement during swallowing 0.1 mm, SD 0.1) were in accordance with those previous studies^{17,20}. Difference in percentage of participants with lateral movements during swallowing, and its dimension could be explained with different materials and methods used. Minimal lateral deviations during swallowing can be considered as normal, regardless of existence of tooth contacts during swallowing.

Results of the sagittal incisal point and the condylar position demonstrated intrasubject and intersubject variability, both in antero-posterior and in vertical dimensions, which was in accordance with previous studies^{20,31}. Various studies demonstrated that reference positions embrace an area rather than a single point^{10,25,32,33}. Following that assumption the positions of temporomandibular condyles and mandible during swallowing could also represent an area, and not a single point, which was confirmed by results of this study. The position of condyles during swallowing in vertical and antero-posterior direction was grouped within 0.5 mm in more than 80% of participants (Figure 1). That space could represent physiological swallowing area, from 0.1 anterior- 0.4 mm posterior, and from 0.4 mm superior- 0.1 mm inferior to the rest position.

The main limitation of this study is the lack of similar studies to compare results, specially the movements of condyles during the act of swallowing. Based on results of the present study, it can be assumed that different patterns of condylar movements during swallowing exist. Future studies should be focused on research of those different patterns.

Conclusions

On average there is a slight tendency of condylar movement toward posterior during swallowing, although it can-

not be considered as a rule. Minimal mandibular lateral deviations during swallowing can be considered normal. Due to intersubject and intrasubject variability, the swallowing cannot be recommended as the only method for determining vertical dimension of occlusion, but rather as an auxiliary method.

REFERENCES

1. PALMER JB, RUDIN NJ, LARA G, CROMPTON AW, Dysphagia, 7 (1992) 187. DOI: 10.1007/BF02493469. — 2. DENT J, DODDS WJ, FRIEDMAN RH, SEKIGUCHI T, HOGAN WJ, ARNDORFER RC, PETERIE DJ, J Clin Invest, 65 (1980) 256. DOI: 10.1172/JCI109667. — 3. DODS WJ, STEWART ET, LOGEMANN JA, Am J Roentgenol, 154 (1990) 953. DOI: 10.2214/ajr.154.5.2108569. — 4. SAITOH E, SHIBATA S, MATSUO K, BABA M, FUJII W, PALMER JB, Dysphagia, 22 (2007) 100. DOI: 10.1007/s00455-006-9060-5. — 5. PALMER JB, HIEMAE KM, MATSUO K, HAISHIMA H, Physiol Behav, 91 (2007) 91. DOI: 10.1016/j.physbeh.2007.01.018. — 6. FUJIKI T, DEGUCHI T, NAGASAKI T, TANIMOTO K, YAMASHIRO T, TAKANO-YAMAMOTO T, Angle Orthod, 83 (2013) 591. DOI: 10.2319/060412-464.1. — 7. OSAWA A, MAESHIMA S, MATSUDA H, TANAHASHI N, Neuroradiology, 55 (2013) 413. DOI: 10.1007/s00234-012-1117-6. — 8. TICAC R, CANDRLIC B, JURANIC J, PAVELIC G, PEDISIC D, PUSIC M, Coll Antropol, 36 (2012) 125. — 9. WILLIAMSON EH, HALL JT, ZWEMER JD, Am J Orthod Dentofacial Orthop, 98 (1990) 507. — 10. CELAR AG, KUNDIM, PIESHLINGER E, FURHAUSER R, KOHLMAIER B, J Oral Rehabil, 27 (2000) 70. DOI: 10.1046/j.1365-2842.2000.00488.x. — 11. NISWONGER ME, J Am Dent Assoc, 21 (1934) 1572. — 12. SHANAHAN TE, J Prosthet Dent, 91 (2004) 206. — 13. MILLET C, JEANNIN C, VINCENT B, MALQUARTI G, J Oral Rehabil, 30 (2003), 1118. DOI: 10.1046/j.1365-2842.2003.01201.x. — 14. KURTH LE, J Am Dent Assoc, 59 (1959) 669. — 15. FREESE AS, SCHEMAN P, Management of Temporomandibular Joint Problems (Mosby Co, St Louis, 1962). — 16. KOBAYASHI J, TERADA Y, HIRAYASU R, Nihon Hotetsu Shika Gakkai Zasshi, 33 (1989) 1. DOI: 10.2186/jjps.33.1. — 17. FERRARIO VF, SFORZA C, MIANI A, D'ADDONA A, TARTAGLIA G, Int J Prosthodont, 5

Acknowledgements

This work was supported, in part, by Ministry of Science, Education and Sports of the Republic of Croatia (scientific project »Occlusion and temporomandibular dysfunction«, no. 065-0650448-0438).

(1992) 158. — 18. CELAR A, SIEJKA E, SCHATZ J, FURHAUSER R, PIESHLINGER E, Cranio, 14 (1996) 42. — 19. ABDEL-HAKIM AM, J Prosthet Dent, 47 (1982) 12. — 20. DE SADALLA KB, DE SOUZA RF, DE ASIS MOLLO F JR, COMPAGNONI MA, Cranio, 25 (2007) 37. — 21. TINGEY EM, BUSCHANG PH, TROCKMORTON GS, Am J Orthod Dentofacial Orthop, 120 (2001) 614. DOI: 10.1067/mod.2001.119802. — 22. CASTROFLORIO T, ICARDI K, TORSELLO F, DEREGIBUS A, DEBERNARDI C, BRACCO P, Cranio 23 (2005) 130. — 23. KANTOR ME, SILVERMANN SI, GARFINKEL L, J Prosthet Dent, 28 (1972) 593. — 24. KYDD WL, SANDER A, J Dent Res, 40 (1961) 419. DOI: 10.1177/00220345610400030601. — 25. CATIC A, NAEIJE M, J Oral Rehabil, 26 (1999) 661. DOI: 10.1046/j.1365-2842.1999.00441.x. — 26. FOGLIO-BONDA PL, MIGLIARETTI G, CAVALLO F, ROCCHETTI V, BODIN C, Arch Oral Biol, 51 (2006) 581. DOI: 10.1016/j.archoralbio.2006.01.005. — 27. UHAC I, KOVAC Z, VUKOVOJAC S, ZUVIC-BUTORAC M, GRZIC R, DELIC Z, Coll Antropol, 26 (2002) 285. — 28. CAMPOS AA, NATHANSON D, ROSE L, J Prosthet Dent, 76 (1996) 282. — 29. ALVAREZ MC, TURBINO ML, BARROS C, PAGNANO VO, BEZZON OL, Braz Dent J, 20 (2009) 78. DOI: 10.1590/S0103-64402009000100014. — 30. KOLLER MM, MERLINI L, SPANDRE G, PALLA S, J Oral Rehabil, 19 (1992) 413. DOI: 10.1111/j.1365-2842.1992.tb01583.x. — 31. INGERVALL B, BRATT CM, CARLSSON GE, HELKIMO M, LANTZ B, Acta Odontol Scand, 29 (1971) 549. DOI: 10.3109/00016357109026333. — 32. PIESHLINGER E, CELAR A, CELAR R, JAGER W, SLAVICEK R, J Orofac Pain, 7 (1993) 68. — 33. DELIC Z, SIMUNOVIC-SOSKIC M, PERINIC-GRZIC R, VUKOVOJAC S, RAJIC Z, KUNA T, Coll Antropol, 24 (2000) 31.

S. Čimić

University of Zagreb, School of Dental Medicine, Department of Removable Prosthodontics, Gundulićeva 5, 10000 Zagreb, Croatia.
e-mail: scimic@sfzg.hr

KRETNJA TEMPOROMANDIBULARNIH KONDILA TIJEKOM GUTANJA

SAŽETAK

Iako je bilo studija koje su proučavale kretnje i položaje donje čeljusti tijekom gutanja, rezultati nisu konzistentni, te i dalje položaj kondila tijekom gutanja ostaje nepoznat. Svrha istraživanja bila je proučavanje kinematike donje čeljusti i kondila, te određivanje stvarnih putanja i položaja donje čeljusti i kondila tijekom procesa gutanja. Istraživanje je provedeno na uzorku od 44 studenata stomatologije. Mjerenja su izvedena s elektroničkim aksiografom. Nakon što je paraokluzijska žlica pričvršćena na donji zubni niz, svaki ispitanik progutao je slinu pet puta, iz položaja fiziološkog mirovanja. Položaj lijevog i desnog kondila mjeren je tijekom završne faze gutanja u sagitalnoj ravnini. Položaj sagitalne incizalne točke tijekom završne faze gutanja mjeren je u sagitalnoj, frontalnoj i horizontalnoj ravnini, te su podaci statistički obrađeni. Prosječna kretanja kondila bila je prema posteriorno (lijevo 0,17 mm, SD 0,28, desno 0,16 mm, SD 0,25) i superiorno (lijevo 0,14 mm, SD 0,20, desno 0,14 mm, SD 0,23). Anteriorni i/ili inferiorni položaj imalo je 20% ispitanika. Prosječna kretanja sagitalne incizalne točke tijekom gutanja bila je anteriorno (0,30 mm, SD 0,53) i superiorno (0,81 mm, SD 0,84). Prosječna kretanja donje čeljusti prema lateralno iznosila je 0,1 mm (SD 0,1). Rezultati ovog istraživanja sugeriraju da retruzija kondila tijekom gutanja nije pravilo, iako u prosjeku postoji blaga tendencija kondila prema posteriorno. Gutanje se može koristiti kao pomoćna metoda za određivanje vertikalne dimenzije okluzije.