

## MICROEMBOLUS DETECTION BY TRANSCRANIAL DOPPLER SONOGRAPHY – TECHNICAL AND CLINICAL ASPECTS

Vlasta Vuković, Arijana Lovrenčić Huzjan and Vida Demarin

University Department of Neurology, Sestre milosrdnice University Hospital, Zagreb, Croatia

**SUMMARY** – Transcranial Doppler can detect microembolic signals which are characterized by unidirectional high intensity increase, short duration, random occurrence, producing a “whistling” sound. Microembolic signals have been proven to represent solid or gaseous particles within the blood flow. Microemboli have been detected in a number of clinical settings: carotid artery stenosis, aortic arch plaques, atrial fibrillation, myocardial infarction, prosthetic heart valves, patent foramen ovale, valvular stenosis, during invasive procedures (angiography, percutaneous transluminal angioplasty), surgery (carotid, cardiopulmonary bypass, orthopedic), and in certain systemic diseases. Despite numerous studies performed so far, clinical significance of microembolic signals is still unclear. This article provides an overview of the development and current state of technical and clinical aspects of microembolus detection.

**Key words:** *Brain – physiopathology; Brain – pathology; Intracranial embolism – physiopathology; Intracranial embolism – complications; Intracranial embolism – ultrasonography*

### Introduction

Embolization is the cause of ischemic stroke in 40%-80% of cases<sup>1</sup>. The possibility of emboli detection in intracranial circulation is very important since stroke is the second cause of death (the first in women) and the third cause of disability in Croatia<sup>2</sup>. Transient ischemic attack (TIA) is a warning sign of stroke; it is often caused by emboli lodged in a distal artery that underwent successful lysis<sup>3</sup>.

In the last 15 years a substantial number of studies dealing with emboli detection have been performed, while the clinical relevance of so-called high intensity transient signals (HITS) is still under debate. HITS are proven to represent emboli passing within cerebral circulation<sup>4</sup>. Emboli are particles of platelets, fibrinogen, cholesterol, fat, particles of disrupted plaque (thrombus) or gas bubbles that travel through circulation. First studies on em-

boli detection have been performed in the '60s<sup>5</sup>. In 1990 Spencer *et al.* reported on patients undergoing carotid endarterectomy (CEA) in whom HITS could be detected during the preparation phase of the artery, before opening of the artery lumen; detected HITS were assumed to represent emboli<sup>6</sup>.

Ever since, emboli have been detected in a number of clinical conditions: carotid artery stenosis, aortic arch plaques, atrial fibrillation, myocardial infarction, prosthetic heart valves, patent foramen ovale, valvular stenosis, during carotid surgery, open heart surgery, stent implantation, percutaneous transluminal angioplasty, and angiography<sup>7-17</sup>. Clinical significance of emboli detected in cerebral circulation is still unclear. While the vast majority of HITS are asymptomatic, there is substantial evidence at disposal that HITS are relevant in certain clinical conditions.

Consensus regarding emboli detection has been made, since different researchers had different identification criteria for emboli. The most important technical parameters affecting the detectability of microembolic signals are<sup>17</sup>:

1. relative intensity increase – ratio of the acoustic power backscattered from the embolus to that of the mov-

Correspondence to: Vlasta Vuković, M.D., University Department of Neurology, Sestre milosrdnice University Hospital, Vinogradska c. 29, HR-10000 Zagreb, Croatia  
E-mail: ???

Received August 16, 2004, accepted February 28, 2005

- ing blood surrounding the embolus; it is usually measured in decibels;
- detection threshold – ranging from 3 to 9 dB has been recommended;
  - size of the sample volume – most investigators use a value of sample volume length between  $\geq 3$  and  $\leq 10$  mm;
  - Fast Fourier Transform (FFT) frequency resolution and temporal resolution – the frequency resolution is given by the reciprocal of temporal resolution; the greater the number of points used for the FFT, the poorer the temporal resolution; therefore a compromise is necessary. At present 64, 128 or 256 frequency bins are preferred;
  - FFT temporal overlap – FFT overlap of at least 50% is essential; smaller overlaps (e.g., 10%) impose the risk of missing individual microembolic signals;
  - dynamic range of the instrumentation – a wide dynamic range prevents overloading of the receiver. Dynamic range depends on the manufacturer; devices presently marketed have dynamic ranges on the order of 30-50 dB;
  - transmitted ultrasound frequency – a frequency of 2 MHz is most frequently used; the sensitivity is lower with higher frequencies;
  - filter settings – high-pass filters suppress low frequencies originating from arterial wall oscillation; the level of high- and low-pass filters should be kept constant;

- recording time – depends on the study population (see below).

#### Characteristics of HITS

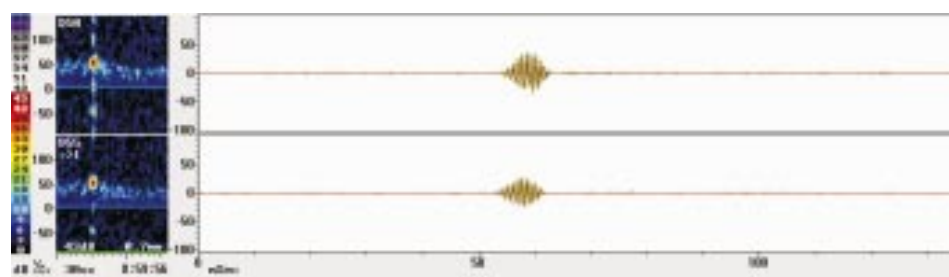
- short lasting ( $< 0.01$ - $0.03$  s) intensity increase
- unidirectional intensity increase ( $> 3$  dB) within the Doppler frequency spectrum
- intensity increase focused around 1 frequency
- random occurrence within the cardiac cycle
- produce a “whistle”, “chirping” or “clicking” sound when passing through the sample volume

#### Artifacts

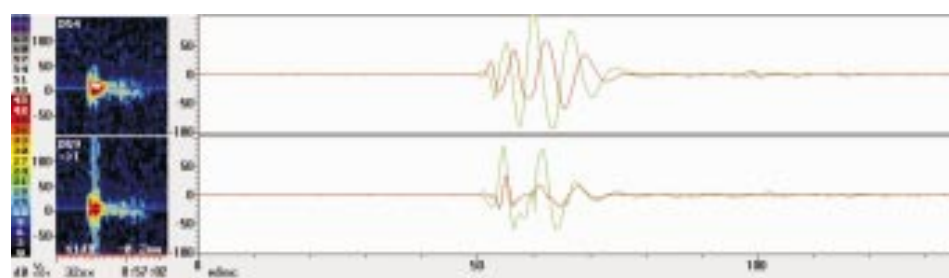
Artifacts also cause intensity increase of Doppler spectrum. Artifacts can be caused by patient moving the head, coughing, chewing or any movement that causes displacement of the probe. Intensity increase caused by artifacts will be present as bidirectional (above and under the zero line). Large, solid emboli or gaseous emboli may cause overload of the receiver which can produce similar signals as artifacts. Therefore it is important that the TCD machine has a wide dynamic range (at least 50 dB). Artifacts cause intensity increase usually of low frequency, around the zero line and produce sounds like “rumble”<sup>18</sup>.

#### Equipment

TCD machine for emboli detection should have a special software for emboli detection with a sufficient dynamic



*Fig. 1. Emboli signals detected in a patient with carotid artery stenosis*



*Fig. 2. Artifacts caused by coughing*

range. Two 2 MHz frequency probes are connected to a band or aluminum wire which is placed on the patient's head. The machine should have automatic saving of every change of Doppler spectrum caused by frequency shift, so detailed analysis can later be performed as many times as required. Video taping of the recordings is even better because not all softwares have the possibility to reproduce sound which is an important characteristic of emboli.

FFT signal processing is widely used in the evaluation of HITS. In FFT based calculations, the time window overlap is of considerable importance; HITS falling between two FFT intervals are likely to appear smaller than those in the middle, and if the overlap is very small HITS can even disappear. Modern equipment seldom encounters insufficient overlaps, if using older technology, window overlap should be taken in consideration when assessing HITS<sup>19</sup>.

New TCD machines, "multigate Doppler", enable better differentiation of emboli from artifacts. Two sample volumes are placed at a distance of at least 5 mm one from another, which enables recording of Doppler spectrum at 2 depths of an artery. When the embolus is moving from proximal to distal part of the artery, it passes 2 gates (sample volumes) and is then recorded twice with a delay in time, showing in the spectrum as two different appearances. Artifact is recorded simultaneously in both sample volumes and makes the same appearance. The main criteria for differentiation of HITS and artifacts in multigate Doppler machines is time difference (delay) of HITS<sup>20</sup>.

Emboli analysis other than FFT calculation is being improved with other methods such as Wigner distribution function, narrow band hypothesis, non-linear forecasting, frequency filtering of time domain data, and wavelet transformation<sup>21</sup>.

A new transcranial modality, power M-mode Doppler (PMD), has been developed to overcome the difficulties in location and insonation through transcranial ultrasound windows. PMD has 33 sample gates placed with 2-mm spacing for display of Doppler signal power, colored red and

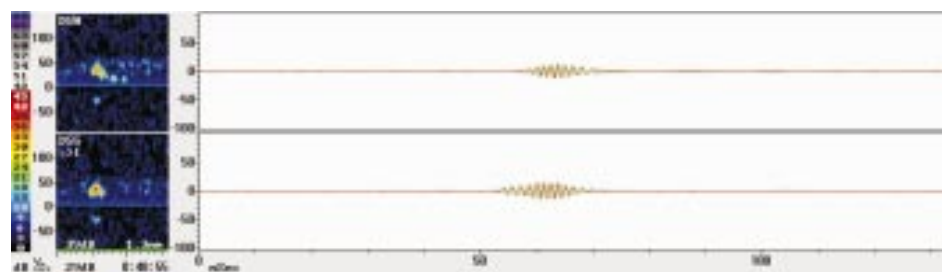
blue for directionality, in an M-mode format. The spectrogram from a user-selected depth is displayed simultaneously. PMD facilitates window location and alignment of the ultrasound beam to view blood flow from multiple vessels simultaneously, without sound or spectral clues. Microemboli appear as characteristic sloping high-power tracks in the PMD image<sup>22</sup>.

Although technological improvement in the area of emboli detection has recently been achieved, it is still impossible to reliably distinguish the composition of emboli. *In vivo* and *in vitro* studies have tried to differentiate gaseous from solid emboli. Differentiation between solid and gaseous microemboli is based on the principle that solid emboli reflect more ultrasound at higher frequency, whereas the opposite is the case for gaseous emboli. This principle is used in multifrequency TCD instrumentation where the vessels are insonated simultaneously with 2.5 and 2.0 MHz and can be used for the differentiation between gaseous and solid emboli<sup>23</sup>. Differentiation of solid and gaseous emboli has also been demonstrated by oxygen inhalation<sup>14</sup>. Intensity, duration and frequency are useful to distinguish between the two, however, it is still impossible to differentiate between particles of fat, platelet aggregates or particles of atheroma<sup>24</sup>.

#### Procedure of Emboli Detection

The patient is usually supine, kindly asked to sustain from coughing, head movements, etc. The aluminum wire (or tight rubber band) is placed on the patient's head, and both middle cerebral arteries (MCA) are insonated through temporal windows. When the Doppler signal is located, it is important to achieve a clear signal from the depth of 45-55 mm; insonation too close to the carotid siphon may result in recordings of false positive signals which are caused by blood turbulence<sup>25</sup>. At 45-55 mm depths the blood stream is mostly laminar and little turbulence is expected. After achieving a clear signal, the probes are fixed; monitoring is performed over at least 1 hour (extended monitoring is preferable if the patient is cooperative).

Fig. 3. Emboli signals detected in a patient with atrial fibrillation; arrows show time difference in MESS occurrence by use of multigate Doppler



### Monitoring Time

Optimal time of monitoring depends on the clinical entity. In patients with implanted artificial heart valves in whom HTS can be detected in large proportion, monitoring for 30 minutes will be sufficient. In patients with carotid artery stenosis, atrial fibrillation or other cardiac disease, the frequency of emboli is usually low, 1-2 emboli signals over 60 minutes. Extended monitoring, for more than 1 hour, or repetitive monitoring over a couple of days in succession, is in relation with the percentage of emboli positive patients<sup>26,27</sup>. Embolic activity is highest in the first couple of hours after stroke; however, emboli may be detectable days and weeks after cerebrovascular incidents, which means that those patients are at a higher risk of stroke<sup>28,29</sup>. It must be highlighted that patients who have no recorded emboli signals (even on repetitive monitoring) cannot be declared as “emboli negative”. However, patients who have detectable emboli, especially in larger number, should be considered as high risk patients for stroke.

Emboli detection may help in localization of embolic source: emboli detected in both MCAs are usually from cardiac source, and emboli detected ipsilaterally to a carotid artery stenosis are probably dislodged from intraluminal thrombus or plaque disruption<sup>30,31</sup>.

Although emboli monitoring is considered as a safe and noninvasive method, a small number of studies have focused on this issue. *In vivo* studies have shown that bilateral monitoring of MCA with 530 mW/cm<sup>3</sup> over 8 hours caused no abnormal immediate or late changes of the tissue, as shown on histologic specimens; the power used in this study exceeded the power which is used in commercial TCD machines<sup>32</sup>.

### Clinical Aspects of Emboli Detection

Cerebral microemboli can be detected in a variety of clinical conditions. Emboli detection may help in:

#### I Localization of embolic source

1. Arterial source of emboli
  - a) atherosclerotic artery disease
    - carotid stenosis
    - intracranial artery stenosis
    - aortic arch plaques
  - b) dissection of carotid arteries
  - c) aortic aneurysm
2. Cardiac sources of emboli
 

Major significance	Minor significance
Atrial fibrillation	Mitral valve prolapse

- |                            |  |
|----------------------------|--|
| Valvular stenosis (mitral) | Patent foramen ovale                     |
| Myocardial infarction      | Aneurysm of atrial septum                |
| Thrombus in left ventricle | Valvular calcifications (mitral, aortic) |
| Infective myocarditis      | Prosthetic heart valve                   |
| Myxoma in left atrium      |  |
| Dilatative cardiomyopathy  |  |

#### II Identification of patients with high stroke risk

Besides the causes stated under I, includes

- a) hypercoagulable state
- b) systemic diseases such as antiphospholipid syndrome, Sneddon's syndrome

#### III Monitoring during invasive procedures and surgery

- a) cardiopulmonary bypass
- b) orthopedic surgery
- c) carotid endarterectomy
- d) percutaneous luminal angioplasty
- e) angiography

#### IV Monitoring of therapeutic efficacy

### Atherosclerotic Disease

#### Carotid stenosis

Detection of emboli ipsilaterally to carotid stenosis may localize the source of emboli, help in classification/etiology of cerebrovascular symptoms, indicate asymptomatic patients with higher stroke risk.

The frequency of embolic signals is higher in patients with higher grade of carotid stenosis: stenosis >29% is not prone to embolization, 30%-69% stenosis may in certain conditions produce emboli, and stenosis >70% is prone to embolization<sup>33,34</sup>. Plaque characteristics are also important: intraluminal thrombosis, irregular plaque surface, and ulceration are in relation with emboli frequency<sup>35,36</sup>.

Studies have shown great variability of detected emboli in patients with carotid stenosis, however, all studies are consistent in the observation that the frequency of emboli in asymptomatic patients is significantly lower. In one study symptomatic patients with severe carotid stenosis were emboli positive in 77%, and asymptomatic in only 16%<sup>37</sup>. In another study emboli were detected in 27% of symptomatic and 2.9% of asymptomatic patients<sup>38</sup>. In several studies a shorter time interval between stroke and monitoring was related to the frequency of detected emboli<sup>16,20,39,40</sup>.

Most of the patients with severe carotid stenosis will eventually produce microemboli. However, the production

of emboli is random, and it is likely that many hours of monitoring are required to determine whether a patient with symptomatic carotid diseases is emboli positive. Microemboli in these patients can identify patients at risk and furthermore indicate periods of transiently increased risk in individual patients<sup>41</sup>. After carotid endarterectomy, emboli signals disappear or the frequency is significantly lower<sup>42</sup>.

Dissection of carotid arteries is an embolic source, and emboli can be detected in a high proportion of these patients<sup>43</sup>.

The presence of emboli in cerebral circulation can be regarded as a risk factor for stroke<sup>44-46</sup>.

#### Aortic arch atheroma

Aortic arch atheroma has long been underestimated as an embolic source. Studies have shown that aortic arch atheroma is a strong and independent risk factor for ischemic stroke. The risk of stroke increases sharply when the thickness of plaques is greater than 4 mm; the attributable stroke risk is 12.6%; microembolic signals can be detected in 14.3% of these patients<sup>47</sup>.

#### Cardiac Diseases

Stroke is a relatively frequent complication in patients with cardiac diseases; 15%-30% of strokes are caused by cardiac diseases<sup>13</sup>. Clinical and epidemiological observations show that patients with thrombi in left ventricle, atrial fibrillation and other cardiac diseases have a higher risk of continuous embolization; these observations have been substantiated by the presence of MES in cerebral circulation detected by TCD in patients with such conditions<sup>48,49</sup>. Prospective studies have shown that recurrent stroke or systemic embolization is high in this group of patients, up to 20%<sup>28,50</sup>. Strokes due to cardioembolism are in general severe and prone to early and longterm recurrence. Cardioembolism can be reliably suspected on clinical grounds but is often difficult to document.

#### Prosthetic heart valves

Thromboembolism is a significant complication in patients with prosthetic heart valves (PHV). Patients with mechanical, especially mitral valves have a higher risk of thromboembolism than patients with biological or aortic heart valves<sup>51</sup>. The majority of studies have reported on a high proportion of patients with detectable HITS in cerebral circulation, ranging from 50% to 90%<sup>52-56</sup>. Five days after implantation of PHV emboli signals were detectable

in 75% of patients, approximately 10 *per* hour, one year later 90% of patients had HITS in cerebral circulation, 55 *per* hour<sup>56</sup>.

HITS detected in patients with PHV have higher intensity and duration than HITS detected in patients with carotid stenosis or atrial fibrillation<sup>30,55,57</sup>. The majority of HITS in patients with PHV correspond to gaseous origin, e.g., due to cavitations at mechanical heart valves; it was demonstrated in experimental studies with mechanical PHV and in studies where inhalation of oxygen led to a decrease in HITS in patients with PHV but the frequency remained unchanged in patients with atherothrombotic source of emboli<sup>14</sup>.

Clinical relevance of HITS in patients with PHV is unclear. The lack of association between HITS, clinical symptoms and cognitive functioning suggests that most of these signals are clinically not relevant except for those detected after O<sub>2</sub> inhalation<sup>58</sup>. Larger prospective studies are needed to elucidate whether HITS in patients with PHV are a risk factor for stroke and whether certain types of mechanical PHV and optimal anticoagulant/antiaggregation therapy would influence the frequency of HITS.

#### Atrial fibrillation

Atrial fibrillation (AF) is a frequent cardiac rhythm disorder in older patients. AF is present in 1.7% of the population aged 60-64, and in 6% of the population older than 75 years<sup>59</sup>. The incidence of stroke in patients with AF is 4.5% *per* year<sup>60</sup>. In cases when AF is associated with mitral valve stenosis, the risk of stroke is 17 times higher<sup>61</sup>. The majority of strokes in patients with AF are embolic in origin; emboli signals can be detected in 15%-30%<sup>62,63</sup>.

Paroxysmal AF is also considered a risk factor for stroke; the incidence of embolic incidents in patients with paroxysmal AF is similar to that in patients with chronic AF<sup>64</sup>.

Ischemic stroke is more severe than in patients with sinus rhythm, the outcome is often fatal, in survivors recurrent stroke is more frequent and neurologic deficit is more severe<sup>65,66</sup>. Emboli detection in patients with AF can reveal patients at a high stroke risk.

#### Spontaneous echo contrast

Spontaneous echo contrast can be visualized by transthoracic echocardiography, it appears like a "swirl" or a "cloud" in left atrium and left appendage<sup>67</sup>. This phenomenon is due to erythrocyte aggregation in the presence of macromolecules in conditions of blood stasis<sup>68</sup>. Spontaneous echo contrast is present in patients with AF, dilated



atrium and left appendage, PHV (mitral) and severe ventricular dysfunction<sup>68</sup>.

Echo contrast is an independent risk factor for thrombus formation in left atrium and for systemic embolization<sup>68</sup>.

#### Myocardial infarction

Approximately 2.5% of patients with acute myocardial infarction will have stroke within 2-4 months<sup>69</sup>. Patients with anterior wall infarct have a stroke risk of 6%, and those with inferior wall 1%<sup>70</sup>. In a prospective study in patients with anterior wall MI, emboli signals could be detected in 21%<sup>70</sup>. Mobile thrombi in left ventricle, anterior and apical localization as well as the size of dyskinetic wall segment have a predictive value for stroke<sup>69</sup>.

#### Infective myocarditis

The prevalence of stroke in patients with infective myocarditis is 15%-20%<sup>71</sup>. The size of vegetations has a predictive value, the risk of embolization is higher in patients with vegetations larger than 10 mm, in patients with endocarditis of mitral valve and mobile vegetations<sup>71</sup>.

#### Dilatative congestive cardiomyopathy

Impaired systolic function results in low ejection fraction; when dilatation becomes significant, as a frequent complication mural thrombi are being formed<sup>69</sup>. The incidence of embolic complications in patients with cardiomyopathy is 4% *per year*<sup>70</sup>. Embolic signals are detectable in 1/3 of patients with dilatative congestive cardiomyopathy<sup>13</sup>.

#### Mitral valve prolapse

The prevalence of mitral valve prolapse (MVP) in the general population is 1%-15%<sup>72</sup>. Isolated MVP is not considered as a significant risk factor for stroke in older patients, but in younger patients myxomatous change of mitral valves is considered to be in relationship with cerebrovascular incidents<sup>72</sup>.

#### Patent foramen ovale

The prevalence of patent foramen ovale (PFO) in the general population is 22%-34.4%<sup>73,74</sup>. In patients with cryptogenic stroke, especially younger patients, a high prevalence of PFO has been found<sup>75,76</sup>. The rate of recurrent stroke or TIA is 9.9%<sup>77</sup>. TCD has shown to be highly specific and sensitive, and may serve as an excellent alternative method to the gold standard of transesophageal echocardiography (TEE) in the diagnosis of PFO<sup>78</sup>. When

performing TEE, the presence of PFO is confirmed if gas bubbles are seen within 3 cardiac cycles after contrast injection; and when performing TCD when MES are detected in the MCA 10 seconds after injection of contrast agent prepared as agitated isotonic saline solution in the cubital vein<sup>79</sup>. Valsalva maneuver performed during contrast injection increases the sensitivity. PFO has shown to be a significant risk factor for stroke in younger patients.

Two factors have been identified as factors that potentially increase the risk of stroke:

- 1) PFO associated with atrial septal aneurysm (ASA) – a multicenter study has shown that stroke risk over 4 years is 19.2% in patients with PFO and ASA and only 5.6% in patients with isolated PFO<sup>80</sup>
- 2) size of PFO – a study has shown that PFO >2 mm is present in a higher proportion of patients with cryptogenic stroke (26%) than in patients with identified cause (6%)<sup>81</sup>. Other study has shown the size of PFO to be >4 mm in patients with stroke as opposed to the healthy control group with the size of PFO <2 mm<sup>82</sup>. As a method for evaluation of the size of PFO the amount of blood (MES) after i.v. contrast or agitated saline injection has been proposed; a four level categorization according to MES count should be applied<sup>79</sup>:
  - a) 0 MES – negative result
  - b) 1-10 MES – small PFO
  - c) >10 MES – large PFO
  - d) curtain – “shower” of MES, numerous bubbles where a single bubble cannot be identified

A clinical study has shown that the presence of “curtain” correlates with the highest risk of stroke<sup>83</sup>.

The size of right-to-left shunt estimated with TCD may not be in correlation with the size of PFO estimated with echocardiography, as other factors can influence the blood volume that passes through the shunt<sup>84</sup>.

PFO is present in a high percentage in scuba divers with complications due to decompression disease; the risk is 2.5-4.5 times higher in patients with PFO<sup>85,86</sup>.

TCD can serve as an excellent screening method for the detection and size of right-to-left shunt; TEE is indicated in shunt positive patients to confirm the localization of the shunt, and to investigate the presence of ASA or other cardiac abnormalities.

#### Cardiac tumors

Although rare, atrial myxoma is the most frequent primary cardiac tumor, usually present in the left atrium. Due to its fragile nature, myxoma has a high potential for embolization to the brain as well as to other organs<sup>87</sup>.

## Monitoring During Invasive Procedures

### Cardiopulmonary bypass

In the last 2 decades cardiac surgery has gained significant progress; however, postoperative transient or persistent neurologic deficit is present in a large proportion of patients. Perioperative stroke occurs in 2%-3% of adult cardiac surgery patients and significant cognitive dysfunction is experienced by 40%-60% of patients in the first postoperative week<sup>88</sup>. Perioperative neurocognitive abnormalities are associated with a greatly increased risk of perioperative mortality, lengthy intensive care and hospital stay. Longterm cognitive dysfunction, ranging from months to years, occurs in 25%-40% of patients resulting in a decreased quality of life<sup>88</sup>.

The exact pathophysiological mechanism responsible for postcarotid artery bypass graft (CABG) deficit is not clear; the two most important are hypoperfusion and microembolism. In patients with postoperative neurologic deficit emboli can be detected twice as high as in patients without emboli signals in cerebral circulation<sup>9</sup>. Neurologic deficit was present 8 weeks postoperatively in 8.6% of patients in whom <200 emboli during CABG were detected, and in 43% of patients with 1000 detectable emboli *per* surgery<sup>89</sup>. Improvement of technology results in better postoperative outcome: the introduction of filters has resulted in a lower incidence of neurologic lesions (5%) as compared with patients who had the surgery performed with unfiltered machines (27%)<sup>89</sup>.

Observations from these and similar studies indicate that microembolization could be a significant cause of neurologic and cognitive deficits in patients after CABG.

### Orthopedic surgery

Orthopedic surgery is associated with a high risk of perioperative complications; embolism might be the cause of confusion states that often complicate these surgeries. Knee and hip arthroplasty is associated with cerebral microembolism in 30%-60% of patients<sup>90</sup>. Cerebral embolism has been documented during scoliosis surgery in cases with right-to-left shunt through PFO<sup>91</sup>.

### Carotid endarterectomy (CEA)

Prospective studies in patients with high grade carotid stenosis have shown that stroke occurred in patients with cerebral microemboli detected with TCD who had not had a surgery; the risk significantly decreased after CEA and emboli signals had disappeared or significantly decreased<sup>42,92</sup>.

Emboli signals can be detected during the dissection phase of the artery, especially during implantation and removal of the shunt and after clamp release<sup>6,93</sup>.

The efficacy of CEA largely depends on postoperative results, i.e. perioperative complications. Intraoperative monitoring of hemodynamic changes and detection of MES may significantly influence postoperative outcome<sup>94</sup>. A study in 500 patients has shown that microemboli detected during surgery are the probable cause of cerebrovascular complications in 54%; the incidence of persistent neurologic deficit decreased from 7% (documented after the first 100 surgeries) to 2% (documented in the next 400 surgeries) when surgeons changed the operative strategy according to intraoperative TCD information<sup>93</sup>.

### Percutaneous transluminal angioplasty (PTA)

Advantages and disadvantages of PTA as compared with classic CEA are still a matter of debate. Main disadvantages are attributed to the higher risk of neurologic complications due to hemodynamic ischemia during balloon inflation and microembolization after plaque disruption. Studies have shown inconsistent results. Several studies have shown that despite higher frequency of detected emboli, stroke risk was not higher in patients in whom PTA was performed, whereas others put in doubt the advantages of PTA due to the high frequency of emboli and complications during the procedure<sup>12,95</sup>. The use of cerebral protection devices appears to reduce thromboembolic complications during PTA and stenting; the combined stroke and death rate within 30 days in patients treated with cerebral protection devices was 1.8% as compared with 5.5% in patients without these devices<sup>96</sup>.

Experimental studies have shown that the majority of MES are gaseous in origin, whereas MES detected during balloon inflation are probably attributable to solid particles<sup>97</sup>.

### Angiography

Angiography of the aortic arch is associated with 1% risk of stroke with permanent deficit, and 3% risk of mild to moderate stroke or TIA<sup>10,11</sup>. In a study with 24 patients undergoing angiography, all patients had detectable emboli signals, approximately 51 *per* patient, the majority of emboli signals had the characteristics of gas bubbles, the number of detected MES correlated with the volume of injected contrast, and all patients except one who had stroke were asymptomatic<sup>11</sup>.

MES detected during angiography are attributable to gas bubbles, contrast injection, clot formation in catheter, and disrupted atheromatous material<sup>10,11</sup>.

Angiography in acute stroke is associated with a higher risk of neurologic deficit progression<sup>98</sup>.

Magnetic resonance studies have shown an increased number of brain parenchymal lesions after angiography, although the majority of patients had no neurologic deficit<sup>99</sup>.

### Systemic Diseases

Emboli signals in cerebral circulation are detectable in primary antiphospholipid syndrome, Sneddon's syndrome, systemic lupus, Behcet's disease and Takayasu's arteritis, and are in temporal relation with cerebrovascular incidents in these patients<sup>100-103</sup>.

### Coagulation

Coagulation mechanisms in patients with stroke, TIA, coronary and other cardiac diseases are not fully understood. Clinical studies have shown that hyperfibrinogenemia is in positive correlation with cardiovascular and cerebrovascular diseases<sup>104-107</sup>. Patients with progressive atherosclerosis have higher levels of fibrinogen compared with those with nonprogressive disease<sup>108</sup>. Patients with fibrinogen blood level > 5 g/L have a fourfold risk of thromboembolic complications<sup>109</sup>. Embolic signals are detectable with a higher frequency in patients with higher fibrinogen levels<sup>104</sup>.

### Monitoring of Therapeutic Efficacy

Monitoring of therapeutic effect has shown that after CEA emboli disappear or decrease in frequency, a finding consistent across studies<sup>42,92</sup>. Studies that investigated the efficacy of anticoagulant and antiaggregation therapy and frequency of emboli have shown various results. Although some studies have shown a decrease in emboli frequency after aspirin or heparin administration, consistent correlation has not been found. However, the CARESS trial (first multicenter, randomized, double blind trial that used MES detection as endpoint to evaluate antiplatelet therapy) has shown that clopidogrel + aspirin is superior to aspirin alone in reducing the frequency of MES in patients with recent symptomatic carotid stenosis. Monitoring of therapeutic efficacy has been consistent after CEA<sup>28,29,31,110-113</sup>.

S-nitrosoglutathione (GSNO) is a nitric oxide donor that appears to have relative platelet specificity. The administration of GSNO in patients with carotid artery stenosis resulted in a rapid reduction in the frequency of embolic signals of 84% at 0-3 hours, 95% at 6 hours, and 100% at 24 hours. Despite its short half-life, GSNO proved highly

effective in rapidly reducing the frequency of embolic signals in this patient group<sup>114</sup>.

Glycoprotein IIb/IIIa receptor antagonist tirofiban is a highly selective platelet aggregation inhibitor. The administration of tirofiban resulted in microembolic rate drop from a median range of 38 to zero in patients with severe carotid artery stenosis, however, the inhibitory effect of tirofiban is reversible<sup>115</sup>.

### Clinical Significance of Emboli Detection

Clinical significance of emboli detection is not fully elucidated; numerous studies have shown various results. A significantly higher frequency of emboli signals was detected in patients with acute stroke when monitoring was performed within the first couple of hours as compared to post stroke days. Patients in whom emboli signals are detectable later more frequently have recurrent stroke, often fatal. A certain proportion of patients with detectable emboli signals are asymptomatic, although correlation of cerebral microemboli with clinical symptoms (stroke or TIA ipsilateral to carotid stenosis, higher incidence of stroke in patients with cardiac diseases, neurologic complications after angiography, postoperative neurologic complications after CEA, in patients after CABG) was shown in a number of studies. It is important to emphasize that the vast majority of emboli do not produce immediate symptoms. Great variability of results demonstrated in various studies is attributable to the small number of included patients, inhomogeneous patient groups, different TCD machines and equipment settings, and different criteria for emboli characterization. Despite disputable clinical significance in certain conditions, the potential benefit of TCD emboli detection is substantial. Emboli in cerebral circulation indicate asymptomatic patients with increased stroke risk. In symptomatic patients the etiology of neurologic deficit may be elucidated and appropriate therapy introduced.

Emboli detection may help in differentiation between hemodynamic and embolic stroke. In certain cases emboli detection may indicate the embolic source; in patients with carotid stenosis emboli signals will be detected ipsilaterally to the stenosis, whereas in patients with cardiac diseases emboli can be detected in both MCAs, or in all cerebral arteries.

Patients with cerebral microembolism have higher cognitive deficits; cumulative effect of embolism is thought to be the cause. Even a minor neuropsychological impairment should not be underestimated, and the presence of an embolic source should be regarded as the pos-



sible cause of cognitive decline. Imaging techniques (CT scan, MRI, DWI-MRI) can show “silent” areas of cerebral ischemia; these small and multiple areas of acute or sub-acute brain infarction may occasionally present with clinical features atypical for brain embolism or will not produce any apparent symptoms<sup>116</sup>.

Besides the size and composition of emboli, other factors play a role in asymptomatic/symptomatic patients; these factors probably include collateral circulation and characteristics of the recipient vessel.

Multicenter studies with a large number of patients and standardized monitoring protocols are needed to elucidate the clinical significance of emboli signals in cerebral circulation.

## References

1. BOGOUSLAVSKY J, CACHIN C, REGLIF, DESPLAND PA, Van MELLE G, KAPENBERG L. Cardiac sources of embolism and cerebral infarction – clinical consequences and vascular concomitants: the Lausanne Stroke Registry. *Neurology* 1991;41:855-9.
2. Croatian Health Service Yearbook 2001. Croatian National Institute of Public Health, Zagreb 2002:38.
3. DEMARIN V, *et al.* Priručnik iz neurologije. Bjelovar: Prosvjeta, 1998.
4. MARKUS HS, LOH A, BROWN MM. Detection of circulating cerebral emboli using Doppler ultrasound in a sheep model. *J Neurol Sci* 1994;122:117-24.
5. SPENCER MP, LAWRENCE GH, THOMAS GI, SAUVAGE LR. The use of ultrasonics in the determination of arterial atheroembolism during open heart surgery. *Ann Thorac Surg* 1969;8:489-97.
6. SPENCER MP, THOMAS GI, NICHOLLS SC, SAUVAGE LR. Detection of middle cerebral artery emboli during carotid endarterectomy using transcranial Doppler ultrasonography. *Stroke* 1990;21:415-23.
7. INFELD B, BOWSER DN, GERRATY RP, VOUKELATOS J, GRIGG L, MITCHELL PJ, HOPPER JL, DAVIS SM. Cerebral microemboli in atrial fibrillation detected by transcranial Doppler ultrasonography. *Cerebrovasc Dis* 1996;6:339-45.
8. SMITH JL, EVANS DH, GAUNT ME, LONDON NJM, BELL PRF, NAYLOR AR. Experience with transcranial Doppler monitoring reduces the incidence of particulate embolization during carotid endarterectomy. *Br J Surg* 1998;85:56-9.
9. STUMP DA, TEGELER CH, ROGERS AT, COKER LH, NEWMANN SP, WALLENHAUPT SL, HAMMON JW. Neuropsychological deficits are associated with the number of emboli detected during cardiac surgery. *Stroke* 1993;24:509.
10. GERRATY RP, BOWSER DN, INFELD B, MITCHELL PJ, DAVIS SM. Microemboli during carotid angiography. *Stroke* 1996;27:1543-7.
11. BENDSZUS M, KOLTZENBURG M, BURGER R, WARMUTH-METZ M, HOFMANN E, SOLYMOSI L. Silent embolism in diagnostic cerebral angiography and neurointerventional procedures: a prospective study. *Lancet* 1999;354:1594-7.
12. McCLEARY AJ, NELSON M, DEARDENT NM, CALVEY TAJ, GOUGH MJ. Cerebral haemodynamics and embolization during carotid angioplasty in high-risk patients. *Br J Surg* 1998;85:771-4.
13. SLIWKA U, JOB FP, WISSUMA D, DIEHL R, FLACHSKAMPF FA, HONRATH A, NOTH J. Occurrence of transcranial Doppler high-intensity transient signals in patients with potential cardiac sources of embolism. *Stroke* 1995;26:2067-70.
14. DROSTE DW, HANSBERG T, KEMENY V, HAMMEL D, SCHULTE-ALTDORNEBURG G, NABAVI DG, KAPS M, SCHELD HH, RINGELSTEIN EB. Oxygen inhalation can differentiate gaseous from nongaseous microemboli detected by transcranial Doppler ultrasound. *Stroke* 1997;28:2453-6.
15. DEMARIN V, VUKOVIĆ V, PODOBNIK-ŠARKANJI S. Cerebral microemboli in patients with cardiac diseases. *Eur J Neurol* 1997;4 (Suppl 1):62.
16. DEMARIN V, RUNDEK T, VUKOVIĆ V. Prevalence of cerebral emboli in patients with carotid artery disease. In: Klingerhoefer J, ed. *New trends in cerebral hemodynamics and neurosonology*. Grad: Elsevier Science B.V., 1997:420-44.
17. RINGELSTEIN RB, DROSTE DW, BABIKIAN VI. Consensus on microembolic detection by TCD. International Consensus Group on Microembolic Detection. *Stroke* 1998;29:725-9.
18. MARKUS HS, LOH A, BROWN MB. Computerized detection of cerebral emboli and discrimination from artifact using Doppler ultrasound. *Stroke* 1993;24:1667-72.
19. MARKUS HS. Importance of time window overlap in the detection and analysis of embolic signals. *Stroke* 1995;26:2044-7.
20. DROSTE DW, HAGEDORN G, NÖTZOLD A, SIEMENS HJ, SIEVERS HH, KAPS M. Bigated transcranial Doppler for the detection of clinically silent circulating emboli in normal persons and patients with prosthetic cardiac valves. *Stroke* 1997;28:588-92.
21. HENNERICI MG, MEAIRS SP. High intensity transient signals. In: ????. *Cerebrovascular ultrasound. Theory, practice and future developments*. Cambridge: Cambridge University Press, 2001:299.
22. MOEHRING MA, SPENCER MP. Power M-mode Doppler (PMD) for observing blood flow and tracking emboli. *Ultrasound Med Biol* 2002;28:49-57.
23. RUSSELL D, BRUCHER R. Online automatic discrimination between solid and gaseous cerebral microemboli with the first multi-frequency transcranial Doppler. *Stroke* 2002;33:1975-80.
24. RODRIGUEZ RA, GIACHINO A, HOSKING M, NATHAN HJ. Transcranial Doppler characteristics of different embolic materials during *in vivo* testing. *J Neuroimaging* 2002;12:259-66.
25. ALEXANDROV AV, DEMARIN V. Insonation techniques and diagnostic criteria for transcranial Doppler sonography. *Acta Clin Croat* 1999;38:97-108.
26. DROSTE DW, RITTER M, KEMENY V, SCHULTE-ALTDORNEBURG G, RINGELSTEIN BE. Microembolus detection at follow-up in 19 patients with acute stroke. *Cerebrovasc Dis* 2000;10:272-7.
27. MOLLOY J, KHAN N, MARKUS HS. Temporal variability of asymptomatic embolization in carotid artery stenosis and optimal recording protocols. *Stroke* 1998;29:1129-32.

28. SLIWKA U, LINGNAU A, STOHLMANN WD, SCHMIDT P, MULL M, DIEHL RR, NOTH J. Prevalence and time course of microembolic signals in patients with acute stroke. *Stroke* 1997;28:358-63.
29. FORTEZAAM, BABIKIAN VL, HYDE C, WINTER M, POCHAY V. Effect of time and cerebrovascular symptoms on the prevalence of microembolic signals in patients with cervical carotid stenosis. *Stroke* 1996;27:687-90.
30. GROSSET DG, GEORGIADIS D, KELMAN AW, LEES KR. Quantification of ultrasound emboli signals in patients with cardiac and carotid disease. *Stroke* 1993;24:1922-4.
31. RIES S, SCHMINKE U, DAFFERTSHOFER M, SCHINLMAYR C, HENNERICI M. High intensity transient signals and carotid artery disease. *Cerebrovasc Dis* 1995;5:124-7.
32. BUNEGIN L, GELINEAU J, ALBIN MS. Physiologic, histologic and neurologic response to simultaneous bilateral cerebral vessel Doppler imaging at high beam intensity. *J Neurosurg Anesthesiol* 1998;10:42-8.
33. EICKE BM, von LORENTZ J, PAULUS W. Embolus detection in different degrees of carotid disease. *Neurol Res* 1995;17:181-4.
34. VUKOVIĆ V, DEMARIN V, HUZJAN-LOVRENČIĆ A, PODOBNIK-ŠARKANJI S. Analysis of cerebral microemboli in relationship to carotid stenosis and plaque type. *Cerebrovasc Dis* 1998;8(Suppl 4):101.
35. SITZER M, MULLER W, SIEBLER M. Plaque ulceration and lumen thrombus are the main sources of cerebral microemboli in high-grade internal carotid artery stenosis. *Stroke* 1995;26:1231-3.
36. SIEBLER M, KLEINSCHMIDT A, SITZER M, STEINMETZ H, FREUND HJ. Cerebral microembolism in symptomatic and asymptomatic high-grade internal carotid artery stenosis. *Neurology* 1994;44:615-8.
37. VUKOVIĆ V. Atherosclerotic plaque – morphology, dynamics, complications and symptoms. *Acta Clin Croat* 1998;37(Suppl 2):19-24.
38. BABIKIAN VL, HYDE C, POCHAY V, *et al.* Clinical correlates of high-intensity transient signals detected in transcranial Doppler sonography in patients with cerebrovascular disease. *Stroke* 1994;25:1570-3.
39. MARCUS HS, THOMPSON N, DROSTE DW, *et al.* Cerebral embolic signals in carotid artery stenosis and their temporal variability. *Cerebrovasc Dis* 1994;4:22. (Abstract)
40. Van ZUILEN EV, MAUSER HW, van GIJN, *et al.* The relationship between cerebral microemboli and symptomatic cerebral ischaemia: a study of transcranial Doppler monitoring. *Cerebrovasc Dis* 1994;4:20.
41. HUTCHINSON S, RIDING G, COULLS, McCOLLUM CN. Are spontaneous microemboli consistent in carotid disease? *Stroke* 2002;33:685-8.
42. SIEBLER M, SITZER M, ROSE G, *et al.* Silent cerebral embolism caused by neurologically symptomatic high-grade carotid stenosis: event rates before and after carotid endarterectomy. *Brain* 1993;116:1005-15.
43. MOLINA CA, ALVAREZ-SABIN J, SCHONEWILLE W, MONTANER J, ROUIRA A, ABILLEIRA S, CODINA A. Cerebral microembolism in acute spontaneous internal artery dissection. *Neurology* 2000;55:1738-41.
44. MOLLOY J, MARKUS HS. Asymptomatic embolization predicts stroke and TIA risk in patients with carotid artery stenosis. *Stroke* 1999;30:1440-3.
45. VASSILEVA E, SCHNORF H, PERSONENI O, FLOCH-ROHR J. Microembolic signals and early recurrent cerebral ischemia in carotid artery disease. *Stroke* 1999;30:1493.
46. VALTON L, LARRUE V, le TRAON AP, MASSABUAU P, GERAUD G. Microembolic signals and risk of early recurrence in patients with stroke or transient ischemic attack. *Stroke* 1998;29:2125-8.
47. VIGUIER A, PAVY le TRAON A, MASSABUAU P, VALTON L, LARRUE V. Asymptomatic cerebral embolic signals in patients with acute cerebral ischemia and severe aortic arch atherosclerosis. *J Neurol* 2001;248:768-71.
48. STRATTON J, RESNICK A. Increased embolic risk in patients with left ventricular thrombi. *Circulation* 1987;75:1004-11.
49. NABAVI D, ARATO S, DROSTE DW, SCHULTE G. Microembolic load in asymptomatic patients with cardiac aneurysm, severe ventricular dysfunction and atrial fibrillation. *Cerebrovasc Dis* 1998;8:214-21.
50. YASAKA M, YAMAGUCHI T, OHTA J, SAWADA T, SHICHIRI M, OMAE T. Clinical features of recurrent embolization in acute cardioembolic stroke. *Stroke* 1993;24:1681-5.
51. CAMPBELL COWAN J. Surgery for valvar heart disease. In: HALL RJC, JULIAN DG, eds. *Diseases of the cardiac valves*. Edinburgh: Churchill Livingstone, 1989.
52. DEMARIN V, VUKOVIĆ V. HITS in patients with prosthetic heart valves. *J Neurol Sci* 1997;150(Suppl): 80.
53. MÜLLER HR, BURCKHARDT D, CASTY M, PFISTERER M, BUSER MW. High intensity transcranial Doppler signals (HITS) after prosthetic valve implantation. *J Heart Valve Dis* 1994;3:602-6.
54. GEORGIADIS D, GROSSET DG, KELMAN A, *et al.* Prevalence and characteristics of intracranial microemboli signals in patients with different types of prosthetic cardiac valves. *Stroke* 1994;25:587-92.
55. MARCUS HS, DROSTE DW, BROWN MM. Detection of asymptomatic cerebral embolic signals with Doppler ultrasound. *Lancet* 1994;343:1011-2.
56. BRAEKEN SK, RUSSELL D, BRUCHER R, *et al.* Cerebral emboli in prosthetic heart valve patients. *Stroke* 1994;25:739.
57. DEMARIN V, RUNDEK T. Clinical relevance of cerebral emboli detection in patients with nonvalvular atrial fibrillation and prosthetic heart valves. *Neurology* 1997;48:153.
58. NADAREISHVILI ZG, BELETSKY V, BLACK SE, FREMES SE, FREDMAN M, KURZMAN D, LEACH L, NORRIS JW. Is cerebral microembolism in mechanical prosthetic heart valves clinically relevant? *J Neuroimaging* 2002;12:310-5.
59. LAKE FR, CULLEN KJ, de KLERKN. Atrial fibrillation and mortality in an elderly population. *Aust N Z J Med* 1989;19:231-6.
60. WOLF PA, ABBOTT R, KANNEL WB. Atrial fibrillation as an independent risk factor for stroke: the Framingham study. *Stroke* 1991;22:983-8.

61. LIN HL, WOLF PA, KELLY-HAYES M, BEISER AS, KASE CS, BENJAMIN EJ, D'AGOSTINO RB. Stroke severity in atrial fibrillation. The Framingham study. *Stroke* 1996;27:1760-4.
62. CULLINANE M, WAINWRIGHT R, BROWN A, MONAGHAN M, MARCUS HS. Asymptomatic embolization in subjects with atrial fibrillation not taking anticoagulants: a prospective study. *Stroke* 1998;29:1810-5.
63. RUNDEK T, DEMARIN V, VUKOVIĆ V, PODOBNIK-ŠARKANJIS, STARČEVIĆ B. TCD detection of cerebral emboli in patients with nonvalvular atrial fibrillation: a 1 year follow-up survey. In: KLINGERHOEFER J, ed. *New trends in cerebral hemodynamics and neurosonology*. Grad: Elsevier Science B.V., 1997:435-40.
64. LIP GYH, LOWE DGO, RUMLEYA, DUNN FG. Fibrinogen and fibrin D-dimer levels in paroxysmal atrial fibrillation: evidence for intermediate elevated levels of intravascular thrombogenesis. *Am Heart J* 1996;131:724-30.
65. JORGENSEN HS, NAKAYAMA H, REITH J, RAASCHOU HO, OLSEN TS. Acute stroke with atrial fibrillation. *Stroke* 1996;10:1765-9.
66. FLEGEL KM, HANLEY J. Risk factors for stroke and other embolic events in patients with nonrheumatic atrial fibrillation. *Stroke* 1989;8:1000-3.
67. CHIMOWITZ MI, DeGEORGIA MA, POOLE RM, HEPNER A, ARMSTRONG WM. Left atrial spontaneous echo contrast is highly associated with previous stroke in patients with atrial fibrillation. *Stroke* 1993;24:1015-9.
68. BLACK IW, HOPKINS AP, LEE LCL, WALSH WF. Left spontaneous echo contrast: a clinical and echocardiographic analysis. *J Am Coll Cardiol* 1991;18:398-404.
69. MANNING W. Role of transesophageal echocardiography in the management of thromboembolic stroke. *Am J Cardiol* 1997;80:19-28.
70. Cerebral Embolism Task Force. Cardiogenic brain embolism: the second report of the Cerebral Embolism Task Force. *Arch Neurol* 1989;46:727-43.
71. FREDBERG RS, GOODKIN GM, PEREZ JL, TINICK PA, KRONZON I. Valve strands are strongly associated with systemic embolization: a transesophageal echocardiographic study. *J Am Coll Cardiol* 1995;26:1709-12.
72. ORENCIA AJ, PETTY GW, KHANDHERIA BK. Risk of stroke with mitral valve prolapse in population-based cohort study. *Stroke* 1985;26:7-13.
73. KONSTADT SN, LOUIE EK, BLACK S, RAO TLK, SCANLON P. Intraoperative detection of patent foramen ovale by transesophageal echocardiography. *Anesthesiology* 1991;74:212-6.
74. HAGEN PT, SCHOLZ DG, EDWARDS WD. Incidence and size of patent foramen ovale during first 10 decades of life: an autopsy study of 965 normal hearts. *Mayo Clin Proc* 1984;59:17-20.
75. LECHAT PH, MAS JL, LASCAULT G. Prevalence of patent foramen ovale in patients with stroke. *N Engl J Med* 1988;318:1148-52.
76. JEANRENAUD X, BOGOUSLAVSKY J, PAYOT M, REGLI F, KAPPENBERGER L. Patent foramen ovale and cerebral infarct in young patients. *Schweiz Med Wochenschr* 1990;120:823-9.
77. NEDELTCHEV K, ARNOLD M, WAHL A, STURZENEGGER M, VELLA EE, WINDECKER S, MEIER B, MATTLE HP. Outcome of patients with cryptogenic stroke and patent foramen ovale. *J Neurol Neurosurg Psychiatry* 2002;72:347-50.
78. ALBERT A, MULLER HR, HETZEL A. Optimized transcranial Doppler technique for the diagnosis of cardiac right-to-left shunts. *J Neuroimaging* 1997;7:159-63.
79. JAUSS M, ZANETTE E. Detection of right-to-left shunt with ultrasound contrast agent and transcranial Doppler sonography. *Cerebrovasc Dis* 2000;10:490-6.
80. MAS JL, ZUBER M. Recurrent cerebrovascular events in patients with patent foramen ovale, atrial septal aneurysm, or both and cryptogenic stroke or transient ischemic attack. French Study Group on patent foramen ovale and atrial septal aneurysm. *Am Heart J* 1995;130:1083-8.
81. STEINER M, DI TULLIO MR, RUNDEK T, GAN R, CHEN X, LIGUORI C, BRAININ M, HOMMA S, SACCO RL. Foramen ovale size and embolic brain imaging findings among patients with ischemic stroke. *Stroke* 1998;29:99-105.
82. SCHUCHLENZ HW, WEIHS W, HORNER S, QUEHENBERGER F. The association between the diameter of a patent foramen ovale and the risk of embolic cerebrovascular events. *Am J Med* 2000;109:456-62.
83. SERENA J, SEGURA T, PEREZ-AYUSO MJ, BASSAGANYAS J, MOLINA A, DAVALOS A. The need to quantify right-to-left shunt in acute ischemic stroke: a case-control study. *Stroke* 1998;29:1322-8.
84. KERUT EK, NORFLEET WT, PLOTNICK GD, GIKLES T. Patent foramen ovale: a review of associated conditions and the impact of physiological size. *Am J Coll Cardiol* 2001;38:613-23.
85. WILMHURST PT, BRYSON P. Relationship between the clinical features of neurological decompression illness and its causes. *Clin Sci* 2000;99:65-75.
86. SCHWERZMANN M, SEILER C. Recreational scuba diving, patent foramen ovale and their associated risks. *Swiss Med Wkly* 2001;131:365-74.
87. Cerebral Embolism Task Force. Cardiogenic brain embolism: the second report of the Cerebral Embolism Task Force. *Arch Neurol* 1989;46:727-43.
88. HINDMAN BJ. Emboli, inflammation, and CNS impairment: an overview. *Heart Surg Forum* 2002;5:249-53.
89. PUGSLEY WB, KLINGER L, PASCHALIS C, *et al.* Does arterial line filtration affect the bypass related cerebral impairment observed in patients undergoing coronary artery surgery? *Clin Sci* 1988;75(Suppl 19):30-1.
90. SULEK CA, DAVIES LK, ENNEKING FK, GEAREN PA, LOBATO EB. Cerebral microembolism diagnosed by transcranial Doppler during total knee arthroplasty: a correlation with transesophageal echocardiography. *Anesthesiology* 1999;91:672-6.
91. RODRIGUEZ RA, SINCLAIR B, WEATHERDON D, LETTS M. Patent foramen ovale and brain microembolization during scoliosis surgery in adolescents. *Spine* 2001;26:1719-21.
92. van ZUILEN EV, MOLL FL, VERMUELN FE, MAUSER HW, VAN GIJN J, ACKERSTAFF RG. Detection of cerebral microem-

- boli by means of transcranial Doppler monitoring before and after carotid endarterectomy. *Stroke* 1995;26:210-3.
93. SPENCER MP. Transcranial Doppler monitoring and causes of stroke from carotid endarterectomy. *Stroke* 1997;28:685-91.
  94. LENNARD N, SMITH J, DUMVILLE J, ABBOTT R, EVANS DH, LONDON NJM, BELL PRF, NAYLOR AR. Prevention of postoperative thrombotic stroke after carotid endarterectomy: the role of transcranial Doppler. *J Vasc Surg* 1997;26:579-84.
  95. HANKEY GJ, WARLOW CP, SELLAR RJ. Cerebral angiographic risk in mild cerebrovascular disease. *Stroke* 1990;21:209-22.
  96. KASTRUP A, GROSCHEL K, KRAPP H, BREHM BR, DICHI-GANS J, SCHULZ JB. Early outcome of carotid angioplasty and stenting with and without cerebral protection devices: a systematic review of the literature. *Stroke* 2003;34:813-9.
  97. MARCUS HS, BROWN MM. Differentiation between different pathological cerebral embolic materials using transcranial Doppler in an *in vitro* model. *Stroke* 1993;1:1-5.
  98. FIESCHI C, ARGENTINO C, LENZI GL, *et al.* Clinical and instrumental evaluation of patients with ischaemic stroke within the first six hours. *J Neurol Sci* 1987;91:311-22.
  99. GERRATY RP, BOWSER DN, INFELD B, *et al.* Microemboli during carotid angiography. Association with stroke risk factors or subsequent magnetic resonance imaging changes? *Stroke* 1996;9:1543-7.
  100. KUMRAL E, EYAPAN D, AKSU K, KESER G, KABASAKAL Y, BALKIR K. Microembolus detection in patients with Takayasu's arteritis. *Stroke* 2002;33:712-6.
  101. SITZER M, SOHNGEN D, SIEBLER M. Cerebral microembolism in patients with Sneddon's syndrome. *Arch Neurol* 1995;52:271-5.
  102. SPECKER C, RADEMACHER J, SOHNGEN D. Cerebral microemboli in patients with antiphospholipid syndrome. *Lupus* 1997;6:638-44.
  103. KUMRAL E, EYAPAN D, OKSEL E, KESER G, BEREKEROGLU MA, BALKIR K. Transcranial Doppler detection of microembolic signals in patients with Behcet's disease. *J Neurol* 1999;246:592-5.
  104. VUKOVIĆ V. Korelacija transkranijuskog doplera s kliničkim statusom i parametrima koagulacije u otkrivanju moždanih embolusa. MS thesis. Zagreb: School of Medicine, University of Zagreb, 2002.
  105. RESCH KL, ERNST E, AATRAIA, PAULSEN HF. Fibrinogen and viscosity as risk factors for subsequent cardiovascular events in stroke survivors. *Ann Intern Med* 1992;117:371-5.
  106. HEPPELL RM, BERKIN KKE, McLENACHAN JM, DVIES JA. Haematostatic and haemodynamic abnormalities associated with left atrial thrombosis in non-rheumatic atrial fibrillation. *Heart* 1997;77:407-11.
  107. VUKOVIĆ V, DEMARIN V, RUNDEK T, STARČEVIĆ B. Fibrinogen as a risk factor in patients with HITS. *Stroke* 1998;29(Suppl 1):2240.
  108. COULL BM, BEAMER N, de GARMO P, SEXTON G, NORDT F, KNOXR, SEAMAN GV. Chronic blood hyperviscosity in subjects with acute stroke, transient ischemic attack, and risk factors for stroke. *Stroke* 1991;22:162-8.
  109. DOUTREMEPUICH F, AGUEJOUF O, BELOUGNE-MALFATTI E, DOUTREMEPUICH C. Fibrinogen as a factor of thrombosis: experimental study. *Thromb Res* 1998;90:57-64.
  110. RINGELSTEIN EB, MARKUS HS, on behalf of the CARESS Investigators. The effect of dual antiplatelet therapy compared with aspirin on asymptomatic embolization in carotid stenosis: the CARESS trial. 5<sup>th</sup> World Stroke Congress, Vancouver B.C., Canada, June 23-26, 2004:189.
  111. GOERTLER M, BAEUMER M, KROSS R. Rapid decline of cerebral microemboli of arterial origin after intravenous acetylsalicylic acid. *Stroke* 1999;30:66-9.
  112. MARKUS HS, THOMSON ND, BROWN MM. Asymptomatic cerebral embolic signals in symptomatic and asymptomatic carotid artery disease. *Brain* 1995;118:1005-11.
  113. STREIFLER JY, KATZ M. Cardiogenic cerebral emboli: diagnosis and treatment. *Curr Opin Neurol* 1995;8:45-54.
  114. KAPOSZTA Z, MARTIN JF, MARKUS HS. Switching off embolization from symptomatic carotid plaque using S-nitroglutathione. *Circulation* 2002;105:1480-4.
  115. JUNGHANS U, SIEBLER M. Cerebral microembolism is blocked by tirofiban, a selective nonpeptide platelet glycoprotein Iib/IIIa receptor antagonist. *Circulation* 2003;107:2717-21.
  116. ALY A, BABIKIAN VL, BAREST G, ARTINIAN M, FORTEZA A, KASE CS. Brain microembolism. *J Neuroimaging* 2003;13:140-6.



## Sažetak

## OTKRIVANJE MIKROEMBOLUSA TRANSKRANIJSKOM DOPPLER SONOGRAFIJOM – TEHNIČKI I KLINIČKI ASPEKT

*V. Vuković, A. Lovrenčić-Huzjan i V. Demarin*

Pomoću transkranijskog doplera mogu se otkriti mikroembolijski signali koji su obilježeni pojavom jednosmjernih signala visokog intenziteta, kratkog su trajanja, pojavljuju se u vremenski nepravilnom slijedu, a zvuče “poput zvižduka”. Smatra se da mikroembolijski signali predstavljaju solidne čestice ili mjehuriće zraka koji putuju krvnom strujom. Mikroembolijski signali otkriveni su dosad kod bolesnika s karotidnom stenozom, plakom luka aorte, atrijskom fibrilacijom, infarktom miokarda, s umjetnim srčanim zaliscima, kod prohodnog foramena ovale, valvulne stenozе, za vrijeme invazivnih zahvata (angiografija, perkutana transluminalna angioplastika), za vrijeme operacija (karotidnih arterija, kardiopulmonalne prenosnice, ortopedske operacije) i kod nekih sistemskih bolesti. Usprkos brojnim istraživanjima kliničko značenje mikroembolijskih signala nije sasvim razjašnjeno. U ovom članku iznosi se pregled razvoja i najnovija tehnološka dostignuća, kao i klinički aspekti otkrivanja mikroembolusa.

Ključne riječi: