

WARTIME CRANIOBASAL INJURIES IN SOUTHERN CROATIA

Mario Tudor¹, Lorainne Tudor² and Katarina Ivana Tudor²

¹University Department of Neurosurgery, Split University Hospital; ²School of Medicine, University of Split, Split, Croatia

SUMMARY – During the war in Croatia (1991-1995), 26 patients with craniobasal (facio-orbital) injuries were treated in southern Croatia. Numerous complications that accompany these lesions give them specific neurosurgical importance. Patient records were retrospectively analyzed in order to assess outcome in this group of patients. Cerebrospinal fluid fistula was observed in one third of the patients. Cerebrospinal fluid fistula based infection occurred in over 50% of cases. Endocranially located retained foreign bodies were seen in 10 patients. A higher rate of reoperation (mostly for cerebrospinal fluid fistula) was recorded in this group of patients as compared with other sites of head injuries. Favorable outcome was recorded in 18 and unfavorable outcome in 8 patients, whereas 3 patients died. This survey of patient records showed it to be of utmost importance to follow the well defined neurosurgical policy according to which the primary wound repair (especially of the torn basal dura mater) should be a definitive one. Cerebrospinal fluid fistula, retained foreign bodies, low Glasgow Coma Scale on admission, and reoperation exert an unfavorable effect on patient outcome.

Key words: *Brain injuries – epidemiology; Craniobasal trauma – complications; War; Wounds, penetrating – complications; Croatia*

Introduction

Cranio-cerebral injury, either primary or secondary, is often fatal. These injuries account for 10%-15% of all war injuries and are the most common cause of death at the battlefield^{1,2}. Head injuries in war are in their appearance massive, and often very destructive for all neurocranial layers, involving a broad population^{3,4}. According to the angle of impact upon cranial structures they can be of penetrating, perforating, and tangential type^{3,4}. A special group of open war injuries to the head are those called craniobasal injuries (facio-orbito-cranio-basal injuries). In this type of injuries, the projectile intruding the skull or leaving it after causing the lesion traverses paranasal cavities and/or eye-hole, providing a broad communication between the contaminated outer world and the sterile endocranial content^{5,6}. Even when direct brain lesions caused by the projectile intracranial pro-

gression are excluded, the complications such as cerebrospinal fluid fistula (CSFF) and ascending meningitis that accompany craniobasal lesions make them highly significant. Although known as a phenomenon since ancient times, post-traumatic CSFF was first described in 1770 by Bidloo. W. Dandy accomplished the first neurosurgical CSFF repair of a frontobasal injury using a fascia lata graft and muscle. Attention should be paid to the so-called discontinuous fracture where the fracture of the calvaria at the site of projectile entry is not connected with the one at the skull base⁶.

In the series presented by Campbell and Kuhlenbeck, the incidence of these lesions exceeded 35%⁷. After resuscitation measures, all patients underwent neurologic and radiologic diagnostic workup.

Computed tomography (CT) coronal and axial thin slices performed through eye holes and neurocranium, also using 'bony' window, enabled optimal selection of neurosurgical strategy, including head and neck surgeon and ophthalmologist consultation. The neurosurgical treatment consisted of large craniotomy, gentle but thorough debridement, removal of all reachable indriven foreign bodies, watertight dural closure using a graft, and skin closure without tension^{3,4}. Simple wound closure was performed in those patients show-

Correspondence to: *Mario Tudor, MD, MS*, Department of Neurosurgery, Split University Hospital, Vjekoslava Spinčića 1, HR-21000 Split, Croatia

Received February 10, 2004, accepted in revised form December 5, 2004

E-mail: mario.tudor1@st.htnet.hr

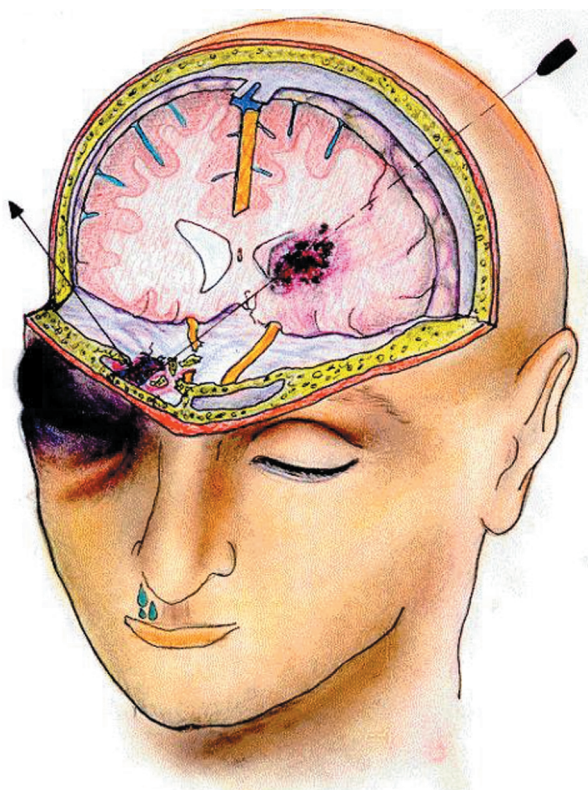


Fig. 1. Discontinuous fracture (according to Johnson and Dutt, 1947)⁶.

ing no space occupying lesions (excluded by CT scan), those who were admitted to the hospital in a time period shorter than 6 hours from the wounding, those who had a wound diameter of less than 2 cm, and those with Glasgow Coma Scale (GCS) greater than 10 points⁸. Tetanus prophylaxis

and penicillin crystal (6x4 MIU/d), gentamicin (3x80 mg/d) and metronidazole (3x500 mg/d) were routinely administered to all patients. All patients received sodium phenobarbital (2x100 mg) for prevention of seizures⁸⁻¹⁰.

Patients and Methods

From August 1991 till October 1995, a total of 176 patients with craniocerebral injuries sustained in war were treated at Department of Neurosurgery, Split University Hospital⁹. There were 26 (14.8%) patients with craniobasal war injury (Table 1).

There were 24 men and two women, mean age 30 years. In the great majority of patients, the time elapsed from wound infliction (transport time) to hospital admission was less than 48 hours, and in only two patients more than 48 hours. The wounding agents were shell fragments in two thirds and bullets in one third of patients. The initial neurologic status (GCS score)¹¹ was unfavorable (≤ 7) in 14 and favorable (> 7) in 11 patients. One patient was sedated and under the influence of a relaxant. There were different direct effects of the projectile intrusion into the endocranium (CT and skull x-rays): 5 aerocoele, 12 intracerebral hematomas (ICH), 1 epidural hematoma, 1 intraventricular hemorrhage, and 1 encephalocele into the sphenoid sinus. In all patients a comminuted fracture of the skull base was present.

More than a half of patients were treated through large craniotomy and one third by simple wound closure, whereas three patients were operated on elsewhere.

On outcome assessment, the Glasgow Outcome Scale (GOS)¹² was intentionally modified to enable easier evaluation. Death, vegetative state, and severe disability were

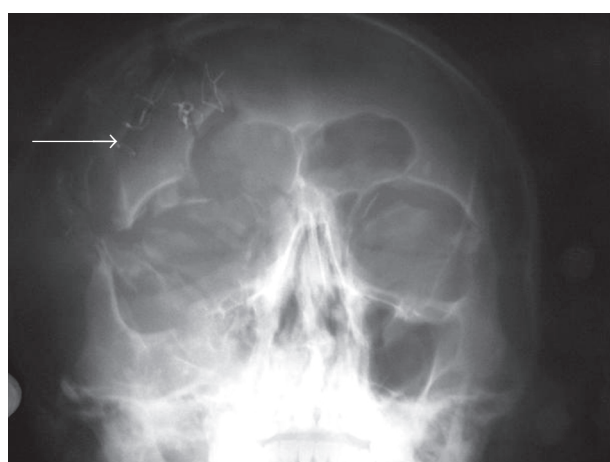


Fig. 2. Numerous superficially and endocranially located shell fragments.

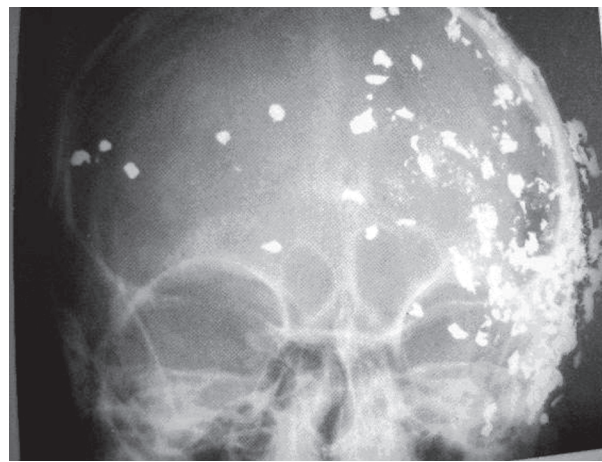


Fig. 3. Frontobasal multifragmented fracture involving orbital hole.

Table 1. Craniobasal injuries in major armed conflicts

| Armed conflict/Author | % of craniobasal injuries |
|----------------------------------------|---------------------------|
| World War II (1939-1945), H.W. Cushing | 3.0 |
| Korean war (1950-1953), A.M. Meirowsky | 3.9 |
| Vietnam war (1965-1973), Hammon/Rish | 1.5 |
| Israel war (1982-1985), B. Brandvold | 13.2 |
| Croatia war (1991-1995), M. Tudor | 14.8 |

classified as unfavorable outcome, whereas favorable outcome included moderate disability and good recovery^{9,13}.

The Kruskal-Wallis χ^2 -test, Mann-Whitney U test, Fisher exact test and χ^2 distribution test were used on statistical analysis.

Results

Three deaths were recorded in the group of patients with craniobasal injuries. The mortality rate slightly exceeded total mortality rate (10.23%, N=176). All patients with lethal outcome had unfavorable GCS (≤ 7 points) on admission. These patients died 3-4 days from the wounding, i.e. from primary neurosurgical management, so death was caused by the primary, irreversible, extensive cerebral lesion rather than by the complications commonly observed in this anatomic region.

Early complications developed in one third of patients: CSFF in seven (Fig. 4) and infection (meningoencephali-

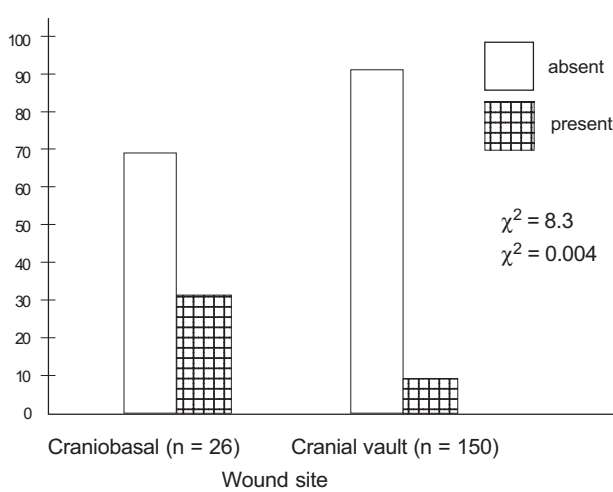


Fig. 4. Relationship between cerebrospinal fluid fistula (CSFF) and wound site.

tis) in five patients (including four of the five patients with CSFF). Bacteriologic analysis of CSF from the infected patients showed an equal distribution of gram-positive and gram-negative infectious agents, with a predominance of *Staphylococcus aureus* and *Acinetobacter* sp. It should be noted that the initial infection with gram-positive bacteria was later substituted by gram-negative bacteria. All patients initially received the same antibiotic prophylaxis, which was subsequently specifically changed according to the antibiotic sensitivity report. Two patients developed early seizures.

On postoperative control CT scans, 12 patients were free from retained foreign bodies endocranially, whereas in ten patients foreign bodies had not been (or could not be) properly removed. Only two infections were recorded in the group of patients free from retained foreign bodies on control CT, whereas in ten patients with the evidence of retained foreign bodies there were 4 cases of meningoencephalitis, 5 cases of CSFF, and one patient with early seizures.

The size of the projectile endocranial trajectory had no statistical significance on the outcome, as favorable outcome was recorded in seven of nine patients with the bullet trajectory through both cerebral hemispheres. Only two of seven patients with two or more cerebral lobi involved had unfavorable outcome.

The transport time had no effect on the incidence of infectious complications because all patients were admitted to the hospital and underwent neurosurgical management within the time period shorter than the critical 48 hours.

In the group of patients operated on by large craniotomy there was only one reoperation, whereas in the group with the simple wound closure and/or operation there were three reoperations. All patients reoperated on (n=4) had a CSFF (with or without infection).

According to the simplified GOS, there were eight (30%) patients with unfavorable outcome and 18 (70%) patients with favorable outcome.

Discussion

Mortality rate in recent large armed conflicts is still high (10%) despite advances in neurosurgical techniques, well organized health service, and properly trained personnel. In the group of patients with craniobasal lesions it is slightly higher (11.5%) because of the specific anatomic region (border between the neurocranium and viscerocranium) and common use of high velocity missiles. In the management of craniocerebral war injuries, the primary neurosurgical goal is to reduce intracranial pressure (decompressive craniecto-

my, evacuation of all spaciocompressive endocranial hematomas), to provide optimal perfusion of the brain tissue, to remove all reachable foreign endocranial materials (especially bone fragments), to perform thorough debridement, to close dura mater in a watertight fashion, and to ensure that skin exerts no tension over cranial defects^{2-4,9}. The same holds for craniobasal defects and torn basal dura mater. The defects should be repaired optimally in order to prevent CSFF either through the skin at the wounding site or CSF rhinorrhea or CSF otorrhea (discontinuous fracture)^{5,6,14,15}. The incidence of CSFF in the war was as high as 18%, and in our patients (N=176) it was 12%^{9,13}. In this special group of patients (craniobasal injuries) it is 27%. CSFF provides a basis for different infectious complications, their incidence being as high as 50%¹⁵⁻¹⁷. In the presence of CSFF, the rate of infection is 15-fold that without CSFF.

In wartime, it may often be difficult to perform a distinguished radiologic workup (e.g., CT cisternography with coronal slices) and to locate the site of cranial base defects, or to define the site of dura perforation, although generally, the defects are commonly larger than those from peacetime accidents. In cases with very extensive wounds (defects) it may occasionally be difficult to act according to the aforementioned principles of management for these lesions. Without a multispecialty approach (that may even include a plastic surgeon) by a neurosurgeon, an ophthalmologist, and a head and neck surgeon, it is not easy to close the defects in these rare cases. The reoperation rate is higher than for war wounds located elsewhere (cranial vault). It is well known that reoperations contribute significantly to poorer outcomes.

In our series, the reason for reintervention was CSFF and/or infection in the majority of cases. Therefore, therapeutic goal is that the primary wound repair (especially of the craniobasally torn dura mater) be a definitive one, followed by aggressive intensive therapy and early rehabilitation. The type of projectile, the type of war wound, the transport time, the size of the projectile endocranial trajectory, and the patient's age and sex had no significant impact on the outcome, whereas primary brain lesion (initial GCS), CSFF, retained endocranial foreign bodies, infections and reoperations had a major impact on the outcome.

References

1. AARABI B. Causes of infections in penetrating head wounds in the Iran-Iraq war. *Neurosurgery* 1989;25:923-6.
2. COOPER PR, ed. Gunshot wounds of the brain in head injury. Baltimore: Williams and Wilkins, 1982:257-74.
3. IVEKOVIĆ V, JELIČIĆ I. Opći principi liječenja ratnih kranio-cerebralnih ozljeda. *Acta Med Croat* 1992;46 (Suppl):13-7.
4. JELIČIĆ I. O ratnim kranio-cerebralnim ozljedama. *Acta Med Croat* 1992;46 (Suppl):7-11.
5. DILLON JD Jr, MEIROWSKY AM. Facio-orbito cranial missile wounds. *Surg Neurol* 1975;4:515-8.
6. JOHNSON RT, DUTT P. On dural laceration over paranasal and petrous air sinuses. *Br J Surg* 1947; War Surg Suppl 1:141-67.
7. CAMPBELL EH, KUHLENBECK H. Mortal brain wounds: a pathologic study. *J Neuropathol Exp Neurol* 1950;9:139-49.
8. TAHA JM, SABA MI, BROWN JA. Missile injuries to the brain treated by simple wound closure: results of protocol during the Lebanese conflict. *Neurosurgery* 1991;29:380-3.
9. TUDOR M. Craniocerebral injuries in war. MS thesis. Zagreb: University of Zagreb, 1996:130.
10. YOUNG B, RAPP RP, NORTON JA, *et al.* Failure of prophylactically administered phenytoin to prevent early posttraumatic seizures. *J Neurosurg* 1983;58:231-5.
11. TEASDALE G, JENNETT B. Assessment of coma and impaired consciousness. A practical scale. *Lancet* 1974;2:81-3.
12. JENNETT B, BOND M. Assessment of outcome after severe brain damage. A practical scale. *Lancet* 1975;1:480-4.
13. TUDOR M. Prediction of outcome in patients with missile craniocerebral injuries during the Croatian war. *Mil Med* 1998;163:486-8.
14. CALVERT CA. Orbito-facio-cranial gunshot wounds. *Br J Surg* 1947; War Surg Suppl 1:119-29.
15. MEIROWSKY AM, CAVENESS W, DILLON J, *et al.* Cerebrospinal fluid fistulas complicating missile wounds of the brain. *J Neurosurg* 1981;54:44-8.
16. SEKULIĆ A, HOTUJAC-ŠVERKO M, BRNOBIĆ M, *et al.* Post-traumatske infekcije. *Acta Med Croat* 1992;46 (Suppl):47-8.
17. WANNAMAKER GT, PULASKI EJ. Pyogenic neurosurgical infections in Korean battle casualties. *J Neurosurg* 1958;15:512-8.

Sažetak

RATNE KRANIOBAZALNE OZLJEDE U JUŽNOJ HRVATSKOJ

M. Tudor, L. Tudor i K.I. Tudor

Tijekom rata u Hrvatskoj (1991.-1995.) u južnoj Hrvatskoj liječeno je 26 bolesnika s kraniobazalnim (facio-orbitalnim) ozljedama. Brojne komplikacije koje prate ove ozljede čine ih osobito značajnim za neurokirurgiju. Provedena je retrospektivna analiza bolesničkih kartona kako bi se procijenio ishod u ovoj skupini bolesnika. Likvorska fistula zabilježena je u jedne trećine bolesnika. Infekcija proizišla iz takve fistule nastupila je u preko 50% slučajeva. Zaostala strana tijela u endokranijumu nađena su u 10 bolesnika. U ovoj skupini bolesnika zabilježena je viša stopa ponovnih operacijskih zahvata (uglavnom zbog likvorske fistule) u usporedbi s drugim mjestima ozljeda glave. Povoljan ishod zabilježen je u 18, a nepovoljan ishod u 8 bolesnika, dok su trojica umrla. Zaključuje se kako je od vrhunske važnosti slijediti dobro utvrđen neurokirurški protokol prema kojemu primarno zbrinjavanje rane (poglavito pokidane bazalne dure mater) mora biti konačno. Likvorska fistula, zaostala strana tijela, niska vrijednost na Glasgowskoj ljestvici kome kod prijma te ponovna operacija nepovoljno utječu na ishod.

Ključne riječi: *Ozljede glave – epidemiologija; Kraniobazalna trauma – komplikacije; Rat; Rane, penetrirajuće – komplikacije; Hrvatska*