

## BRENNER TUMOR OF THE OVARY

Hrvojka Soljačić-Vraneš<sup>1</sup>, Petar Klarić<sup>1</sup>, Lada Bolf-Benković<sup>1</sup> and Ahmed Pirkić<sup>2</sup>

<sup>1</sup>University Department of Gynecology, <sup>2</sup>Ljudevit Jurak Clinical Department of Pathology, Sestre milosrdnice University Hospital, Zagreb, Croatia

**SUMMARY** – Brenner tumor of the ovary is very rare, mostly benign, small, and unilateral. It mostly occurs in elderly women and produces no symptoms. In the last ten years (1994-2004), seven women were operatively treated at Sestre milosrdnice University Hospital in Zagreb for Brenner tumor. Six patients were treated for this type of tumor, whereas in one patient Brenner tumor was an accidental finding. The former six patients underwent preoperative ultrasonography and Ca 125 determination. The patient age ranged from 41 to 72 years. In six cases, the tumor was unilateral. One patient had a mucinous proliferating cystadenoma in the same ovary affected with benign Brenner tumor. The size of tumors varied from 0.5 to 20 cm in diameter.

**Key words:** *Ovarian neoplasms – diagnosis; Ovarian neoplasms – pathology; Brenner tumors – diagnosis; Brenner tumors – pathology; Ovary – ultrasonography*

### Introduction

Brenner tumor is a fibroepithelial tumor composed of transitional cell epithelial nests, similar to bladder epithelium<sup>1</sup>. It does not originate from ovarian surface epithelium. Tumor cells originate from islets of congenital epithelium that have reached ovarian stroma in an unknown way, however, they have also been postulated to originate from rete ovary<sup>2</sup>. Tumor firmness depends on the amount of connective tissue. These tumors are usually small, solid, firm, greyish knots, up to 2 cm in size, however, they may also be quite big, and in such cases usually with cystic components as the result of cystic degeneration and necrosis. In 95% of cases, they are unilateral. Tumors are generally symptom-free and occur in the elderly. Malignant cases are extremely rare (roughly two percent of all cases)<sup>2</sup>, and so are proliferative Brenner tumors. In malignant cases the growth is fast, with ascites.

Correspondence to: *Hrvojka Soljačić-Vraneš, M.D.*, University Department of Gynecology, Sestre milosrdnice University Hospital, Vinogradska c. 29, HR-10000 Zagreb, Croatia  
E-mail: zoran.vranes@zg.htnet.hr

Received April 20, 2005, accepted in revised form July 18, 2005

### Patients and Methods

During a ten-year period (1994-2004), seven patients with Brenner tumor were operatively treated at Sestre milosrdnice University Hospital in Zagreb. The patients were aged 41 to 72, one of them 41 and six over 52. The patients underwent ultrasonography and determination of Ca 125 tumor marker. Six women were operated on for ovarian neoplasm, whereas in one patient Brenner tumor was accidentally detected on hysterectomy for myoma.

### Results

Four patients were free from tumor symptoms, and tumor was detected on routine gynecologic ultrasonography (Fig. 1). All four patients underwent control gynecologic examinations for up to two years, including Ca 125 tumor marker testing (which were normal in all cases, ranging from 4.3 to 23.3 U/ml). In the last seven years, tumor vascularity was explored by resistance index (RI), which was greater than 0.42 in all cases, predicting a benign disease. Modified ultrasound score was determined in the last four years. Modified ultrasound score (modification of ultrasound score as described by Ku-

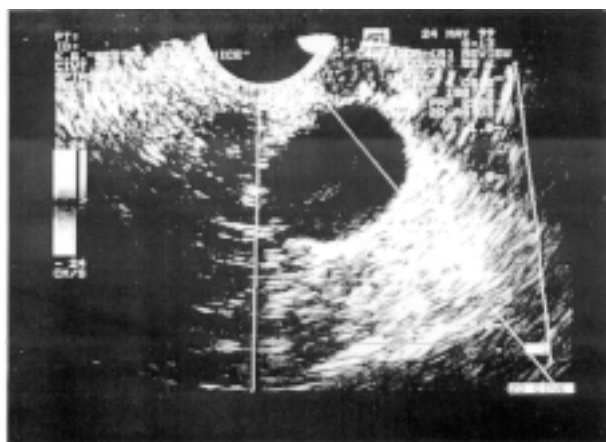


Fig. 1. Brenner tumor: sonographic scan in a study patient.

pešić *et al.*<sup>3</sup>) includes the following: the appearance of tumor margins, intratumoral shades, partitions, solid components, tumor vascularization and echogenicity, and presence of peritoneal fluid. All these parameters are scored, and the sum of all scores predicts benign or malignant nature of the tumor. Our patients showed a “benign ultrasound score”. Tumor persistence indicated operation in all study patients. Laparoscopic adnexectomy was performed in one patient, hysterectomy and bilateral adnexectomy in two patients, and bilateral adnexectomy in one patient who had previously undergone hysterectomy. Histopathologic analysis showed benign Brenner tumors composed of both epithelial nests and

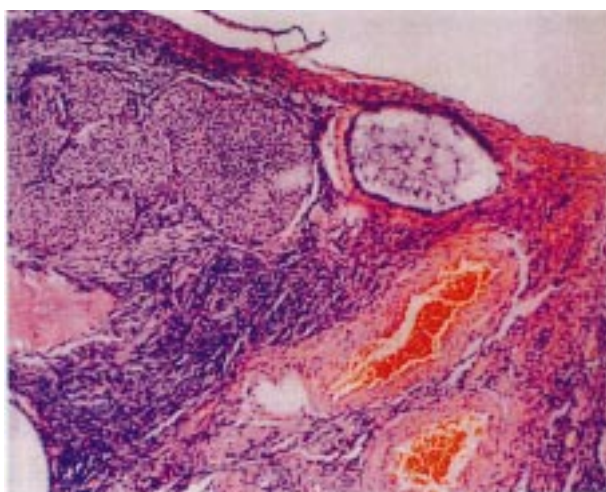


Fig. 2. Brenner tumor: histopathologic finding in a study patient showing round to oval clusters of stratified epithelial cells of transitional type, without the evidence of atypical nuclei dispersed in solid collagen stroma. (HE X100)

fibrous stromas in all four patients as well as in the patient in whom Brenner tumor was an accidental finding. Clusters of round to oval stratified epithelial cells of transitional type, without evidence for nuclear atypia, were dispersed in solid collagen stroma (Fig. 2). Tumor diameter was up to 1.5 cm, and it was bilateral in only one case.

The remaining two patients presented with abdominal swelling, suspect of malignant disease. In one case (age 52, with uterus extirpated two years before) abdominal swelling persisted for two months with pressure sensations in the upper abdomen and breathing difficulties. Ca 125 was within the reference values. Upon preoperative examinations, the patient underwent the operation that revealed a cystic formation of 24x18x3cm, which filled up abdominal cavity. The growth was partially fixed in Douglas space, multilocular, with many cavities that differed in size and were filled up with mucinous contents. The surface of cysts was smooth, with some solid parts at the base. Histopathologic analysis showed a tumor composed of two components that were closely connected: a benign Brenner tumor and a mucinous proliferating cystadenoma. The other patient with swelling of the abdomen (age 72) had noticed swelling for a year before she underwent gynecologic and ultrasound examination. Ultrasound showed a growth of 18x10 cm in size, with solid elements and hypoechogenic field up to 4.3x2.5 cm. The operation showed the left ovary to have transformed into a tumor mass of 15 cm in diameter, which was trilobular, with mucinous filling, smooth surface and containing a solid mass at the base, 2-3 cm in diameter. Histopathologic analysis indicated Brenner tumor.

## Discussion

Brenner tumor is very rare<sup>1</sup>. The most common site is ovary, however, it has also been described in other organs such as testis and epididymis<sup>4</sup>. It is mostly benign. Over a ten-year period, 1373 women were operated on at Sestre milosrdnice University Hospital for adnexal tumors (benign, proliferative, malignant, cysts). Brenner tumor was present in only seven (0.51%) cases, all benign. In one case the tumor had two components, Brenner tumor (benign) and papillary mucinous cystadenoma. Such cases have already been described in the literature<sup>5-7</sup>. In this and one more case, the tumor was large, cystic, and multilocular. Hoffman *et al.*<sup>8</sup> have also shown that large Brenner tumors are usually multilocu-

lar and cystic. Small tumors are composed of epithelial nests and fibrous stroma<sup>1</sup>, which was observed in five women with small tumors. Brenner tumors observed in our study mostly occurred in older women, which is consistent with literature data<sup>6,9</sup>. In most cases it is unilateral, however, it may also be bilateral<sup>5,9</sup>.

## References

1. DAMJANOVI. Ovarij (jajnik). In: JUKIĆ S, *et al.* Patologija ženskog spolnog sustava. 3<sup>rd</sup> ed. Zagreb: AGM, 1999;155-224.
2. GREGUREVIĆ M, PAVLIĆ Z, GRIZELJ V. Ginekologija. Zagreb: Jumena, 1987.
3. KUPEŠIĆ S, BJELOŠ D, KURJAKA. Trodimenzionalna doplerska angiografija unapređuje dijagnostiku tumora jajnika. (Three-dimensional ultrasound and power doppler improve the diagnosis of ovarian tumors). Gynaecol Perinatol 2000;9:99-103.
4. CACCAMO D, SOCIAS M, TRUCHET C. Malignant Brenner tumor of the testis and epididymis. Arch Pathol Lab Med 1991;115: 524-7.
5. WAXMAN M. Pure and mixed Brenner tumors of the ovary: clinicopathologic and histogenetic observations. Cancer 1979;43: 1830-9.
6. MOON WJ, KOH BH, KIM SK, KIM YS, RHIM HC, CHO OK, HAHM CK, BYUN JY, CHO KS, KIM SH. Brenner tumor of the ovary: CT and MR findings. J Comput Assist Tomogr 2000;24:72-6.
7. PEJOVIĆ T, BURKI N, ODUNSI K, FIEDLER P, ACHONG N, SCHWARTZ PE, WARD DC. Well-differentiated mucinous carcinoma of the ovary and coexisting Brenner tumor both exhibit amplification of 12q14-21 by comparative genomic hybridization. Gynecol Oncol 1999;74:134-7.
8. HOFFMAN M, RUFFOLO EH, HARRIS W. Giant Brenner tumor. Case report. J Fla Med Assoc 1989;76:772-3.
9. CONFORTI S, Di SERIO C, DONOFRIO V, MASTRANTONIO P. Bilateral Brenner tumor. Eur J Gynaecol Oncol 1989;10: 438-41.

## Sažetak

### BRENNEROV TUMOR JAJNIKA

*H. Soljačić-Vraneš, P. Klarić, L. Bolf-Benković i A. Pirkić*

Brennerov tumor jajnika je vrlo rijedak, uglavnom benignan, većinom malen, najčešće jednostran. Obično se javlja u starijih osoba i ne izaziva nikakve smetnje. U posljednjih 10 godina (1994.-2004.) u Kliničkoj bolnici "Sestre milosrdnice" operirano je sedam bolesnica s Brennerovim tumorom. Šest ih je operirano zbog tumora jajnika, dok je kod jedne bolesnice Brennerov tumor otkriven kao slučajni histopatološki nalaz. Kod šest bolesnica koje su operirane zbog tumora jajnika prijeoperacijski je učinjena ultrasonografija i pretraga na biljeg Ca 125. Žene su bile u dobi od 41 do 72 godine. U šest bolesnica je tumor bio jednostran. Kod jedne žene nađen je mucinozni proliferirajući cistadenom u istom ovariju s benignim Brennerovim tumorom. Tumori su bili promjera od 0,5 do 20 cm.

Ključne riječi: *Neoplazme jajnika – dijagnostika; Neoplazme jajnika – patologija; Brennerovi tumori – dijagnostika; Brennerovi tumori – patologija; Jajnik – ultrasonografija*