

A RARE CASE OF SQUAMOUS CELL CARCINOMA IN URINARY BLADDER DIVERTICULUM SUCCESSFULLY TREATED BY BLADDER-SPARING SURGERY

Goran Štimac¹, Matej Knežević², Igor Grubišić¹, Soip Soipi¹, Davor Tomas³ and Božo Krušlin^{3,4}

¹Clinical Department of Urology, Sestre milosrdnice University Hospital Center, Zagreb; ²Department of Urology, Dr. Josip Benčević General Hospital, Slavonski Brod; ³Ljudevit Jurak Clinical Department of Pathology, Sestre milosrdnice University Hospital Center; ⁴School of Medicine, University of Zagreb, Zagreb, Croatia

SUMMARY – The aim is to report a rare case of squamous cell carcinoma arising in a urinary bladder diverticulum and present recent literature overview of treatment options. A 56-year-old man presented with intermittent hematuria. Ultrasound examination indicated primary carcinoma in the urinary bladder diverticulum. Diagnosis was confirmed with cystoscopy and computed tomography. Transvesical diverticulectomy with regional lymphadenectomy was undertaken. Two years after initial treatment, the patient was well without evidence of tumor relapse. This report implicates that although aggressive surgical approach is recommended in the majority of bladder diverticulum tumors, simple diverticulectomy may be indicated in selected, confined cases.

Key words: *Carcinoma, squamous cell; Urinary bladder neoplasms; Diverticulum – pathology; Diverticulum – surgery; Case reports*

Introduction

Tumors arising within urinary bladder diverticula are rare. Pathophysiological explanation of carcinogenic transformation is based on urinary stasis within poorly contractile diverticula and chronic inflammation. Additionally, bladder diverticulum neoplasms have a poorer prognosis than tumors arising within the urinary bladder lumen¹. Early transmural infiltration through a thinned diverticular wall is considered as a main causal factor. Most of the intradiverticular neoplasms are urothelial, with rare incidence of adenocarcinomas, squamous cell carcinomas and sarcomas². A carcinoma within a urinary bladder diverticulum represents a therapeutic challenge regarding poor prognosis and lack of clear and sufficiently supported therapeutic guidelines. This article presents recent and

concise literature overview on treatment options, and illustrates an extremely rare case of a patient with primary intradiverticular squamous cell carcinoma successfully treated by a non-radical surgical approach.

Clinical Presentation and Intervention

A 56-year-old man presented with intermittent hematuria. Ultrasound examination indicated urinary bladder diverticulum. Cystoscopy revealed large diverticulum on the right wall of the urinary bladder with the tumor protruding into the bladder lumen. Urine cytology showed atypia and dyskaryosis. Intravenous urography verified bladder diverticulum with narrow neck on the right bladder wall measuring 5x6 cm with intraluminal filling defect (Fig. 1A). Computed tomography (CT) confirmed diverticulum with proliferative broad base lesion measuring 4x2 cm, which was related to the lateral wall of the diverticulum (Fig. 1B). The surrounding adipose tissue was blurred, and pelvic lymph nodes were not enlarged. Transvesical diverticulectomy and regional lymphadenectomy

Correspondence to: Goran Štimac, MD, PhD, Clinical Department of Urology, Sestre milosrdnice University Hospital Center, Vinogradska c. 29, HR-10000 Zagreb, Croatia
E-mail: goran.stimac2@zg.t-com.hr

Received September 23, 2014, accepted November 24, 2014

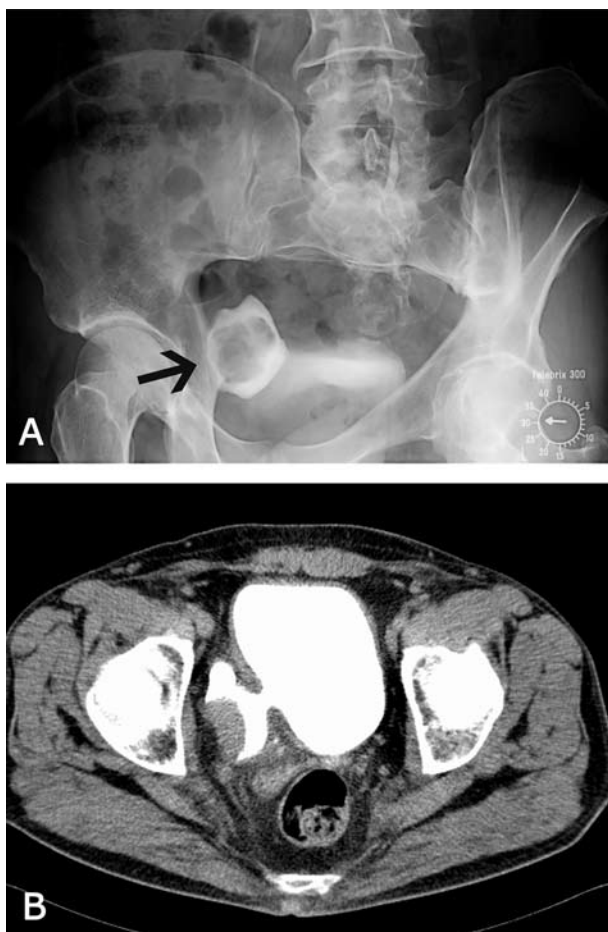


Fig. 1. Radiographic findings: (A) intravenous urography showed bladder diverticulum on the right bladder wall measuring 5x6 cm with intraluminal filling defect; (B) abdominal computed tomography revealed a proliferative broad base tumor measuring 4x2 cm, which was related to the lateral wall of the narrow neck diverticula.

were performed. The specimen was sent to pathology. On gross examination, a whitish tumor with papillary surface was found within the diverticulum (Fig. 2A). The tumor measured up to 3.5 cm in diameter and extended through all layers of the diverticular wall with penetration into the surrounding adipose tissue. Histopathology showed a tumor composed of well-differentiated squamous cells with larger foci of cornification (Fig. 2B). Part of the diverticular lumen surface was composed of metaplastic squamous epithelium. The tumor involved the entire thickness of the diverticular wall with penetration into the peridi-

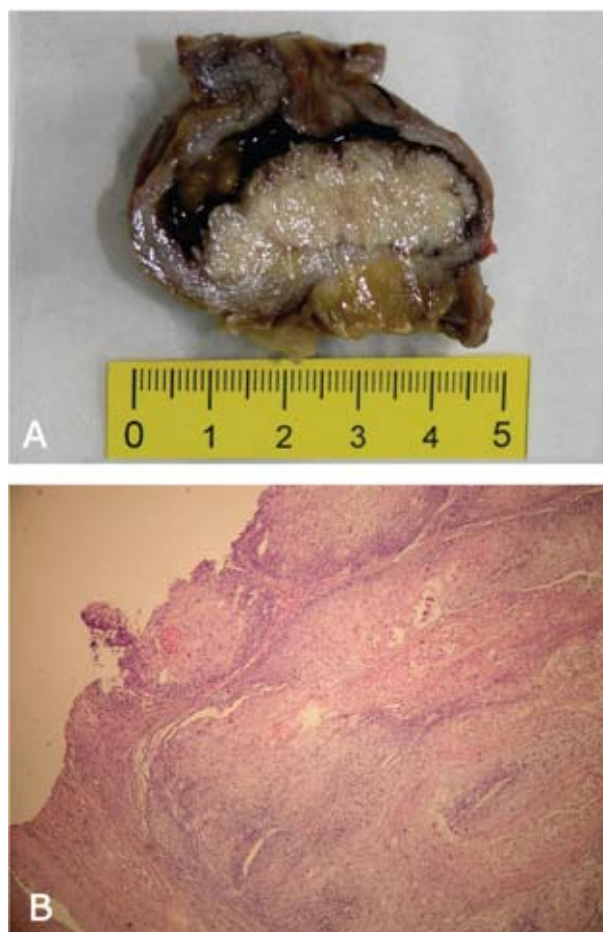


Fig. 2. Macroscopic and histologic findings: (A) gross specimen of bladder diverticulum containing a whitish tumor with papillary surface measuring up to 3.5 cm and penetrating into the surrounding adipose tissue; (B) the tumor was composed of well-differentiated squamous cells with larger foci of cornification. (HE, X100)

verticular adipose tissue. Surgical resection margins were tumor-free. The finding described corresponded to squamous cell carcinoma of the bladder diverticulum (T2bNxMxG2). Three months postoperatively, the patient had no symptoms. Follow up CT showed no signs of primary tumor. The patient was periodically followed up with complete examination and imaging. Two years after initial treatment, the patient was still well without urinary symptoms and evidence of tumor relapse.

Discussion

Urinary bladder diverticula are mostly acquired defects in the weakened muscular areas of the bladder wall. Increased intravesical pressure in patients with bladder neck obstruction or neurogenic bladder is the underlying cause. Patients with urinary bladder diverticula have 2%-7% chance of developing diverticular tumor³. Urinary stasis within poorly contractile diverticula, chronic inflammation and prolonged exposure to urinary carcinogens are predisposing factors for malignant transformation of diverticular urothelium⁴. Accordingly, most of the diverticular tumors are urothelial carcinomas, with rare occurrence of adenocarcinomas, squamous cell carcinomas and sarcomas. Painless hematuria is a major symptom and the diagnosis is confirmed with ultrasound, cystoscopic examination and radiologic imaging (intravenous urography and CT). Urine cytology is also helpful in the initial diagnosis and follow up of tumor recurrence.

A carcinoma within a bladder diverticulum is a therapeutic challenge and the value of treatment options has been discussed in the literature. There are still no firm recommendations for treatment of bladder diverticular tumors due to their occasional and rare appearance. Most of the studies available present small series of cases, with no prospective trials. The most common subject of discussion is the aggressiveness and the extent of surgical treatment. Neuzillet *et al.*⁵ conducted a literature overview and noticed a more frequent incidence of higher stage intradiverticular tumors than classical bladder tumors at the time of diagnosis with worse prognosis. They propose limitation of conservative treatment, considering a risk of underestimation of the extent and multifocality of the tumor. Transurethral resection alone has been suggested for low grade Ta-T1 tumors or followed by BCG therapy in cases of associated carcinoma *in situ*. Diverticulectomy associated with pelvic lymphadenectomy has been proposed for unifocal high-grade tumors. High-grade multiple tumors or associated with carcinoma *in situ* warrant total cystectomy. Golijan *et al.*⁶ describe the outcomes of 39 patients treated for bladder diverticulum tumor. They performed initial transurethral resection in all patients with sequential classification of tumors as superficial (Ta, Tis), superficially invasive intradiverticular (T1) or extradiverticular (T3+). Superficial or superficially

invasive cases were treated either conservatively with repeat transurethral resection, or with partial or radical cystectomy. Patients with extradiverticular extension were treated with partial or radical cystectomy. They report on a mean 5-year disease specific survival of 72% and support a conclusion on a more conservative approach for tumors confined to bladder diverticulum. In their study including a series of 32 patients, Sallami *et al.*⁷ found radical cystectomy to be the gold standard for invasive tumors. Endoscopic resection combined with intravesical immunotherapy should be reserved for superficial tumors (Ta, T1). In some cases, surgery alone, including radical resection, partial cystectomy or transurethral resection is not adequate. Complementary chemotherapy and radiotherapy are therefore optional, depending on the pathologic finding, considering the overall poorer prognosis of diverticular tumors than bladder tumors⁸.

As shown, the treatment of bladder diverticulum tumors varies in extent and is often dependent on the specific evaluation of each individual case. There is also no uniform specific grading system for diverticular tumors⁴. It is emphasized that superficial invasive carcinomas represent a dilemma in terms of aggressiveness and that the position of simple diverticulectomy is still questionable. In our case, we decided to conduct a less aggressive approach with a bladder-sparing procedure. Diverticulectomy was performed despite the superficially invasive squamous cell carcinoma, with consecutive intensive monitoring, which proved to be successful.

Conclusion

This report presents a case of a patient with a rare squamous cell diverticular carcinoma who underwent bladder-sparing surgical treatment based on diagnostic evaluation. Histopathology revealed extradiverticular spread of the tumor with clear surgical margins. Despite the non-radical approach, the patient was treated successfully and remained free from recurrence two years after surgery.

References

1. Grubišić I, Leniček T, Tomas D, Džombeta T, Trnski D, Tomašković I, Krušlin B. Primary osteosarcoma of ivericulum mimicking intradiverticular calculus: a case report. *Diagn Pathol.* 2011;6:37.

2. Tamas EF, Stephenson AJ, Campbell SC, Montague DK, Trusty DC, Hansel DE. Histopathologic features and clinical outcomes in 71 cases of bladder diverticula. *Arch Pathol Lab Med.* 2009;133:791-6.
3. Dondalski M, White EM, Ghahremani GG, Patel SK. Carcinoma arising in urinary bladder diverticula: imaging findings in six patients. *AJR Am J Roentgenol.* 1993;161:817-20.
4. Haecker A, Riedasch G, Langbein S, Alken P, Michel MS. Diverticular carcinoma of the urinary bladder: diagnosis and treatment problems. A case report. *Med Princ Pract.* 2005;14:121-4.
5. Neuzillet Y, Comperat E, Rouprêt M, Larre S, Roy C, Quintens H, Houede N, Pignot G, Wallerand H, Soulie M. Intradiverticular bladder tumours: review of the Cancer Committee of the French Association of Urology. *Prog Urol.* 2012;22:495-502.
6. Golijanin D, Yossepowitch O, Beck SD, Sogani P, Dalbagni G. Carcinoma in a bladder diverticulum: presentation and treatment outcome. *J Urol.* 2003;170:1761-4.
7. Sallami S, Ben Rhouma S, Hafsia G, Noura Y, Horchani A. Intradiverticular tumors of the bladder: diagnostic and therapeutic problems: report of 32 cases. *Tunis Med.* 2011;89:663-7.
8. Dong WX, Ping YX, Liang WC, Jian LZ, Lin ZJ. Small cell carcinoma of the urinary bladder diverticulum: a case report and review of the literature. *J Cancer Res Ther.* 2013;9:151-3.

Sažetak

RIJEDAK SLUČAJ KARCINOMA PLOČASTIH STANICA U DIVERTIKULU MOKRAĆNOG MJEHURA USPJEŠNO IZLIJEČEN POŠTEDNOM KIRURGIJOM

G. Štimac, M. Knežević, I. Grubišić, S. Soipi, D. Tomas i B. Krušlin

Cilj je predstaviti rijedak slučaj karcinoma pločastih stanica u divertikulu mokraćnog mjehura i prikazati pregled novije literature o mogućnostima liječenja. Muškarac u dobi od 56 godina javio se zbog intermitentne hematurije. Ultrazvučnim pregledom postavljena je sumnja na karcinom u divertikulu mokraćnog mjehura. Dijagnoza je potvrđena cistoskopski i kompjutoriziranom tomografijom. Potom je učinjena transvezikalna divertikulektomija s regionalnom limfadenektomijom. Dvije godine nakon početnog liječenja bolesnik je dobrog općeg stanja, bez dokaza o recidivu tumora. Iako se agresivni kirurški pristup preporuča u većini tumora smještenih u divertikulu mokraćnog mjehura, jednostavna divertikulektomija može biti indicirana u odabranim slučajevima.

Ključne riječi: *Karcinom, planocelularni; Mokraćni mjehur, tumori; Divertikulum – patologija; Divertikulum – kirurgija; Prikazi slučaja*