

## OROFACIAL GRANULOMATOSIS: CASE REPORT

Vlaho Brailo<sup>1</sup>, Vanja Vučićević Boras<sup>1</sup>, Sven Seiwert<sup>2</sup>, Vedran Tomašić<sup>3</sup>, Iva Bakale<sup>1</sup>, Danica Vidović Juras<sup>1</sup> and Suzana Ljubojević Hadžavdić<sup>4</sup>

<sup>1</sup>Department of Oral medicine, School of Dental Medicine, University of Zagreb and Zagreb University Hospital Center; <sup>2</sup>Department of Pathology, Zagreb University Hospital Center and School of Medicine, University of Zagreb; <sup>3</sup>Clinical Department of Gastroenterology, Sestre milosrdnice University Hospital Center; <sup>4</sup>Clinical Department of Dermatology and Venereology, Zagreb University Hospital Center, Zagreb, Croatia

**SUMMARY** – An 18-year-old girl was referred to the Department of Oral Medicine with upper lip swelling. She was in good general health and laboratory tests were within the normal range. Histopathologic diagnosis did not reveal the presence of granulomas. This is consistent with the finding that 30% of patients with orofacial granulomatosis do not have granulomas on their biopsies. The patient was treated with intralesional steroids once a week for three weeks. The lesion subsided, but not completely, and recurred partially after ketchup intake. This case report highlights the fact that in every patient with non-odontogenic facial or oral swelling, systemic diseases such as sarcoidosis, Crohn's disease, tuberculosis, etc. must be excluded. Furthermore, it is not unusual that in patients with orofacial granulomatosis, noncaseating granulomas are absent in the histopathologic finding.

**Key words:** *Granulomatosis, orofacial – diagnosis; Granulomatosis, orofacial – therapy; Case reports*

### Introduction

Orofacial granulomatosis (OFG) is a clinical term describing orofacial swelling in the absence of systemic disease. Currently, a hypothesis describes OFG as a consequence of random influx of inflammatory cells rather than a specific, single antigen<sup>1</sup>. Usually, OFG presents as lip swelling or oral mucosal swelling. OFG may also present as oral ulcerations, vertical lip fissures, angular cheilitis, cobblestoning of oral mucosa, and mucosal tags. Recently, a case of gingival enlargement as the only OFG manifestation has been described<sup>2</sup>. Nowadays, OFG is more frequently seen in children and young adults<sup>3</sup>. The edema is painless, non-pruritic and nonerythematous<sup>4</sup>. The swelling may be persistent, recurrent and progressive<sup>4</sup>. Aller-

gies such as hay fever, asthma or atopic eczema seem to be more prevalent in patients with OFG and their prevalence is 12%-60%<sup>5-7</sup>. In an early study of 75 patients with OFG, the incidence of allergy was 60%<sup>8</sup>. Cinnamon and benzoates have been found to be positive on patch testing in patients with OFG<sup>9</sup>. The role of allergy would be supported by clinical presentation (patients frequently report swelling after specific dietary or other environmental exposure) and response to exclusion diets (cinnamon and benzoate free)<sup>10</sup>.

### Case Report

Our 18-year-old patient presented with upper lip swelling on the right side, which had lasted for four years (Fig. 1). The patient was not taking any medication and was otherwise healthy. Biopsy was performed and histopathologic finding revealed hyperplastic parakeratotic epithelium and underneath rare collagen and adipose tissue with rare clustered mononuclear cells. HLA genotyping showed HLA A1 and A26, HLA

Correspondence to: *Vanja Vučićević Boras, DDM, Department of Oral Medicine, School of Dental Medicine, University of Zagreb, Gundulićeva 5, HR-10000 Zagreb, Croatia*

E-mail: boras@sfzg.hr

Received December 16, 2013, accepted October 1, 2014

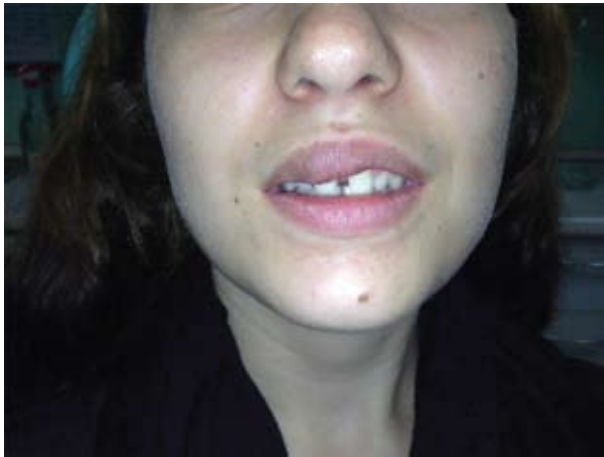


Fig. 1. Upper lip enlargement on admission.

B17 and B44, HLA DR7, DR11, DR52 and DR53. She did not have fissured tongue and had no signs of facial palsy. Her complete blood count, serum iron and vitamin B12 were within the normal range. The patient was referred for colonoscopy due to persistent constipation and occasional diarrhea, which revealed no disturbances. Her PPD finding was borderline positive and she was referred for chest x-ray in order to exclude tuberculosis and sarcoidosis, especially as her serum angiotensin-converting enzyme level was borderline positive again. However, chest x-ray showed normal findings. The patient's allergic tests for nutritive and inhalational allergens proved negative.

We did suggest elimination diet in our patient, especially as the lesion tended to recur after ketchup intake (which was not the case with chocolate intake) but she did not want to pursue elimination diet. The patient was treated with intralesional steroid injections (methylprednisolone acetate 40 mg/mL, Depo Medrol®), 0.2 mL *per* visit divided into two equal parts and applied on two sites in her upper lip once a week for three weeks. The lip lesion subsided one week after the last injection but recurred after consumption of ketchup.

## Discussion

Marcoval *et al.*<sup>4</sup> report that in 65% of their patients with OFG, the presence of labial swelling predominantly involving upper lip was highly suggestive of OFG. In northern Europe, patients with OFG are advised to obtain colonoscopy findings; however, this

is not the case in southern Europe<sup>4</sup>, as seen in our patient. It has been suggested that OFG might be caused by delayed hypersensitivity to gold, mercury and cobalt<sup>11,12</sup>, however, our patient did not have any dental materials on her upper frontal teeth. Other patients we have recently described had no metal fillings/crowns near the area of lip enlargement either. It has been postulated that OFG might be associated with certain HLA haplotypes such as HLA A3, B7 and DR2<sup>13</sup>, however, HLA genotyping in our patient showed the presence of different HLA haplotypes (HLA A1 and A26, HLA B17 and B44, HLA DR7, DR11, DR52 and DR53).

Various food substances and additives have been blamed to be the cause of OFG and many patients are advised to adhere to elimination diet<sup>14,15</sup>, a finding which is consistent with the finding in our patient, as remission correlated with ketchup intake which is known to contain benzoates. However, allergic tests for nutritive and inhalational allergens were all negative.

Marcoval *et al.*<sup>4</sup> report that OFG in southern Europe does not correlate with Crohn's disease, a finding which we can also confirm, as none of our patients with OFG had Crohn's disease<sup>16</sup>. Histopathologic finding did not reveal noncaseating granulomas, a finding that is consistent with OFG in approximately 45% of OFG patients<sup>17,18</sup>.

The list of differential diagnoses regarding lip enlargement may include tumors, cysts, sarcoidosis, Crohn's disease, foreign body reactions, Melkersson-Rosenthal syndrome, Wegener's granulomatosis, cheilitis granulomatosa or hairy cell leukemia, amyloidosis, hypersensitivity reactions (food substances and additives, cosmetic antigens) angioneurotic edema, C1 esterase deficiency, infective agents such as tuberculosis, actinomycosis, syphilis, systemic mycoses, leprosy and cat-scratch disease<sup>3,19,20</sup>.

Therapy for oral OFG lesions consists of intralesional steroid injections and various treatment modalities have been proposed such as once a week, twice a week and every day, however, our experience shows that intralesional injections once or twice a week for three to four weeks are sufficient to eliminate symptoms in most of the patients<sup>15,16</sup>.

Even though our patient's swelling showed no granulomas on biopsy, clinical presentation and re-

sponse to intralesional steroids led us to make the diagnosis of OFG.

## References

1. Grave B, McCullough M, Wiesenfeld D. Orofacial granulomatosis – a 20-year review. *Oral Dis.* 2009;15:46-51.
2. Kaarthikeyan G, Arvind M, Jayakumar ND, Khakar M. Idiopathic orofacial granulomatosis in a young patient: a rare entity. *J Oral Maxillofac Pathol.* 2012;16:432-4.
3. Rana AP. Orofacial granulomatosis: a case report with review of literature. *J Indian Soc Periodontol.* 2012;16:469-74.
4. Marcoval J, Vinas M, Bordas X, Jucgla A, Servitje O. Orofacial granulomatosis: clinical study of 20 patients. *Oral Surg Oral Med Oral Pathol Oral Radiol.* 2012;113:e12-e17.
5. Armstrong DK, Biagoni P, Lamey PJ, Burrows D. Contact hypersensitivity in patients with orofacial granulomatosis. *Am J Contact Dermat.* 1997;8:35-8.
6. Armstrong DK, Burrows D. Orofacial granulomatosis. *Int J Dermatol.* 1995;34:830-3.
7. Haworth RJ, Maclayden EE, Ferguson MM. Food intolerance in patients with orofacial granulomatosis. *Hum Nutr Appl Nutr.* 1986;40:447-56.
8. James J, Patton DW, Lewis CJ, Kirkwood EM, Ferguson MM. Orofacial granulomatosis and clinical atopy. *J Oral Med.* 1986;41:29-30.
9. Patel P, Brostoff J, Campbell H, *et al.* Clinical evidence for allergy in orofacial granulomatosis and inflammatory bowel disease. *Clin Trans Allergy.* 2013;3:26-33.
10. Wray D, Rees SR, Gibson J, Forsyth A. The role of allergy in oral mucosal diseases. *QJ Med.* 2000;93:507-11.
11. Lazarov A, Kidron D, Tulchinsky Z, Minkow B. Contact orofacial granulomatosis caused by delayed hypersensitivity to gold and mercury. *J Am Acad Dermatol.* 2003;49:1117-20.
12. Pryce DW, King CM. Orofacial granulomatosis associated with delayed hypersensitivity to cobalt. *Clin Exp Dermatol.* 1990;15:384-6.
13. Gibson J, Wray D. Human leucocyte antigen typing in orofacial granulomatosis. *Br J Dermatol.* 2000;143:1097-131.
14. Patton DW, Ferguson MM, Forsyth A, James J. Orofacial granulomatosis: a possible allergic basis. *Br J Oral Maxillofac Surg.* 1985;23:235-42.
15. Reed BE, Barrett AP, Katelaris C, Bilous M. Orofacial sensitivity reactions and role of dietary components. Case reports. *Aust Dent J.* 1993;38:287-91.
16. Alajbeg I, Rogulj AA, Hutinec Z. Orofacial granulomatosis treated with intralesional triamcinolone. *Acta Dermatovenol Croat.* 2011;19(3):165-9.
17. Al Johani KA, Moles DR, Hodgson TA, Porter SR, Fedele S. Orofacial granulomatosis: clinical features and long term outcome of therapy. *J Am Acad Dermatol.* 2010;62:611-20.
18. Williams AJ, Wray D, Ferguson A. The clinical entity of orofacial Crohn's disease. *QJ Med.* 1991;79:451-8.
19. Critchlow WA, Chang D. Cheilitis granulomatosa: a review. *Head Neck Pathol.* 2013 Sep 22. [Epub ahead of print].
20. Bakula A, Lugović-Mihić L, Šitum M, Turčin J, Šinković A. Contact allergy in the mouth: diversity of clinical presentations and diagnosis of common allergens relevant to dental practice. *Acta Clin Croat.* 2011;50(4):553-61.

## Sažetak

### OROFACIJALNA GRANULOMATOZA: PRIKAZ SLUČAJA

V. Brailo, V. Vučićević Boras, S. Seiwert, V. Tomašić, I. Bakale, D. Vidović Juras i S. Ljubojević Hadžavdić

Osamnaestogodišnja djevojka bila je upućena na Zavod za oralnu medicinu s oteklinom gornje usne. Inače je bila dobrog općeg stanja i laboratorijski nalazi bili su unutar normalnih raspona. Patohistološki nalaz biopata usne nije pokazao prisutnost granuloma, što je u skladu s nalazima drugih autora, jer oko 30% oboljelih od orofacijalne granulomatoze nema granulome u biopatu. Pacijentica je liječena intralezijom primjenom kortikosteroida jednom tjedno tijekom tri tjedna te se otekline većim dijelom povukla, ali se djelomice opet pojavila nakon uzimanja kečapa. Ovaj prikaz slučaja pokazuje kako je u pacijenata koji nemaju odontogeni uzrok otekline lica ili usta potrebno isključiti sistemske bolesti poput sarkoidoze, Crohnove bolesti, tuberkuloze i dr. Nadalje, nije neuobičajeno da se u bolesnika s orofacijalnom granulomatozom ne nađu granulomi u patohistološkom nalazu.

Ključne riječi: *Granulomatoza, orofacijalna – dijagnostika; Granulomatoza, orofacijalna – terapija; Prikazi slučaja*