

PHACOEMULSIFICATION THROUGH THE SMALL PUPIL

Ante Ercegović, Ivana Kalauz-Surać and Jasenka Brajković

Department of Ophthalmology, Šibenik General Hospital, Šibenik, Croatia

SUMMARY – The aim of the report is to describe phacoemulsification through a small pupil without enlarging it. The small, poorly dilated pupil is one of the most common problems the cataract surgeons are faced with. There are several options available when working on the eyes with a small pupil. One option is to enlarge the pupil, and the other is to work through it. We present the procedure of phacoemulsification through a small pupil without enlargement. The essence of this technique is to produce multiple small nuclear fragments that are easy to consume and do not cause excessive stress to the pupillary sphincter. Using this method, successful phacoemulsification was performed with minimal or no pupil widening maneuvers, restoring the preoperative pupil configuration.

Key words: *cataract surgery, phacoemulsification, small pupil*

Introduction

One of the most important things in cataract surgery is pupil size. Unfortunately, many patients fail to show appropriate response to topical mydriatic agents, resulting in small, poorly dilated pupils, smaller than 4 mm. Phacoemulsification through a small pupil is associated with a higher incidence of intraoperative complications such as capsular rupture, vitreous loss, dropped nucleus, endothelial cell loss and zonular dehiscence. Therefore, the operation through a small pupil remains a challenge to the surgeon.

Many factors may cause small pupil. The most common causes are pseudoexfoliation (PEX) syndrome, chronic miotic therapy, previous trauma or surgery, uveitis with synechiae, diabetes mellitus, and recently the intraoperative floppy iris syndrome (IFIS)¹⁻⁵.

Several options are available when working on the eyes with small pupils. Pupils that cannot be adequately dilated with pharmacologic agents can be treated in different surgical ways, one of which is the operation through the pupil without enlarging it. The most common reason to work through a small pupil without en-

largement is that it may not seem so small once we have decided to perform it. We present the procedure of phacoemulsification through a small pupil without enlarging it.

Patients and Methods

Pupils were preoperatively dilated with 10% phenylephrine hydrochloride and 1% tropicamide eye drops 3 times every 10 minutes, starting 1 hour before surgery; 0.0% flurbiprofen eye drops were also administered 4 times a day starting 1 day before surgery. Tetracaine eye drops were administered 4-5 times within a 15-minute interval immediately before surgery.

A limbal self-sealing incision was made with a 3.0 slit knife superotemporally on the right eye and superonasally on the left eye. Upon creating a limbal tunnel, the anterior chamber was irrigated with 0.5% bupivacaine hydrochloride (Marcaine, Astra Zeneca). Then, 3% sodium hyaluronate (Vitrax II, AMO) was injected into the anterior chamber in the pupillary plane, in an attempt to viscodilate the small pupil. The second incision was made in clear cornea. Pupil size was measured just before anterior capsulorhexis was initiated, and it was 3.6 mm. Continuous curvilinear capsulorhexis was done with a needle and capsulorhexis forceps next to the pupillary rim (Fig. 1). Cortical cleaving hydrodis-

Correspondence to: *Ante Ercegović, MD, MS*, Department of Ophthalmology, Šibenik General Hospital, Stjepana Radića 83, HR-22000 Šibenik, Croatia

Received January 30, 2007, accepted March 26, 2007

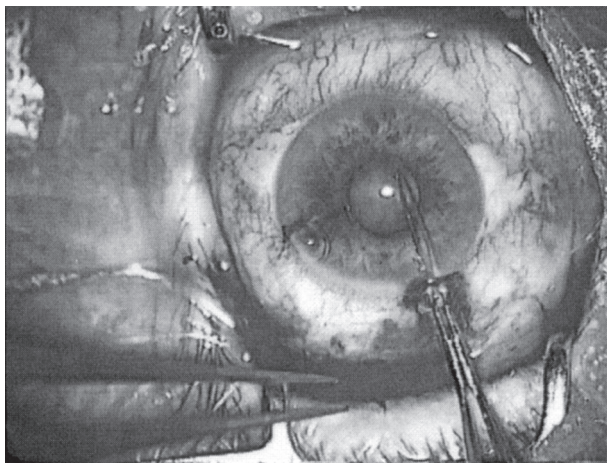


Fig. 1. Continuous curvilinear capsulorrhexis next to the pupillary margin.

section and rotation were done with a small cannula (it is important to perform it very carefully), utilizing injections in several different quadrants.

Phacoemulsification was performed with a Universal II phacoemulsifier (Alcon). The first step of phaco was an initial crack (chop *in situ*) performed by phaco tip (ABS Cobra microtip) and chopper (which does not move from the periphery to the center; it remains within the capsulorrhexis margin). The phaco tip was buried in the center of the endonucleus raising it slowly and then the vertical element of the chopper was depressed posteriorly to initiate the crack. Then the chopper was repositioned to the depth of the crack, which was followed by a lateral separation movement. After that, the heminucleus was divided mechanically into multiple small fragments using a phaco chop technique. The nuclear fragments were consumed within the central space in the pupillary plane (in some cases it may be necessary to bring the nuclear fragments into view to the anterior chamber).

Typical machine settings during chopping were US power 60%-70%, vacuum 250-400 mm Hg, and aspiration flow rate (AFR) 20-24 cc/min. Vacuum was progressively reduced as the chopped fragments were removed. During removal of the last fragments, the vacuum was at 100 mm Hg.

The epinucleus was removed with a phaco probe (retracting the iris with a chopper gives good access to the epinucleus) and machine parameters during the procedure were US power 60%-70%, vacuum 250-400 mm Hg, and aspiration flow rate 16 cc/min. After the epinucleus

had been removed, the cortex was aspirated with an automated irrigation/aspiration (I/A) probe. Then the anterior chamber and capsular bag were filled with a viscoelastic agent (Vitrax II, AMO). The incision was enlarged to 3.5 mm for intraocular lens (IOL) insertion and a foldable silicone (PhacoFlex II, AMO) or acrylic (AcrySof, Alcon) IOL was implanted in the capsular bag. The viscoelastic agent was then removed with an I/A probe.

A dose of 1.5 mg dexamethasone and 5 mg gentamicin were administered subconjunctivally. Postoperative medication included dexamethasone eye drops 5 times a day and ointment once a day within 1 month.

Discussion and Conclusion

Many patients that present for cataract removal have complications with pupils which do not adequately dilate despite several pharmacological attempts with topical mydriatic agents. The causes are numerous and can include iris spincter sclerosis due to aging, synechiae, previous trauma or surgery, diabetes mellitus, chronic miotic therapy, iridoschisis, uveitis, PEX and IFIS¹⁻⁵.

Most of the small pupil widening techniques can be grouped into one of the following categories: "mechanical viscomydrasis" (Healon 5)^{3,6}; surgical (proximal iridectomy, pupillary membrane dissection, multiple partial sphincterotomies, etc.)^{2,7}; stretching (iris-retractor hooks, Beehler pupil dilators, bimanual dilatation, silicone pupil expander, etc.)⁸⁻¹¹; and ring expanders (PMMA pupil dilator ring, Perfect pupil-polyurethane ring)^{2,8}. Most of these techniques provide adequate dilatation with appropriate visualization, however, they also suffer from some disadvantages such as iris trauma, extended operative time, new incisions, cost (some are expensive), and increased uveal response, all of which can lead to permanent pupil distortion (abnormal pupil shape postoperatively)^{2,8,12,13}.

However, in some cases it may not be necessary to perform these manipulations. We have shown one of the possible ways of working through a small pupil without previous enlargement. In our case, the phaco procedure was performed in the small central space within a small capsulorrhexis margin. It is very important to produce multiple small nuclear fragments, which are easy to consume and do not cause excessive stress to the pupillary sphincter. The main challenge in such cases is proper understanding of fluid dynamics to prevent inadvertent aspiration of the uveal tissue or posterior capsule.

References

1. MASKET S. Cataract surgery complicated by the miotic pupil. In: BURATTO L, OSHER RH, MASKET S, eds. Cataract surgery in complicated cases. Thorofare, NJ: Slack, Inc., 2000:132-5.
2. KERSHNER RM. Management of the small pupil for clear corneal cataract surgery. J Cataract Refract Surg 2002;28:1826-31.
3. COLVARD DM, KANDAVEL R. Viscoelastic solutions to challenging surgeries. Rev Ophthalmol 2006;13:1-3.
4. CHANG DF, CAMPBELL JR. Intraoperative floppy iris syndrome associated with tamsulosin. J Cataract Refract Surg 2005;31:664-73.
5. ZACZEK A, ZETTERSTROM C. Cataract surgery and pupil size in patients with diabetes mellitus. Acta Ophthalmol Scand 1997;75:429-32.
6. FISHKIND W, KOCH PS. Managing the small pupil. In: KOCH PS, DAVISON JA, eds. Textbook of advanced phacoemulsification techniques. Thorofare, NJ: Slack, Inc., 1991:79-90.
7. FINE IH. Pupilloplasty for small pupil phacoemulsification. J Cataract Refract Surg 1994;20:192-6.
8. AKMAN A, YILMAZ G, OTO S, AKOVA Y. Comparison of various pupil dilatation methods for phacoemulsification in eyes with a small pupil secondary to pseudoexfoliation. Ophthalmology 2004;111:1693-8.
9. OETTING TA, OMPHROY LC. Modified technique using flexible iris retractors in clear corneal surgery. J Cataract Refract Surg 2002;28:596-8.
10. FINE IH, HOFFMAN RS. Phacoemulsification in pseudoexfoliation: challenges and options. J Cataract Refract Surg 1997;23:160-5.
11. BIRCHALL W, SPENCER AF. Misalignment of flexible iris hook retractors for small pupil cataract surgery: effects on pupil circumference. J Cataract Refract Surg 2001;27:20-4.
12. VASAVADA A, SINGH R. Phacoemulsification in eyes with a small pupil. J Cataract Refract Surg 2000;26:1210-8.
13. YUGUCHI T, OSHICA T, SAWAGUCHI S, KAIYA T. Pupilary functions after cataract surgery using flexible iris retractor in patient with small pupil. Jpn J Ophthalmol 1999;43:20-4.

Sažetak

FAKOEMULZIFIKACIJA KROZ USKU ZJENICU

A. Ercegović, I. Kalauz-Surać i J. Brajković

Cilj je prikazati fakoemulzifikaciju kroz usku zjenicu bez njezina proširenja. Mala, slabo dilatirana zjenica jedan je od najčešćih problema s kojima se susreću operateri. Na raspolaganju je nekoliko mogućnosti za rad na očima s uskom zjenicom. S jedne strane to su metode dilatacije zjenice, a s druge rad kroz usku zjenicu bez dodatnog proširenja. Predstavljamo fakoemulzifikaciju kroz usku zjenicu bez dodatnog širenja. U osnovi ove metode je proizvesti mnogo malih nuklearnih fragmenata koje je tada jednostavno ukloniti a da se pritom ne uzrokuje prekomjeran stres zjeničnog sfinktera. Napravljena je uspješna fakoemulzifikacija s minimalnim zahvatima širenja zjenice ostavljajući prijeoperacijski izgled zjenice.

Ključne riječi: *kirurgija katarakte, fakoemulzifikacija, uska zjenica*

