

## OPTIC NEURITIS AND MULTIPLE SCLEROSIS: OUR EXPERIENCE

Davor Galetović, Lovro Bojić, Dobrila Karlica, Kajo Bućan, Veljko Rogošić and Ljubo Znaor

University Department of Ophthalmology, Split University Hospital, Split, Croatia

**SUMMARY** – Idiopathic optic neuritis is idiopathic inflammation of the optic nerve. Multiple sclerosis is a chronic inflammatory demyelinating process of the central nervous system that affects mostly women aged 20-40. Modern diagnostic methods (MRI, VEP, and computerized perimetry) can confirm or exclude demyelinating etiology of the process. The study included 31 patients with optic neuritis hospitalized at University Department of Ophthalmology, Split University Hospital in Split, Croatia, between January 1, 2004 and December 31, 2005. The incidence of idiopathic optic neuropathy at Department was 3.2/100,000 in 2004 and 3.4/100,000 in 2005. The majority of patients were in the 20-40 age group. In 22 (84.62%) patients, MRI showed brain demyelinating lesions. Most patients had prolonged VEP latencies. The incidence of idiopathic optic neuropathy has shown a significant increase in the last two years. Brain MRI was the key diagnostic method, along with significant symptoms and signs of idiopathic optic neuropathy. High dose corticosteroid pulse therapy, as described before, was demonstrated to have a beneficial effect on quick recovery of visual acuity and lengthening of relapse-free period.

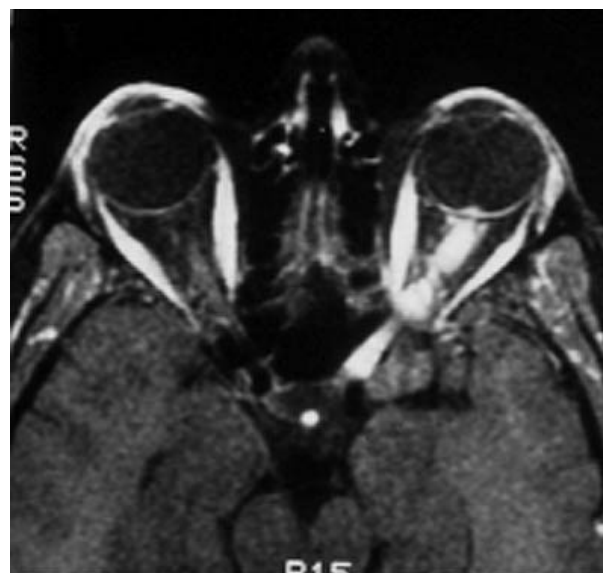
**Key words:** *Optic neuritis*

### Introduction

Idiopathic optic neuritis is idiopathic inflammation of the optic nerve. It may develop isolated or concurrently with disseminated demyelinating processes. Optic neuritis most commonly affects young women aged 20-40, its incidence being estimated to 1-5/100,000. The most important symptoms are acute onset of central vision loss, described as dim or foggy vision, or a gray central blur with color washout, developing over several days<sup>1</sup>. Figure 1 shows typical magnetic resonance imaging (MRI) finding in one of our patients with optic neuritis.

Multiple sclerosis (MS) is a chronic inflammatory demyelinating process of the central nervous system that affects mostly women aged 20-40. The diagnosis of clinically defined MS (CDMS) demands at least two sepa-

rate episodes of neurological disturbances and two anatomically distinct lesions accompanied by demyelina-



*Fig. 1. Typical MRI finding in one of our patients with optic neuritis.*

Correspondence to: *Davor Galetović, MD*, University Department of Ophthalmology, Split University Hospital, Spinčićeva 1, HR-21000 Split, Croatia  
E-mail: [nikolina.galetovic@public.carnet.hr](mailto:nikolina.galetovic@public.carnet.hr)

Received January 30, 2007, accepted March 26, 2007

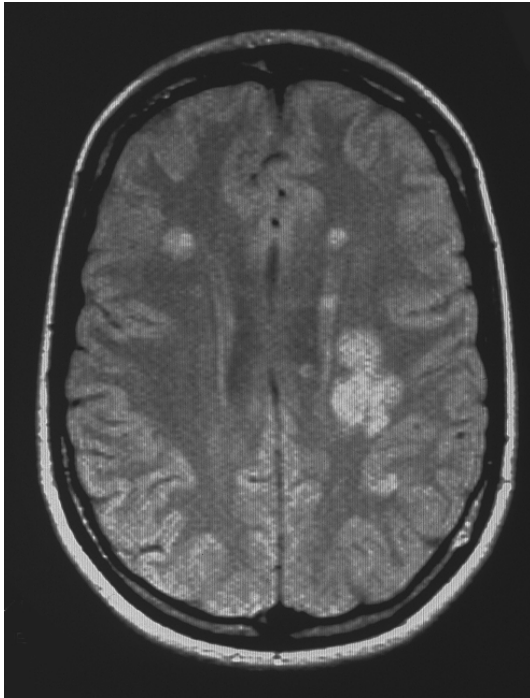


Fig. 2. MRI scan of one of our patients with clinically significant multiple sclerosis.

tion<sup>2,3</sup>. The diagnosis is substantially based on MRI findings. Figure 2 shows MRI scans of one of our patients with CDMS.

None of the treatments showed long term benefit for visual acuity. Corticosteroids are indicated in case of severe visual loss, major visual field defects, and in the presence of demyelination on MRI<sup>4</sup>. Immunomodulators such as interferon  $\beta$  1a (Avonex, Biogen) are also used as long lasting therapy<sup>5,6</sup>. Any mode of therapy should be confirmed by a neurologist<sup>2</sup>.

The aim of this study was to assess the incidence of and the key diagnostic and therapeutic procedures for idiopathic optic neuropathy, and to evaluate the success rate recorded.

### Patients and Methods

Thirty-one patients with optic neuritis hospitalized between January 1, 2004 and December 31, 2005 at University Department of Ophthalmology, Split University Hospital in Split, Croatia, were included in the study. Idiopathic optic neuropathy was diagnosed for the first time in 27 (87.10%) patients, whereas four (12.90%) patients were hospitalized for the disease relapse. There

were seven (22.58%) male and 24 (77.42%) female patients, aged 15-73. Monocular symptoms were present in 28 (90.32%) and binocular symptoms in three (9.67%) patients. Visual acuity was assessed using Snellen's charts in all patients before and after therapy. Funduscopy, tonometry, color vision assessment with pseudoisochromatic charts, and pupillary reaction studies were also performed. Computerized perimetry, visual evoked potentials (VEP), laboratory tests, and neurological and internist examinations were additionally done. Brain MRI was obtained in 26 (80.77%) and VEP determination in 25 (80.64%) patients.

Pulse corticosteroid therapy was administered in 25 (80.64%) patients. It consisted of 1g or 4 times 250 mg of methylprednisolone i.v. for 3 days, followed by oral or i.m. 1 mg/kg of prednisone daily for 11 days, with tapering for another 4 days. Pulse corticosteroid therapy was not used in patients with well preserved visual acuity (0.7-0.9), mild visual field defects, and those free from demyelinating defects identified on MRI.

### Results

The incidence of idiopathic optic neuropathy at our Department was 3.2/100,000 in 2004 and 3.4/100,000 in 2005. The study included seven (22.58%) men and 24 (77.42%) women. In 27 (87.10%) patients, idiopathic optic neuritis was diagnosed for the first time, whereas four (12.90%) patients were hospitalized for relapse of the disease. The majority of patients were in the 18-45 age group (Fig. 3). All patients had more or less compromised visual field, with mostly central and paracentral or peripheral arcuate scotomata. All patients had positive relative afferent papillary defect, and some showed mild or severe dyschromatopsia. Optic disc edema was found in three (9.67%) patients. In all other patients, funduscopy findings were normal. Periorbital pain caused by eye movement was recorded in 13 (41.93%) patients.

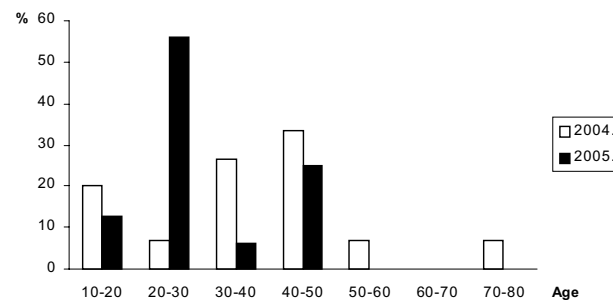


Fig. 3. Patient age distribution.

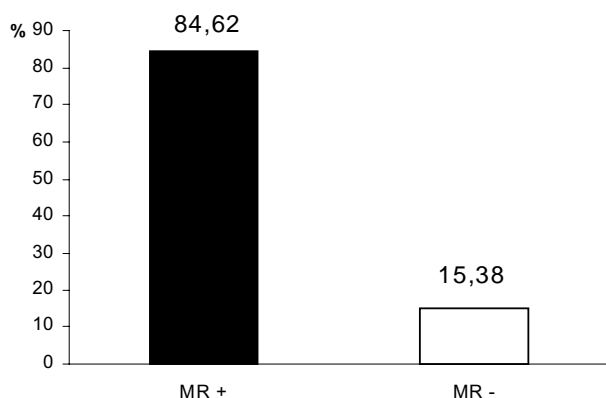


Fig. 4. MRI results in 26 patients.

In 22 (84.62%) patients, MRI showed brain demyelinating lesions (Fig. 4). Most patients had elongated VEP latency, which ranged between 104 and 164 ms (Fig. 5). Besides optic nerve neuritis symptoms, four (12.90%) patients also showed neurological signs, e.g., accentuated plantar and abdominal reflexes with mild walking instability. Laboratory results did not suggest systemic disease of any kind in any of study patients. Visual acuity was reduced in all patients (from light perception and projection up to 0.9). All patients experienced improvement of visual acuity after pulse therapy. Figures 6 and 7 show visual acuity before and after pulse corticosteroid therapy. Visual acuity improved only slightly in seven (22.58%) and substantially in the rest of patients; in eight (25.80%) patients visual acuity was nearly normal (0.8-1.0). The mean visual acuity in all patients was 0.15 before and 0.52 after therapy.

## Conclusion

The incidence of idiopathic optic neuritis has shown significant increase in the last two years as compared

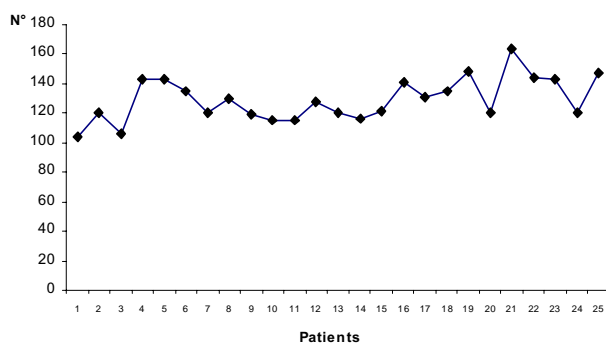


Fig. 5. VEP latencies in 25 patients.

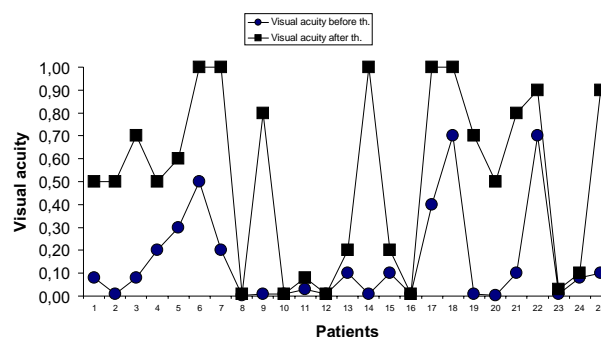


Fig. 6. Visual acuity before and after pulse corticosteroid therapy in 25 patients.

with the incidence recorded during the 1985-2003 period, when it was estimated to 1.91/100,000 inhabitants<sup>7</sup>. Brain MRI was the key diagnostic method, along with pronounced symptoms and signs of idiopathic optic neuropathy. By use of MRI and other modern diagnostic methods such as VEP and computerized perimetry (Octopus), we can confirm or rule out with high accuracy the presence of demyelinating etiology in patients with idiopathic optic neuritis. We administered pulse corticosteroid therapy according to Optic Neuritis Treatment Trial (ONTT) guidelines, with the aim of accelerating recovery and prolonging time to possible relapses. It is estimated that the possible spontaneous recovery may occur in some 4 weeks<sup>4</sup>. According to our results, substantial recovery of visual acuity occurred after 14 days of pulse therapy in most patients. Since the study started on January 1, 2004, four (12.90%) patients were re-hospitalized for optic neuritis relapse until now. The results described above support the use of pulse therapy as the most efficacious mode of treatment for visual acuity recovery and delay of the disease relapse.

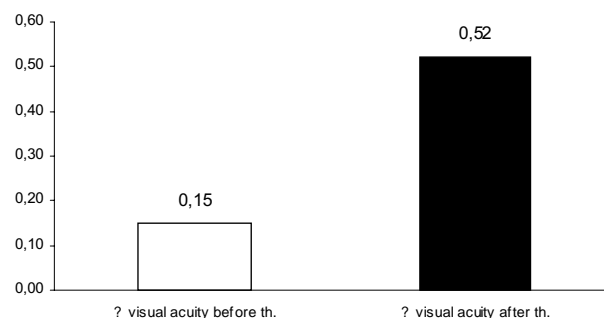


Fig. 7. Mean visual acuity before and after pulse corticosteroid therapy in 25 patients.

Idiopathic optic nerve inflammation develops in isolation or in the context of disseminated demyelinating disease. Since the first acute episode is solely the first sign of demyelinating disease, “clinically isolated syndrome”, and as it usually manifests with sudden loss of visual acuity, patients with suspected optic neuritis should visit an ophthalmologist within 24 hours<sup>1</sup>. Initial evaluation is focused on confirming acute optic nerve dysfunction, differentiation from other acute optic neuropathies, and the need of additional examinations to determine the actual state, most appropriate therapy, and future risk of MS development.

## References

1. LEVIN L, ARNOLD A. Idiopathic optic neuritis. In: LEVIN L, ARNOLD A, eds. Neuro-ophthalmology. New York: Thieme, 2005;198-202.
2. FALE AUTORI. The 5-year risk of MS after optic neuritis. Experience of the Optic Neuritis Treatment Trial. Optic Neuritis Study Group. *Neurology* 1997;49:1404-13.
3. BECK RW, TROBE JD, MOKE PS, GAL RL, XING D, BHATTI MT, BRODSKY MC, BUCKLEY EG, CHROUSOS GA, CORBETT J, EGGENBERGER E, GOODWIN JA, KATZ B, KAUFMAN DI, KELTNER JL, KUPERSMITH MJ, MILLER NR, NAZARIAN S, ORENGO-NANIA S, SAVINO PJ, SHULTS WT, SMITH CH, WALL M. High- and low-risk profiles for the development of multiple sclerosis within 10 years after optic neuritis: experience of the Optic Neuritis Treatment Trial. *Arch Ophthalmol* 2003;121:944-9.
4. BECK RW, CLEARY PA, ANDERSON MM, JR., KELTNER JL, SHULTS WT, KAUFMAN DI, BUCKLEY EG, CORBETT JJ, KUPERSMITH MJ, MILLER NR *et al.* A randomized, controlled trial of corticosteroids in the treatment of acute optic neuritis. The Optic Neuritis Study Group. *N Engl J Med* 1992;326:581-8.
5. JACOBS LD, BECK RW, SIMON JH, KINKEL RP, BROWN-SCHIEDLE CM, MURRAY TJ, SIMONIAN NA, SLASOR PJ, SANDROCK AW. Intramuscular interferon beta-1a therapy initiated during a first demyelinating event in multiple sclerosis. Champs Study Group. *N Engl J Med* 2000;343:898-904.
6. FALE AUTORI. Interferon beta-1a for optic neuritis patients at high risk for multiple sclerosis. *Am J Ophthalmol* 2001;132:463-71.
7. BOJIĆ L, IVANIŠEVIĆ M, SINIČIĆ A, ROGOŠIĆ V, GALETOVIĆ D, LEŠIN M, CLEMENTI-KOSTRENIĆ D. The incidence of optic neuritis in Split-Dalmatian County, Croatia. In: MANDIĆ Z, ed. Proceedings of the 5<sup>th</sup> Congress of the Croatian Ophthalmological Society with International Participation, Hvar, Croatia. *Ophthalmol Croat* 2005;14:22.

## Sažetak

### OPTIČKI NEURITIS I MULTIPLA SKLEROZA: NAŠA ISKUSTVA

*D. Galetović, L. Bojić, D. Karlica, K. Bućan, V. Rogošić i Lj. Znaor*

Idiopatski optički neuritis je upala vidnoga živca nepoznatog uzroka. Multipla skleroza je kronični upalni demijelinizirajući proces središnjega živčanog sustava, koji se najčešće javlja kod žena u dobi od 20 do 40 godina. Moderne dijagnostičke metode (magnetska rezonanca, vidni evocirani potencijali i kompjutorizirana perimetrija) omogućavaju potvrđivanje ili isključivanje demijelinizacijske etiologije procesa. U ovu studiju bio je uključen 31 bolesnik hospitaliziran između 1. siječnja 2004. i 31. prosinca 2005. godine u Klinici za očne bolesti Kliničke bolnice Split u Splitu, Hrvatska. Incidencija optičkog neuritisa u Klinici bila je 3,2/100.000 stanovnika u 2004. te 3,4/100.000 stanovnika u 2005. godini. Većina bolesnika je bila u dobi od 20 do 40 godina. Magnetska rezonanca je pokazala demijelinizacijske promjene u 22 (84,62%) bolesnika. Većina bolesnika je imala produžene VEP latencije. Incidencija idiopatske optičke neuropatije je pokazala značajan porast u posljednje dvije godine. Magnetska rezonanca mozga je bila ključna dijagnostička metoda uza značajne simptome i znakove idiopatske optičke neuropatije. Pulsna terapija kortikosteroidima u visokim dozama, kako je to prethodno objašnjeno, pokazala se je korisnom za brz oporavak vidne oštine te za produljenje vremena do recidiva.

Ključne riječi: *Optički neuritis*