

ASKIN'S TUMOR – A RARE TUMOR OF THE THORACOPULMONARY REGION

Anto Bekić¹, Muharem Mehulić¹, Marijan Gorečan¹, Suzana Kukulj¹, Diana Krmpotić¹ and Merica Veir²

¹University Hospital for Pulmonary Diseases, Zagreb; ²Novi Marof Special Hospital for Subacute Diseases, Novi Marof, Croatia

SUMMARY – Askin's tumor is a malignant small round cell tumor affecting the thoracopulmonary region. Because of its neuroectodermal origin it is also known as primitive neuroectodermal tumor. This rarely seen and aggressive malignant tumor most frequently occurs in children and young adults. The symptoms and clinical presentation as well as radiomorphologic abnormalities are nonspecific. Therefore, establishing an accurate diagnosis of Askin's tumor is difficult, thus histologic and immunohistologic findings are important. Immunohistologic stain of the specific marker neuron-specific enolase is essential. In addition, Askin's tumor shows histologic features similar to Ewing's tumor located in the bones, which suggests it to belong to the group of Ewing's tumors. Therapeutic approach is multimodal, e.g., surgical resection, chemotherapy, and radiation. Overall prognosis is poor. The objective of this report is to point to this unusual tumor of the thoracopulmonary region. A 23-year-old female with a giant right chest tumor mass and immunohistologic findings of the surgical specimen characteristic of Askin's tumor is described.

Key words: *Lung neoplasms – pathology; Lung neoplasms – histology; Lung neoplasms – diagnosis; Case report*

Introduction

Askin's tumor is a very rare, highly malignant tumor of the thoracopulmonary region¹⁻³. It was first described by Askin *et al.* in 1979⁴. They suggested its neuroectodermal origin based on the morphology and ultrastructural changes. Later it was confirmed by Linnoila *et al.* using immunohistochemical staining for neuron-specific enolase (NSE)⁵. Histologic features of Askin's tumor include small round cells, which are often NSE-positive^{1,6-8}. The term primitive neuroectodermal tumor (PNET) is synonymous, however, it is usually used for a localization outside the thoracopulmonary region. The usual and unusual PNET localizations have been identified⁹⁻¹². The clinical presentation and radiologic appearance of the lesions are nonspecific, which adds to the importance of the histologic and

immunohistochemical diagnosis⁹. Due to its histologic similarities to classic Ewing's sarcoma, Askin's tumor is also referred to as extraskeletal Ewing's sarcoma¹², and it belongs to the Ewing's family of tumors^{2,13}. In contrast to Askin's tumors, Ewing's sarcoma is immunohistochemically characterized by negativity for NSE immunostaining. Genetic analysis, electron microscopy and immunohistochemical studies have allowed for more reliable identification of the origin and classification of this tumor¹³, which is usually observed in children and young adults.

Case report

A 23-year-old female was admitted to the hospital for generalized weakness, sweating, recurrent fever to 38 °C, occasional chills and shaking, dry cough, intermittent attacks of suffocation and dyspnea. The patient had experienced pain on and off in the right side of her chest as well as in her thoracic and lumbosacral spine but the pain was transitory. The onset of the discomforts was three months prior to hospital admission. Antimicrobial therapy failed to

Correspondence to: *Anto Bekić, M.D., M.S.*, University Hospital for Pulmonary Diseases, Jordanovac 104, HR-10000 Zagreb, Croatia

E-mail: anto.bekic@zg.htnet.hr

Received November 24, 2003, accepted in revised form February 10, 2004

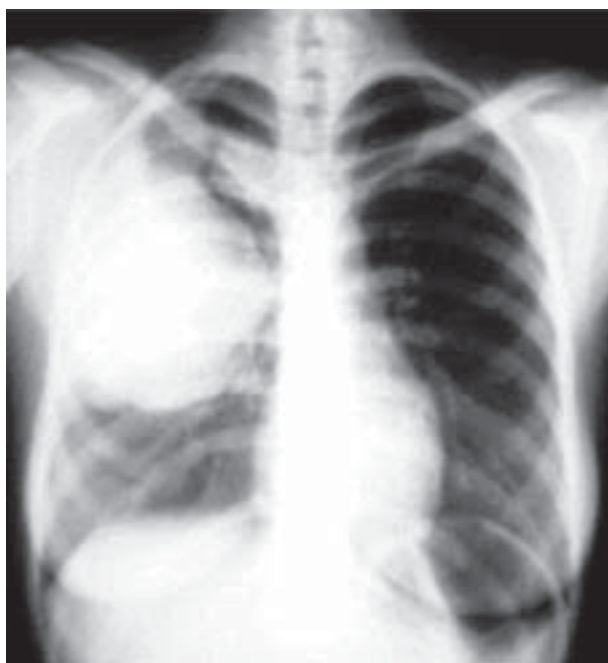

Figure 1. A giant right chest tumor mass spreading from hilus to chest wall

provide any improvement. Apart from childhood pneumonia and surgery for treatment of appendicitis, the patient's medical history included no other diseases. She occasionally took nonsteroidal antirheumatics for pain.

The patient was of average osteomuscular constitution and nutritional status, with somewhat pale skin, lucid, oriented, febrile (up to 38 °C), with no peripheral lymphadenopathy. In her head and neck status no abnormality was detected, and the chest wall was normal. On auscultation normal respiration was heard, except above the upper half

of the right pulmonary lobe, where it was found to be weakened. Heart action was rhythmic, sounds were clear, and no murmur was detected. Blood pressure was 110/70 mm Hg. The abdomen was tender and painless with no organomegaly, and no extremity abnormalities were detected.

Biochemical findings: erythrocyte sedimentation rate 84; WBC $8.8 \times 10^9/L$ (neutrophils 66.8%, lymphocytes 17%, monocytes 15.2%, eosinophils 0.6%); RBC $3.83 \times 10^{12}/L$; hemoglobin 109 g/L; hematocrit 0.32; platelets $278 \times 10^9/L$; total protein 59.00 g/L (albumins 45.4%, globulins: alpha 1 8.7%, alpha 2 19.3%, beta 12.1%, gamma 14.5%); lactate dehydrogenase 1803 U/L (reference range 0-460 U/L), and fibrinogen 16.6 g/L (reference range: 1.7-3.9 g/L). The results of all other biochemical blood tests were within the normal values. The urinalysis findings complied with the reference values.

Summation chest radiography and native tomography showed in the upper half of the right hemithorax laterally and dorsally along the thoracic wall a giant tumor mass of polymorphic characteristics, 14 cm in size, reaching the hilus and even compressing and dislocating the bronchi. The other tumefaction in the region measuring approximately 4 cm in diameter was localized medially in the retroclavicular area. No dislocation of the mediastinum was found. On the left side, no abnormalities were detected. The heart was found to be of an appropriate shape and size (Fig. 1). Chest CT scans revealed two tumor masses: one of a polymorphic structure, 10x12 cm in size, in the upper half of the right hemithorax (Fig. 2), penetrating into the intercostal space (Fig. 3), and one smaller mass, 3 cm in diameter, that was located paravertebrally. Upper abdominal CT scans revealed no focal pathologic lesions of either the spleen or the liver. Abdominal ultrasonography showed

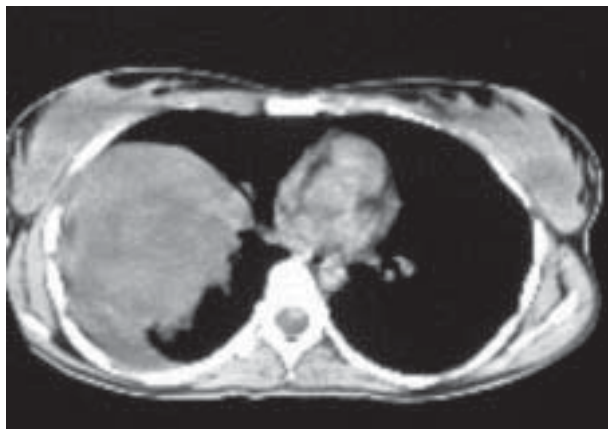


Figure 2. Polymorphic structure of the tumor

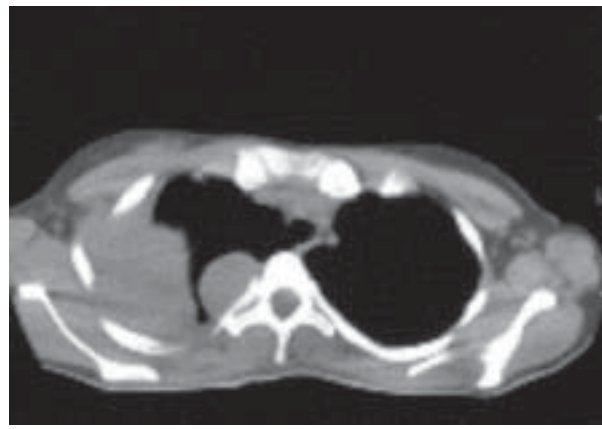


Figure 3. Extension of the tumor into intercostal spaces

no metastatic changes. On the radiographs of the lumbosacral spine in two projections and of the pelvis and hips no metastatic changes were detected.

Electrocardiography revealed sinus rhythm of 97/min, semivertical electrical axis, and nonspecific repolarization abnormalities. Spirometry identified minor restrictive ventilatory defects. Diffusion capacity for carbon monoxide was moderately impaired. Arterial blood gas analysis determined partial respiratory insufficiency with hyperventilation.

Cytology of the transthoracic biopsy specimen obtained from the right intrathoracic mass revealed blood, lymphatic cells, and several clusters of poorly preserved cells suspect of malignancy.

The patient was operated on ten days following hospital admission. At surgery the tumor was found to infiltrate the major part of the right upper lung lobe, posteriorly paravertebral intercostal spaces, and laterally the 5th rib. Involvement of the diaphragm and parietal pleura from the 7th to the 12th rib by numerous metastatic masses was also evident. The tumor was posteriorly paravertebrally separated from the tumor infiltrated thoracic wall. In addition to right upper lung lobectomy and resection of a segment of the 5th rib, numerous metastatic masses were excochleated from the parietal pleura and diaphragm, and the mass excised from the diaphragm was referred for histopathologic analysis.

Gross pathomorphologic examination of the resected right upper lung lobe revealed that the lobe was for the largest part permeated with a grayish-white soft tumor, measuring 14x11x8 cm with foci of intratumorous hemorrhage. Histologic examination showed a small cell tumor, and immunohistochemical findings positive for NSE and CD 99 revealed an Askin's tumor. The tumor tissue identical to that of the primary tumor involved the resected section of the 5th rib as well as the adjacent connective tissue and thoracic wall musculature along with an infiltrate resected from the diaphragm. No tumor tissue was found in the mediastinal lymph node.

The postoperative course was satisfactory. Postoperatively, two masses developed in the soft tissues of the occipital right and parietal left region of the head. Skull radiography showed no pathologic changes. Fine needle aspiration biopsy of the masses revealed poorly preserved cells of a malignant metastatic neoplasm with low-grade differentiation, and metastases of PNET were inferred. The patient was transferred to oncology ward for further chemotherapy and radiotherapy. Magnetic resonance tomography performed at that point supported osteolytic changes

in the thoracic and lumbar spine with metastatic infiltration of the spinal canal. The patient received telecobalt irradiation therapy to the spine, and later to the thorax for metastatic lesions. She was also given cytostatic polychemotherapy consisting of three cycles of vincristine, adriamycin and cyclophosphamide. After the third cycle of chemotherapy the patient exhibited disease progression and development of multiple metastases, and chemotherapy was withdrawn for a markedly deteriorated general condition. The patient died seven months after the onset of the disease symptoms.

Discussion

Askin's tumor typically involves soft tissues of the thoracic wall and paravertebral structures. It rarely affects the pulmonary parenchyma, and it seems to most commonly arise from the intercostal nerves^{5,13}. The differential diagnosis of Askin's tumor includes Ewing's sarcoma, rhabdomyosarcoma, neuroblastoma and lymphoma², whereas some other primary or secondary tumors of the thoracic wall are less frequently considered. Askin's tumor is occasionally observed as a secondary neoplasm, after the treatment for acute lymphoblastic leukemia and complete remission of Hodgkin's disease¹³. For the diagnosis of Askin's tumor, certain criteria should be met: localization in the thoracic region, typical histomorphologic characteristics, and specific immunohistochemical markers¹³. In our patient, all these preconditions were met.

Clinical manifestations are relatively nonspecific. Pain in the thoracic wall, which may additionally be deformed by the tumor mass, seems to be the most common symptom associated with Askin's tumor. Further features would include subfebrile or high temperature, dyspnea, nonproductive cough, weight loss, pleural effusion, therapy resistant pneumonia, hemoptysis, hoarseness, and Horner's syndrome^{2,8,13,14}. The clinical manifestations presented in our patient were also nonspecific. Incidentally discovered Askin's tumors have also been reported in the literature^{15,16}.

Conventional radiography usually shows a mass of various size accompanied by calcifications, erosions of the ribs, pleural effusions, and even pneumothorax^{13,14}. On CT scans heterogeneity is noticed particularly in large tumors due to the areas of necrosis and hemorrhage as well as infiltrations of the thoracic wall and rib destruction¹³. In addition, small pulmonary metastases from this tumor are also detectable on CT. Magnetic resonance tomography is not necessary, and should be resorted to when an infiltration of the thoracic wall is suspected. It has proven useful

in the visualization of an extrathoracic disease¹⁷. Polymorphism of the tumor and infiltration of the thoracic wall were also observed in our patient.

Histologically, Askin's tumor is characterized by invasive growth, small round cells with a hyperchromatic nucleus, and sometimes a weakly PAS-positive cytoplasm^{4,13}. Our patient also exhibited a cytoplasm weakly positive for PAS. The cytoplasm was scanty, the nucleus-plasma quotient was high, and multiple prominent nucleoli as well as sporadic pseudorosettes were revealed¹³. An accurate histologic diagnosis requires immunohistochemistry. NSE appears to be an important marker. Although immunohistochemistry tests may not necessarily be always positive for NSE, other neural markers such as chromogranin and synaptophysin may also confirm a neural phenotype^{6,13}. Some authors have observed NSE in 95%-100% of these patients⁵. Immunohistochemically, our patient showed tumor cells diffusely positive for NSE, focally positive for vimentin, and membranous positivity for CD 99.

Late dissemination despite a local finding was described by Askin as being characteristic of this tumor⁴. Some authors found no distant metastases at the time of diagnosis in more than a half of patients¹. The finding of distant metastases at initial diagnosis is an exception rather than a rule^{4,14}. The most usual sites of dissemination include the bones, bone marrow, lungs, liver, lymph nodes and spleen, and multiple metastases are present in one third of patients².

A multimodal approach, which consists of radical surgical resection, chemotherapy and irradiation is advocated for the treatment of this tumor, however, there has been no unique scheme so far^{14,15,18,19}. The majority of authors support resection because this tumor shows a significant propensity towards local recurrences^{4,8,13}. Complete resection appears to be superior to other modalities of surgical treatment¹⁹. Multiple resections for recurring Askin's tumors have been reported in the literature¹⁸. Neoadjuvant therapy, which seems to improve resectability, is proposed^{1,2,8,13,20}. In all instances postoperative chemotherapy and radiotherapy are mandatory due to micrometastases and tendency to recurrences. There is no unique scheme for chemotherapy. Because of resemblance to Ewing's sarcoma, the analogous therapeutic scheme is followed. More intensive therapy is advocated¹³.

In our patient, the multimodal approach to the treatment was also chosen. The major part of the primary tumor and metastases were surgically removed, and after postoperative recovery palliative irradiation telecobalt therapy in combination with cytostatic therapy was administered.

The prognosis of Askin's tumor is very poor in spite of improvements that have been achieved in therapy over the last twenty years. Variable data on the average survival rates have been reported. The 2-year survival rate is reported to be 28% to 38%, and the 6-year rate is 14% to 17%⁶. An average survival of 8 and 18 months has been reported by some authors^{4,5}. Lethal outcome within one year of the diagnosis has been documented in numerous reports and small studies^{13,14}. Our patient also died seven months of the first manifestation of symptoms. The presence of metastases at the time of diagnosis is considered to be a highly unfavorable prognostic factor⁸.

References

1. CHRISTIANSEN S, SEMIK M, DOCKHORN-DWORNICZAK B, ROTKER J, THOMAS M, SCHMIDT C *et al.* Diagnosis, treatment and outcome of patients with Askin tumors. *Thorac Cardiovasc Surg* 2000;48:311-5.
2. HAGE R, DUURKENS VAM, SELDENRIJK CA, BRUTEL de la RIVIÈRE, SWIETEN HA, van den BOSCH JMM. Primitive neuroectodermal tumor: report of two cases and review of the literature. *J Thorac Cardiovasc Surg* 2002;124:833-6.
3. DRINGS P, HASSE J, HERMANEK P, WAGNER G. Klassifikation maligner Thoraxtumoren. Lunge. Pleura. Mediastinum. Berlin, Heidelberg: Springer-Verlag 2003:194.
4. ASKIN FB, ROSAI J, SIBLEY RK, DEHNER LP, McALISTER WH. Malignant small cell tumor of the thoracopulmonary region in childhood: a distinctive clinicopathologic entity of uncertain histogenesis. *Cancer* 1979; 43:2438-51.
5. LINNOILARI, TSOKS M, TIRCHE TJ, MARANGOS PJ, CANDRARS. Evidence for neural origin and PAS-positive variants of the malignant small cell tumor of thoracopulmonary region ('Askin tumor'). *Am J Surg Pathol* 1986;10:124-33.
6. CONTESSO G, LLOMBART-BOSCH A, TERRIER Ph, PEYDRO-OLAYA A, HENRY-AMAR M, OBERLIN O *et al.* Does malignant small round cell tumor of the thoracopulmonary region (Askin tumor) constitute a clinicopathologic entity? *Cancer* 1992;69:1012-20.
7. SCHMIDT D, HERRMANN C, JÜRGENS H, HARMS D. Malignant peripheral neuroectodermal tumor and its necessary distinction from Ewing's sarcoma. *Cancer* 1991;68:2251-9.
8. TAKAHASHI K, DAMBARA T, UESKUSA T, NUKIWA T, KIRA S. Massive chest wall tumor diagnosed as Askin tumor. Successful treatment by intensive combined modality therapy in an adult. *Chest* 1993;104:287-8.
9. KHONG PL, CHAN GC, SHEK TW, TAM PK, CHAN FL. Imaging of peripheral PNET: common and uncommon locations. *Clin Radiol* 2002;57:272-7.
10. VIRANI MJ, JAIN S. Primary intraspinal primitive neuroectodermal tumor (PNET): a rare occurrence. *Neurol India* 2002;50:75-80.

11. HYUN CB, LEEYR, BEMILLER TA. Metastatic peripheral primitive neuroectodermal tumor (PNET) masquerading as liver abscess: a case report of liver metastasis in orbital PNET. *J Clin Gastroenterol* 2002;35:93-7.
12. ADAIR A, HARRIS SA, COPPEN MJ, HURLEY PR. Extraskelital Ewing's sarcoma of the small bowel: case report and literature review. *J R Coll Surg Edinb* 2001;46:372-4.
13. PROMNITZ S, PETRI F, SCHULZ HJ, GELLERT K. Der Askin-Tumor – eine Rarität. Ein Fallbericht mit Einflüssen der Literatur. (Askin's tumor – a rare entity. Case report with influences from the literature) *Pneumologie* 1999;53:393-9.
14. SARKAR MR, BAHR R. Der Askin Tumor. (The Askin tumor) *Chirurg* 1992;63:973-6.
15. TAKANAMI I, IMAMURA T. The treatment of Askin tumor: results of two cases. *J Thorac Cardiovasc Surg* 2000;123:391-2.
16. BRUNELLIA, AL REFAI M, FIANCHINI A. Malignant small cell (Askin) tumor of the thoracopulmonary region originating from the phrenic nerve. *J Thorac Cardiovasc Surg* 1999;118:373-4.
17. BURGE HJ, NOVOTNY DB, SCHIEBLER ML, DELANY DJ, McCARTNEY WH. MRI of Askin's tumor. Case report at 1,5T. *Chest* 1990; 97:1252-4.
18. TAKANAMI I, IMAMURA T, NARUKE M, KODAIRA S. Long-term survival after repeated resections of Askin tumor recurrences. *Eur J Cardiothorac Surg* 1998;13:313-5.
19. HARVEY JC, BERGLAND R, PISCH J, KRISHNAMACHARI VT, REICH H, MALAMUD S *et al.* Superior results with complete resection of Askin's tumor. *Semin Surg Oncol* 1993;9:156-9.
20. VERONESI G, SPAGGIARI L, De PAS T, SOLLI PG, De BRAUD F, CATALANO GP *et al.* Preoperative chemotherapy is essential for conservative surgery of Askin tumors. *J Thorac Cardiovasc Surg* 2003;125:428-9.

Sažetak

ASKINOV TUMOR – RIJEDAK TUMOR PRSIŠTA I PLUĆA

A. Bekić, M. Mehulić, M. Gorečan, S. Kukulj, D. Krmptić i M. Veir

Askinov tumor je maligni tumor malih okruglih stanica koji zahvaća područje prsnoga koša i pluća. Zbog njegovog neuroektodermalnog podrijetla poznat je i kao primitivni neuroektodermalni tumor. Ovaj rijetko viđeni i agresivni maligni tumor najčešće se javlja u djece i mlađih odraslih osoba. Simptomi i klinički izgled, kao i radiomorfološke nenormalnosti su nespecifične. Stoga je teško postaviti točnu dijagnozu Askinova tumora, pa su histološki i imunohistološki nalazi vrlo važni. Od ključnog je značenja imunohistološko bojenje na specifičan biljeg za neuron specifičnu enolazu. Uz to, Askinov tumor ima histološka obilježja slična Ewingovu tumoru smještenom u kostima, što ukazuje na to da pripada skupini Ewingovih tumora. Terapijski pristup je višestruk, npr. kirurško odstranjenje, kemoterapija i zračenje. Sveukupna je prognoza loša. Namjera ovoga prikaza je ukazati na ovaj neuobičajen tumor prsnoga koša i pluća. Opisana je 23-godišnja bolesnica s golemom tumorskom masom u desnom dijelu prsnoga koša i imunohistološkim nalazima kirurškog uzorka znakovitima za Askinov tumor.

Ključne riječi: *Plućne neoplazme – patologija; Plućne neoplazme – histologija; Plućne neoplazme – dijagnostika; Prikaz slučaja*