

ESOPHAGEAL HEMANGIOPERICYTOMA OR HEMANGIOPERICYTOMA-LIKE TUMOR: A CASE REPORT AND REVIEW OF THE LITERATURE

Drinko Baličević¹, Irena Novosel², Davor Tomas¹, Davor Hrabar³, Ahmed Pirkić¹ and Mladen Belicza¹

¹Ljudevit Jurak University Department of Pathology, Sestre milosrdnice University Hospital, Zagreb; ²Department of Pathology, Dr. Ivo Pedišić County Hospital, Sisak; ³Department of Gastroenterology, Sestre milosrdnice University Hospital, Zagreb, Croatia

SUMMARY – Hemangiopericytoma is a rare malignant vascular tumor deriving from pericytes. It usually occurs in the extremities and retroperitoneum, and extremely rarely in the gastrointestinal tract. A case of hemangiopericytoma in the gastroesophageal region is reported. A 56-year-old man was treated with H₂-receptor antagonist for dyspeptic symptoms that had occurred three months before. Therapy failed to prove successful and gastroendoscopy was performed in March 2001 to reveal slightly reddish ventricular mucosa with normal rugal folds and a sessile, polypoid, grayish mass of rough surface located at the gastroesophageal junction. Histopathologic examination of polypoid mass samples revealed a vascular tumor covered with squamous epithelium. The hallmarks of the tumor were numerous branching, slit-like capillary channels with 'staghorn' appearance, and large gaping sinusoidal spaces enclosed within nests of ovoid cells. Vascular invasion, mitotic activity, giant cells and necrosis were not found. Immunohistochemical analysis showed diffuse and strong reactivity for vimentin and focal, low or moderate reactivity for actin, S-100 and smooth muscle actin. Proliferation index measured by PCNA and Ki-67 ranged from 2% to 13% (median 11.2%) and from 5% to 18% (median 7.6%), respectively. A diagnosis of hemangiopericytoma with low malignant potential was made. Almost two years of the intervention, the patient is alive and free from any signs of tumor spread.

Key words: *Esophageal neoplasms – pathology; Hemangiopericytoma – pathology; Hemangiopericytoma – immunohistochemistry*

Introduction

Hemangiopericytoma (HP) is a rare malignant vascular tumor deriving from Zimmermann's pericytes¹. It is almost always a solitary and solid tumor with smooth surface, its color ranging from grayish-white to reddish-brown. In three fourths of cases, the tumor is well circumscribed and encapsulated. In spite of that, surgical excision may be difficult because of profuse bleeding, and re-exploration is occasionally needed. HP metastasizes to the lungs, bone and liver in approximately 50% of patients. It is a tumor of adults, median age 45, and

rarely affects infants and children. The tumor shows an equal sex involvement^{1,2}.

HP may occur as a slowly growing, deep seated, painless mass at any anatomic site, however, lower extremities, pelvic fossa, retroperitoneum, head and neck, trunk and upper extremities are most commonly affected. It can also be found in subcutaneous tissue. Rare cases of lipomatous HP, meningeal HP, HP of the nasal passages and paranasal sinuses, orbital HP, and HP of miscellaneous sites are on record^{1,2}. HP is extremely rare in the gastrointestinal tract, and only three cases of esophageal HP have been reported in recent literature³⁻⁵. The most common localization of HP in the gastrointestinal tract was stomach, and only few isolated cases of ileum, colon and rectum involvement have been described⁶⁻¹².

Correspondence to: *Drinko Baličević, M.D., Ph.D.*, Ljudevit Jurak University Department of Pathology, Sestre milosrdnice University Hospital, Vinogradska c. 29, HR-10000 Zagreb, Croatia

Received March 5, 2003, accepted in revised form May 28, 2004

HP was first described and named by Stout and Murray, who also postulated its origin from pericytes¹³. Pericytes were first identified by Rouget in 1873 and further defined by Zimmermann in 1923. Pericytes are contractile, arborizing cells arranged ubiquitously along capillaries and venules, and encircle the vasculature. Pericytes are thought to represent modified smooth muscle cells or resting mesenchymal stem cells capable of undergoing myoid, fibrohistiocytic and endothelial differentiation. These cells have no readily identifiable light microscopic and immunohistochemical features but are recognized ultrastructurally by their topographic relation to small blood vessels and close association with the endothelial basal lamina^{1,2,13}.

Stout has reported on a series of 25 cases seven years after the first description of HP⁵. In spite of the solidified histopathology of the tumor, established in 1955, the controversy about the true existence of HP still exists and it seems that with the extensive use of immunohistochemistry it is becoming even more doubtful. The current approach applied by Stout and Enzinger is primarily to exclude any other diagnosis before HP is confirmed^{1,5}.

The diagnosis of HP is traditionally based on a microscopic pattern characterized by the branching appearance of small and large vessels. This vascular pattern can be seen in a variety of other benign and malignant tumors, and may lead directly to a suggestion that HP does not exist as an entity^{1,2,5}.

Grossly, HP is a solitary, well to fairly well circumscribed mass covered by a thin vascular pseudocapsule measuring 4-8 cm in diameter. On cut section, the color ranges from gray-white to red-brown, with a variable number of dilated vascular spaces. Hemorrhagic areas and cystic degeneration are frequently observed. Necrosis is common in

malignant forms of HP. The diagnosis of classic HP depends on identification of the typical architectural pattern in association with a population of relatively bland mesenchymal cells that display no discernible differentiation under the light microscope. Characteristically, the tumor consists of tightly packed round to fusiform cells with indistinct cytoplasmic borders that are arranged around the elaborate vasculature. The ramifying vascular network exhibits striking caliber variation^{1,2,5,13}.

The diagnosis of malignant HP is sometimes problematic. A combination of mitotic activity, cellularity, hemorrhage and necrosis is important to estimate malignancy^{1,2,5}. Recent studies recommend proliferation index as a standard procedure to demonstrate malignancy in HP^{14,15}.

Patient and Methods

Patient

A 56-year-old man was treated with H2-receptor antagonist for dyspeptic symptoms that had occurred three months before. Therapy failed to prove successful, and gastroendoscopy was performed in March 2001 to reveal slightly reddish ventricular mucosa with normal rugal folds and a sessile, polypoid, grayish mass of rough surface located at the gastroesophageal junction. During the intervention, biopsy of the gastric mucosa and polypectomy were performed. Control gastroscopy showed no residual pathologic changes.

Methods

Three gastric mucosa samples and five polypoid specimens from the gastroesophageal region, measuring up to 3 mm were obtained for histopathologic analysis. The specimens were fixed in 10% buffered formaldehyde, paraffin embedded, cut at 5-mm thickness, and routinely stained with hematoxylin and eosin. The method of Giemsa staining was used to determine colonization with *Helicobacter pylori*. Gomori method and immunohistochemistry were used to analyze specimens from the gastroesophageal region. Deparaffinization and immunohistochemical staining were performed following the Microwave Streptavidin ImmunoPeroxidase (MSIP) protocol on a DAKO TechMate™ Horizon automated immunostainer. We used primary antibodies to epithelial membrane antigen (EMA), S-100, smooth muscle actin (SMA), actin, CD34, pancytokeratin, Factor VIII, vimentin, CD-117, proliferating cell nuclear antigen (PCNA), and Ki-67 (Table 1). Appropriate positive and negative controls were used throughout

Table 1. Antibody source and dilution

| Antibody | Clone | Manufacturer | Dilution |
|-----------------|---------|--------------|----------|
| EMA | E29 | Dako | 1:100 |
| S-100 | Z0311 | Dako | 1:200 |
| Actin | 1A4 | Dako | 1:50 |
| (smooth muscle) | | | |
| Actin | HHF35 | Dako | 1:75 |
| CD34 | BI-3C5 | Dako | 1:50 |
| Pancytokeratin | AE1/AE3 | Dako | 1:100 |
| Factor VIII | F8/86 | Dako | 1:50 |
| Vimentin | Vim 3B4 | Dako | 1:50 |
| CD-117 | A4502 | Dako | 1:400 |
| PCNA | PC10 | Dako | 1:200 |
| Ki-67 | Ki-S5 | Dako | 1:50 |

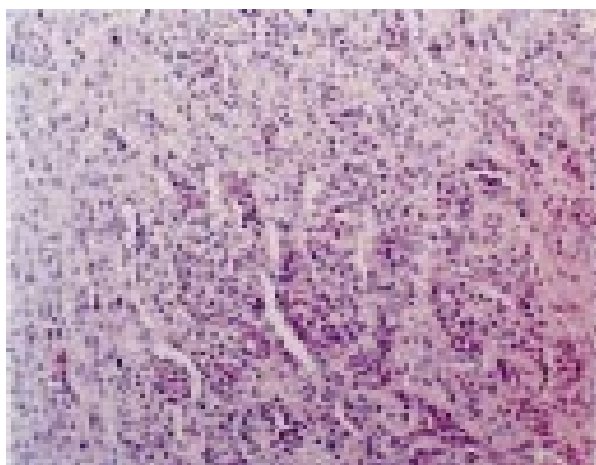


Fig. 1. Hemangiopericytoma (H&E, X200). Numerous small and large branching vessels surrounded by nests and cords of tumor cells.

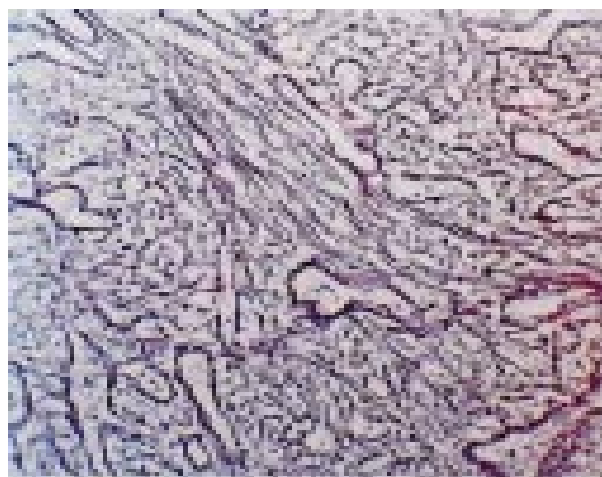


Fig. 2. Hemangiopericytoma (Gomori, X200). Gomori method showed abundant reticulin fibers outlining vessels and forming a meshwork around individual tumor cells.

the analysis. Mitotic activity and proliferation index were counted under high power magnification (X400).

Results

Histopathology

Histopathologic examination of the gastric mucosa confirmed chronic gastritis with moderate colonization with *Helicobacter pylori*, whereas examination of polypoid specimens from the gastroesophageal region revealed a vascular tumor covered with squamous epithelium. The hallmarks of the tumor were numerous branching, slit-like capillary channels with a 'staghorn' appearance, and large gaping sinusoidal spaces enclosed within nests of ovoid cells. These cells formed a distinctly tufted, woven pattern (Fig. 1). Gomori method showed abundant reticulin fibers outlining the vessels and forming an intricate meshwork around individual tumor cells (Fig. 2). The tumor showed a predominantly solid pattern consisting of moderately polymorphic cells without mitotic activity. Vascular invasion, giant cells and necrosis were not found.

Table 2. Immunohistochemistry results

| Antibody | Vimentin | EMA | CK | S-100 | SMA | Actin | CD34 | CD-117 | Factor VIII |
|----------|----------|-----|----|-------|-----|-------|------|--------|-------------|
| Reaction | +++ | - | - | + | + | ++ | - | - | - |

(-) negative reaction;

(+) mild and focal reaction;

(++) moderate reaction;

(+++) diffuse and strong reaction

Immunohistochemistry

Immunohistochemical analysis showed diffuse and strong reactivity for vimentin (Fig. 3) and focal, low or moderate reactivity for actin, S-100 and SMA. Immunoreactivity for pancytokeratin, EMA, CD-117 and Factor VIII

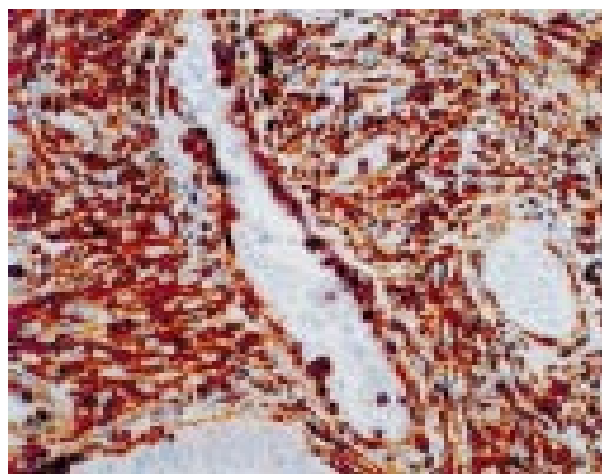


Fig. 3. Hemangiopericytoma (vimentin, X400). Tumor cells were strongly positive for vimentin.

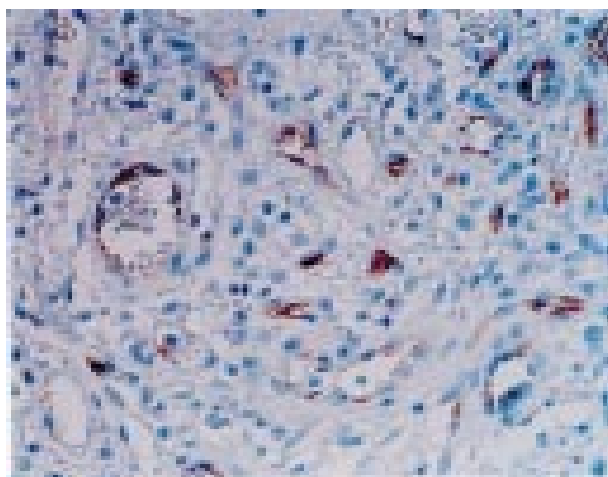


Fig. 4. Hemangiopericytoma (CD34, X400). Immunoreaction to CD34 was only observed in vessels.

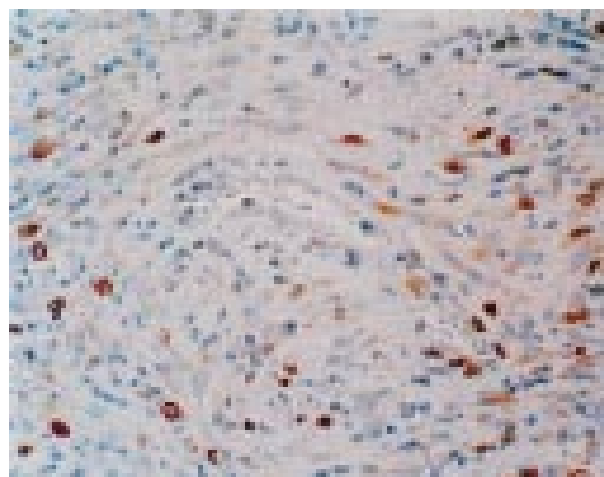


Fig. 5. Hemangiopericytoma (PCNA, X400). Proliferation index measured by PCNA ranged between 2% and 13%.

was negative. CD34 was only positive in endothelial cells (Table 2, Fig. 4). Proliferation index was analyzed in ten different fields under high magnification (X400). The proliferation index measured by PCNA and Ki-67 ranged from 2% to 13% (median 11.2%) and from 5% to 18% (median 7.6%), respectively (Table 3, Fig. 5).

Discussion

Primary mesenchymal tumors of the esophagus, and especially HP, are rare^{1,2}. To our knowledge, only three cases of primary esophageal HP have been reported in the English-language medical literature³⁻⁵. Also, HP rarely affects other parts of the gastrointestinal tract. In recent literature, 21 cases of HP in the stomach, four in the ileum and jejunum, three in the colon and only one in the rectum have been reported⁶⁻¹². Most of these cases were accompanied by unexpected and unusual metabolic and even obscure symptoms mimicking other clinical and histopathologic entities^{16,17}.

HP is an uncommon tumor with a histologic pattern similar to many other tumors, and the diagnosis of HP is usually based on exclusion^{1,2,5}. The following morphologic features should be evaluated for diagnostic purposes: vasculature, histologic pattern (solid, myxoid, trabecular,

alveolar), and features that correlate with aggressive behavior such as cellular pleomorphism, necrosis, mitotic activity, appearance of giant cells, and recently described proliferation index^{1,2,5-7,14,15}.

Necrosis is more frequent in recurring or metastasizing HP. Together with mitotic figures, necrosis is the most reliable histologic criterion for predicting malignancy or suggesting an uncertain biologic potential^{1,2}.

The staghorn or outlet-like configuration of vessels is the most prominent histologic finding. Dilated and branching vessels communicate with small or minute vessels that may be partly compressed and obscured by the surrounding cellular proliferation. Broad zones of hyalinization are much less common in HP than in solitary fibrous tumors (SFT). Focal spindle cell areas may be present but are never arranged in long bundles or fascicles as in SFT. Focal solid cellular area or focal palisading reminiscent of a neural tumor may be present. Pericytes are considered to be pluripotential cells. Abundant stromal collagen separating tumor cells could be the consequence of the process of repair of necrotic regions found in the tumor, or could be attributed to infarction, especially if the tumor is pedunculated or intraluminal^{7,18,19}.

Hypoglycemia and obscure clinical symptoms have been noted in association with both HP and SFT, particularly if localized in the pelvis and retroperitoneum. These tumors are often large and slow growing. The symptoms may even require glucose infusion and abate with tumor removal^{16,17}. They are mediated through the production of insulin-like growth factors (IGFs) by the tumor. Interestingly, IGFs and IGF receptor (IGF-R) can be identified

Table 3. Proliferation indices

| PCNA | Ki-67 |
|--------------------------|-------------------------|
| 5%-18% (median 11.2%) | 2%-13% (median 7.6%) |

in tumor cells even in the absence of clinical hypoglycemia. IGF-IR belongs to the family of transmembrane tyrosine kinase receptors. Its absolute requirement for the establishment and maintenance of the transformed phenotype proves its central role in the mechanism of transformation. In addition to these, IGFs stimulate tumor cell proliferation through an autocrine loop that can be announced when the receptors are inactivated. Therefore, IGF and especially IGF-IR could be responsible not only for malignant transformation but also for hypoglycemia in some patients¹⁰⁻²³. Our patient was without symptoms associated with hypoglycemia, and glucose level in peripheral blood was normal.

The exact genetic background of malignant HP is still unknown, although chromosome 12 has been most often implicated^{1,2}. Pavelić *et al.* report on progressive accumulation of multiple genetic lesions in the development of HP, stressing the activation of *myc*, *fos*, *jun*, *ras*, IGF1, IGF-II and IGF-IR genes, and simultaneous inactivation of the p53 gene²⁰⁻²².

The existence of hemangiopericytoma as a distinct tumor entity remains a controversial concept despite all advances in immunohistochemistry. Table 4 shows the results of immunohistochemical staining of HP in several recent studies^{14,24-27}.

The immunohistochemical analysis recommended by Enzinger and Stout includes vimentin, desmin, actin, CD34, CD31 and Factor VIII^{1,5,7}. Tumor cells are usually

immunoreactive for vimentin, whereas actin and desmin are only focally present. CD34 is positive in approximately two thirds of HP cases, which is less than in SFT. Vascular antigens are absent, except for endothelial cells lining the vascular spaces^{1,5,7}. Enzinger's panel of immunohistochemistry tests to confirm HP is a standard basis, which several studies tried to improve with CD34 and introduction of proliferative markers (PCNA, MIB, Ki-67) in order to indicate the aggressiveness of HP. The significance of CD34 is still unclear^{28,29}. Middleton *et al.* used CD31, CD34, vimentin, actin, cytokeratin, S-100 and SMA in a study including 17 cases of HP. The study showed uniform reactivity for CD34 and vimentin, whereas CD31, cytokeratin, CD31 and S-100 showed uniformly negative results. Actin and SMA were focally positive in one case each¹⁴. Saleh and Haapaniemi used vimentin, cytokeratin, CD34, Factor VIII, S-100 and HHF35. Immunoreactivity was recorded for vimentin, CD34 and HHF35, whereas other markers showed no positive reaction²⁴. Flores-Stadler *et al.* additionally used desmin, alpha₁-antitrypsin and Factor XIIa, of which only desmin showed clearly negative reaction²⁵. In their study of four tumors, Folpe *et al.* recorded positive immunoreactivity for Factor XIIa and collagen IV, whereas CD34 and SMA were positive in only two cases, and the reaction for desmin, actin and S-100 was negative in all cases²⁶. Of all authors found in the literature, Guillou *et al.* used the most extensive immunohistochemistry panel. Their report of 13 cases shows interesting and

Table 4. Immunohistochemistry analysis of hemangiopericytoma reported in the literature

| Author(s) | Vimentin | Cytokeratin | CD 31 | CD 34 | Factor VIII | Desmin | Actin | S-100 | SMA | EMA | CD 117 |
|------------------------------------|----------|-------------|---------|---------|-------------|---------|---------|---------|---------|--------|---------|
| Saleh <i>et al.</i> (n=1) | + | - | | + | - | | | - | | | |
| Flores-Stadler <i>et al.</i> (n=1) | + | - | | - | - | + | | | | | |
| Middleton <i>et al.</i> (n=17) | + | - | - | + | | | + | | + | | |
| | (17/17) | (17/17) | (17/17) | (17/17) | | | (17/17) | | (17/17) | | |
| Folpe <i>et al.</i> (n=4) | | | | + | | - | - | - | + | | |
| | | | | (2/4) | | (4/4) | (4/4) | (4/4) | (2/4) | | |
| Guillou <i>et al.</i> (n=13) | + | - | - | + | - | - | - | - | - | - | - |
| | (13/13) | (13/13) | (12/12) | (10/13) | | (13/13) | (11/13) | (10/13) | (7/13) | (9/13) | (12/13) |
| | | | 1ND | | | | 1ND | | 1ND | 1ND | 1ND |

(+) positive reaction;

(-) negative reaction;

ND - not done

almost controversial results. All tumors showed immunoreactivity for vimentin, cytokeratin, CD31 and desmin. CD99 was positive in 12, bcl-2 in 7, CD34 in 10, actin in one, S-100 in 3, SMA in 5, and EMA in 4 cases. Inhibin and CD-117 were negative in all cases²⁷.

In our patient, strong reactivity was observed for vimentin, moderate for actin, and focal for SMA and S-100. CD34 was only positive in endothelial cells, whereas other study markers were negative, which is consistent with literature data^{1,14,24-27} (Table 2).

Differential diagnosis of HP is usually difficult because many other tumors, especially fibrous histiocytoma, synovial sarcoma, mesenchymal chondrosarcoma, juxtaglomerular tumors and SFT may share similar histologic and immunohistochemical patterns^{1,2}. Differential diagnosis between HP and SFT is especially difficult. In their study, Guillou *et al.* pointed to a new problem in the differential diagnosis between HP and SFT. After extensive investigation of 13 cases, which included sex, age, site, size, original pathologic diagnosis, treatment, surgical margins, follow-up, light microscopy findings, immunohistochemistry and electron microscopy findings, Guillou *et al.* concluded that lipomatous HP (L-HP) and SFT were the same etiologic but not the same pathologic entity, and considered L-HP as a variant of SFT with lipocytes²⁷.

Clinical behavior of HP is unpredictable, and the metastatic rate varies from 10% to 60% in different studies^{1,2}. Few authors have reported different criteria for assessment of HP malignancy. Enzinger and Smith claim large size (>5 cm in diameter), increased mitotic rate (≥ 4 mitoses per 10 HPF – high malignant potential; 1-3 mitoses per 10 HPF – low malignant potential), increased cellularity, presence of immature and pleomorphic tumor cells, foci of hemorrhage and necrosis as ominous signs⁷. A study conducted at Mayo Clinic connected malignant behavior with a low degree of anaplasia and 1 mitosis per 10 HPF or a moderate degree of cellular anaplasia and 2 mitoses per 20 HPF². Middleton *et al.* demonstrated that tumors with a trabecular pattern, necrosis, mitoses, vascular invasion and cellular atypia more frequently had recurrences and metastases. In the same study, proliferation index measured with MIB1 (Ki-67) was between 2% and 40%. Tumors with a more aggressive course showed higher proliferating rate (>15%) as compared with tumors without recurrence and metastases¹⁴. Similar studies have been reported by Yu *et al.*³⁰ and Kowalski *et al.*¹⁵. It seems that proliferation index correlates better with tumor behavior than mitotic index; proliferation index over 10% usually implies higher malignant potential^{14,15}. Controversially, Goldman *et al.* in their

study of 17 cases concluded that there was no appropriate method to determine malignant potential of any particular HP³¹.

Surgical excision is the treatment of choice for any tumor site. The malignant HP response to chemotherapy and radiotherapy is variable and unpredictable. The 5-year disease-free survival is about 50%. Longterm follow-up is needed because 10% of tumors recur after 5 years¹⁹.

In our patient, the median proliferation index was up to 10% measured by Ki-67, however, mitotic activity, trabecular pattern, necrosis and giant cells were not observed. Therefore, we considered this tumor as a HP with low malignant potential. Almost two years after the intervention, the patient is alive and free from any signs of tumor spread.

In conclusion, HP is not a clearly delineated entity with characteristic histologic and immunohistochemical pattern. Its diagnosis is mainly based on exclusion, and its clinical behavior is unpredictable.

References

1. ENZINGER FM. Soft tissue tumor. 4th ed. St. Louis: Mosby, 2001:1005.
2. ROSAI J. Ackermann's Surgical pathology. 8th ed. St. Louis: Mosby, 1996:2065.
3. BURKE JS, RANCHOD M. Hemangiopericytoma of the esophagus. Hum Pathol 1981;12:96-100.
4. SMITH RT, SMALL WC, MANSOUR K. Case report: hemangiopericytoma of the esophagus. Br J Radiol 1995;68:1031-3.
5. STOUT AP. Hemangiopericytoma. A study of 25 new cases. Cancer 1949;2:1027-35.
6. FISCHER JH. Hemangiopericytoma. A review of twenty cases. Can Med Assoc J 1969;83:1136-9.
7. ENZINGER FM, SMITH BM. Hemangiopericytoma. An analysis of 106 cases. Hum Pathol 1976;7:61-82.
8. OLSEN EG, WELLWOOD JM. Hemangiopericytoma of the small intestine. A report of three cases. Br J Surg 1970;57:66-9.
9. NEILY PJ, COOPER GG, O'HARA MD, McGRADY BJ. Ileal hemangiopericytoma and von Recklinghausen's disease. Br J Clin Pract 1992;46:212-3.
10. SUKHORUKOV VA, LEBEDEV NN. Hemangiopericytoma of a Meckel's diverticulum complicated by intra-abdominal hemorrhage. Khirurgiia 1988;5:131-2.
11. BALLAB, STRONG L, HASTINGS A. Malignant haemangiopericytoma of the terminal ileum presenting with peritonitis and transcoelomic metastasis. Br J Surg 1984;71:161-2.
12. LARSEN TE, CRAM RW. Hemangiopericytoma of the small bowel: a case report and review of the literature. Can J Surg 1970;13:503.
13. STOUT AP, MURRAY MR. Hemangiopericytoma. A vascular tumor featuring Zimmermann's pericytes. Ann Surg 1942;116:26-33.

14. MIDDLETON LP, DURAY PH, MERINO M. The histological spectrum of hemangiopericytoma: application of immunohistochemical analysis including proliferative markers to facilitate diagnosis and predict prognosis. *Hum Pathol* 1998;129:636-40.
15. KOWALSKI PJ, PAULINO AF. Proliferation index as a prognostic marker in hemangiopericytoma of the head and neck. *Head Neck* 2001;23:492-6.
16. ADAMS J, LODGE JPA, PARKER D. Liver transplantation for metastatic hemangiopericytoma associated with hypoglycemia. *Transplantation* 1999;67:488-9.
17. TEALE JD. Non-islet cell tumour hypoglycaemia. *Clin Endocrinol (Oxf)* 1999;51:147.
18. ENZINGER FM, KINDBLUM LG, NIELSE JM, STEINER B, SVENDSE P. Hemangiopericytoma. A clinicopathologic, angiographic and microangiopathic study. *Cancer* 1978;42:2412-27.
19. McMASTER MJ, SOULE EH, IVINS JW. Hemangiopericytoma: a clinicopathologic study and long-term follow up of 60 patients. *Cancer* 1975;36:2332.
20. PAVELIĆ K, ČABRIJAN T, HRAŠČAN R, *et al.* Molecular pathology of hemangiopericytoma accompanied by severe hypoglycemia: oncogenes, tumor suppressor genes and the insulin-like growth factor family. *J Cancer Res Clin Oncol* 1998;124:307-14.
21. PAVELIĆ K, PAVELIĆ ZP, ČABRIJAN T, KARNER I, SAMARŽIJA M, STAMBROOK P. Insulin-like growth factor family in malignant haemangiopericytoma: the expression and role of insulin-like growth factor I receptor. *J Pathol* 1999;188:69-75.
22. PAVELIĆ K, SPAVENTI Š, GLUNČIĆ V, *et al.* The expression and role of insulin-like growth factor II in malignant hemangiopericytomas. *J. Mol Med* 1999;77:865-9.
23. BASERGA R. The insulin-like growth factor I receptor. A key to tumor growth? *Cancer Res* 1995;55:249-52.
24. SALEH HA, HAAPANIEMI J. Aspiration biopsy cytology of malignant hemangiopericytoma metastatic to the lungs. Cytomorphologic and immunocytochemical study of a case. *Acta Cytol* 1997;41:1265-8.
25. FLORES-STADLER EM, CHOU P, WALTERHOUSE D, BOURSOS E, GONZALEZ-CRUSSI F. Hemangiopericytoma of the liver: immunohistochemical observations, expression of angiogenic factor, and review of literature. *J Pediatr Hematol Oncol* 1997;5:449-54.
26. FOLPE AL, DEVANEY K, WEISS S. Lipomatous hemangiopericytoma. A rare variant of hemangiopericytoma that may be confused with liposarcoma. *Am J Surg Pathol* 1999;23:1201-7.
27. GUILLOU L, GEBHARD S, COINDRE JM. Lipomatous hemangiopericytoma: a fat-containing variant of solitary fibrous tumor? Clinicopathologic, immunohistochemical, and ultrastructural analysis of a series in favor of a unifying concept. *Hum Pathol* 2000;31:1108-15.
28. TRAWEKST, KANDALAFI PL, MEHTA P, BATTIGORA H. The human hematopoietic progenitor cell antigen (CD34) in vascular neoplasia. *Am J Clin Pathol* 1991;96:25-31.
29. POBLET E, JIMENEZ-ACOSTA F, ROCAMORA A. QBEND/10 (anti-CD34 antibody) in external root sheath cells and hair tumour. *J Cutan Pathol* 1994;21:224-8.
30. YU CC, HALL PA, FLETCHER CD, *et al.* The prognostic value of immunohistochemical staining with a monoclonal antibody to proliferating cell nuclear antigen (PCNA). *Histopathology* 1991;19:29-33.
31. GOLDMAN SM, DAVIDSON AJ, NEAL J. Retroperitoneal and pelvic hemangiopericytomas. Clinical, radiologic and pathologic correlation. *Radiology* 1988;168:13-7.

Sažetak

HEMANGIOPERICITOM ILI HEMANGIOPERICITOMU NALIK TUMOR JEDNJAKA: PRIKAZ SLUČAJA I PREGLED LITERATURE

D. Baličević, I. Novosel, D. Tomas, D. Hrabar, A. Pirkić i M. Belicza

Hemangiopericitom je rijedak maligni vaskularni tumor koji potječe od pericita. Najčešće je javlja na ekstremitetima, te u području peritoneuma, a iznimno rijetko ga se nalazi u probavnom sustavu. Opisuje se slučaj hemangiopericitoma nađenog u gastroezofagusnom području. Bolesnik star 56 godina liječen je tri mjeseca antagonistima H-2 receptora zbog dispeptičnih problema. Preporučena terapija nije pokazala očekivani rezultat, pa je učinjena gastroskopija. Nađena je sesilna polipozna tvorba veličine novčića, sivkaste boje i neravne površine u gastroezofagusnom području. Histopatološki je odstranjena tvorba bila građena od razgranatih kapilarnih prostora tipa 'staghorn', okruženih gnijezdima ovalnih stanica koje su tvorile solidan uzorak. Nekroze, vaskularna invazija, velike stanice i mitoze nisu nađene. Tumorske stanice su pokazivale difuznu, izrazito pozitivnu imunoreakciju na vimentin, dok je reakcija na aktin, S-100 i glatkomišićni aktin bila žarišna i slabog intenziteta. Proliferacijska aktivnost tumora iznosila je između 2% i 13% (medijan 11,2%) mjerena pomoću PCNA, te između 5% i 18% (medijan 7,6%) mjerena pomoću Ki-67. Postavljena je dijagnoza hemangiopericitoma niskog malignog potencijala. Skoro dvije godine nakon postavljene dijagnoze bolesnik je bez znakovna bolesti.

Ključne riječi: *Neoplazme jednjaka – patologija; Hemangiopericitom – patologija; Hemangiopericitom – imunokemija*