

PREDOMINANCE OF CD4 POSITIVE BONE MARROW STROMAL CELLS IN PATIENTS WITH EARLY STAGE OF CLASSIC HODGKIN'S DISEASE MIXED CELLULARITY VARIANT

Demetrio Tamiolakis¹, Ioannis Venizelos², Athanasia Kotini³, Maria Lambropoulou⁴, Theodoros Jivannakis⁵, Anna Efthimiadou⁶, Panagiotis Boglou⁴ and Nikolas Papadopoulos⁴

¹Department of Cytology, Regional Hospital of Chania; ²Department of Pathology, Ippokration General Hospital of Salonica; ³Department of Medical Physics, Democritus University of Thrace; ⁴Department of Histology-Embryology, Democritus University of Thrace; ⁵Department of Pathology, General Hospital of Drama; ⁶Department of Physiology, Democritus University of Thrace, Greece

SUMMARY – The aim of the study was to determine the possible bone marrow involvement in patients with early stages of classic Hodgkin's disease mixed cellularity variant diagnosed by lymph node biopsy at initial presentation not responding to radiotherapy alone. The study cohort consisted of 20 patients (18 displaying B-cell genotype and two T-cell genotype) with stages I-II Hodgkin's disease according to Ann Arbor classification treated with radiotherapy alone, seven of them not responding to therapy. Southern blot hybridization using a specific EBV Bam H1W fragment probe showed the presence of EBV genomes in two patients. All 20 patients underwent iliac crest trephine biopsy and a panel of antibodies including CD45, CD20, CD4, CD8, CD45RO, CD56, CD30, ALK-1, CD-15, EMA, CD61, and CD68 was performed. A statistically significant predominance of CD45, CD45RO and CD4 positive stromal cells was found in seven patients that failed to respond to therapy (χ^2 -test: $p=0.021$, $p=0.019$ and $p=0.015$, respectively). The predominance of CD4 positive cells in the bone marrow stroma might be suggestive of involvement by Hodgkin's disease in the early stage (I-II) patients (indicating upstaging) who fail to show remission on radiotherapy alone, and could explain the abnormal cytokine production, which may contribute to diminished T-cell immunity and inefficient antitumor responses despite a vast majority of infiltrating reactive immune cells.

Key words: *Hodgkin's disease – pathology; Bone marrow – pathology; Hodgkin's disease – immunohistochemistry*

Introduction

Classic Hodgkin's disease is one of the most common types of malignant lymphomas in the western world. It is characterized by the presence of a low number of tumor cells (usually <1%) designated as Hodgkin and Reed-Sternberg (HRS) cells residing in an abundant admixture of nonmalignant cells (inflammatory cells) of different types¹. The identification of the normal cellular counterpart of HRS cells has been the focus of numerous investi-

gations in the last few decades. Immunohistologic studies have disclosed an expression of either B-cell or T-cell antigens in 20% to 40% of Hodgkin's disease cases, mostly restricted to a small proportion of Reed-Sternberg cells²⁻⁷. Attempts at detecting clonal antigen receptor rearrangements in whole tissue DNA extracts by means of Southern blot analysis or polymerase chain reaction (PCR) failed in most instances⁸⁻¹². Only when methods for single cell isolation had become available, it could be demonstrated that HRS cells harbored clonal immunoglobulin gene rearrangements with somatic hypermutations in more than 90% of Hodgkin's disease cases¹³⁻¹⁵. This suggests that most cases of classic Hodgkin's disease originate from B cells at the germinal or postgerminal center stage differentiation.

Correspondence to: *Assoc. Professor Nikolas Papadopoulos*, Democritus University of Thrace, Dragana, 68100 Alexandroupolis, Greece
E-mail: npapad@med.duth.gr

Received December 18, 2003, accepted September 22, 2004

Hodgkin's disease comprises two distinct entities: the rare nodular lymphocyte-predominant Hodgkin's disease (NLPHD) and the common classic Hodgkin's disease (cHD) form. NLPHD and cHD differ mainly in histologic features such as cytology of the tumor cells and composition of the reactive infiltrates, immunophenotypic and genetic characteristics of the tumor cells, and distribution of the neoplastic cells within the target lymph node¹⁶⁻¹⁸.

Bone marrow involvement in Hodgkin's disease is low at initial presentation (6%) in patients with stage I and II disease, and in nodular sclerosis (1%, 2% and 4%, respectively)¹⁹. The highest incidence of bone marrow involvement is found with lymphocyte depletion and mixed cellularity Hodgkin's disease^{20,21}. However, since bone marrow involvement is one of the criteria for systemic spread (stage IV), bone marrow biopsy is still an integral part of initial investigation in patients with Hodgkin's disease.

It is of interest that CD4+ T lymphocytes with T helper 2 (Th2)-like immunophenotype are the most abundant cell type in Hodgkin's lymphoma tissues²². Th2 cells produce interleukin-5 (IL-5), which primes T cells and activates eosinophils²³. Moreover, the interaction of these T cells with neoplastic cells and eosinophils also involves ligands of TNF receptors (CD30L and CD40L)²⁴. T lymphocytes as well as eosinophils transmit proliferative and antiapoptotic signals *via* these ligands to HRS cells and thereby influence tumor biology^{24,25}.

In our series, we studied the immunohistochemistry profile of bone marrow stromal cells in early stages (I-II) of classic Hodgkin's disease mixed cellularity variant treated with radiotherapy alone, in order to explain the partial response to treatment, given that the reactive lymphocytes in Hodgkin's disease involved bone marrow are predominantly CD4 positive T cells.

Material and Methods

The study population included 20 patients (16 male and four female, age range 32-72 years) with stage I-II Hodgkin's disease according to Ann Arbor criteria. In all patients, the classic Hodgkin's disease mixed cellularity variant was revealed by routine lymph node histologic and immunohistochemistry examinations. The study was approved by the regional ethics committees, an informed consent in writing was obtained from all study patients, and the study was performed in accordance with the institutional guidelines.

The genotypic profile of our Hodgkin's disease patients (cervical lymph node involvement) is shown in Table 1. In

brief, HRS cells of 18 cases harbored highly mutated rearranged *IgH* genes, whereas the remaining two cases displayed HRS cells with clonal TCR rearrangements. Southern blot hybridization using a specific EBV Bam H1W fragment probe showed the presence of EBV genomes in two cases (patients Nos. 5 and 8).

Table 1. Genotyping of classic Hodgkin's disease mixed cellularity variant (cervical lymph nodes involved)

Patient No.	Age (yrs)/Sex	Genotype
1	55/M	B
2	71/M	B
3	60/F	T
4	34/M	B
5	36/M	B
6	32/F	T
7	38/M	B
8	42/F	B
9	43/M	B
10	35/M	B
11	53/M	B
12	47/M	B
13	38/F	B
14	49/M	B
15	51/M	B
16	40/M	B
17	56/M	B
18	64/M	B
19	39/M	B
20	72/M	B

The possibility that the two Hodgkin's lymphomas with rearranged TCR genes were confused with anaplastic large cell lymphomas, which may mimic Hodgkin's disease, was excluded by their negative labeling for ALK-1, the expression of which is restricted to anaplastic large cell lymphoma^{26,27}. The antibodies recognizing megakaryocytes CD61 (Y2/51) were included to be sure that the abnormal cells really derived from Hodgkin's disease.

All study patients were treated with radiotherapy alone. Seven patients showed no remission of the disease presenting with the characteristic clinical symptoms (fever, night sweat and weight loss). Iliac crest trephine bone marrow biopsy was performed in all study subjects.

Immunohistochemistry. *Following short decalcification, bone marrow biopsy specimens were processed for routine and immunohistochemistry examination by a panel of monoclonal antibodies against CD30 (Ber-H2), CD15 (C3D1), EMA, CD45 (LCA),*

CD20 (L26), CD4, CD8, ALK-1, CD45RO (UCHL1), CD56 (NK cells), CD61 (Y2/51), and CD68 (PG-M1). Immunostaining was performed on formalin-fixed, paraffin-embedded sections employing the alkaline phosphatase antialkaline phosphatase (APAAP) technique²⁸. Paraffin-embedded sections were pretreated by pressure cooking, as described elsewhere²⁹.

The immunostained sections were examined with a X40 objective and distribution of the above listed antibodies within the cell was recorded. Every stained cell was scored as positive regardless of staining intensity. A 10x10 square calibrated grid was inserted into the eyepiece of an Olympus BX40 binocular microscope to count the number of positive cells.

Five-to-ten high power fields *per* section were examined, and at least 1000 cells were scored, depending on cellularity. The number of positive cells *per* high power field was recorded.

Results

Results are presented in Table 2.

Histology. The bone marrow appearance was hypercellular in eight, hypocellular in seven, and normocellular in the rest of five patients. Bone marrow stroma replacement by fibrous or granulomatous tissue was not observed in any of the 20 study patients.

Immunohistochemistry. The sections were examined independently by two observers, and positive cellular staining for the respective antibodies was manifested as yellow cytoplasmic granularity and/or surface membrane expres-

sion. The following findings were recorded: 1) no evidence of lymphocyte-rich Hodgkin's disease (L&H cells), mononuclear Hodgkin's disease, binocular Hodgkin's disease, or nodular sclerosis variant (lacunar cells): CD30-, CD15-, EMA-; 2) evidence for the presence of megakaryocytes: CD61+; and 3) a mild increase in the number of lymphoid cells constituting up to 20%-25% of the nucleated cell population in the bone marrow: CD45+. The T cell to B cell ratio was estimated to be from 8:1 to 9:1. The small-cell type lymphocytes, preferentially located in the center of the marrow space, were arranged either in small clusters of 2-10 lymphocytes resembling minute bunches of grapes, or in 1-2 cell thickness layers distributed in a way that we called a "streamlet like" or "Indian" like pattern. A paratrabeular pattern of localization was not considered, however, randomly reactive lymphoid follicles were observed. On immunohistochemical grounds, the lymphocytes were identified as being of T cell origin. Such a cellular arrangement was considered as a piece of evidence against lymphomatous lesion.

A predominance of CD4 expression in the bone marrow stroma was found in seven nonresponding patient-cases (Fig. 1) as differentiated from 13 cases with favorable outcome (Fig. 2). The difference was statistically significant (χ^2 -test, $p=0.015$).

Discussion

To date, there has been a common agreement that bone marrow biopsy should always be performed by trephine in all patients with newly diagnosed Hodgkin's lymphoma,

Table 2. Immunophenotyping of classic Hodgkin's disease mixed cellularity variant (bone marrow biopsy)

Immunohistochemistry (cells/mm ²)	Nonresponsive cases (n=7)	Responsive cases (n=13)	Statistical significance
CD45 (+)	68.1±20.8	45.7±15.2	p=0.021
CD45RO (+)	70.4±32.7	32.5±17.8	p=0.019
CD4 (+)	38.2± 6.4	28.9± 7.6	p=0.015
CD61 (+)	2.65±0.73	2.55±0.81	Nonsignificant
CD20 (+)	9.1± 2.7	8.9± 1.8	Nonsignificant
CD56 (+)	—	—	—
CD30 (+)	—	—	—
CD15 (+)	—	—	—
EMA (+)	—	—	—
CD68 (+)	3.12±0.38	3.21±0.79	Nonsignificant
CD8 (+)	5.68±0.96	5.85±1.08	Nonsignificant
ALK (+)	—	—	—

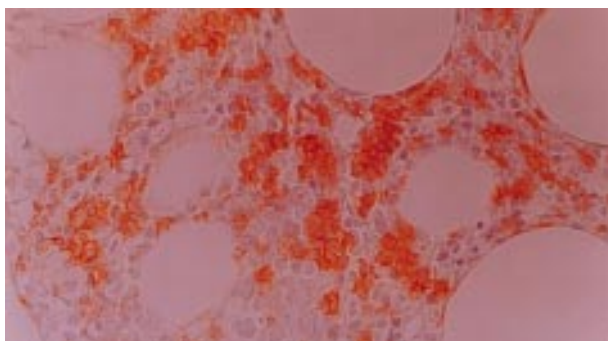


Fig. 1. Immunohistochemical expression of CD4 in bone marrow stroma of patients with stage I-II Hodgkin's disease nonresponsive to radiotherapy (strong reactivity). Immunostaining with CD4 Mab, APAAP technique; original magnification X400.

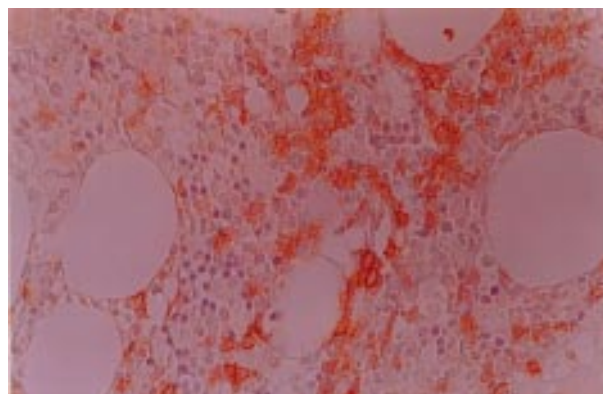


Fig. 2. Immunohistochemical expression of CD4 in bone marrow stroma of patients with stage I-II Hodgkin's disease responsive to radiotherapy (mild reactivity). Immunostaining with CD4 Mab, APAAP technique; original magnification X400.

even knowing that early clinical stages (I and II) seldom have bone marrow involvement and that bone marrow is very rarely involved in lymphocyte predominant Hodgkin's lymphoma³⁰. However, the College of American Pathologists Protocol for the Examination of Specimens from Patients with Hodgkin's Disease states that bone marrow biopsy is optional in clinical stages I-II³¹. Also, Spector *et al.*³² recommend that bone marrow biopsy be only included in staging procedure when the patient presents with fever, spleen enlargement, leukopenia and "poor histologic subgroup" (mixed cellularity and lymphocyte depleted Hodgkin's lymphoma).

The diagnostic criteria for Hodgkin's lymphoma in bone marrow have not changed essentially since the now historical clinicopathologic studies by Lukes³³ and Bartl *et al.*³⁴. The criteria differ slightly depending on whether the primary diagnosis of Hodgkin's lymphoma is just being established or the patient has already been diagnosed with Hodgkin's lymphoma at another location. The criteria are as follows:

- 1) diagnostic: typical Reed-Sternberg cells or their variants in a proper background. Mononuclear variants in a proper background are only diagnostic in patients with a previously established diagnosis;
- 2) strongly suggestive but not diagnostic: abnormally large cells that lack the nuclear features of Reed-Sternberg cells but are present in a cellular and/or fibrotic background that is characteristic of Hodgkin's lymphoma; and
- 3) suggestive: focal or diffuse fibrosis or necrosis only in a previously diagnosed patient.

Various combinations of these patterns may be seen in the same biopsy specimen or in different biopsy specimens from the same patient. In addition, amorphous eosinophilic background material may be apparent. Necrosis is occasionally detected prior to treatment³⁵, but is more common in treated patients. Granulomas are sometimes associated with infiltration, however, they also occur in the absence of bone marrow infiltration. Reticulin is increased in the areas of infiltration and collagen is often present. There may occasionally be osteolysis or osteosclerosis, whereas bone remodeling is usually observed³⁴. There is a tendency of the involvement to be quite extensive, with more than 70% of bone marrow affected, or to be minimal (less than 30% of bone marrow involved). Focal or discrete involvement may be observed as small lesions surrounded by normal hematopoietic tissue or at a paratrabecular location. With diffuse involvement, Hodgkin's lymphoma occupies the entire space between osseous trabeculae. The morphology is highly variable but usually there is a polymorphous cellular composition with lymphocytes, plasma cells, histiocytes, neutrophils and granulocytes, Reed-Sternberg cells and Hodgkin cells. The latter may be very rare and multiple biopsy sections are recommended. The hematopoietic tissue adjacent to Hodgkin's lymphoma in the bone marrow often shows nonspecific changes. There may be general hyperplasia. Hyperplasia of the granulocytic series with eosinophilia, plasmacytosis and megakaryocytic hyperplasia may be found in patients with Hodgkin's lymphoma with no evidence for bone marrow involvement. With bone marrow involved, the patient is by definition in stage IV, however, bone marrow involvement is also recognized as an unfavorable prognostic sign *per se*.

In HIV infected patients, bone marrow involvement is often the first sign of the disease. In these cases, the lymphocytic background consists predominantly of CD8 suppressor T-cells, unlike Hodgkin's disease in normal hosts, where the lymphocytes are predominantly CD4 helper T-cells³⁶.

The diagnosis of Hodgkin's lymphoma should preferentially be confirmed by immunohistochemistry (CD3, 20, 15, 45, 30 and EMA). When the initial diagnosis of Hodgkin's lymphoma is made on a trephine, biopsy of the lymph node should always be done before treatment for both confirmation of the diagnosis and for subclassification. One should not attempt to classify Hodgkin's lymphoma on the basis of bone marrow biopsy. The histology of Hodgkin's lymphoma in bone marrow and in lymph node may differ significantly, and all types of Hodgkin's lymphoma may produce the appearance of lymphocyte depletion and fibrosis in bone marrow.

As in other tissues, the main differential diagnosis in cases of Hodgkin's lymphoma includes non-Hodgkin's lymphoma, especially anaplastic large cell lymphoma³⁷, and T-cell-rich (and histocyte-rich) large B-cell lymphoma^{38,39}. Peripheral T-cell lymphoma with polymorphous cell proliferation and epithelioid histiocytes are particularly problematic⁴⁰. Rare cases of B-CLL with occasional Reed-Sternberg cells may also pose a difficulty⁴¹. The lesions should be distinguished from mastocytosis, granulomatous diseases and myelofibrosis either as a primary bone marrow disease or as fibrosis induced by x-ray or other noxae. The value of routine bone marrow biopsy for staging of Hodgkin's lymphoma is being questioned. However, if bone marrow biopsy is performed, bilateral biopsies are warranted.

In our setting, we found that bone marrow stromal cells exhibited a statistically significant ($p=0.015$) prevalence of CD4 expression in cases of stage I-II Hodgkin's disease treated with radiotherapy alone⁴² as compared with the patients responding to therapy, suggesting that the increase in CD4 might be connected with bone marrow involvement, indicating upstaging of the disease. On the other hand, our findings may be viewed as suggesting that the chemokines locally produced by T lymphocytes are implicated in the accumulation of abundant reactive infiltrates (e.g., eosinophils) in classic Hodgkin's disease and thereby influence tumor biology. Confirmation of this hypothesis would necessitate studies in large groups of patients and longer observation period including unfavorable disease outcomes.

References

- HARRIS NL, JAFFE ES, STEIN H, *et al.* A revised European-American classification of lymphoid neoplasms: a proposal from the International Lymphoma Study Group [see comments]. *Blood* 1994;84:1361-92.
- DALLENBACH FE, STEIN H. Expression of T-cell-receptor beta chain in Reed-Sternberg cells. *Lancet* 1989;2:828-30.
- FALLINI B, STEIN H, PILERI S, *et al.* Expression of lymphoid-associated antigens on Hodgkin's and Reed-Sternberg cells of Hodgkin's disease: an immunocytochemical study on lymph node cytopins using monoclonal antibodies. *Histopathology* 1987;11:1229-42.
- AGNARSSON BA, KADIN ME. The immunophenotype of Reed-Sternberg cells: a study of 50 cases of Hodgkin's disease using fixed frozen tissues. *Cancer* 1989;63:2083-7.
- KADIN ME, MURAMOTO L, SAID J. Expression of T-cell antigens on Reed-Sternberg cells in a subset of patients with nodular sclerosis and mixed cellularity Hodgkin's disease. *Am J Pathol* 1988;130:345-53.
- SCHMID C, PAN L, DISS T, ISAACSON PG. Expression of B-cell antigens by Hodgkin's and Reed-Sternberg cells. *Am J Pathol* 1991;139:701-7.
- ZUKERBERG LR, COLLINS AB, FERRY JA, HARRIS NL. Co-expression of CD15 and CD20 by Reed-Sternberg cells in Hodgkin's disease. *Am J Pathol* 1991;139:475-83.
- HERBST H, TIPPELMANN G, ANAGNOSTOPOULOS I, *et al.* Immunoglobulin and T-cell receptor gene rearrangement in Hodgkin's disease and Ki-1-positive anaplastic large cell lymphoma: dissociation between phenotype and genotype. *Leuk Res* 1989;13:103-16.
- WEISS LM, STRICKLER JG, HU E, WAMKE RA, SKLAR J. Immunoglobulin gene rearrangements in Hodgkin's disease [published erratum appears in *Hum Pathol* 1986;17:1106]. *Hum Pathol* 1986;17:1009-14.
- KNOWLES DM, NERIA A, PELICCI PG, *et al.* Immunoglobulin and T-cell receptor beta-chain gene rearrangement analysis of Hodgkin's disease: implications for lineage determination and differential diagnosis. *Proc Natl Acad Sci USA* 1986;83:7942-6.
- TAMARU J, HUMMEL M, ZEMLIN M, KALVELAGE B, STEIN H. Hodgkin's disease with a B-cell phenotype often shows a Hodgkin's disease VDJ rearrangement and somatic mutations in the VH genes. *Blood* 1994;84:708-15.
- SAATI T, GALOIN S, GRAVEL S, *et al.* IgH and TcR-gamma gene rearrangements identified in Hodgkin's disease by PCR demonstrate lack of correlation between genotype, phenotype, and Epstein-Barr virus status. *J Pathol* 1997;181:387-93.
- KUPPERS R, RAJEWSKY K, ZHAO M, *et al.* Hodgkin and Reed-Sternberg cells picked from histological sections show clonal immunoglobulin gene rearrangements and appear to be derived from B cells at various stages of development. *Proc Natl Acad Sci USA* 1994;91:10962-6.

14. HUMMEL M, ZIEMANN K, LAMMERT H, PILERI S, SABATINI E, STEIN H. Hodgkin's disease with monoclonal and polyclonal populations of Reed-Sternberg cells [see comments]. *N Engl J Med* 1995;333:901.
15. KANZLER H, KUPPERS R, HANSMANN ML, RAJEWSKY K. Hodgkin and Reed-Sternberg cells in Hodgkin's disease represent the outgrowth of a dominant tumor clone derived from (crippled) germinal center B cells. *J Exp Med* 1996;184:1495-505.
16. STEIN H, HUMMEL M, DURKOP H, FOSS HD, HERBST H. Biology of Hodgkin's disease. In: CANELLOS GP, LISTER TA, SKALAR J, eds. *The lymphomas*. Philadelphia, PA: WB Saunders, 1998:287-98.
17. MARAFIOTI T, HUMMEL M, ANAGNOSTOPOULOS I, *et al.* Origin of nodular lymphocyte-predominant Hodgkin's disease from a clonal expansion of highly mutated germinal-center B-cells. *N Engl J Med* 1997;337:453-8.
18. MARAFIOTI T, HUMMEL M, FOSS HD, *et al.* Hodgkin and Reed-Sternberg cells represent an expansion of a single clone originating from a germinal center B-cell with functional immunoglobulin gene rearrangements but defective immunoglobulin transcription. *Blood* 2000;95:1443-50.
19. FRISCH B, BARTL R. Biopsy interpretation of bone and bone marrow. In: *Hodgkin's disease (HD)*. Arnold 2nd Edition, 1999:305.
20. NEIMAN RS, ROSEN PJ, LUKES RJ. Lymphocyte-depletion Hodgkin's disease. A clinicopathologic entity. *N Engl J Med* 1973;288:751-5.
21. O'CARROLL DI, McKENNA RW, BRUNNING RD. Bone marrow manifestations of Hodgkin's disease. *Cancer* 1976;38:1717-28.
22. POPERNA S. Immunology of Hodgkin's disease. *Clin Hematol* 1996;9:447.
23. SALLUSTRO F, MacKAY CR, LANZAVECCHIA A. Selective expression of the eotaxin receptor CCR3 by human T helper 2 cells. *Science* 1997;277:2005-7.
24. PINTO A, ALDINUCCI D, GLOGHINI A, ZAGONEL V, DEGAN M, PERIN V, TODESCO M, DE IULLIS A, IMPROTA S, SACCO C, GATTEI V, GRUSS HJ, CARBONE A. The role of eosinophils in the pathobiology of Hodgkin's disease. *Ann Oncol* 1997;8:89-96.
25. PINTO A, ALDINUCCI D, GLOGHINI A, ZAGONEL V, DEGAN M, IMPROTA S, JUZBASIC S, TODESCO M, PERIN V, GATTEI V, HERRMANN F, GRUSS HJ, CARBONE A. Human eosinophils express functional CD30 ligand and stimulate proliferation of a Hodgkin's disease cell line. *Blood* 1996;88:3299-305.
26. SARRIS AH, LUTHRA R, PAPANIMITRACOPOULOU V, *et al.* Amplification of genomic DNA demonstrates the presence of the t(2;5) (p23;q35) in anaplastic large cell lymphoma but not in other non-Hodgkin's lymphomas, Hodgkin's disease, or lymphomatoid papulosis [see comments]. *Blood* 1996;88:1771-9.
27. HERBST H, ANAGNOSTOPOULOS J, HEINZE B, DURKOP H, HUMMEL M, STEIN H. ALK gene products in anaplastic large cell lymphomas and Hodgkin's disease. *Blood* 1995;86:1694-700.
28. CORDELL JL, FALINI B, ERBER WN, *et al.* Immunoenzymatic labeling of monoclonal antibodies using immune complexes of alkaline phosphatase and monoclonal anti-alkaline phosphatase (APAAP complexes). *J Histochem Cytochem* 1984;32:219-29.
29. NORTON AJ, JORDAN S, YEOMANS P. Brief, high-temperature heat denaturation (pressure cooking): a simple and effective method of antigen retrieval for routinely processed tissues. *J Pathol* 1994;173:371-9.
30. MUNKER R, HASENCLEVER D, BROSTEANU O, HILLER E, DIEHL V, for the German Hodgkin's Lymphoma Study Group. Bone marrow involvement in Hodgkin's disease. An analysis of 135 consecutive cases. *J Clin Oncol* 1995;13:403-9.
31. COMPTON CC, FERRY JA, ROSS DW. Protocol for the examination of specimens from patients with Hodgkin's disease. A basis for checklists. *Arch Pathol Lab Med* 1999;123:75-80.
32. SPECTOR N, NUCCI M, OLIVEIRA De MORAIS JC, MAIOLINO A, PORTUGAL RD, COSTA MA, PULCHERI W. Clinical factors predictive of bone marrow involvement in Hodgkin's disease. *Leuk Lymphoma* 1997;26:171-6.
33. LUKES RJ. Criteria for involvement of lymph node, bone marrow, spleen, and liver in Hodgkin's disease. *Cancer Res* 1971;31:1755-67.
34. BARTL R, FRISCH B, BURKHARDT R, HUHNS D, PAPPENBERGER R. Assessment of bone marrow histology in Hodgkin's disease: correlation with clinical factors. *Br J Haematol* 1982;51:345-60.
35. KINNEY MC, GREER JP, STEIN RS, COLLINS RD, COUSAR JB. Lymphocyte-depletion Hodgkin's disease. Histopathologic diagnosis of marrow involvement. *Am J Surg Pathol* 1986;10:219-26.
36. URGER PD, STRAUCHEN JA. Hodgkin's disease in AIDS-complex patients. Report of four cases and tissue immunologic marker studies. *Cancer* 1986;58:821-5.
37. FRIZZERA G. The distinction of Hodgkin's disease from anaplastic large cell lymphoma. *Semin Diagn Pathol* 1992;9:291-6.
38. SKINNIDER BF, CONNORS JM, GASCOYNE RD. Bone marrow involvement in T-cell-rich B-cell lymphoma. *Am J Clin Pathol* 1997;108:570-8.
39. DELABIE J, WEISENBURGER DD, KENNES C, *et al.* Histiocyte-rich B-cell lymphoma: a distinct clinicopathologic entity possibly related to lymphocyte predominance Hodgkin's disease, paragranuloma subtype. *Am J Surg Pathol* 1992;16:37-48.
40. DELABIE J, GREINER TC, WEISENBURGER DD. Concurrent lymphocyte predominance Hodgkin's disease and T-cell lymphoma. A report of three cases. *Am J Surg Pathol* 1996;20:355-62.
41. McKENNA RW. The bone marrow manifestations of Hodgkin's disease, non-Hodgkin's lymphoma and lymphoma-like disorders. In: KNOWLES DB, ed. *Neoplastic hematopathology*. Vol. 1. New York: Williams and Wilkins, 1992:1135-80.
42. MAZZAROTTO R, BOSO C, SCARZELLO G, RUBELLO D, CASARA D, AVERSA S, CHIARION-SILENI V, MONFARDINI S, SOTTI G. Radiotherapy alone in the treatment of clinical stage I-IIA, nonbulky, Hodgkin's disease: single-institution experience on 73 patients staged with lymphangiography and laparoscopy. *Am J Clin Oncol* 2000;25:149-52.

Sažetak

PREVLAST CD4 POZITIVNIH STROMALNIH STANICA KOŠTANE SRŽI U BOLESNIKA S RANIM STUPNJEM HODGKINOVE BOLESTI MIJEŠANE CELULARNOSTI

D. Tamiolakis, I. Venizelos, A. Kotini, M. Lambropoulou, Th. Jivannakis, A. Efthimiadou, P. Boglou i N. Papadopoulos

Cilj rada bio je utvrditi moguću zahvaćenost koštane srži u bolesnika s ranim stadijima klasične Hodgkinove bolesti, varijanta miješane celularnosti, dijagnosticirane biopsijom limfnog čvora, koji pri prvom dolasku nisu odgovorili na samu radioterapiju. Bolesnička skupina sastojala se je od 20 bolesnika (18 s B-staničnim genotipom i dvoje s T-staničnim genotipom) u I.-II. stadiju prema klasifikaciji iz Ann Arбора, koji su bili liječeni samo radioterapijom. Sedmero bolesnika nije odgovaralo na ovu vrst liječenja. Southern blot hibridizacija uz primjenu specifične fragmentne sonde EBV Bam H1W pokazala je prisutnost EBV genoma u dvoje bolesnika. Svih 20 bolesnika podvrgnuto je trepanacijskoj biopsiji ilijačnog grebena i provedeno je ispitivanje panelom protutijela uključujući CD45, CD20, CD4, CD8, CD45RO, CD56, CD30, ALK-1, CD-15, EMA, CD61 i CD68. U sedmero bolesnika koji nisu odgovarali na liječenje utvrđena je statistički značajna prevlast stromalnih stanica pozitivnih na CD45, CD45RO i CD4 (χ^2 -test: $p=0,021$, $p=0,019$ odnosno $p=0,015$). Prevlast stanica pozitivnih na CD4 u stromi koštane srži moglo bi ukazivati na zahvaćenost koštane srži Hodgkinovom bolešću u bolesnika s ranim stadijem (I.-II.) (tj. porast stadija) u kojih ne dolazi do remisije bolesti nakon same radioterapije, te bi moglo objasniti nenormalnu proizvodnju citokina, što možda doprinosi smanjenoj T-imunosti i nedostatnom protutumorskom odgovoru usprkos goleme većine infiltriranih reaktivnih imunih stanica.

Ključne riječi: *Hodgkinova bolest – patologija; Koštana srž – patologija; Hodgkinova bolest – imunohistokemija*