

**A CASE OF CHILDHOOD TUBERCULOSIS FROM MODERN PERIOD BURIAL FROM CRKVARI, NORTHERN CROATIA**  
**BIOARHEOLOŠKA ANALIZA DJEČJEG KOŠTANOG MATERIJALA SA NOVOVJEKOVNOG NALAZIŠTA CRKVARI, SZ SLAVONIJA**

**Željka BEDIĆ**

viši znanstveni asistent  
Hrvatska akademija znanosti i umjetnosti  
Antropološki centar  
Ante Kovačića 5, 10000 Zagreb  
zbedic@hazu.hr

Primljeno / Received: 15. 10. 2015.  
Prihvaćeno / Accepted: 4. 12. 2015.  
Izvorni znanstveni rad  
Original scientific paper  
UDK / UDC: [902.2+572] (497.5Crkvari)"20"  
611.9

**Vlasta VYROUBAL**

viši znanstveni asistent  
Hrvatska akademija znanosti i umjetnosti  
Antropološki centar  
Ante Kovačića 5, 10000 Zagreb  
vyroubal@hazu.hr

**Tatjana TKALČEC**

znanstveni suradnik  
Institut za arheologiju  
Ul. Ljudevita Gaja 32, 10000 Zagreb  
ttkalcec@iarh.hr

**Mario ŠLAUS**

znanstveni savjetnik  
Hrvatska akademija znanosti i umjetnosti  
Antropološki centar  
Ante Kovačića 5, 10000 Zagreb  
mario.slaus@zg.htnet.hr

**SUMMARY**

*This paper presents the results of a comprehensive bioarchaeological analysis of skeletal remains from grave 398 from the Medieval and Modern Period site Crkvari located in Slavonia, Croatia. Age-at-death of the individual recovered from this grave, determined by standard anthropological criteria, is between 7.5 and 8.5 years. Detailed paleopathological analyses suggest the presence of infectious disease. The most noticeable changes are observed on the vertebral column and ribs and include: resorption and prolapse of the corpus of the 3rd to 9th thoracic vertebrae, ankylosis of vertebral arches from the 7th cervical to the 7th thoracic vertebrae, Pott's gibbus from the 2nd thoracic to 7th thoracic vertebrae, complete resorption of the bodies of the 3rd to 5th thoracic vertebrae, porotic and osteolytic lesions on the neural arches of the 12th thoracic, 1st and 2nd lumbar vertebrae, marked flattening of the sternal ends of the 4th left and 8th right ribs, and swelling of the vertebrae*

*ends of the three left and three right ribs. After excluding other non-infectious and infectious diseases, the most likely cause of these changes is tuberculous spondylitis which, along with joint involvement and osteomyelitis, is one of the most common manifestations of skeletal tuberculosis in children. Archaeological analysis suggests that this child lived during the 17th century, at the start of an epidemic of tuberculosis that affected Europe and coincided with the revival of trade routes and a flourishing of craft and commerce activities that increased in the area around Crkvari. These activities may have facilitated the spread of infectious diseases including tuberculosis.*

**Key words:** Crkvari, 17<sup>th</sup> century, child tuberculosis, Pott's gibbus

**Ključne riječi:** Crkvari, 17. stoljeće, dječja tuberkuloza, Pottov gibus (grba)

## INTRODUCTION

Tuberculosis is an infectious disease caused by *Mycobacterium tuberculosis* that is most often transmitted through the respiratory system. The primary infection usually starts in the lungs, after which it disseminates by the blood stream to other parts of the body – the kidneys, brain and bones. The spine is the most common (in approximately 40% of cases) affected bone element.<sup>1</sup> In most cases of spinal tuberculosis an abscess erodes the anterior part of the vertebral body and the intervertebral disc, ultimately resulting in the destruction of the vertebral body and the development of the characteristic gibbus of Pott's disease. In pre-antibiotic times this deformity was present in nearly 60% of cases involving spinal tuberculosis.<sup>2</sup> Until now just a few cases of tuberculosis have been reported in Croatian archaeological series.<sup>3</sup> Although numerous cases of tuberculosis affecting juveniles have been described in the international scientific literature,<sup>4</sup> the only published case of subadult tuberculosis from Croatia is the skeleton of a subadult aged between 10 and 12 years from the archaeological site of St. Martin's Square in Umag dated from the 9th to the end of the 17th century.<sup>5</sup> The paper describes destructive lesions on the vertebrae and sacrum and porosity on long and flat bones both of which are consistent

<sup>1</sup> AUFDERHEIDE, Arthur C. and RODRÍGEZ-MARTÍN Conrado. *The Cambridge Encyclopedia of Human Paleopathology*, Cambridge, 1998., 121.

<sup>2</sup> REINHART, Max. Die Fälle von Spondylitis Tuberculosa in der Aargauischen Heilstätte Barmelweid aus den Jahren 1912-1930, *Beiträge zur Klinik der Tuberkulose*, 79, Berlin, 1932., 745-749.

<sup>3</sup> RAJIĆ, Petra and UJČIĆ, Željko. Anthropological Analysis of the Late Roman/Early Medieval Cemetery of Novigrad (Istria), *Collegium Antropologicum*, 27, Zagreb, 2003, 803-808; RAJIĆ ŠIKANJIĆ, Petra and UJČIĆ, Željko. Antropološka analiza ranokršćanske/ranosrednjovjekovne populacije s groblja u Novigradu (Istria), *Histria archaeologica*, 34, Pula, 2005., 103-129; ŠLAUS, Mario. *Bioarheologija. Demografija, zdravlje, traume i prehrana starohrvatskih populacija*, Zagreb, 2006., 140-148.; BEDIĆ, Željka. Osteological evidence for spinal tuberculosis in medieval skeletal series from Croatia, *Abstracts Book of the 18th European Meeting of the Paleopathology Association*, Wien, 2010., 40.; PREMUŽIĆ, Zrinka and RAJIĆ ŠIKANJIĆ, Petra. Starohrvatska populacija iz Triblja - zdravlje i bolesti/ Early Croatian Population from Tribalj, *Histria archaeologica*, 41, Pula, 2011., 205-220.; NOVAK, Mario, MARTINČIĆ, Ozana, STRINOVIĆ, Davor, ŠLAUS, Mario. Skeletal and dental indicators of health in the late mediaeval (12-15th century) population from Nin, southern Croatia, *Homo*, 63 (6), 435-450.; KRZNAR, Siniša and NOVAK, Mario. Slučaj koštane tuberkuloze s nalazišta Sv. Ivan Krstitelj u Ivankovu kraj Vinkovaca, *Prilozi Instituta za arheologiju u Zagrebu* 30, Zagreb, 2014., 93-106.

<sup>4</sup> MAGNUS, K. G. and HOFFMAN, E. B. Pyogenic spondylitis and early tuberculous spondylitis in children: differential diagnosis with standard radiographs and computed tomography, *Journal of Pediatric Orthopaedics*, 20, New York, 2000., 539-543.; DABERNAT, Henri and CRUBÉZY, Éric. Multiple bone tuberculosis in a child from predynastic upper Egypt (3200 BC), *International Journal of Osteoarchaeology*, 20 (6), 2009., 719-730.; MATOS, Vitor, MARQUES, Carina, LOPES, Célia. Severe vertebral collapse in a juvenile from the graveyard (13th/14th-19th Centuries) of the São Miguel Church (Castelo Branco, Portugal): differential palaeopathological diagnosis, *International Journal of Osteoarchaeology*, 21, 2009., 208-217; LEWIS, Mary. Tuberculosis in the Non-adults from Romano-British Poundbury Camp, Dorset, England, *International Journal of Paleopathology*, 1 (1), 2011., 12 - 23.

<sup>5</sup> TRUPKOVIĆ, Marko, RAJIĆ ŠIKANJIĆ, Petra and PREMUŽIĆ, Zrinka. Tuberkuloza kod djeteta s nalazišta na Trgu sv. Martina u Umagu, *Histria archaeologica*, 42, 2012., 233-242.

with tuberculosis. Since cases of subadult tuberculosis are rare in the Croatian osteological samples, this paper aims to contribute to this knowledge by describing the osteological remains of a subadult dated to the 17th century that exhibits features characteristic of tuberculosis.

## ARCHAEOLOGICAL CONTEXT

The chapel of St. Lawrence is located on a prominent hill above the village of Crkvari (in Croatian 'Crkva=Church'). Archaeological excavations (in several campaigns from 2003 to 2013) conducted by the Institute of Archaeology showed the presence of an important medieval site<sup>6</sup> where, during the High and Late Middle Ages, a more elaborate sacral complex was built, most likely on the grounds of the 11th century Early Medieval cemetery. At the peak of the buildings phase, a single-nave early Gothic church was widened into a large three nave church with a spire on the west side, and encircled by a moat (**Fig. 1**). By the end of the 17th century, and most certainly in the 18th century the north sacristy was no longer in use and that space was used as a burial ground. Out of the total of 599 so far excavated graves, subadults were recovered from 227 graves. This implicates a high frequency of subadult mortality during the Medieval and Modern Period. Grave No 398 was located in the south-east, between the apse of the chapel and the church stone wall fence.

By analysing all grave finds it will be possible to establish a more precise dating and stratigraphy of the Modern Period burials. At this time it is only possible to hypothesise on the dating of grave No 397 according to the medallion found in that grave which dates to the last phase of burials (18th/19th century) performed on that cemetery. Since grave No 397 had damaged grave No 398 it can be presumed that enough time had passed between these two burials (**Fig. 2**). Under the grave No 398 lies another Modern Period burial (grave No 401). It is evident that grave No 398 does not belong to the beginnings of the older phase of the Modern Period burials. This is all indicative of the time the actual burial must have taken place, after the enclosure wall had been erected. Grave No 401 can be dated to the mid 16th century, and if one is to take into account the amount of time that had passed in order for the local population to forget about the grave that lies underneath and its position, grave No 398 can roughly be dated to the 17th century.

## ANTHROPOLOGICAL ANALYSIS AND RESULTS

The osteological material recovered from Grave No 398 was in a good state of preservation, but, because of later inhumations, the skeleton was only partially preserved (**Fig. 3** and **Fig. 4**). Age-at-death was estimated at between 7.5 and 8.5 years using Scheuer and Black criteria,<sup>7</sup> primarily depending on dental calcification and chronology of formation and eruption of permanent dentition. The right epiphyseal humeral length (201 mm) suggests a slightly younger individual who was about 7 years old at the time of death. The pathological changes on the skeleton were observed macroscopically, and then recorded according to guidelines in the standard paleopathological literature.<sup>8</sup>

Tuberculosis in subadults generally affects the vertebrae, hip, knee and ankle joints. In some cases it also affects the cranial vault, most commonly the frontal and parietal bones. Tubercular lesions that appear on cranial bones are characteristically round or oblong lytic lesions that can lead to complete perforation of the skull.<sup>9</sup>

<sup>6</sup> TKALČEC, Tatjana. Arheološka istraživanja nalazišta Crkvari – crkva sv. Lovre 2012. godine, *Annales Instituti Archaeologici*, IX, Zagreb, 20-25.

<sup>7</sup> SCHEUER, Louise and BLACK, Sue. *The Juvenile Skeleton*, London, 2004.

<sup>8</sup> BUIKSTRA, Jane and UBELAKER, Douglas. *Standards for data collection from human skeletal remains: Proceedings of a Seminar at the Field Museum of Natural History*. Arkansas Archeological Survey Research Series, 44: Fayetteville, Arkansas, 1994.; ORTNER, Donald J. *Identification of Pathological Conditions in Human Skeletal Remains*, San Diego, 2003.; BRICKLEY, Megan and MCKINLEY, Jacqueline. *Guidance to standards for recording human skeletal remains*, Institute of Field Archaeologists and British Association of Biological Anthropology and Osteoarchaeology, Southampton-Reading, 2004.

<sup>9</sup> LEWIS, M. Tuberculosis in the Non-adults...,14.

The pathological changes observed on the subadult skeleton from Crkvari include changes on both the cranium and postcranium.

In the skull, indicators of nutritional stress are present: cribra orbitalia in the roof orbits and linear enamel hypoplasia (LEH) on the maxillary left incisor and canine, and mandibular incisors bilaterally. Cribra orbitalia manifests as a sievelike expansion in the orbital plates of the frontal bone, while LEH is generally defined as any macroscopic defect in the enamel surface. Usually these pathologies suggest possible periods of stress in childhood related to metabolic stress, inadequate nutrition, endemic parasitism, unhygienic living conditions, and chronic gastrointestinal diseases.<sup>10</sup>

Additional pathological changes on the frontal bone include mild ectocranial porosity, superior to the nasal cavity that projects laterally into the area above the orbits.

In both parietal bones the complete ectocranial surface is affected by porosity, especially along the sagittal suture. Mild ectocranial porosity and several shallow, oblong lesions are present on the occipital bone. Both temporal bones also exhibit mild ectocranial and endocranial porosity as does the maxilla. The left zygomatic bone exhibits an enlarged nutrient foramen and porosity along its inferior part. Porous bone is also present on the medial surfaces of both mandibular rami.

The ribs exhibit two differing pathological features - flattening of the sternal ends in the 4th left and 8th right rib, and bulging on the vertebral ends of the three left and three right ribs. Additionally, a large lytic lesion is present on the visceral surface of the 3rd left rib (**Fig. 5**). The most prominent pathological changes are noticeable on the spinal column: resorption and prolapse of the bodies of the 3rd to 9th thoracic vertebrae (**Fig. 6**), ankylosis of the vertebral arches from the 7th cervical to the 7th thoracic vertebrae, Pott's gibbus from the 2nd thoracic to 7th thoracic vertebrae (**Fig. 7**), complete destruction of the bodies of the 3rd to 5th thoracic vertebrae, and porotic and osteolytic lesions on the neural arches of the 12th thoracic, 1st and 2nd lumbar vertebrae.

## DISCUSSION

The severe vertebral body destruction resulting in kyphosis, ankylosis of the posterior thoracic spine, and marked changes on the majority of the preserved ribs suggest that this individual suffered from an advanced form of tuberculosis.<sup>11</sup> Differential diagnostics needs to, however, rule out the following non-infectious and infectious conditions: neoplastic disease, trauma, vertebral osteomyelitis, brucellosis, and fungal infections.

Neoplastic diseases are more common in older adults and are characterised by multifocal skeletal involvement<sup>12</sup> that is not the case in this individual where all of the major pathological changes are located in the vertebrae and ribs. Concerning trauma, while vertebral compression fracture can cause angular deformity, usually only one vertebra is involved and the destruction of multiple vertebral bodies that at the same time exhibit completely unaffected vertebral arches is uncommon.<sup>13</sup> An additional argument against a possible diagnosis of trauma are the changes noted on the ribs that cannot be related to traumatic events and the fact that none of the other preserved skeletal elements display any evidence of trauma.

<sup>10</sup> LANPHEAR, Kim M. Frequency and Distribution of Enamel Hypoplasias in a Historic Skeletal Sample, *American Journal of Physical Anthropology*, 81, 1990., 35-43; LARSEN, Clark S. *Bioarchaeology: Interpreting behavior from the human skeleton*, Cambridge, 1997.; MITTLER, Diane M. and VAN GERVEN, Dennis P. Developmental, diachronic, and demographic analysis of cribra orbitalia in the medieval Christian populations of Kulubnarti, *American Journal of Physical Anthropology*, 93, 1994., 287-297.; STUART-MACADAM, Patty. Porotic hyperostosis: a new perspective, *American Journal of Physical Anthropology*, 87, 1992., 39-47.

<sup>11</sup> AUFDERHEIDE, A.C. and RODRÍGUEZ-MARTÍN, C. *The Cambridge Encyclopedia...*; ROBERTS, Charlotte and BUIKSTRA, Jane E. *The Bioarchaeology of Tuberculosis: a global view on a reemerging disease*, Gainesville, 2003.; ORTNER, Donald J. *Identification of Pathological...*230-235.

<sup>12</sup> GREENSPAN, Adam and REMAGEN, Wolfgang. *Differential Diagnosis of Tumors and Tumor-like Lesions of Bone and Joints*, Philadelphia, New York, 1998.

<sup>13</sup> ORTNER, D. J. *Identification of Pathological...*235.

Vertebral osteomyelitis rarely occurs in children,<sup>14</sup> and when it does in 75% of the cases only one vertebra is involved.<sup>15</sup> When multiple involvement of adjacent vertebrae occurs the intervertebral discs are usually less affected than in tuberculosis and a sharply angulated gibbus (one of the main features of this case) is uncommon.<sup>16</sup> In brucellar spondylitis, kyphosis and gibbus deformity are rare. Focal bone destruction in individual vertebral bodies is common but is usually accompanied with bony repair characterized by osteophyte formation<sup>17</sup> that is completely lacking in this individual. Madkour and Sharif (1989)<sup>18</sup> and al-Eissa *et al.* (1990)<sup>19</sup> report that brucellar spondylitis rarely occurs in children, in whom brucellosis generally has a tendency to affect the joints.<sup>20</sup>

Considering fungal infections, Imhof (2005)<sup>21</sup> reports that fungal infections are an uncommon cause of spondylitis. Also, these infections generally cause more sharply demarcated lytic lesion with »space occupying lesions«<sup>22</sup> that differ from the appearance presented by the affected vertebra in the individual from Crkvari.

As shown above, other infectious diseases are not likely to be related to the disease that affected the child from Crkvari. The most probable diagnosis for this specimen is tuberculous spondylitis which, along with joint involvement and osteomyelitis, is one of the most common manifestations of skeletal tuberculosis in children.<sup>23</sup> Because of the great vascular supply of the disc, children are prone to infection that starts in the disc, spreads to the vertebral body and then adjacent vertebra.<sup>24</sup>

The pathological changes noted in the ribs, particularly the lytic lesion on the left 3rd rib and the swelling of the vertebral ends of the three left and three right ribs may be related to a collateral tuberculous phenomenon - a paravertebral abscess. Ortner (2003)<sup>25</sup> reports on unilateral or bilateral paravertebral (psoas) abscess formation is a common complication of spinal tuberculosis. Unfortunately, it is very hard to distinguish between bone abnormalities resulting directly from an active tuberculous focus, and changes that are secondary reactions to the presence of a paravertebral abscess.

Although porotic and osteolytic lesions on the posterior vertebral elements (neural arches) are rarely present in tuberculosis, Kelley and El-Najjar (1980)<sup>26</sup> examining the skeletons from the Hamman-Todd

<sup>14</sup> KULOWSKI, Jacob. Pyogenic osteomyelitis of the spine: An analysis and discussion of 102 cases, *Journal of Bone and Joint Surgery*, 18, Boston, 1936., 343-364.

<sup>15</sup> DONATI, Mario. Ober die Acute und Subacute »Osteomyelitis Purulenta« der Wirbelsäule, *Archiv für Klinische Chirurgie, Berlin* 79, 1906., 1116-1163.

<sup>16</sup> ORTNER, D. J. *Identification of Pathological...*191.

<sup>17</sup> RESNICK, Donald. Osteomyelitis, septic arthritis, and soft tissue infection: organisms. In: *Bone and Joint Imaging*, London, 1996., 684-716.; AUFDERHEIDE, A.C. and RODRÍGUEZ-MARTÍN, C. *The Cambridge Encyclopedia...*; MAYS, Simon, A. Lysis at the Anterior Vertebral Body Margin: Evidence for Brucellar Spondylitis? *International Journal of Osteoarchaeology* 17, 2007., 107 - 118.; MATOS, V., MARQUES, C., LOPES, C. Severe vertebral collapse...213.

<sup>18</sup> MADKOUR, Monir and SHARIF, H. Bone and joint imaging. In: *Brucellosis*, London, 1989., 105-115.

<sup>19</sup> AL-EISSA, Youssef, KAMBAL, Abdulmajeed, ALRABEEAH, *Abdullah*, ABDULLAH, Asaad, AL-JURAYYAN, Nasir, AL-JISHI, Nuhad. Osteoarticular brucellosis in children, *Annals of the Rheumatic Diseases*, 49, London, 1990., 896-900.

<sup>20</sup> LEWIS, M. Tuberculosis in the Non-adults...17,18.

<sup>21</sup> IMHOF, Herwig. Nonneoplastic disease of the spine. Understanding the Manifestations of Disease. In: *Radiologic-Pathologic Correlations from Head to Toe*, Berlin, 2005., 719.

<sup>22</sup> HERSHKOVITZ, Israel, ROTHSCHILD Bruce, DUTOUR O., GREENWALD C., Clues to recognition of fungal origin of lytics skeletal lesions, *American Journal of Physical Anthropology*, 106, 1998., 51.

<sup>23</sup> TEO, H., PEH, W. Skeletal tuberculosis in children, *Pediatric Radiology*, 34 (11), Berlin, New York, 2004., 853-860.

<sup>24</sup> BUIKSTRA, Jane. The Caribou Eskimo: general and specific disease, *American Journal of Physical Anthropology*, 5, 1976., 351-368.; ANTUNES, J. Lobo. Infections of the spine, *Acta Neurochirurgica*, 116, Wien 1992., 179-186.

<sup>25</sup> ORTNER, D. J. *Identification of Pathological...*232.

<sup>26</sup> KELLEY, Marc and EL-NAJJAR, Mahmoud. Natural variation and differential diagnosis of skeletal changes in tuberculosis, *American Journal of Physical Anthropology*, 52, 1980., 153-167.

collection recognized neural arch lesions in 20% of analysed skeletons that exhibited spinal tuberculosis.

The young age of the individual from Crkvari is in accordance with presently available data that suggests that in archaeological series tuberculosis of the spinal column was common in subadults.<sup>27</sup> After about seven years of age there is a decline in both skeletal tuberculosis manifestations,<sup>28</sup> and spinal tuberculosis.<sup>29</sup>

Bearing in mind that it takes between 1–3 years before spinal changes develop in infants under 5 years of age,<sup>30</sup> and the fact that the subadult from Crkvari exhibits severe but healed pathological changes it seems likely that the onset of the disease had started at least a few years earlier. Registered LEH on both maxillary and mandibular permanent teeth according to Goodman *et al.* (1980)<sup>31</sup> mineralization diagram for the enamel show that severe physiological stress occurred when this child was between 2 and 4 years of age. Some anthropological studies suggest that the enamel hypoplasia occurring in that period should be connected with the negative effects of weaning.<sup>32</sup>

The presence of cribra orbitalia has been recorded in some instances of child tuberculosis.<sup>33</sup> As the aetiology of cribra orbitalia is still not completely understood,<sup>34</sup> (some of the causes could be inadequate nutrition, parasitism, and unhygienic living conditions) its presence in this individual cannot unambiguously be attributed to tuberculosis. Other pathological changes on the skull that are present in a relatively mild form – the ectocranial porosity on the frontal, parietal and temporal bones are suggestive of other diseases: anaemia or metabolic bone disease.<sup>35</sup>

The individual analyzed in this paper was contemporaneous with the beginning of an epidemic of tuberculosis that coincided with the growth of larger, more crowded cities, and widespread poverty that characterized the urban poor of 17th century Europe. Over the following decades tuberculosis became the »Great White Plague« of Europe, with a peak in the late 18th century during which time it was responsible for approximately 25% of all deaths.<sup>36</sup> *Mycobacterium tuberculosis*, transmitted directly from person to person through the inhalation of droplets from an infected individual,<sup>37</sup> would be the agent responsible for this epidemic.

The political and economic situation in the greater Crkvari area (along the Drava River, near Oravica) during the 17th century suggests an increase in population density combined with revived trade

<sup>27</sup> AUFDERHEIDE, A.C. and RODRÍGEZ-MARTÍN, C. *The Cambridge Encyclopedia...*; ROBERTS, C. and BUIKSTRA, J. *The Bioarchaeology of Tuberculosis...*; ORTNER, Donald J. *Identification of Pathological...*230.

<sup>28</sup> ALFER, Carl. Die Häufigkeit der Knochen und Gelenktuberkulose in Beziehung auf Alter, Geschlecht, Stand und Erbllichkeit, *Beiträge zur Klinischen Chirurgie*, 18, München, 1892., 277-290.

<sup>29</sup> SORREL, Étienne and SORREL-DEJERINE Mme. *Tuberculose Osseuse et Osteoarticulaire*, Paris, 1932.

<sup>30</sup> WALLGREN Arvid. The time-table of tuberculosis, *Tubercle* 29, 1948., 245–251.

<sup>31</sup> GOODMAN, Alan, ROSE, Jerome and ARMELAGOS George. Enamel Hypoplasias as Indicators of Stress in Three Prehistoric Populations from Illinois, *Human Biology* 52(3), 1980., 515-528.

<sup>32</sup> HERRING, D Anne, SAUDERS, Shelley R, KATZENBERG, M Anne. Investigating the weaning process in past populations, *American Journal of Physical Anthropology*, 105, 1998., 425–439.; WRIGHT, Lori E. Intertooth patterns of hypoplasia expression: implications for childhood health in the Classic Maya Collapse, *American Journal of Physical Anthropology*, 102, 1997., 233–247.

<sup>33</sup> LEWIS, M. Tuberculosis in the Non-adults...20.; SPEKKER, Olga, PÁLFI, György, KOZOCSEY, Gréti, PÓSA, Annamária, BEREZKI Zsolt, MOLNÁR, Erika. New cases of probable skeletal tuberculosis from the Neolithic period in Hungary – A morphological study, *Acta Biologica Szegediensis*, 56(2), 2012., 115-123.

<sup>34</sup> WALKER, Phillip, BATHURST, Rhonda, RICHMAN, Rebecca, GJERDRUM, Thor, ANDRUSHKO, Valerie. The causes of porotic hyperostosis and cribra orbitalia: a reappraisal of the iron-deficiency anaemia hypothesis, *American Journal of Physical Anthropology*, 139, 2009., 109–125.

<sup>35</sup> BRICKLEY, Megan and MCKINLEY, Jacqueline. *The bioarchaeology of metabolic bone disease*, Academic Press, 2010.

<sup>36</sup> CEGIELSKI, P. J., CHAUHAN, S. L., CHIN, D. P. The global epidemiology and control of tuberculosis In: *New topics in tuberculosis research*, 2007.

<sup>37</sup> ORTNER, D. J. *Identification of Pathological...*227.

that may have facilitated the spread of *Mycobacterium tuberculosis*. This period is characterised by relatively peaceful living conditions during which trade routes revived, and centres for processing raw materials (milling) were established in this area. Export of wheat, fruit, and pigs also increased, possibly due to the establishing of centres of provisioning.<sup>38</sup>

Tuberculosis can also be transmitted by *Mycobacterium bovis*, through the consumption of meat and dairy products from infected animals,<sup>39</sup> and in that context it is important to note that until the first half of the 18th century animal husbandry, including cattle raising, was probably one of the most important economies in Slavonia.<sup>40</sup> As no significant morphological differences in the manifestations of tuberculosis on the skeleton exist between tuberculosis caused by *Mycobacterium tuberculosis* and that caused by *Mycobacterium bovis*, additional DNA analyses are necessary if the specific type of *Mycobacterium tuberculosis* responsible for the changes noted in the subadult from Crkvari is to be identified.

Given the circumstances in 17th century Crkvari, it is more than likely that the child from grave No 398 was not an isolated case and that other members of this community were also infected by *Mycobacterium tuberculosis*. These may have gone unnoticed because the disease frequently does not leave traces on the skeleton. It is approximated that nearly 30 million people suffer from tuberculosis today, and only between 1-3% develop any skeletal lesions (Rankin and Tuli 2010).<sup>41</sup>

## CONCLUSION

A severe case of spinal tuberculosis has been identified in the Medieval and Modern Period site Crkvari. A subadult recovered from grave No 398 dated to the 17th century, with an approximate age-at-death between 7.5 and 8.5 years exhibits severe pathological conditions: vertebral body destruction that resulted in kyphosis, ankylosis of the posterior thoracic spine, porotic and osteolytic destruction of the posterior part of the vertebral column and marked changes on the majority of the ribs. Other non-infectious and infectious diseases, as well as trauma, were excluded as a potential diagnosis. This is the first case of subadult tuberculosis with Pott's gibbus recorded in Croatian osteological series, and therefore important for understanding how infectious disease affected subadult health and mortality.

### Acknowledgements:

Grant sponsor - Croatian Science Foundation project number 8100 – 'The effects of endemic warfare on the health of historic period populations from Croatia'

## SAŽETAK

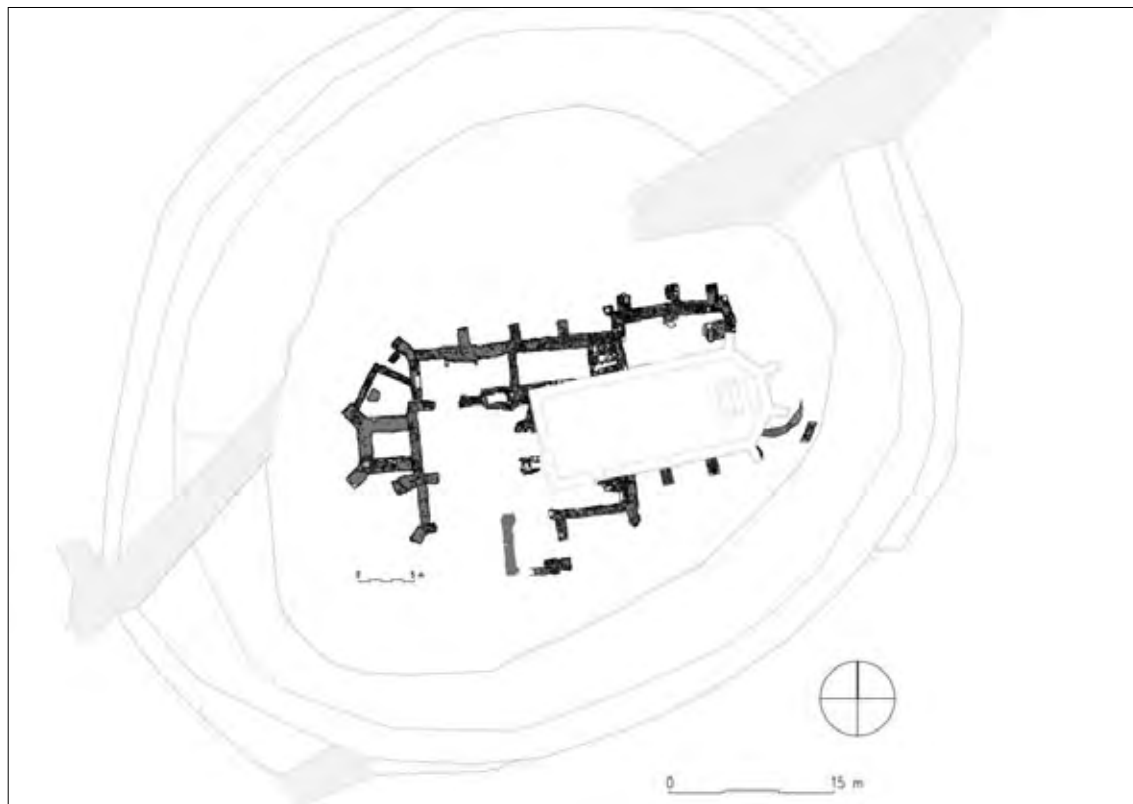
Rad predstavlja rezultate bioarheološke analize koštanog materijala iz groba 398 sa srednjovjekovnog i novovjekovnog nalazišta Crkvari. Kostur je datiran u 17. stoljeće i pripada djetetu starosti između 7,5 i 8,5 godina. Nakon detaljnog pregleda ustanovljene su teške patološke promjene koje su evidentirane na kralježnici i rebrima. Zabilježena je resorpcija i prolaps tijela od 3. do 9. prsnog kralješka, ankiloza (spajanje) lukova od 7. vratnog do 7. prsnog kralješka, Pottova grba od 2. do 7. prsnog kralješka, potpuno uništenje tijela 3., 4. i 5. prsnog kralješka kao i porozitet na 12. prsnom te 1. i 2. slabinskom kralješku. Dva su rebra na sternalnim (prsnim) krajevima spljoštena dok tri lijeva i tri desna rebra pokazuju oticanje. Nakon isključivanja ostalih nezaraznih i zaraznih bolesti, kao najvjerojatnija dijagnoza pokazao se tuberkulozni spondilitis koji se uz osteomijelitis i zahvaćenost na zglobovima najčešće manifestira na kostima djece koja boluju od tuberkuloze. Ovo je dijete živjelo na početku širenja epidemije tuberkuloze u feudalnoj Europi u 17. stoljeću, ali i u vrijeme kada su na području oko Crkvara oživjeli stari trgovački putevi koji su potencijalno mogli biti izvor širenja zaraza.

<sup>38</sup> MOAČANIN, Nenad. Pristup ekohistoriji Podravine prema osmanskim izvorima, *Ekonomska i ekohistorija* 1 (1), 2004., 146.

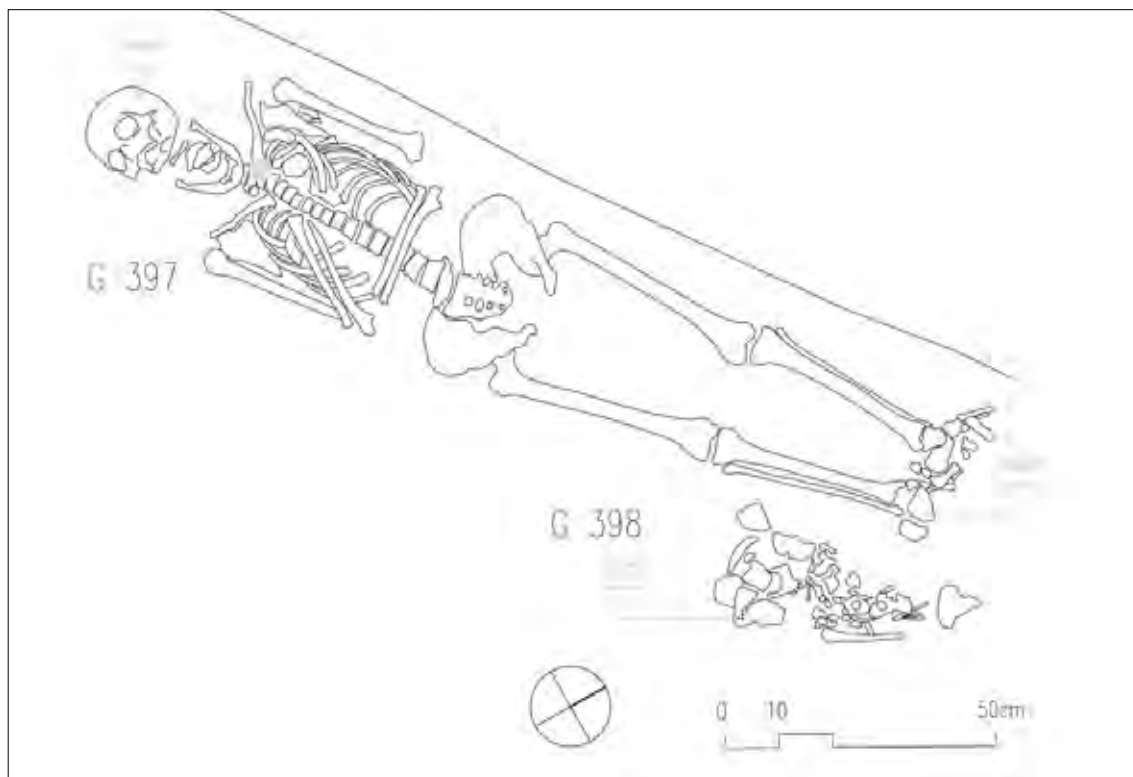
<sup>39</sup> AUFDERHEIDE, A.C. and RODRÍGEZ-MARTÍN, C. *The Cambridge Encyclopedia...*

<sup>40</sup> BUDAK, Neven. *Hrvatska i Slavonija u ranome novom vijeku*, 2007., Zagreb, 110,111.

<sup>41</sup> RANKIN, Kenneth and TULI, Surendar. Skeletal tuberculosis. In: *Children's Orthopaedics and Fractures*, London, 2010., 161–178.

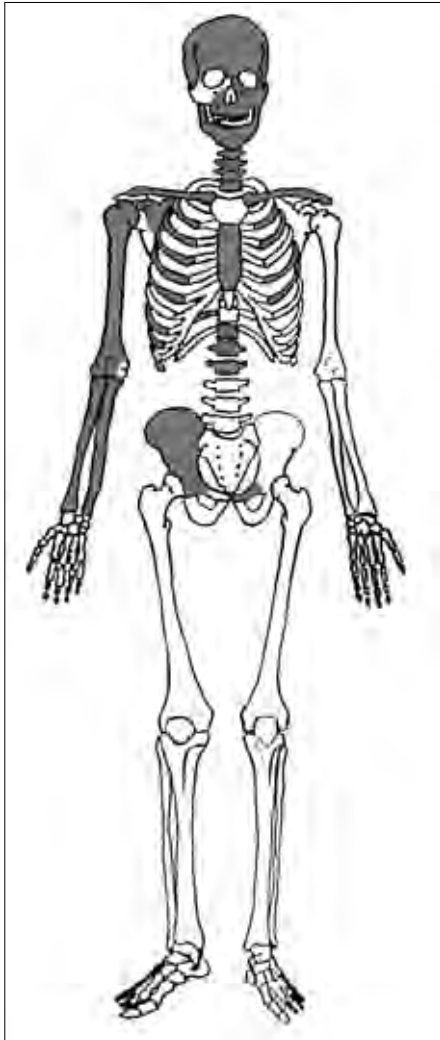


**Fig. 1.** Crkvari - The church of St. Lawrence, situation plan of the site in 2013 (source: Arhindsoks Institute of archaeology).



**Fig. 2.** Graves 398 and 397 (drawing K. Turkalji).

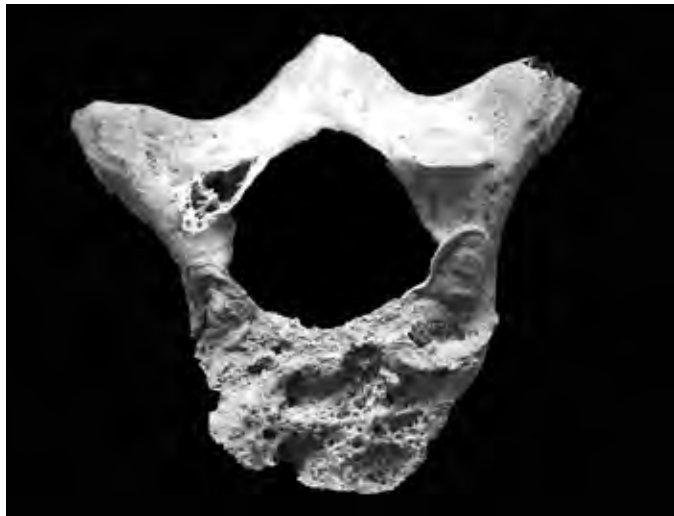




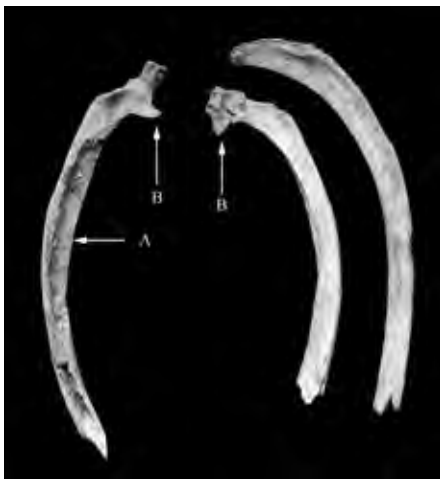**Fig. 4.** Schematic view of the preserved bones.



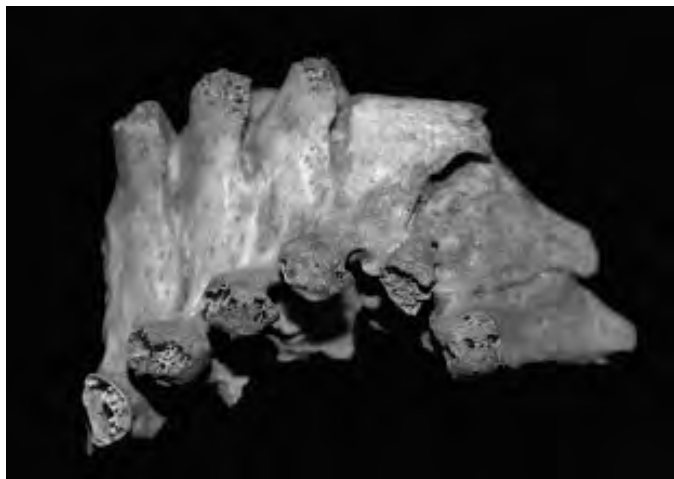
**Fig. 3.** Grave 398 containing burial of the child (photo by S. Krznar).



**Fig. 6.** Resorption of the corpus of the 9th thoracic vertebrae (photo by V. Vyroubal).



**Fig. 5.** Litic lesion on the left rib suggesting the presence of paravertebral abscess formation (A); bulging of the ribs on the vertebrae ends (B) (photo by V. Vyroubal).



**Fig. 7.** Pott's gibbus from the 2nd thoracic to 7th thoracic vertebrae (photo by V. Vyroubal).