

COMPARISON OF COMPOSITE RESTORATION TECHNIQUES

András Katona^{1,*} and Ibrahim Barrak²

¹Hillside Dental
Sopron, Hungary

²Department of Oral and Maxillofacial Surgery – University of Szeged
Szeged, Hungary

DOI: 10.7906/indecs.14.1.10
Regular article

Received: 30 October 2015.
Accepted: 5 January 2016.

ABSTRACT

This article briefly presents the classification, and possible ways of application of composites. Our objective was to compare three different restoration technique in class II cavity preparations, with the aim to determine which technique is the most advantageous in practical point of view. Artificial teeth fabricated from self-curing acrylic resin were used as models. Comparison of marginal sealing was performed macroscopically via direct visual inspection and via tactile control. Two parameters were examined on esthetic evaluation, which were the anatomical shape and the optical appearance. The time required to prepare the restorations were also measured. After the evaluation of the results, the bulk-fill technique was demonstrated to require the shortest time to be performed. This was followed by the oblique (Z) technique, whereas the horizontal incremental technique appeared to be the most time-consuming method. Based on the esthetic evaluation, a remarkable difference can be observed between the bulk-fill technique and the other two incremental techniques, while the mean scores for the oblique and the horizontal techniques were comparable. Based on the results of the visual inspection and instrumental examination, there were no differences in terms of marginal sealing between the three applied methods. Based on these, the use of the appropriate incremental technique can reduce the development of secondary caries and increasing the longevity of composite restorations.

KEY WORDS

direct restorations, operative dentistry, resin-based composite

CLASSIFICATION

JEL: Z19

*Corresponding author, *η*: katonaandras@icloud.com; +36 20 475 66 79;
Lackner Kristóf utca 33/A, 9400 Sopron, Hungary

INTRODUCTION

Traumatic injury to the hard tissues of the tooth, the development of tooth decay (caries), and the weakening of the supporting structure represent a multifactorial process. One of the most essential factors in the development of caries is the change in dietary habits. While people in the old times consumed unprocessed food, people of the 21st century hardly use their teeth. Processed high carb foods are prone to stick to the surface of the teeth, leading to the subsequent destruction of the hard tissues and the accumulation of plaques. People who lived at the beginning of civilization consumed raw meat and nutriment abundant in dietary fibers, thereby cleaning their teeth simultaneously. With the change in dietary habits, people of today need to pay a greater attention to teeth cleaning. It is the dentists' task to conserve the teeth as long as possible and to prevent tooth loss.

Caries is the most frequent disease of the hard tissues of the tooth. Tooth decay is a local, non-specific opportunistic infection, supplemented by civilization-associated components [1]. According to Adler's definition: caries is a chronic process that starts in the external surface of the teeth and subsequently propagates to the deep, leading to an irreparable destruction of the hard tissues of the teeth. It is the resultant of demineralization and remineralization processes [2]. A number of factors may underlie the shift in the balance, which result in hard tissue loss [3]. Several hypotheses exist about the development of caries. Among these, Miller's chemo-parasitic theory (1898) is the most accepted. The theory postulates that cariogenic microorganisms of the oral cavity produce organic acids in the presence of low molecular weight carbohydrates. These acids are able to demineralize the hard tissues of the teeth [1].

Risk factors for caries [3]:

- saliva (amount, consistency, pH value, buffer capacity, fluidity),
- diet (frequency of daily sugar intake, number of daily acid intake),
- fluoride (current and past exposition), and
- biofilm (composition, activity, level of differentiation).

Modifying factors of caries [3]:

- current dental status,
- general health condition,
- lifestyle, and
- socioeconomic status.

In case the tooth suffers injury due to decay, trauma, or iatrogenic reasons, its hard tissues need to be replaced as soon as possible. This can be performed through direct, semi-direct, and indirect ways. In recent days, the most frequently applied material for the direct technique is the hybrid composite [4, 5].

Fields of application of composites [6]:

- class I, II, III, IV, V, and VI restorations,
- covering discolored or hypoplastic enamel,
- esthetic correction (diasthema closure, correction of crown deformities),
- fissure sealing,
- preventive filling (extended fissure sealing),
- core build-up,
- preparation of periodontal splints,
- orthodontic bracket bonding,
- correction of wear facets, and
- restoration of traumatic injuries.

This study briefly presents the evolution, composition, classification, and possible ways of application of composites. Furthermore, it comprehensively discusses and compares via an *in vitro* experiment three direct composite restoration techniques.

OVERVIEW ON DIRECT RESTORATION TECHNIQUES

BULK-FILL

When applying the bulk-fill technique, a composite specifically developed for this purpose is placed into the cavity in a single layer (i.e. increment) (Fig. 1), in up to a thickness of 4 mm. Following the formation of the masticatory surface, the whole filling is cured with light (Fig. 2). Studies indicate this technique to be the least advantageous in terms of polymerization shrinkage [7, 8].

HORIZONTAL INCREMENTAL TECHNIQUE

The composite resin is placed inside the cavity in multiple increments. Each increment is light-cured individually. The increments are placed in parallel with each other (Fig. 3). A maximum layer thickness of 2 mm is recommended to provide adequate curing [9].

OBLIQUE INCREMENTAL TECHNIQUE

Also known as Z-technique, a method developed to reduce the C-factor. The composite resin is placed inside the cavity in multiple increments so that each increment is in contact only with the bottom and one side wall of the cavity (Fig. 4). This results in a relative increase in the free surface of the filling material, and a decrease in the extent of polymerization shrinkage [10].

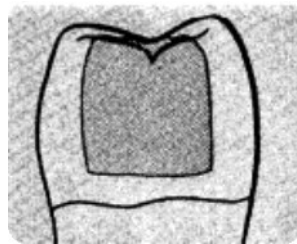


Figure 1. Bulk-fill.

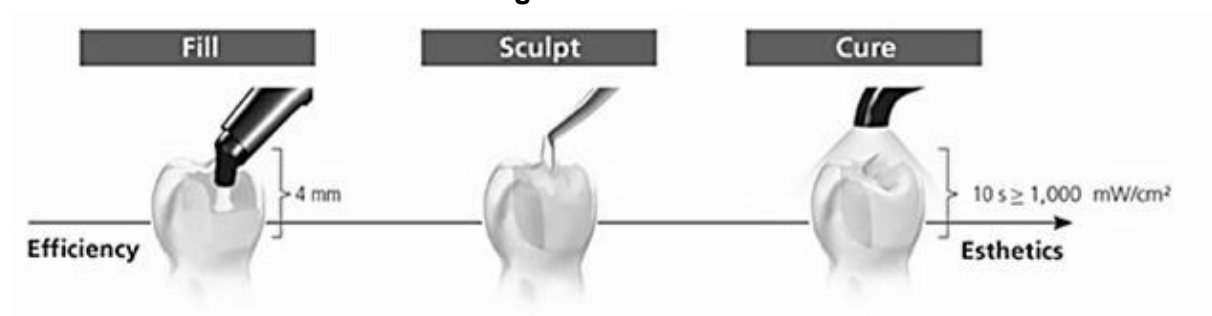


Figure 2. Steps of the bulk-fill restoration technique.

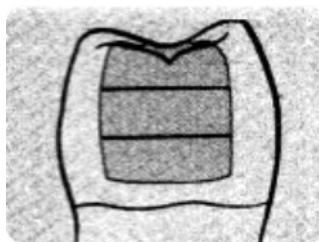


Figure 3. Horizontal incremental filling.

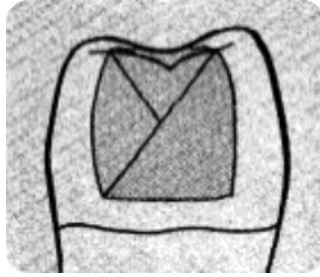


Figure 4. Oblique incremental filling.

OBJECTIVES

Posterior composite restorations have several limitations, among which polymerization shrinkage, a parameter that can have a value between 1,67 % and 5,68 %, is the most significant [11-14]. Several studies have demonstrated that a significant tensile force is generated during polymerization (i.e. shrinkage stress), which leads to the detachment of the composite resin from the tooth [15-17]. This problem is especially characteristic of class II composite restorations, as the proximal box has only little area of enamel for etching. As the composite resin shrinks, contraction gaps develop, which lead to postoperative sensitivity and pulp irritation [18, 19]. This issue can be overcome by choosing the appropriate incremental technique.

Our objective was to compare three different composite restoration techniques in class II cavity preparations, with the aim to determine which technique is the most advantageous in practical point of view. Restoration techniques chosen to be analyzed:

- 1) vertical incremental technique,
- 2) horizontal incremental technique,
- 3) bulk-fill technique.

In case of all three techniques, the time required to prepare the restoration was measured, the marginal sealing was examined, and the esthetic results were compared.

MATERIALS AND METHODS

Three different restoration techniques were compared in class II OD cavities prepared in acrylic teeth. First, model fabrication and duplication, second, cavity preparation and embedding in blue plaster, and eventually, the application of the three different techniques are discussed in the following sections.

EXAMINED MATERIALS

Models – artificial teeth

Artificial teeth fabricated from self-curing Duracryl Plus acrylic resin were used as models (Fig. 5).

Applied composites

Heraeus Kulzer Charisma Classic: light-curing micro-hybrid composite resin. As the refractive indices of the matrix and the filler system are optimally aligned, better color adaptation is provided. Its consistency enables easy and quick modeling. The easy shade range permits precise shade selection (Fig. 6) [20].

Composition: it is based on a bisphenol-A-glycidylmethacrylate (BIS-GMA) matrix and an approximate 61 % (v/v) filler, out of which 60 % (v/v) is an inorganic filler material with a particle size of 0,005 μm – 10 μm , which is of barium aluminum fluoride glass [20].

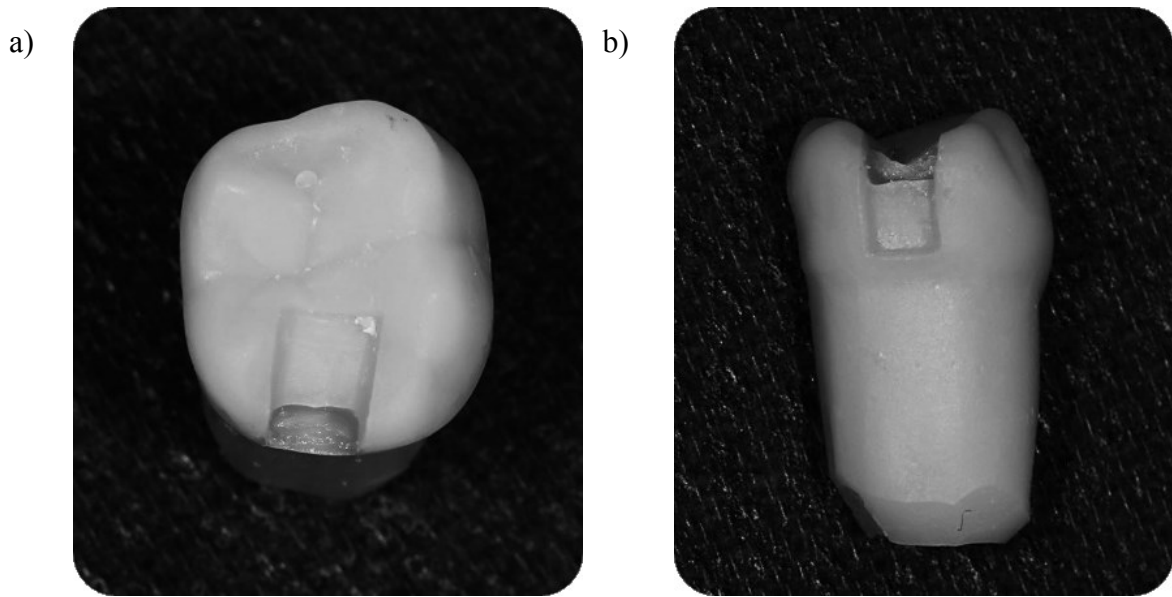


Figure 5. a) Artificial tooth, occlusal view and b) Artificial tooth, proximal view.

Heraeus Kulzer Gluma Self Etch: a seventh generation bonding agent. It is to adhesively bond the composite resins to the hard tissues of the tooth. It enables etching, priming, and bonding, as well as the desensitization of the prepared tooth, all with the application of a single layer. Gluma Self Etch associates its easy application with high bond strength, good marginal sealing, and the alleviation of postoperative hypersensitivity [21].

Composition: acetone-water-based solution containing light-activated methacrylate monomers (Fig. 6) [21].



Figure 6. The bonding agent (Gluma Self Etch) and the composite resin (Charisma Classic).

Ivoclar Vivadent, Tetric Evo Ceram Bulk Fill: Tetric Evo Ceram is a state-of-the-art nano-hybrid composite with high radiopacity. Owing to its polymerization features, it can be applied in layers up to 4 mm thickness. These features minimize shrinkage stress during the polymerization process. The high layer thickness significantly reduces the treatment time. The three universal shades available offer a great esthetic result with a natural transparency. Due to its consistency, it adapts well to the cavity wall. It cures under a light wavelength of 400 nm – 500 nm.

Composition: the monomer matrix consists of dimethacrylates (17 – 18 wt%). The fillers include barium glass, ytterbium trifluoride, mixed oxide, as well as prepolymer (82 – 83 wt %). All these are supplemented by additives, catalysts, stabilizers and dyes (less than 1,0 wt %).

The total content of inorganic filler material in case of bleach shades is 79 – 80 wt % and 60 – 61 % (v/v), whereas 75 – 76 wt% and 53 – 55 % (v/v) in case of all other shades. The particle size of inorganic filler materials ranges between 40 nm and 3000 nm, with the mean particle size being 550 nm (Fig. 7) [22].




Figure 7. Bulk-fill (Tetric Evo Ceram) and its instructions leaflet.

Examination procedures

Examination of different composite restoration techniques on standard size OD cavities prepared in lower right 6 acrylic tooth with the listed elements.

1) three restoration techniques:

- horizontal incremental technique,
- vertical incremental (Z) technique, and
- bulk-fill technique.

2) dimensions of the cavity:

- occlusal box:
 - depth (coronal-apical dimension) 1 mm,
 - length (mesio-distal dimension) 3 mm, and
 - width (oro-vestibular dimension) 2 mm.
- gingival box:
 - depth (coronal-apical dimension) 2+1 mm.

3) Burs used for preparation:

- diamond fissure bur with black mark.

4) Photopolymerization lamp:

- type: Ivoclar Vivadent Bluephase Style LED curing device,
- wavelength 385 nm - 515 nm,
- light intensity 1100 mW/cm² with 10 % tolerance, and
- curing time 20 sec.

5) analyzed parameters:

- total time required to prepare the restoration,
- comparison of marginal sealing (visual and tactile), and
- esthetic evaluation.

6) continuous photodocumentation.

Comparison of marginal sealing was performed macroscopically without magnification, on the one hand, via direct visual inspection, whereas on the other hand, via tactile control, during which the tip of the dental explorer probe was gently slid, first, from the center of the filling through the margins up to the surface of the tooth, followed by a slide from the tooth surface to the center of the filling, thereby looking for height discrepancies and defects.

Two parameters were examined on esthetic evaluation, which were the anatomical shape and the optical appearance. Before evaluation, the teeth were extracted from the plaster and marked with a 'Roman number and capital letter' (e.g., I A) in a completely random manner, where neither the letter nor the number referred to either the restoration technique or any condition characteristic of the particular process. Before placing the marks, the first prepared teeth from each group were excluded; therefore, a total of 27 restorations were evaluated. Three independent dentists were asked to line up all samples in order, first, according to anatomical fidelity, and second, to optical features. Based on these, each sample was scored from 1 to 27 (1 being the best, whereas 27 being the worst rate). The mean values of the three scores obtained from the independent raters for each sample were used as a measure of the subjective evaluation of the restoration technique in terms of both shape and optical characteristics.

A comprehensive description of the experimental process: To compare the different restoration techniques, standard conditions had to be provided. The lower right first molar tooth was chosen as a model for cavity preparation and restoration. As the size, shape, structure and many other parameters of the teeth are highly variable, standard conditions could not have been provided with the use of extracted teeth. Therefore, the OD cavities were prepared in plastic teeth (Fig. 8). The prepared plastic tooth was multiplied by silicone-duplicating, a method widely used in dental technology.

Preparation of the cavity:

- into acrylic teeth, and
- with diamond devices.

Dimensions of the cavity:

- Occlusal box:
 - depth (coronal-apical dimension) 1 mm,
 - length (mesio-distal dimension) 3 mm, and
 - width (oro-vestibular dimension) 2 mm.
- Gingival box:
 - depth (coronal-apical dimension): 2+1 mm.



Figure 8. Preparation of the cavity.

Process of duplication:

After preparation, the acrylic tooth was placed in a plastic cylinder filled with Fegura-Sil Hydro Spezial II duplicating silicone (Fig. 9). This silicone is a universal duplicating material.

Its liquid consistency and excellent shape-preserving feature enables the formation of precise micro-fine impressions. After solidification, the plastic tooth was removed from the silicone block, which was then filled with Duracryl Plus self-curing acrylic resin (Fig. 10). After curing, the acrylic resin was removed from the silicone. The silicone mold was then cleaned and the above process was repeated to give 30 completely uniform, perfect copies of casts.



Figure 9. Embedding.



Figure 10. Resin casting.

So as to correctly build-up the OD cavity, the use of a matrix system is necessary. As the presence of the adjacent teeth are needed to place the matrix and to create a proximal contact, the acrylic teeth were embedded into blue plaster blocks.

The process of embedding in plaster:

The acrylic teeth were cleaned of excess material produced during casting, and were isolated with vaseline. A plastic mold was then filled with blue plaster, which was followed by the implantation of the plastic teeth into the plaster tightly next to each other. The teeth were placed into the plaster in a way that their longitudinal axis became perpendicular whereas their masticatory surface became parallel to the plane of the working bench. A special effort has been made create a realistic reconstruction of the proximal contact points. Following the solidification of the plaster, the acrylic teeth were gently removed from the plaster blocks (Fig. 11). The removal of the teeth was feasible due to their isolation with vaseline and the lack of sites with a lower part being wider than the upper. The plaster was then fabricated in correspondence with the sites of the teeth. The teeth and the plaster were then cleaned of the isolating material. Dentorans, a light body impression material, was mixed and molded into the plaster block (Fig. 11). Each tooth was then placed back to its original place (Fig. 11).

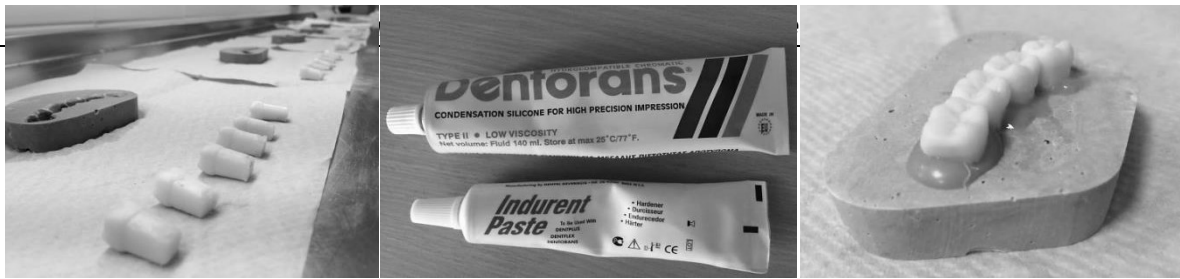

Figure 11. The process of embedding in plaster.

Excess impression material was removed. All these were necessary to provide minimal mobility for the embedded artificial teeth. This made separation possible, and the proximal contact points could thereby be formed.

Following the preparation phases, the formation of the composite restorations took place. A circumferential matrix retainer (Tofflemire) was used with its metal matrices. Separation was performed by a wooden wedge. The cavities were washed by alcohol and the photopolymerization was performed by Ivoclar Vivadent Bluephase Style LED curing device. During the restoration process, the time spent from the application of the adhesive till the end of the restoration was recorded. No finishing and polishing were performed as the acrylic resin used in the experiment was too soft and the teeth would therefore have suffered injury during the process.

The application of the oblique (Z) incremental technique

Placement and adaptation of the matrix system, separation with a wooden wedge, cleaning and drying of the cavity. Application of self-etching adhesive (Heraeus Kulzer Gluma Self Etch – light-curing, self-etching, mono-component adhesive), evaporation of the solvent, light-curing with 20 seconds with LED photopolymerization lamp (Ivoclar Vivadent Bluephase Style). Placement of composite resin (Heraeus Kulzer Charisma Classic A2), oblique incremental placement was applied so that each increment is in contact only with the bottom and one side wall of the cavity. Each increment is cured following placement and shaping (Fig. 12).

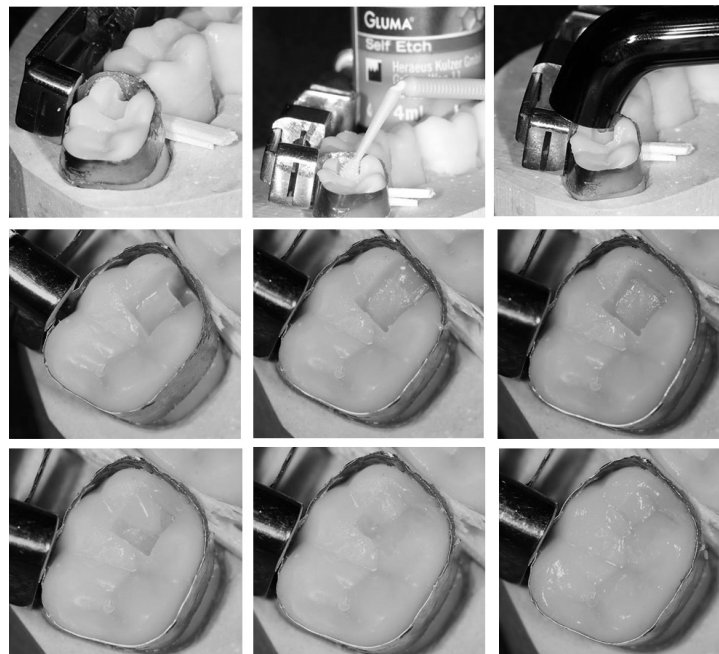


Figure 12. The application of the oblique (Z) incremental technique.

The application of the horizontal incremental technique:

The steps that precede the placement of the composite resin are identical with that of the oblique incremental technique. The resin is placed into the cavity in increments in case of this technique as well; however, in this case, each increment is in contact with the bottom and two

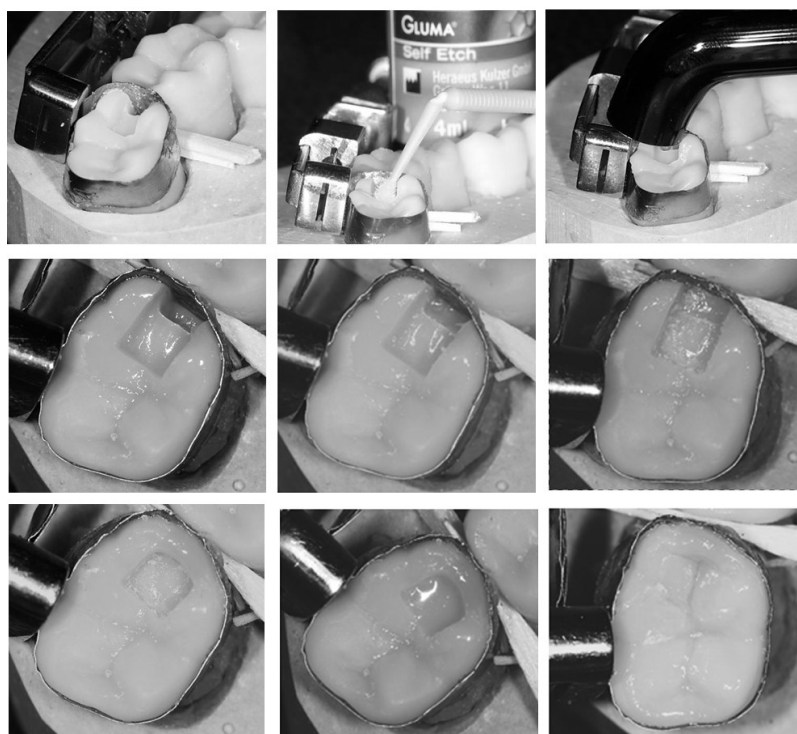


Figure 13. The application of the horizontal incremental technique.

side walls of the cavity. The different increments are in parallel with each other (Fig. 13). Light-curing is necessary following the placement of each layer. For the sake of efficient curing, a maximum layer thickness of 2 mm is recommended.

The application of the bulk-fill restoration technique

After the adhesive preparation of the cavity, in this case, the composite resin is placed into the cavity in one increment (bulk), and the whole bulk is then light-cured after shaping (Fig. 14).

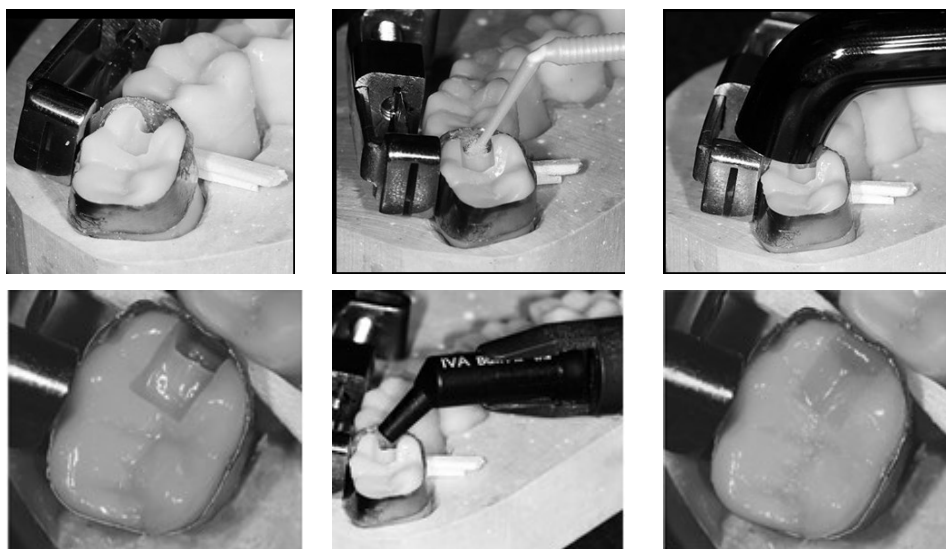


Figure 14. The application of the bulk-fill technique.

The time required to prepare the restorations were measured with the use of a mobile phone application. The measurement was started after placing the matrix system and cleaning the cavity, and was stopped after curing the last composite increment, Table 1.

RESULTS

THE TIME REQUIRED TO PREPARE THE RESTORATION

After the evaluation of the results, the bulk-fill technique was demonstrated to require the shortest time to be performed (Fig. 15). This was followed by the oblique (Z) technique, whereas the horizontal incremental technique appeared to be the most time-consuming method.

Table 1. Time (in seconds) required to prepare in the different restoration techniques.

	Bulk-fill	Oblique (Z)	Horizontal
1.	381	532	634
2.	373	497	620
3.	366	492	609
4.	390	503	601
5.	358	494	604
6.	371	504	630
7.	350	490	581
8.	353	499	594
9.	368	510	580
10.	389	517	602

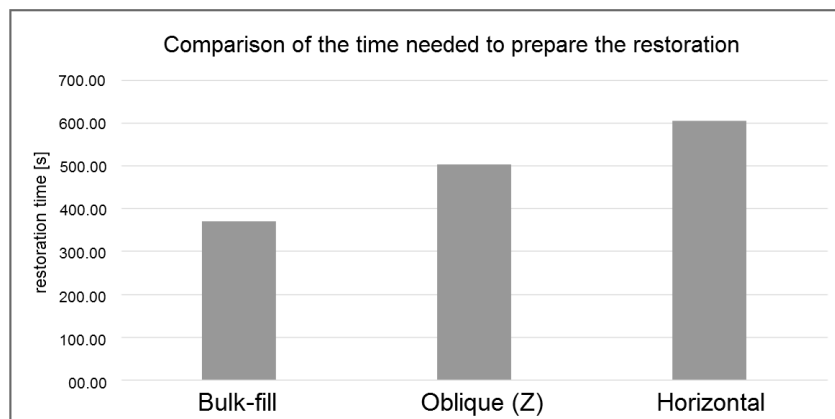


Figure 15. Comparison of the times required to prepare the restoration.

ESTHETIC EVALUATION

Optical characteristics and anatomical fidelity

Based on the evaluation of the obtained scores, a remarkable difference can be observed between the bulk-fill technique and the other two incremental techniques, while the mean scores for the oblique and the horizontal techniques were comparable (Table 2). As the lower numbers stand for better results, the lower mean scores were regarded as more advantageous (Fig. 16).

Table 2. Mean scores of optical and anatomical characteristics.

	mean anatomical score	mean optical score
horizontal	11,2	12,8
oblique	12	9
bulk-fill	19	20,2

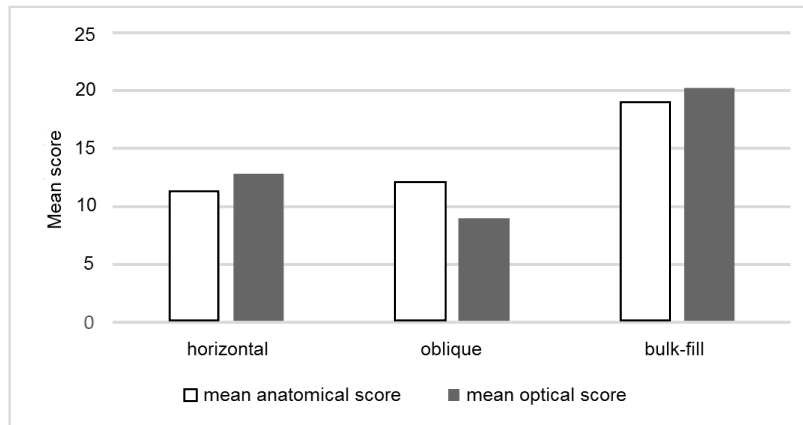


Figure 16. Comparison of optical and anatomical characteristics.

Comparison of marginal sealing

The comparison of marginal sealing was started with visual inspection. All models were examined for the contact between the filling material and the cavity wall. Visually observable gaps and fissures were looked for. After visual inspection, the margins of the filling were examined with a dental explorer probe. This method is suitable for detecting marginal defects that are not observable by inspection. Based on the results of the visual inspection and instrumental examination, there were no differences in terms of marginal sealing between the three applied methods.

DISCUSSION

Incremental techniques using composite resins are widely applied in everyday practice [23]. Since the thickness of the composites that can be cured by light is limited, the application of multiple increments with a number and thickness appropriate for the material characteristics of the respective composite resin is inevitable. The applied incremental technique can influence the value of cavity configuration factor (C-factor) and the extent of polymerization shrinkage [24]. This is because, in case of the application of the composite resin in multiple thin increments, polymerization shrinkage occurs in each increment. Shrinkage of a single thin layer of composite generates remarkably less tensile force than the contraction of a composite bulk that fills the whole cavity. Last but not least, the C-factor is also significantly lower in the above described case, which further reduces the stress associated with polymerization shrinkage. These all contribute to an increased adhesion of the composite to the dentin, as well as the possibility of the development of microleakage [24].

In case the filling material is placed into the cavity in one bulk, it gets in contact with 5 walls and only one free surface will remain. In such a case, the C-factor is maximal, and, therefore, the competition between shrinkage stress and the adhesion of the composite to the dentin is the highest [25]. This thesis examined three different composite restoration techniques. The measurements focused on the time required to prepare the restoration, the comparison of marginal sealing, and the evaluation of the esthetic results.

As regards the time required to prepare the restoration, the bulk-fill technique proved to be the most advantageous, followed by the oblique (Z) technique, and, as the last one, the horizontal incremental technique. In my opinion, the time required to prepare the horizontal and the oblique restoration depends on the expertise of the person preparing the restoration as well. In theory, the time required to prepare the restoration with the horizontal incremental technique should be shorter; however, my measurements demonstrate the contrary. It is

possible that the time required to prepare the restoration is also influenced by which incremental technique the particular expert prefers and uses in everyday practice.

As regards marginal sealing, no remarkable differences could be observed on visual comparison or on instrumental examination by a dental explorer probe.

In esthetic point of view, techniques that apply multiple increments proved to be the most advantageous ones.

From the different restoration techniques, *in vivo* and *in vitro* studies suggest that the bulk-fill technique is of the least benefit [8]. Comparisons of the horizontal and the oblique technique does not show such a coherent result. Studies of some authors demonstrate no significant difference [26, 27], whereas other researchers suggest the use of the oblique technique [10].

CONCLUSION

The bulk-fill technique appeared to be better in terms of the time required to prepare the restoration; however, the placement of the composite in one bulk could lead to the deterioration of shape and esthetics.

The most frequent cause of composite restoration failure is the development of secondary caries [28, 29]. In the vast majority of cases, secondary decay develops owing to insufficient marginal sealing. This develops due to the shrinkage of the composite resin during polymerization. Polymerization shrinkage can be reduced by the use of appropriate incremental technique. Therefore, the appropriate choice of the incremental technique can positively influence, i.e., reduce the polymerization shrinkage, with less shrinkage resulting in better marginal sealing, and a satisfactory marginal sealing in turn decreasing the risk for the development of secondary caries.

Based on these, the use of the appropriate incremental technique reduces the development of secondary caries, thereby increasing the longevity of composite restorations.

REFERENCES

- [1] Bartha, T.: *Curriculum Cariologiae*. Internal text, University of Szeged, Szeged, 2006,
- [2] Bánóczy, J.: *Cariology are endodontics*. In Portuguese. Medicina, Budapest, 1990,
- [3] Pretty, I.A.: *Caries detection and diagnosis: Novel technologies*. Journal of Dentistry **34**(10), 727-739, 2006, <http://dx.doi.org/10.1016/j.jdent.2006.06.001>,
- [4] Christensen, G.J.: *Should resine-based composite dominate restorative dentistry today?* Journal of American Dental Association **141**(12), 1490-1493, 2010, <http://dx.doi.org/10.14219/jada.archive.2010.0112>,
- [5] Sunnegardh-Gronberg, K.; Van Dijken, J.W.V.; Funegård, U.; Lindberg, A. and Nilsson, M.: *Selection of dental materials and longevity of replaced restorations in Public Dental Health clinic in northern Sweden*. Journal of Dentistry **37**(9), 673-678, 2009, <http://dx.doi.org/10.1016/j.jdent.2009.04.010>,
- [6] Fazekas, Á.: *Conservative dentistry and endodontics*. In Hungarian. Semmelweis, Budapest, 2006,
- [7] Kim, M.E. and Park S.H.: *Comparison of Premolar Cuspal Deflection in Bulk or in Incremental Composite Restoration Methods*. Operative Dentistry **36**(3), 320-340, 2011, <http://dx.doi.org/10.2341/10-315-L>,

- [8] Lee, M.R.; Cho, B.N.; Son, H.H.; Um, C.H. and Lee, I.B.: *Influence of cavity dimension and restoration methods on the cups deflection of premolars in composite restoration.* Dental materials **23**(3), 288-295, 2007,
<http://dx.doi.org/10.1016/j.dental.2006.01.025>,
- [9] Lenhard, M.: *Large composite restorations in the posterior region.* International Dentistry SA **11**(5), 50-60, 2009,
- [10] Chi, H.H.: *A Posterior Composite Case Utilizing the Incremental and Stratified Layering Technique.* Operative Dentistry **31**(4), 512-516, 2006,
<http://dx.doi.org/10.2341/05-117>,
- [11] Degee, A.J.; Davidson, C.L. and Smith, A.A.: *A Modified dilatometer of continuous recording of volumetric polymerization shrinkage of composite restorative materials.* Journal of Dentistry **9**(1), 36-42, 1981,
[http://dx.doi.org/10.1016/0300-5712\(81\)90033-6](http://dx.doi.org/10.1016/0300-5712(81)90033-6),
- [12] Goldman, M.: *Polimerization shrinkage of resin based restorative materials.* Austrian Dental Journal **28**(3), 156-161, 1983,
- [13] Hansen, E.K.: *Effect of cavity depth and application technique on marginal adaptation of resins in dentin cavities.* Journal of Dentistry Research **65**(11), 1319-1321, 1986,
- [14] Hansen, E.K. and Asmussen, E.: *Marginal adaptations of posterior resins: effect of dentin-bonding agent and hygroscopic expansion.* Dental Materials **5**(2), 122-126, 1989,
[http://dx.doi.org/10.1016/0109-5641\(89\)90142-5](http://dx.doi.org/10.1016/0109-5641(89)90142-5),
- [15] Asmussen, E.: *Composite restorative resins: composite versus wall to wall polymerization contraction.* Acta Odontologica Scandinavica **33**(6), 337-344, 2009,
<http://dx.doi.org/10.3109/00016357509004638>,
- [16] Bowen, R.L.; Nemoto, K. and Rapson, J.E.: *Adhesive bondig of various materials to hard tissues: forces developing in composite materials during hardening.* Journal of American Dental Associatiun **106**(4), 475-477, 1983,
<http://dx.doi.org/10.14219/jada.archive.1983.0078>,
- [17] Jorgensen, K.D.; Asmussen, E. and Shimokobe, H.: *Enamel damage caused by contracting restorativ resins.* Scandinavian Journal of Dental Research **83**(2), 120-122, 1975,
<http://dx.doi.org/10.1111/j.1600-0722.1975.tb00427.x>,
- [18] Bergenholtz, G.; Cox, C.F.; Loeske, W.J. and Syed, S.A.: *Bacterial leakage around dental restorations: its effect on the pulp.* Journal of Oral Pathology **11**(6), 439-450, 1982,
<http://dx.doi.org/10.1111/j.1600-0714.1982.tb00188.x>,
- [19] Brannström, M.: *Communication between the oral cavity and the dental pulp associated with restorative treatment.* Operative Dentistry **9**(2), 57-68, 1984,
- [20] Heraeus Kulzer International: *Charisma Classic official users manual.*
http://heraeus-kulzer.com/int2/int/dentist/products_from_a_to_z/charisma_1/charisma_classic.aspx,
- [21] Heraeus Kulzer International: *Gluma Self Etch official users manual.*
http://heraeus-kulzer.com/int2/int/dentist/products_from_a_to_z/gluma_2/gluma_self_etch.aspx,
- [22] Official website of Ivoclar Vivadent: *Tetric Evo Ceram Bulk Fill.*
<http://www.ivoclarvivadent.us/update/clinical/issue01/page06.php>,
- [23] Rupp, N.W.: *Clinical placement and performane of composite resin restorations.* Journal of Dental Research **58**(5), 1551-1557, 1979,
<http://dx.doi.org/10.1177/00220345790580052101>,

- [24] Yumei, N.; Xue, M.; Mingwen, F. and Sijie, Z.: *Effect of layering techniques on the micro-tensile bond strength to dentin in resin composite restorations.* Dental Materials **25**(1), 129-134, 2009, <http://dx.doi.org/10.1016/j.dental.2008.04.017>,
- [25] Sano, H.; Ciucchi, B.; Matthews, W.G. and Pashley, D.H.: *Tensile properties of mineralized and demineralized human and bovine dentin.* Journal of Dental Research **73**(6), 1205-1211, 1994, <http://dx.doi.org/10.1177/00220345940730061201>,
- [26] Nadig, R.; Bugalia, A.; Usha, G.; Karthik, J.; Rao, R. and Vedhavathi, B.: *Effect of four different placement techniques on marginal microleakage in Class II composite restorations: An in vitro study.* World Journal of Dentistry **2**(2), 111-116, 2011, <http://dx.doi.org/10.5005/jp-journals-10015-1066>,
- [27] Park, J.; Chang, J.; Ferracane, J. and Bog Lee, I.: *How should composite be layered to reduce shrinkage stress: Incremental or bulk filling?* Dental Materials **24**(11), 1501-1505, 2008, <http://dx.doi.org/10.1016/j.dental.2008.03.013>,
- [28] Demarco, F.F.; Correa, M.B.; Cenci, M.S.; Moraes, R.R. and Opdam, N.J.M.: *Longevity of posterior composite restorations: Not only a matter of materials.* Dental Materials **28**(1), 87-101, 2012, <http://dx.doi.org/10.1016/j.dental.2011.09.003>,
- [29] Kubo, S.: *Longevity of resin composite restorations.* Japanese Dental Science Review **47**(1), 43-55, 2011, <http://dx.doi.org/10.1016/j.jdsr.2010.05.002>.