

SEQUESTERED EXTRUSION OF LUMBAR DISK: EXPERIMENTAL MODEL, CLINICAL PICTURE, DIAGNOSIS AND TREATMENT

Boris Božić¹, Andrej Kogler¹, Lucijan Negovetić¹, Tomislav Sajko² and Nenad Kudelić³

¹University Department of Neurosurgery, Sestre milosrdnice University Hospital; ²Department of Anatomy, Zagreb University School of Medicine; ³Department of Physics, Zagreb University School of Science, Zagreb, Croatia

SUMMARY – Sequestered extrusions of the lumbosacral spine, a type of herniated lumbar disk, with large sequesters located in the spinal canal, so-called sequestered extrusions of the lumbosacral spine, were analyzed. They are mainly located in the L-4-L5 and L5-S1 spinal segments, and less commonly in the L3-L4 spinal segment, and are divided into several groups.

Key words: *Back pain – etiology; Lumbosacral region – diagnosis; Spine – physiology; Weight bearing – physiology; Biomechanics; Cadaver*

Etiology and Pathogenesis

The etiology and pathogenesis of sequestered lumbar disk extrusion are related to an enormous biomechanical force (more than 1000 N) acting upon the lumbar segment of the spine. The experimental model of a fresh human cadaveric specimen of the lumbosacral spine that was continuously loaded with centric and eccentric force spanning from 1000 to 1500 N revealed a great number of dorsal sequestered extrusions and in a few cases ventral extrusion. A total of 35 experiments were performed at the Department of Anatomy, Zagreb University School of Medicine, and Department of Physics, Zagreb University School of Science, Zagreb, Croatia. A similar mechanism, i.e. a strong action of biomechanical force is also responsible for the occurrence of lumbar disk extrusions that are neuro-radiologically verified in patients seeking neurosurgical treatment. In the experiments with torsion of fresh cadaveric human spine, sequestered lumbar disk extrusions occurred upon applying a force of less than 1000 N (800 N) at centric and eccentric load. According to data obtained




Fig. 1. Fresh cadaveric human lumbosacral spine specimen with sequestered lumbar disk herniations caused by the application of mechanical force of 800-1500 N. A screw regulating loading force and a manometer recording the compression force in newtons (N) – upper segment; fresh cadaveric lumbosacral spine specimen – lower segment.

Correspondence to: *Boris Božić, M. D.*, University Department of Neurosurgery, Sestre milosrdnice University Hospital; Vinogradska 29, HR-10000 Zagreb, Croatia

Received June 30, 2003, accepted September 3, 2003

from patient histories, most cases of lumbar disk extrusion occurred upon lifting heavy objects in combination with torsion and rotation. This type of movement is equivalent to torsion applied to specimens in experimental conditions¹⁻³ (Fig. 1).

Clinical Picture

The clinical study was conducted at the University Department of Neurosurgery, Sestre milosrdnice University Hospital, Zagreb, Croatia. The analysis included a series of 4000 patients operated on during the 1990-2000 period. According to literature data, sequestered lumbar disk extrusions account for 3% to 10% of all lumbar disk herniations. In the present study, they were recorded in 5% of all lumbar disk herniations. Clinical picture showed a pronounced algic component, progressive neurologic deficits such as peroneal paresis or paralysis, or progressive cauda equina syndrome^{4,6}. In case of dorsomedial disk herniation, pain is caused by stimulation of the nociceptive receptor located in the fibrous disk ring. In dorsolateral herniation, radicular pain is the result of stimulation of chemoreceptors due to local ischemic changes and metabolic disbalance with subsequent release of substance P, prostaglandins and vasoactive amines^{7,8}.

Table 1. Classification of sequestered lumbar disk herniations according to clinical data and neuroradiologic findings

I – large sequestered dorsomedial extrusions
II – large sequestered dorsomedial and dorsal-unilateral extrusions
III – sequestered dorsomedial and dorsal-bilateral extrusions
IV – sequestered dorsomedial extrusions with intradural sequestration at 'root entry' point
V – sequestered dorsomedial extrusions with uni- or bilateral intradiscal sequestration
VI – sequestered dorsolateral extrusions entering the intervertebral foramen – 'far lateral' herniations

Diagnosis

The diagnostic procedures used in the study were computed tomography (CT) and magnetic resonance imaging (MRI) of the lumbosacral spine. Sequestered lumbar disk extrusions were mainly located at L4-L5 and L5-S1 level, and less commonly at L3-L4 level. According to clinical

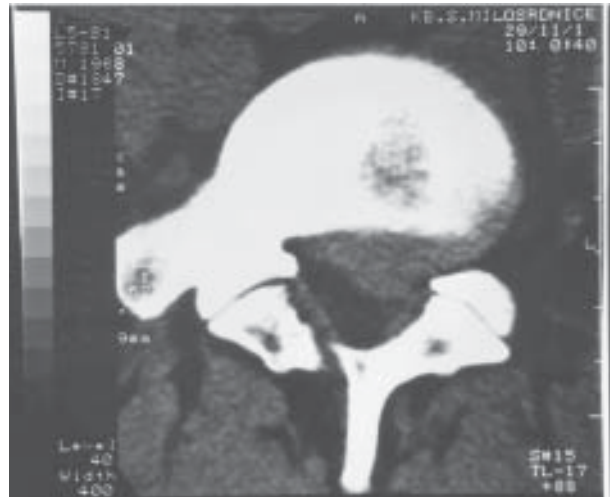

Fig. 2. CT scan showing sequestered dorsolateral left-sided disk extrusion at L4-L5 level.

data and neuroradiologic findings, they were classified into several groups, as shown in Table 1 and illustrated in Figures 2-4.

Treatment

All patients underwent surgery. In most cases, microdiscectomy, flavectomy and interlaminectomy were performed. In some cases, laminectomy had to be done for spinal canal stenosis. Postoperatively, the patients experi-

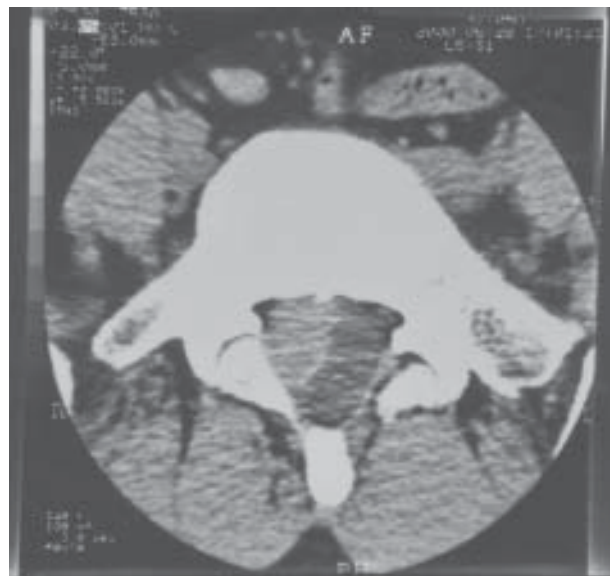

Fig. 3. CT scan showing dorsolateral right-sided extrusions at L5-S1 level.

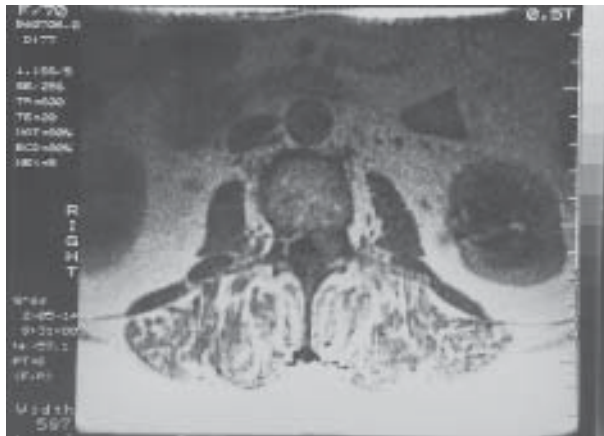


Fig. 4. MRI scan showing dorsolateral left-sided disk extrusion at L3-L4 level.

enced pain relief and amelioration of the neurologic status. In those with peroneal palsy, the neurologic deficit regressed unless experienced for more than 4-5 weeks preoperatively. The cauda equina syndrome caused by dorsomedial disk extrusion improved postoperatively in most cases. Upon discharge from the hospital, the patient treatment continued with physical therapy^{9,10}.

Conclusions

1. Sequestered lumbar disk herniation is due to the action of enormous biomechanical force upon the lumbosacral segment of the spine.
2. Sequestered lumbar disk extrusions are a rare pathomorphological entity which in our clinical material accounted for 5% of all lumbar disk herniations.
3. Clinically, they are characterized by a strong algic component and progressive neurologic deficit, and can be of dorsomedial, dorsolateral, intradural, intradiscal or far lateral localization in the intervertebral foramina.
4. The diagnosis is made by CT and MRI, whereby MRI of the lumbosacral spine is the procedure of choice.
5. Sequestered lumbar disk herniations are treated surgically. Microdiscectomy, flavectomy and interlaminectomy

are most frequently performed. In case of spinal canal stenosis, laminectomy has to be done.

6. The algic component generally improves and neurologic deficit is ameliorated postoperatively.
7. Postoperatively, peroneal palsy caused by sequestered lumbar disk extrusion and persisting for 4-5 weeks recovers at a slower rate, whereas cauda equina syndrome due to intradural sequestration of lumbar disk herniation does not improve completely.

References

1. PANJABI MM, KRAG M, SUMMERS P, VIDEMAN T. Biomechanical time tolerance of fresh cadaveric human spine. *J Orthop* 1985;3:292-300.
2. GUNAR BJ. Occupational biomechanics. In: WEINSTEIN WJ, WIESEL S, eds. *The lumbar spine*. Philadelphia - London - Toronto: WB Saunders Co., 1990:212-24.
3. BOŽIĆ B, NEGOVETIĆ L, IVANČIĆ-KOŠUTA M. Biomechanical analysis of the lumbar spine. *Minim Invas Neurosurg* 1997;40:24-7.
4. BOŽIĆ B, RADIĆ I, NEGOVETIĆ L, KOGLER A, KOVAČ D. Intradural lumbar disc herniation. 11th International Congress of Neurological Surgery. Bologna: Monduzzi Editore International Processing Division, 1997:1417-20.
5. GODERSKV JC, ERICKSON IDE, SELJESKOG EL. Extreme lateral disc herniation. Diagnosis by CT scanning. *Neurosurgery* 1984;14:549-52.
6. SCHISANO G, FRANCO A, NINA P. Intradiscal and intradural lumbar disc herniation: experience with nine cases. *Surg Neurol* 1995;44:536-43.
7. SHAPIRO S. Cauda equina syndrome secondary to lumbar disc herniation. *Neurosurgery* 1993;32:743-7.
8. CASPAR W, CAMPBELL B, BARBIER DD. The Caspar microsurgical discectomy and comparison with a conventional lumbar disc procedure. *Neurosurgery* 1991;28:78-87.
9. NACHEMSON AL. Newest knowledge of low back pain. *Clin Orthop* 1992;279:8-20.
10. EPSTEIN NE, EPSTEIN JA, CARRAS R. Far lateral disc herniations and evaluation of the comparative value of CT, MRI and myelo-CT in diagnosis and management of 60 patients. *Spine* 1990;15:534-9.

Sažetak

SEKVESTRIRANA EKSTRUZIJA LUMBALNOG DISKA: EKSPERIMENTALNI MODEL, KLINIČKA SLIKA, DIJAGNOSTIKA I LIJEČENJE

B. Božić, A. Kogler, L. Negovetić, T. Sajko i N. Kudelić

Etiologija i patogeneza sekvestriranih diskus hernija slabinskoga dijela kralješnice evidentirana je kod prekomjernih biomehaničkih opterećenja slabinskog modela kralješnice (preko 1000 N). Eksperimentalni model je bio svježi humani model slabinske kralješnice koji je bio izložen kontinuiranim ekscentričnim i centričnim opterećenjima od 1000 do 1500 N. Eksperiment je proveden na 35 svježih modela humane slabinske kralješnice u Zavodu za anatomiju Medicinskoga fakulteta i Zavoda za fiziku Prirodoslovno matematičkog fakulteta u Zagrebu. Sličan mehanizam, tj. jaka biomehanička sila, odgovorna je za nastanak sekvestrirane lumbalne ekstruzije diska koja je dokazana neuroradiološki (kompjutorizirana tomografija i magnetska rezonanca kralješnice) u bolesnika koji traže neurokiruršku pomoć. U pokusima s torzijom sekvestrirane ekstruzije slabinske kralješnice javljale su se i pri opterećenjima manjim od 1000 N (800 N) i uz centrična i uz ekscentrična opterećenja. Prema podacima dobivenim iz bolesničkih povijesti bolesti većina slučajeva ekstruzije slabinskog diska nastali su kod podizanja teškog tereta u kombinaciji s torzijom i rotacijom.

Ključne riječi: Križobolja – etiologija; Lumbosakralno područje – dijagnostika; Kralješnica – fiziologija; Opterećenje – fiziologija; Biomehanika; Leš