

CEREBROVASCULAR DISEASE EVALUATION WITH MAGNETIC RESONANCE IMAGING AND MAGNETIC RESONANCE ANGIOGRAPHY

Martina Špero, Miljenko Kalousek, Zoran Rumboldt, Josip Hat, Darko Bedek and Vladimir Kalousek

Section of Neuroradiology, Department of Interventional and Diagnostic Radiology,
Sestre milosrdnice University Hospital, Zagreb, Croatia

SUMMARY – Magnetic resonance imaging (MRI) is an important imaging technique for evaluation of cerebral ischemic changes. Using magnetic resonance angiography (MRA), both large and medium sized intracranial arteries and veins can be visualized by selecting appropriate imaging parameters. The aim of this retrospective study was to evaluate our own results in the diagnosis of cerebrovascular diseases with MRI and MRA, and to compare them with literature data. Data on 278 patients with cerebrovascular symptomatology (158 female and 120 male, mean age 45.54 years), examined between April 2001 and November 2002, were analyzed. MRA was performed in all 278, and both MRA and MRI in 231 patients. On MRA, 90 pathologic alterations of intracranial arteries (69 aneurysms and 21 vascular malformations), 13 intracranial arterial occlusions, 19 intracranial arterial stenoses, and 14 cases of intracranial arteriosclerotic changes were identified. On MRI, 114 strokes (73 brain infarctions, 22 cerebral hemorrhages and 19 sub-arachnoid hemorrhages), 14 vascular malformations and 14 cases of small vessel disease were detected. MRI was found to be a powerful tool to detect ischemic lesions immediately upon stroke onset. MRA is highly sensitive for the detection of occlusive disease in large intracranial arteries. For cerebral venous and sinus thrombosis, MRI and MRA are first line studies. MRA of extracranial and intracranial vessels alone or in combination with transcranial color-coded duplex sonography (TCCD) as well as computed tomography angiography (CTA) may eliminate the need of intra-arterial digital subtraction angiography (DSA) in most patients studied for occlusive cerebrovascular disease. DSA may be reserved for those patients in whom there is a disagreement among the results obtained by use of noninvasive techniques, and for the diagnosis of arteriovenous malformations, whereas MRA can prove useful on follow-up examinations.

Key words: *Cerebrovascular disorders – diagnosis; Cerebral angiography – methods; Magnetic resonance imaging; Magnetic resonance angiography*

Introduction

Within less than a decade, magnetic resonance imaging (MRI) has become a powerful tool for accurate and early diagnosis of cerebral ischemia and has proved helpful in rational therapy for vascular pathology. Spin-echo

(SE) and fast spin-echo (FSE) images show the localization and extent of ischemic areas. Magnetic resonance angiography (MRA) has emerged as an adjunct to MRI and serves as a means for evaluating cerebral arteries and veins. MRA can be used to display major vascular anatomic details in stroke patients without the need of contrast agent injection, and further refinements can provide functional information on flow dynamics in the circle of Willis. The reported accuracies of MRA on visualization of the circle of Willis lie between 71% and 100%¹.

The advent of MRI has significantly changed the use of computed tomography (CT). However, in most insti-

Correspondence to: *Martina Špero, M.D./Prof. Miljenko Kalousek, M.D., Ph.D.*, Section of Neuroradiology, Department of Interventional and Diagnostic Radiology, Sestre milosrdnice University Hospital, Vinogradska c. 29, HR-10000 Zagreb, Croatia

Received April 11, 2003, accepted December 5, 2003

tutions, CT is available around the clock, whereas MRI is not. Therefore, CT still plays a major role in the emergency workup of patients with cerebrovascular diseases such as stroke, and subarachnoid and intracerebral hemorrhage.

In many centers, MRA has replaced conventional catheter-based digital subtraction angiography (DSA) for intracranial vascular disease screening². This is due to its noninvasiveness, whereas DSA has a permanent neurologic complication rate of 0.07% to up to 0.5%³⁻⁵. Further advantages of MRA are satisfactory images of the intracranial vasculature with the possibility to view the vessels from numerous angles, and MRA allows for some quantification of intracranial flow. MRA has lower cost of examination as compared with DSA. The disadvantages of MRA are reduced visualization of small distal branches, poor temporal information, and dependence on the flow or patient's cooperation. The high quality of intracranial MRA is based on the substantial flow effect throughout the cardiac cycle, a small volume of interest, and minimal effects of the most common causes of MR artifacts such as respiration, cardiac motion, and susceptibility changes on the head.

There are several applications where MRI and MRA using widely available techniques can be recommended for evaluation of intracranial vascular pathology such as stroke, arterial stenosis and occlusion, cranial aneurysms, arteriovenous malformations (AVMs), tumors, venous pathology, and vascular compression. The aim was to evaluate our own results in the diagnosis of cerebrovascular diseases with MRI and MRA, and to compare them with literature data.

Patients and Methods

Patients

In this retrospective study we evaluated medical records and reports of MRA and MRI findings of patients with suspected or confirmed cerebrovascular disease who had undergone MR imaging studies between April 2001 and November 2002. During the 20-month period, a total of 278 MRAs of intracranial arteries were carried out in 158 (56.83%) female and 120 (43.17%) male patients, mean age 45.54 (range 10-75) years. In 231 of 278 patients, MRI was also performed.

MRA studies were requested for the following clinical diagnoses: focal brain dysfunction⁶ (n=142; 51.08%): transient ischemic attacks (TIAs) (n=38; 26.76%) and stroke (n=104; 73.24%) – brain infarction (n=36), brain hemorrhage (n=13), subarachnoid hemorrhage (SAH) (n=55); pathologic alterations in cerebral arteries (n=56; 20.14%):

cerebral aneurysm (n=38; 67.86%) and vascular malformation (n=18; 32.14%); inflammatory diseases (n=4; 1.44%): vasculitis (n=3) and meningitis (n=1); brain tumors (n=11; 3.96%); and other symptoms (n=31; 11.15%): cephalgia (n=12), convulsive disorders (n=9), syncope (n=2), epistaxis (n=2), trigeminal neuralgia (n=4), peripheral facial nerve paralysis (n=1) and tinnitus (n=1). For 34 (12.32%) patients, data were lost and unavailable at the time of the study. Clinical diagnoses for MRA study are summarized in Table 1.

Methods

MRI and MRA studies were performed with a 1.0-T MR imaging system (25 mT/m, Magnetom Harmony, Siemens, Erlangen, Germany) with a standard head coil. In 47 of 278 patients, only MRA study was performed, whereas the rest of study patients underwent MRI followed by MRA. The standard MRI study included diffusion weighted echo-planar sequence (DWI) in transverse plane, T1-weighted (T1W) SE sequence in sagittal plane, T2-weighted (T2W) fast SE sequence in transverse plane, fluid attenuated inversion recovery (FLAIR) fast SE se-

Table 1. Clinical diagnoses for magnetic resonance angiography (MRA) study

Clinical diagnosis	n	%
I Focal brain dysfunction	142	51.08
1 Transient ischemic attacks	38	26.76
2 Stroke	104	73.24
brain infarction	36	34.61
brain hemorrhage	13	12.50
subarachnoid hemorrhage	55	52.89
II Pathologic alterations in intracranial arteries	56	20.14
1 Vascular malformation	18	32.14
suspected arteriovenous malformation	14	77.78
embolized arteriovenous malformation	4	22.22
2 Aneurysm	38	67.86
suspected aneurysm	18	47.37
aneurysm after surgical clipping	11	28.95
aneurysm after endovascular therapy	9	23.68
III Inflammatory diseases	4	1.44
IV Brain tumor	11	3.96
V Other symptoms	31	11.15
VI Lost and unavailable data	34	12.23

quence in transverse plane, and T2*-weighted gradient-echo sequence in transverse plane.

MRA of intracranial arteries were performed with standard three-dimensional time-of-flight technique (3D TOF MRA), and in several cases using two-dimensional phase-contrast technique (2D PC MRA). 3D TOF angiograms were reconstructed using maximum-intensity projection (MIP) images and multiplanar projection reconstruction (MPR).

Results

MR angiograms

MRA was performed in 278 patients with cerebrovascular symptomatology. The documentation of MRA studies for 21 (7.56%) patients were lost and unavailable at the time of the study. In the rest of 257 patients the results of MRA studies were as follows: 123 (47.86%) normal MR angiograms and 134 (51.14%) pathologic angiograms. In 27 (20.15%) of 134 abnormal studies there were two coexistent pathologic findings: 6 cases of two aneurysms in the same patient, 1 case of multiple aneurysms of the basilar artery (BA), 1 case of posterior inferior cerebellar artery (PICA) aneurysm and arteriovenous malformation (AVM), and 20 cases of arteriosclerotic disease with other pathologic changes (stroke, aneurysm) at the same time. Thus, 160 abnormal findings were recorded in 134 MR angiograms.

There were 90 (55.56%) cases of pathologic alterations in cerebral arteries: 69 (76.67%) cases of aneurysms and 21 (23.33%) cases of vascular malformation. In 52 (75.36%) of 69 patients we identified aneurysms of the anterior communicating artery (ACoA) (n=14), middle cerebral artery (MCA) (n=9), internal carotid artery (ICA) (n=9), posterior communicating artery (PCoA) (n=7), BA (n=5), anterior cerebral artery (ACA) (n=3), PICA (n=2), posterior cerebral artery (PCA) (n=1), vertebral artery (VA) (n=1) and superior cerebellar artery (SCA) (n=1). Seventeen (24.64%) of 69 patients with cerebral aneurysm underwent surgical clipping (n=8) or endovascular therapy (n=9). Twenty-one (23.33%) cases of vascular malformation included 12 AVMs, 2 venous angiomas and 1 case of carotido-cavernous fistula, arteriovenous fistula and suspected AVM, and 4 cases of AVMs after endovascular treatment.

Arterial occlusions were identified in 13 (8.03%) cases, whereas arterial stenosis was identified with MRA in 19 (11.73%) cases. Arteriosclerotic changes were identified in 14 (8.64%) cases: 6 cases of carotid arteriosclero-

sis and 8 cases of carotid and vertebrobasilar arteriosclerosis.

Aplasia of an intracranial artery was found in 6 (3.70%) and a hypoplastic intracranial artery in 9 (5.56%) MR angiograms. Arterial changes due to vasculitis were found in 3 (1.85%) MR angiograms. Rare variations such as vascular displacement due to cerebral tumor or arterial aplasia at the level of pathologic process were found in 6 (3.70%) cases, whereas in 2 (1.23%) cases MRA findings were undefined. Results of abnormal MRA findings are summarized in Table 2.

MR imaging

MRI studies were performed in 231 of 278 patients who had previously undergone MRA study. MRI studies revealed 69 (29.87%) normal and 162 (70.13%) abnormal findings. In 9 (5.55%) of these 162 MRI studies we found two coexistent pathologic findings in the same patient: 3 cases of SAH with acute brain infarction in the MCA territory, 3 cases of chronic brain infarctions of both MCA and PCA territory, and 3 cases of subacute SAH with acute brain infarction in the MCA territory. Thus, 168 pathologic findings were recorded in 162 MRI studies.

Table 2. Pathologic magnetic resonance angiography (MRA) findings

MRA finding	n	%
I Pathologic alterations in intracranial arteries	90	55.56
1 Aneurysm	69	76.67
identified aneurysm	52	75.36
treated aneurysm (surgical, endovascular)	17	24.64
2 Vascular malformation	21	23.33
identified vascular malformation	17	80.95
treated arteriovascular malformation	4	19.05
II Arterial occlusion	13	8.03
III Arterial stenosis	19	11.73
IV Arteriosclerotic changes	14	8.64
V Aplasia of intracranial artery	6	3.70
VI Hypoplasia of intracranial artery	9	5.56
VII Vasculitis	3	1.85
VIII Rare variations	6	3.70
IX Undefined	2	1.23

In 114 (67.82%) patients, abnormal signal on MR images was related to stroke: brain infarction in 73 (64.04%), brain hemorrhage in 22 (19.30%), and SAH in 19 (16.66%) cases. In 30 (41.10%) of 73 cases with brain infarction, the lesions were acute and involving vascular territory of MCA (n=20), PCA (n=4), ACA (n=1), PICA (n=1), pons (n=3) and hemiparesis alterna (n=1), whereas in 43 (58.90%) cases brain infarctions were in the chronic phase including hemispheric infarction (n=7), lacunar infarction (n=5), chronic infarction of MCA (n=17), PCA (n=7), ACA (n=3), PICA (n=1), pons (n=1), and hypertensive and Binswanger's encephalopathy in one case each. Twenty-two (19.30%) cases of brain hemorrhage included 4 cases of acute hematoma, 10 cases of subacute and 8 cases of organized intracerebral hematoma. Eight of 19 cases (16.66%) of SAH were acute, 4 were acute with intracerebral hematoma, 6 were subacute, and in 1 case SAH was chronic.

In 3 of 14 (8.34%) cases of vascular malformation cerebral aneurysms were identified, i.e. aneurysm of ICA, MCA and SCA, in 10 cases AVMs were identified, with 1 case of the follow up after endovascular treatment.

In 14 (8.34%) cases we found nonspecific changes probably due to small vessel disease (high signal on T2W and FLAIR sequence), whereas demyelination process – multiple sclerosis was detected in 3 (1.79%) cases.

In 8 (4.76%) cases we identified infectious (encephalitis and leptomeningitis) diseases, in 2 (1.21%) cases brain tumors, and in 7 (4.17%) cases changes related to brain aging. Rare pathologic changes such as Dandy-Walker syndrome, focal cortical dysplasia, facial nerve edema and brain compression by a dilated artery were observed in 6 (3.57%) cases. Results of pathologic MRI findings are summarized in Table 3.

Discussion

Today, MRI is an important imaging technique for accurate and early diagnosis of cerebral ischemia, whereas MRA, CT angiography (CTA) and transcranial color-coded duplex sonography (TCCD) are noninvasive techniques for the evaluation of intracranial circulation. MRA used alone or in combination with TCCD may eliminate the need of DSA in most patients studied for occlusive cerebrovascular disease. DSA may be reserved for those patients in whom there is a disagreement among noninvasive techniques, and for the diagnosis of AVM.

The strength of MRI in stroke is its polymodal use: FSE images to show the macroscopic extent of ischemic tissue (i.e. the tissue with altered water content), MRA

to demonstrate large arterial and venous disease (the lack of arterial signal on MRA can be correlated with areas of infarction on MR images), perfusion studies using contrast agents to reveal abnormal flow dynamics at the capillary level, and diffusion-weighted techniques to visualize changes in molecular diffusion of water occurring with stroke. Diffusion of water molecules is modified immediately upon the onset of ischemia and changes with time. Therefore, using diffusion imaging, cerebral ischemia can be visualized much earlier than with conventional FSE techniques, and recent and old infarcts can be differentiated. In acute hemiplegia, DWI and MRA may be abnormal and guide to correct etiology hours before changes on FSE images occur. Thus, MRI is a powerful tool to detect ischemic changes in stroke immediately upon its occurrence and guide to the underlying etiology⁷. In patients presenting with cerebrovascular symptomatology, we identified 62 (54.39%) acute and subacute changes related to stroke by use of MRI.

Table 3. Pathologic magnetic resonance imaging (MRI) findings

MRI finding	n	%
I Stroke	114	67.82
1 Brain infarction	73	64.04
acute	30	41.10
chronic	43	58.90
2 Brain hemorrhage	22	19.30
acute	4	18.18
subacute	10	45.46
organized	8	36.36
3 Subarachnoid hemorrhage (SAH)	19	16.66
acute	8	42.11
acute SAH with intracerebral hematoma	4	21.05
subacute	6	31.58
chronic SAH	1	5.26
II Vascular malformation	14	8.34
1 Aneurysm	3	21.43
2 Arteriovenous malformation	11	78.57
III Small-vessel disease	14	8.34
IV Demyelination process	3	1.79
V Infectious disease	8	4.76
VI Brain tumor	2	1.21
VII Brain aging changes	7	4.17
VIII Rare variations	6	3.57

3D TOF MRA is the most widely used technique for the study of intracranial arteries. It uses a gradient-echo pulse sequence in conjunction with flow compensation (a technique to eliminate flow-related phase shifts that cause signal loss). Flowing blood appears bright (called flow-related enhancement) because fresh spins are constantly flowing into the plane of section, whereas stationary tissues appear dark. The resulting angiograms are referred to as 'white blood' or 'bright blood' images. The techniques to optimize background suppression and flow contrast use magnetization transfer or signal targeting with alternating radiofrequency. Alternatively, PC MRA is based on the phase shift produced by flow along a magnetic field gradient: PC scans utilize a combination of flow-encoding gradients along the predicted path of flow, which are adjusted so that they are sensitive to moving blood at a prespecified range of velocities within the imaging volume. These gradients generate phase shifts between stationary and moving spins, which accounts for the difference in signal intensity between stationary and flowing tissue. Specially calibrated acquisitions, using complex phase subtraction, can also be incorporated to actually measure mean blood flow velocities during the scan. The acquisition and post-processing times of 3D PC are relatively long when compared with comparable TOF acquisitions using equivalent spatial resolution, making the 3D PC methods clinically demanding. 2D PC is a rapid, robust sequence for the detection of flow with a relatively low resolution. More important, the pulse sequence gradient structure makes this method especially vulnerable to signal loss due to complex motion (i.e. turbulence), which is often present distally to tight stenoses, and therefore less accurate in visualizing vessel lumen in the atherosclerotic plaque region.

TOF techniques are much more commonly used in routine clinical evaluation of carotid arteriosclerosis as they are more easily implemented, do not require *a priori* knowledge of the flow velocities within the vessels of interest, and can be designed so that they are less susceptible to flow-related dephasing and intravascular signal loss at sites of stenoses.

Occlusions of major intracranial arteries, most frequently of the MCA or BA, can easily be demonstrated by MRA. Occlusion of smaller arteries is also possible to detect with careful image analysis. Correlation with MR images and clinical presentation is mandatory. Stenosis of an intracranial vessel can be suspected when its lumen suddenly narrows. If stenosis is severe, downstream signals will be reduced, indicating compromised flow. Low to

moderate stenoses are usually well demonstrated by MRA techniques, so that MRA can be used in screening for intracranial vascular diseases. The reported sensitivity and specificity of MRA for outlining high grade stenoses range between 86% and 100%⁸. Because of saturation of the slow-flowing blood distally to the stenosis, high grade stenoses inducing important local flow disturbances are generally overestimated both in diameter and in length. Very severe stenoses can simulate total obstruction, particularly on TOF MRA, again due to saturation, which can be lessened by the injection of gadolinium. MRA can demonstrate stenoses based on vasculitis: in moyo-moya disease, basal occlusions and hypertrophic collaterals in basal ganglia with associated infarcts in the cerebral parenchyma are visible on MRA as well as on plain FSE images⁹. MRA is recommended in case of vessel dissections⁸. Using MRI we found 49 (30.25%) patients with occlusive disease, which is lower than the reported range of MRA sensitivity and specificity. The reasons were patient selection for MRA examination, which was obvious from the clinical diagnoses for MRA, and experience of our neuroradiologists in the evaluation of MRA findings.

For cerebral venous and sinus thrombosis MRI and MRA are first-line investigations. Due to the hyperintense character of a fresh clot, most acute to subacute venous thromboses are already diagnosed on unenhanced T1W images. The purpose of MRA is to confirm the MRI diagnosis of cerebral venous occlusion and to evaluate the extent of venous occlusion (MR venography).

In presumed SAH, the unstable condition of many patients precludes MRI evaluation, and most patients are better served by CT followed by DSA or CTA. Our results on 75.36% of aneurysms identified with MRA are similar to more recent studies. Unpublished data from a study comparing MRA and DSA for aneurysm detection, conducted at our Department from October 2001 till July 2002, showed the MRA sensitivity to be 100%. A recent review of studies comparing MRA and DSA in patients with recent SAH yielded the sensitivity to range between 69% and 100% for detecting at least one aneurysm *per* patient. For the detection of all aneurysms the sensitivity is 70% to 97%, and specificity 75% to 100%^{10,11}. Therefore, MRA can be used on screening for cerebral aneurysms that have not bled. In diagnostic work-up of a patient with suspected cerebral aneurysm, MRA is expected to detect an aneurysm or to confirm its absence; to determine the exact topographic location including the vessel of origin, demonstration of the aneurysmal neck and clarification of the relationship to neighboring vessels; and to demonstrate the morphology and size of the

aneurysm. The follow-up of an aneurysm with MRA is impossible after surgical clipping due to susceptibility artifacts from the implanted material. After endovascular therapy with detachable coils, patients can frequently be adequately followed up with 3D TOF MRA, since platinum coils produce less artifacts. MRA is very well suited for the follow-up of patients with untreated aneurysms or after failure of endovascular therapy.

CT angiography is based on the technique of spiral CT. It can easily be obtained immediately after noncontrast CT upon which the diagnosis is first made. It is minimally invasive because it does not require intra-arterial catheterization. Compared with MRA, it implies radiation and requires injection of iodine-based contrast, but is much simpler to perform, especially in ill patients. The sensitivity of CTA as compared with DSA is 85% to 98%¹⁰, in the same range as that of MRA, whereas recent studies have shown higher sensitivity of CTA for detecting very small aneurysms^{12,13}. On the other hand, with the use of CTA the aneurysms can be detected that have been missed on conventional angiography¹⁴. In patients with the perimesencephalic pattern of hemorrhage on CT, CTA only is the best diagnostic strategy; DSA can only be performed if CTA is negative, and if uncertainty exists about the presence or location of a vertebrobasilar aneurysm on CT angiogram^{15,16}. Multi-slice CTA is a significant improvement over single-slice CTA for cerebral aneurysms. The superior and precise images produced by multi-slice technology display anatomic information not readily available from standard DSA, whereas multi-slice 3D CTA provides better and adequate detail for surgical planning¹⁷. There is no doubt that DSA is on its way out for the pretreatment assessment of cerebral aneurysms, as the techniques of CTA and MRA are still improving, and as neurosurgeons and interventional neuroradiologists are becoming familiar with them.

AVMs are usually already visible on T2W MR images. Information such as the size and location of the nidus, mass effect, regions of gliosis, and old and fresh hemorrhage is provided. Angiography, DSA or MRA is used to demonstrate the number, size and location of the feeding arteries, the size of the nidus, and the presence of draining veins. In most patients, selective and superselective angiography remains necessary to decide what therapy is best for each of them. MRI with MRA can be used in the follow-up of cerebral AVMs after radiosurgery or embolization¹⁸.

In preoperative investigation of cerebral tumors, assessment of tumor size, location and vascularity is well done

by MR imaging. The resolution of MRA is insufficient to evaluate tumor vascularity, however, the venous anatomy needed for the decision on surgical approach, is effectively characterized by MRA, upon gadolinium injection. In stereotactic procedures, a combination of MRI and MRA is used to select target point and to define the safest needle trajectory and approach, thus increasing the safety of the procedure.

With appropriate technique, MRA is able to visualize the tortuosity of the SCA compressing the trigeminal nerve, and the AICA compressing the facial nerve at the cerebellopontine angle, causing trigeminal and facial neuralgia, facial nerve paralysis and hemifacial spasm. By correlation with MR imaging, the diagnosis of vascular compression can be made.

Modern evaluation of cerebrovascular diseases requires MRI and MRA studies of intracranial and extracranial arteries, so, regarding the clinical diagnosis, we recommend the following order of examinations: clinical examination, TCCD followed by MRI with DWI, and MRA of intracranial and extracranial arteries.

MRI and MRA have significantly changed the diagnosis and management of cerebrovascular diseases in the last decade, and this process will probably continue as long as there are further advances in MR hardware and software.

References

1. KATZ DA, MARKS MP, NAPEL SA, BRACCI PM, ROBERTS SL. Circle of Willis. Evaluation with spiral CT angiography, MR angiography, and conventional angiography. *Radiology* 1995;195:445-9.
2. WILMS G, BOSMANS H, DEMAEREL Ph, MARCHAL G. Magnetic resonance angiography of the intracranial vessels. *Eur J Radiol* 2001;38:10-8.
3. CLOFT HJ, JOSEPH GJ, DION JE. Risk of cerebral angiography in patients with subarachnoid hemorrhage, cerebral aneurysm, and arteriovenous malformation. *Stroke* 1999;30:317-20.
4. LEFFERS AM, WAGNER A. Neurological complications of cerebral angiography: a retrospective study of complication rate and patient risk factors. *Acta Radiol* 2000;41:204-10.
5. HEISERMAN JE, DEAN BL, HODAK JA, FLOM RA, BIRD CR, DRAYER BP, FRAM EK. Neurologic complications of cerebral angiography. *AJNR Am J Neuroradiol* 1994;15:1401-7.
6. WHISNANT JP, *et al.* Special Report from the National Institute of Neurological Disorders and Stroke: Classification of cerebrovascular diseases III. *Stroke* 1990;21:637-76.
7. BAUMGARTNER RW, MATTLE HP, AASLID R. Transcranial color-coded duplex sonography, magnetic resonance angiography, and computed tomography angiography: methods, applications, advantages, and limitations. *J Clin Ultrasound* 1995;23:89-111.

8. KRUG B, TERSTEGGE K, NEVELING M, ZÄHRINGER M, KUGEL H, LACKNER K. MRA in patients with cerebrovascular disease. Contraindications of clinical effectiveness. *Acta Radiol* 2000;41:1-7.
9. YAMADA I, MATSUSHIMAY, SUZUKI S. Moyamoya disease: diagnosis with three-dimensional time-of-flight MR angiography. *Radiology* 1992;184:773-8.
10. WARDLAW JM, WHITE PM. The detection and management of unruptured intracranial aneurysms (Review). *Brain* 2000;123:205-21.
11. WHITE PM, TEASDALE EM, WARDLAW JM, EASTON V. Intracranial aneurysms: CT angiography and MR angiography for detection – prospective blinded comparison in a large patient cohort. *Radiology* 2001;219:739-49.
12. VILLABLANCA JP, HOOSHI P, MARTIN N, JAHAN R, DUCKWILER G, LIM S, FRAZEE J, GOBIN YP, SAYRE J, BENTSON J, VINUELA F. Three-dimensional helical computerized tomography in the diagnosis, characterization, and management of middle cerebral artery aneurysms: comparison with conventional angiography and intraoperative findings. *J Neurosurg* 2002;97:1322-32.
13. VILLABLANCA JP, JAHAN R, HOOSHI P, LIM S, DUCKWILER G, PATEL A, SAYRE J, MARTIN N, FRAZEE J, BENTSON J, VINUELA F. Detection and characterization of very small cerebral aneurysms by using 2D and 3D helical CT angiography. *AJNR Am J Neuroradiol* 2002;23:1187-98.
14. HASHIMOTO H, IIDA J, HIRONAKA Y, OKADA M, SAKAKI T. Use of spiral computerized tomography angiography in patients with subarachnoid hemorrhage in whom subtraction angiography did not reveal cerebral aneurysms. *J Neurosurg* 2000;92:278-83.
15. RUIGROKYM, RINKEL GJE, BUSKENS E, VELTHIUS BK, VAN GIJN J. Perimesencephalic hemorrhage and CT angiography. *Stroke* 2000;31:2976-83.
16. VELTHIUS BK, RINKEL GJE, RAMOS LMP, WITKAMP TD, VAN LEEUWEN MS. Perimesencephalic hemorrhage: exclusion of vertebrobasilar aneurysms with CT angiography. *Stroke* 1999;30:1103-9.
17. KATO Y, NAIR S, SANO H, SANJAYKUMAR MS, KATADA K, HAYAKAWA M, KANNO T. Multi-slice 3D-CTA – an improvement over single slice helical CTA for cerebral aneurysms. *Acta Neurochir* 2002;144:715-22.
18. BEDNARZ G, DOWNES B, WERNER-WASIK M, ROSENWASSER RH. Combining stereotactic angiography and 3D time-of-flight magnetic resonance angiography in treatment planning for arteriovenous malformation radiosurgery. *Int J Radiat Oncol Biol Phys* 2000;46:1149-54.

Sažetak

PROCJENA CEREBROVASKULARNE BOLESTI MAGNETSKOM REZONANCIJOM MOZGA I MAGNETSKOM ANGIOGRAFIJOM

M. Špero, M. Kalousek, Z. Rumboldt, J. Hat, D. Bedek i V. Kalousek

Magnetska rezonancija (MR) mozga je važna tehnika prikazivanja u procjeni ishemijskih promjena moždanoga parenhima. Magnetskom angiografijom (MRA) se birajući odgovarajuće parametre prikaza mogu pokazati i velike i male intrakranijske arterije i vene. Cilj ove retrospektivne studije bila je procjena vlastitih rezultata u dijagnostici cerebrovaskularnih bolesti pomoću MR mozga i MRA, te njihova usporedba s literaturnim podacima. Analizirani su podaci 278 bolesnika (158 žena i 120 muškaraca srednje životne dobi od 45,54 godine), koji su bili pregledani u razdoblju od travnja 2001. do studenoga 2002. Učinjeno je 278 postupaka MRA, a u 231 bolesnika učinjena je i MR mozga. MRA je otkrila 88 patološki promijenjenih intrakranijskih krvnih žila (69 aneurizma i 21 vaskularnu malformaciju), 13 okluzija intrakranijskih arterija, 19 stenoza intrakranijskih arterija, te 14 slučajeva arteriosklerotskih promjena intrakranijskih arterija. MR mozga otkrila je 114 cerebrovaskularnih inzulta (73 cerebralne ishemijske, 22 intracerebralne hemoragije i 19 subarahnoidnih hemoragija), 14 vaskularnih malformacija, te 14 slučajeva "patologije malih krvnih žila". MR mozga je moćno sredstvo u otkrivanju ishemijskih promjena neposredno nakon nastupa moždanog inzulta. MRA ima visoku osjetljivost za otkrivanje okluzivne bolesti velikih intrakranijskih arterija. MR mozga i MRA su osnovne pretrage za dijagnozu tromboze moždanih vena i sinusa. Samo se pomoću MRA ekstrakranijskih i intrakranijskih krvnih žila ili u kombinaciji s obojenom dupleks sonografijom krvnih žila glave i vrata (TCCD) te kompjutoriziranom tomografskom angiografijom (CTA) može isključiti potreba za intraarterijskom digitalnom subtrakcijskom angiografijom (DSA) u većine bolesnika pregledanih zbog okluzivne cerebrovaskularne bolesti. DSA može biti rezervirana za one bolesnike kod kojih postoji neslaganje između nalaza neinvazivnih metoda pregleda, te za dijagnozu arteriovenskih malformacija, dok se MRA može rabiti za daljnje praćenje.

Ključne riječi: Cerebrovaskularne bolesti – dijagnostika; Cerebralna angiografija – metode; Prikazivanje magnetskom rezonancijom; Angiografija magnetskom rezonancijom

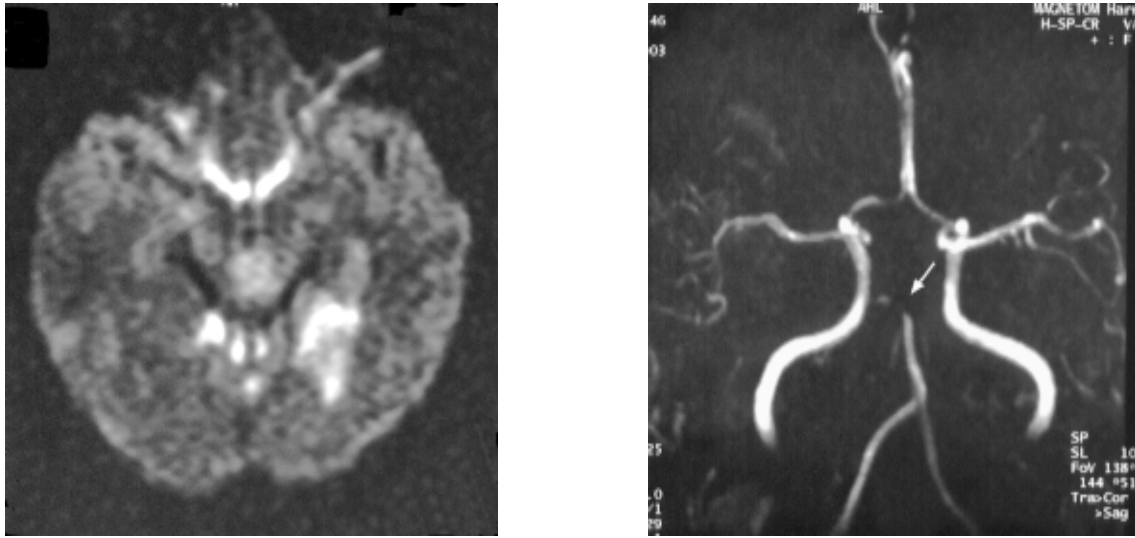


Fig. 1. A 57-year-old female patient with sudden onset of coma 4 hours before the examination: (a) transverse diffusion-weighted image: acute brain infarction of the left and part of the right occipital lobe and upper pontine structures; and (b) transverse MIP of 3D TOF MRA: thrombosis of the upper part of the basilar artery and left posterior cerebral artery, and stenosis of the right posterior cerebral artery (arrow).

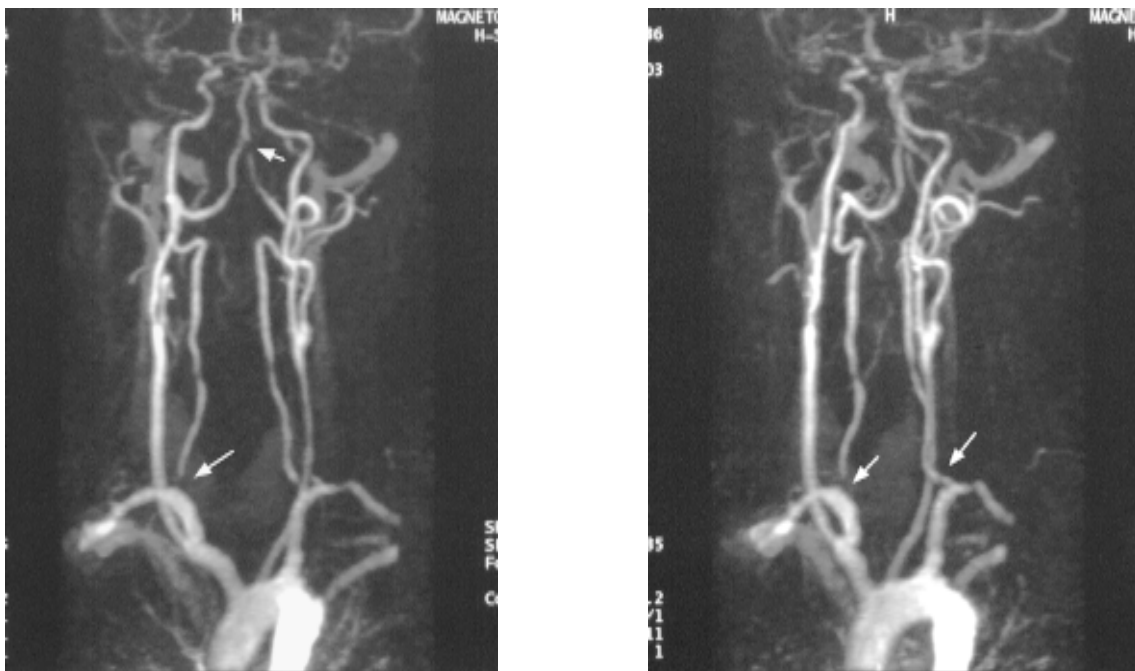


Fig. 2. A 67-year-old male patient with several transient ischemic attacks, stenosis of the left common carotid artery, and suspected stenosis of the origin of the basilar artery on color Doppler flow imaging and transcranial color Doppler: (a) coronal MIP of 3D TOF MRA: stenosis of the origin of the right vertebral artery (arrow), stenosis of the right vertebral artery at the origin of the basilar artery (arrow), and absence of visualization of the left posterior communicating artery; and (b) oblique coronal MIP of 3D TOF MRA: stenosis of the origin of both vertebral arteries (arrows).

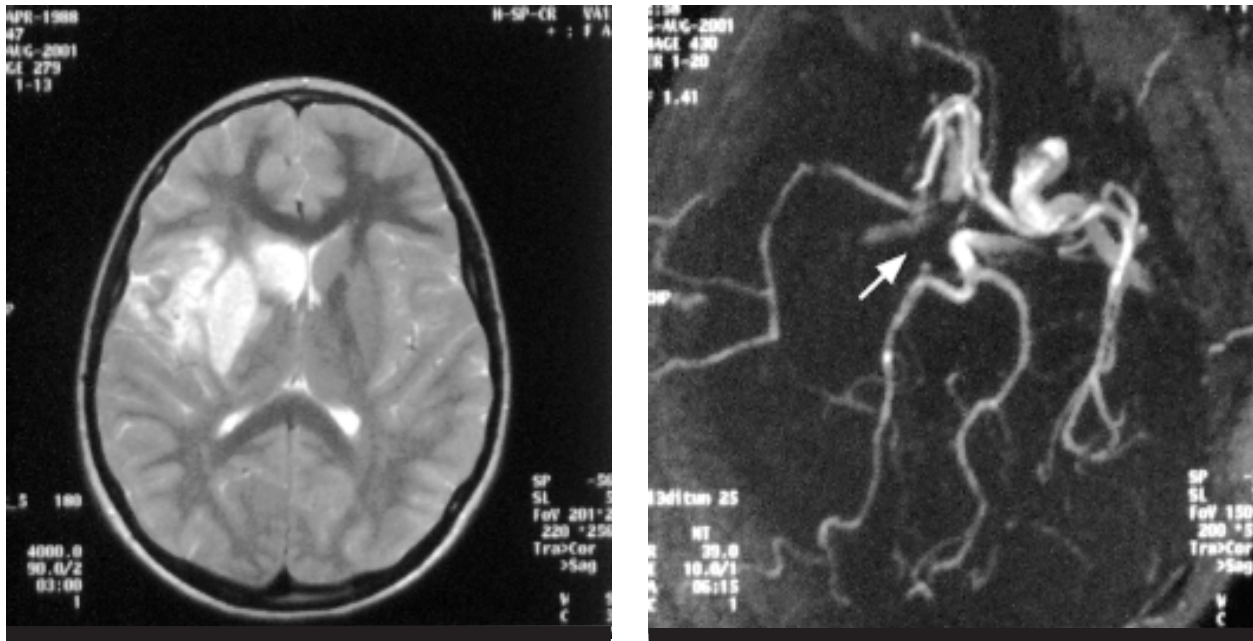


Fig. 3. A 13-year-old male patient with sudden onset of left-sided hemiparesis: (a) transverse T2W image: acute brain infarction including part of the territory of the right middle cerebral artery; and (b) transverse MIP of 3D TOF MRA: incomplete occlusion of the right middle cerebral artery (arrow).

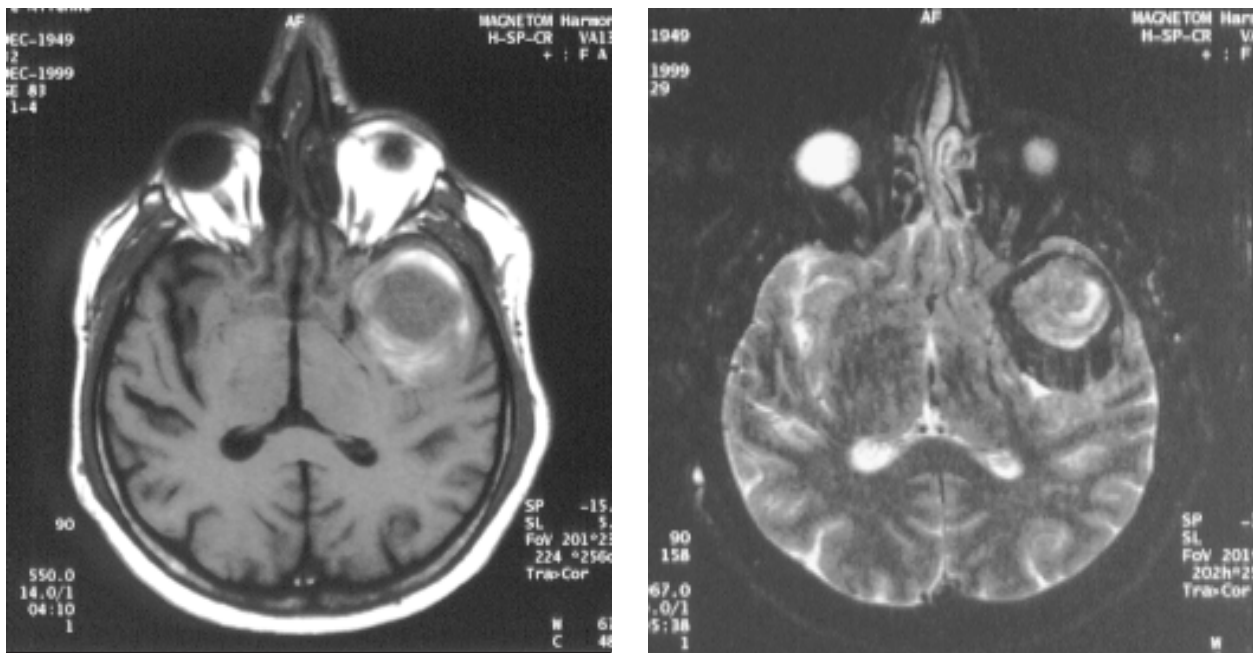


Fig. 4. A 50-year-old male patient with left-sided ophthalmoplegia and cephalaea: (a) transverse T2W image; and (b) transverse T1W image: giant aneurysm of the left middle cerebral artery.

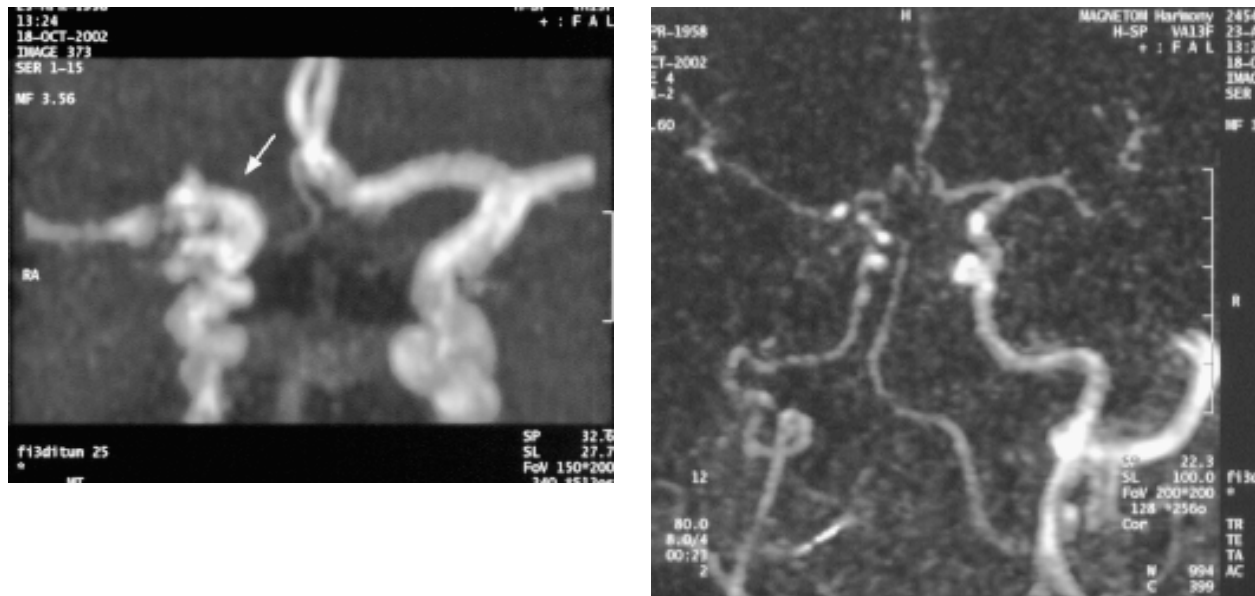


Fig. 5. A 44-year-old male patient with cephalgia: (a) transverse MIP of 3D TOF MRA: fibromuscular dysplasia (arrow); and (b) transverse MIP of 2D PC MRA: fibromuscular dysplasia.

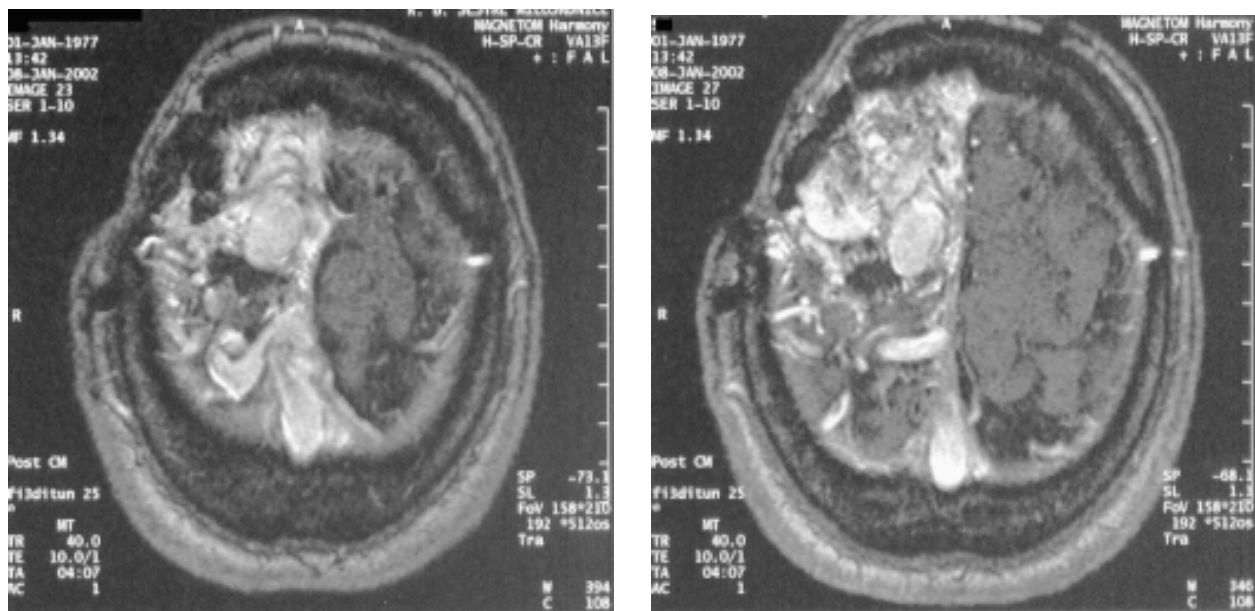


Fig. 6. A 25-year-old male patient with previously embolized right frontoparietal arteriovenous malformation: (a) and (b) contrast-enhanced transverse T2W images.

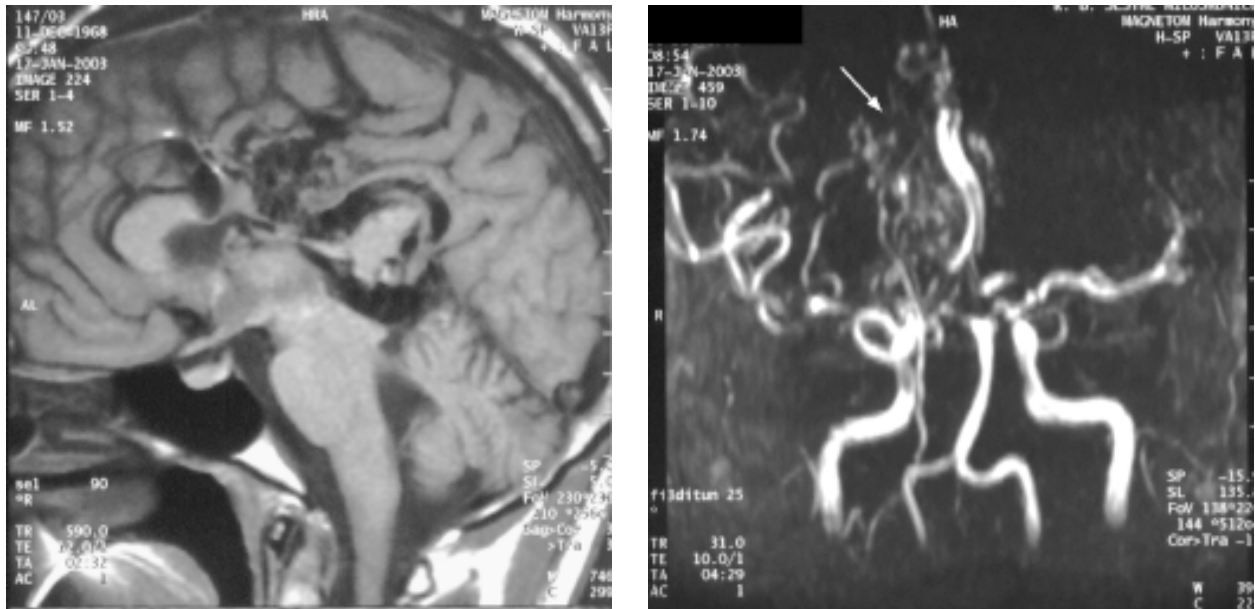


Fig. 7. A 35-year-old female patient with previously embolized arteriovenous malformation of the corpus callosum (arrows): (a) sagittal T1W image; (b) transverse MIP of 3D TOF MRA; and (c) coronal MIP of 2D PC MRA (venography).

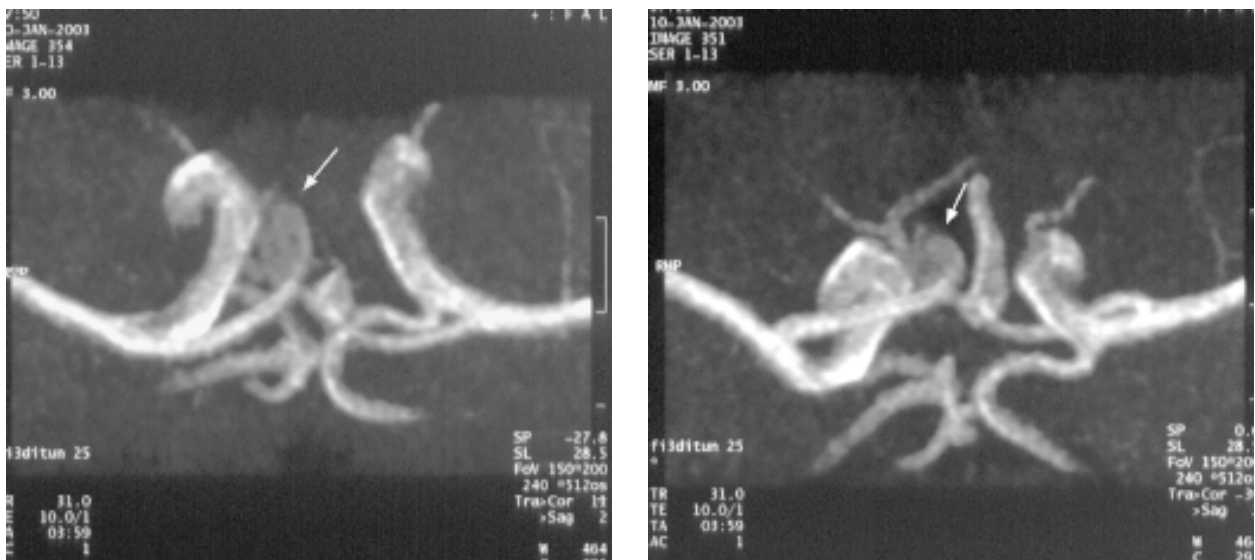


Fig. 8. A 70-year-old male patient with bitemporal reduction in the visual field: (a) transverse MIP of 3D TOF MRA: aneurysm of the anterior communicating artery (arrow); and (b) oblique transverse MIP of 3D TOF MRA: aneurysm of the anterior communicating artery (arrow).

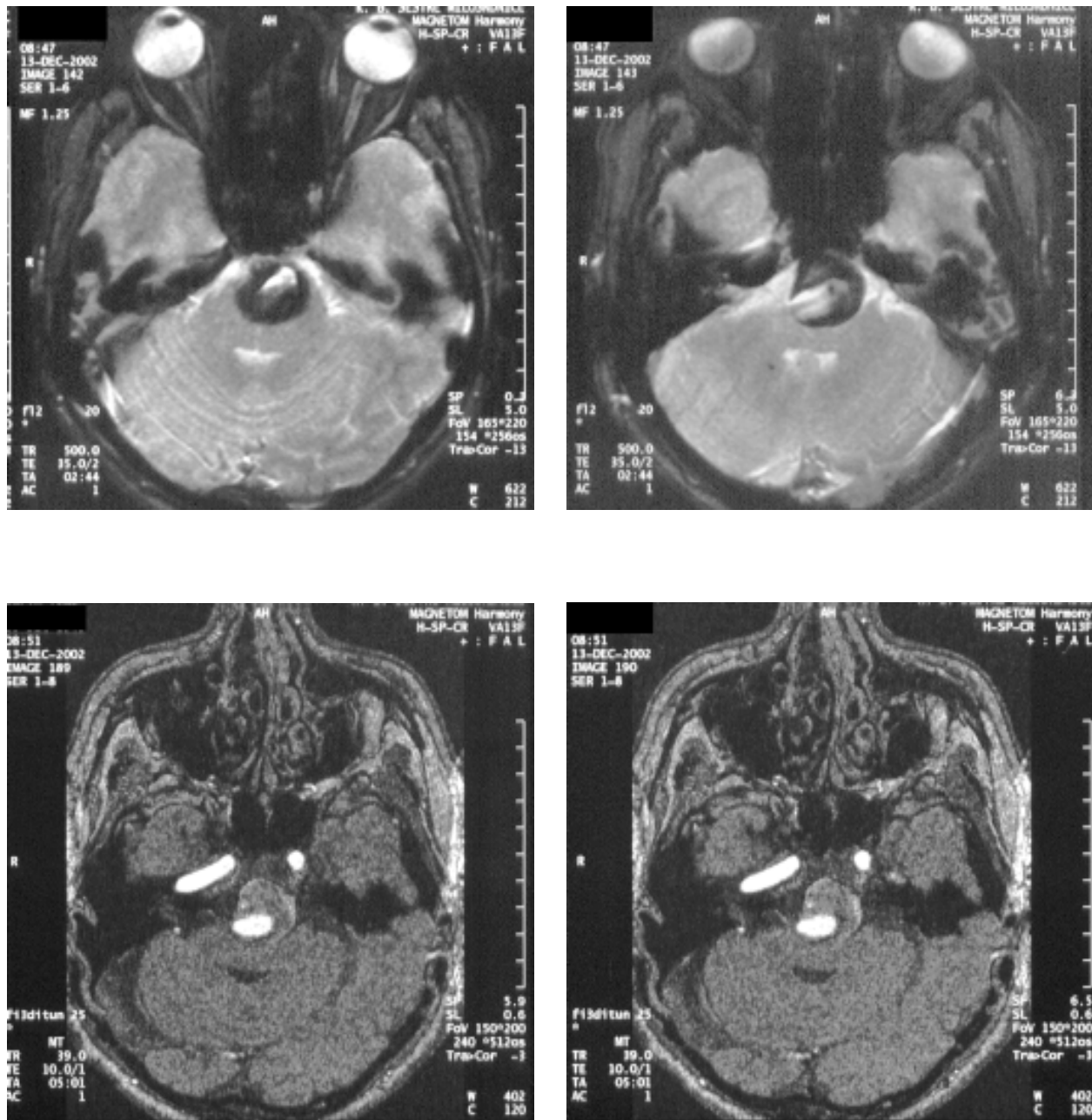


Fig. 9. A 60-year-old male patient with left oculomotor nerve paresis and epistaxis: (a) and (b): transverse T2-weighted gradient-echo images; (c) and (d) 3D TOF MRA: gigant aneurysm of the basilar artery.*