

SONOGRAPHIC FEATURES OF CRANIOCERVICAL ARTERY DISSECTION

Arijana Lovrenčić-Huzjan, Marijana Bosnar-Puretić, Vlasta Vuković and Vida Demarin

University Department of Neurology, Sestre milosrdnice University Hospital, Zagreb, Croatia

SUMMARY – Craniocervical artery dissection (CCAD) is primarily diagnosed by angiography, brain magnetic resonance (MR) or MR angiography. Color Doppler flow imaging (CDFI) has been underrated due to the localization of dissection, which appears to be most commonly localized intracranially. Nevertheless, dissection may manifest in various ways, enabling CDFI to present a broad spectrum of findings. The aim of this study was to analyze ultrasonographic findings in patients with clinical or ultrasonographic presentation of CCAD. Forty-three patients who presented with CCAD over a two-year period were retrospectively analyzed. Twenty-three of these patients showed clinical manifestations of CCAD, whereas in 19 patients ultrasound revealed double lumen or bifurcation stenosis with double lumen. Carotid and vertebral CDFI was performed on an Acuson 128 XP device. Color and power Doppler scans and hemodynamic spectra were analyzed. Data are presented descriptively. Data on 43 patients (28 male and 15 female, mean age 59 ± 11 years) were analyzed. There were 49 ultrasonographically detected dissected vessels (37 carotid, 10 vertebral and 2 subclavian arteries). A string sign was found in 5 patients (5 internal carotid arteries (ICA)), string and pearl sign in 2 patients (1 ICA and 1 vertebral artery (VA)), subintimal flow in one patient (1 ICA), double lumen in 12 patients (3 common carotid arteries (CCA), 7 ICA, 3 VA and 2 subclavian arteries); one patient presented as VA dissection and subarachnoid hemorrhage (SAH; ICA dissection on ultrasonography); carotid stenosis with double lumen under the plaque base was found in 17 patients (2 ACC, 13 bifurcation stenoses, and 2 ICA stenoses with dissection under the plaque base); hemodynamic spectra suggesting distal occlusion were detected in 8 patients (3 ICA, 6 VA); and multiple vessel involvement was present in 7 (16%) patients. Ultrasound can show a broad spectrum of findings in CCAD including direct evidence for intimal flap and detectable subintimal flow as well as signs of hemodynamically significant flow obstruction.

Key words: *Carotid artery diseases, diagnosis; Carotid artery internal dissection, diagnosis; Carotid artery, ultrasonography; Vertebral artery, ultrasonography*

Introduction

Craniocervical artery dissection (CCAD) is a relatively uncommon cause of stroke in the general population but is a common cause of stroke below the age of 40^{1,2}. It is being increasingly recognized as an important mechanism especially in stroke patients with mechanical trauma or manipulation to the head and neck. Internal carotid artery (ICA) dissections seem to be much more common than

vertebral artery (VA) dissection³⁻⁵. Multiple arterial involvement is quite common (8%-60%)⁶⁻⁹. The incidence of CCAD varies between 1 and 3 cases *per* year in large referral-based hospitals^{10,11}. It is possible that underrecognized CCADs exist^{2,4}.

Traditionally, catheter angiography has been established as a method of CCAD imaging which can show smooth or slightly irregular luminal narrowing, pseudoaneurysm, intimal flap or double lumen (specific but found in only <10%) or distal branch occlusion⁴. Magnetic resonance (MR) provides an image of eccentric or circumferential periarterial rim of intramural hematoma that typically shows a hyperintense signal on T1 and T2 weighted images^{10,12,13}. MR angiography has a limited value for im-

Correspondence to: *Arijana Lovrenčić-Huzjan, M.D.*, University Department of Neurology, Sestre milosrdnice University Hospital, Vinogradska c. 29, HR-10000 Zagreb, Croatia
E-mail: arijana-lovrenčić-huzjan@zg.hinet.hr

Received February 18, 2002, accepted in revised form October 6, 2002

aging the same pathomorphologic findings as angiography¹³. Doppler and duplex sonography has been underrated¹²⁻¹⁵. Although color Doppler flow imaging (CDFI) has shown good results in dissection visualization¹⁶⁻²¹, its main limitation is visualization of intracranial dissection, which appears to be the most common localization¹⁹.

The aim of this study was to analyze the spectrum of sonographic findings in patients who presented clinically or ultrasonographically with CCAD during a two-year period.

Patients and Methods

Data on 43 patients with CCAD, examined at Cerebrovascular Laboratory of the University Department of Neurology, Sestre milosrdnice University Hospital in Zagreb from January 1, 1998 till December 31, 1999, were retrospectively analyzed. One group included 23 patients who presented with clinical and ultrasonographic manifestations of CCAD, and one patient with CCAD and subarachnoid hemorrhage (SAH). All these were treated as inpatients, 22 of them hospitalized at University Department of Neurology, one at University Department of Ophthalmology, and one at University Department of Otorhinolaryngology. The other group included 19 patients in whom ultrasound revealed double lumen, or common carotid or bifurcation stenosis with double lumen. There were five inpatients, two of them hospitalized at Department of Cardiology and three at University Department of Neurology. The remaining 14 patients were examined as outpatients referred by a neurologist, cardiologist or vascular surgeon for ultrasonographic evaluation.

In all patients, detailed history was obtained, and physical and neurologic examinations were performed. Color

and power Doppler flow imaging of the carotid, vertebral and subclavian arteries was performed on an Acuson 128 XP with a 7.5 MHz linear array transducer for morphologic investigation and 5 MHz pulsed Doppler for hemodynamic investigation by angle-corrected velocimetry. The sample volume was 1.5 mm. Sensitivity of the system for detecting motion was set for each subject to slightly above the level of color noise²²⁻²⁴. Transcranial Doppler was performed in all patients with a TCD 3D EME and DWL MultiDop XP, 2 MHz probe²⁵. DWL MultiDop XP emboli detection²⁶ and digital subtraction angiography were performed in selected patients.

According to ultrasonographic characteristics, the findings were divided into 6 groups: string sign, string and pearl sign, subintimal flow, double lumen with septum (membrane) between the lumina, common carotid or bifurcation stenosis with double lumen under the plaque base, and hemodynamic spectra suggesting distal occlusion²⁷.

Data are descriptively presented.

Results

Data on 43 patients (28 male and 15 female), mean age 59 ± 11 years, who presented with 49 ultrasonographically detected dissected vessels (37 carotid, 10 vertebral and 2 subclavian arteries), were retrospectively analyzed. String sign (Fig. 1) was present in 5 patients (4 male and 1 female) in 5 ICA. String and pearl sign (Fig. 2) was present in 2 patients: 1 ICA (1 male) and 1 vertebral artery (VA) (1 female). Subintimal flow (Fig. 3) was found in one ICA of one male patient. Double lumen (Fig. 4) was detected in 12 patients (3 female and 9 male): 3 common carotid arteries, 7 ICA, 3 VA and 2 subclavian arteries. One female presented as VA dissection and SAH, however, ultrasound

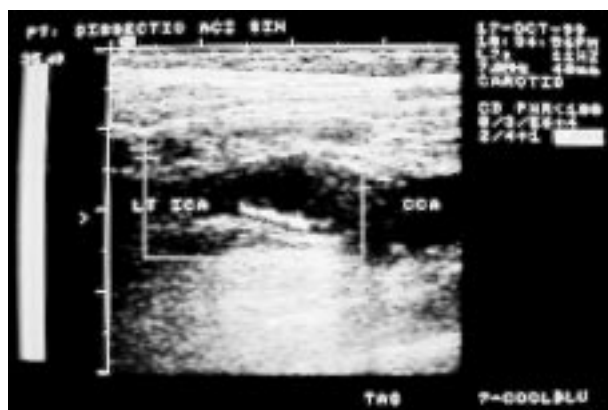


Fig. 1. String sign in ICA. String sign in the left internal carotid artery (ICA): narrow color-coded flow in the left ICA is visible. The rest of the lumen is filled with hematoma.

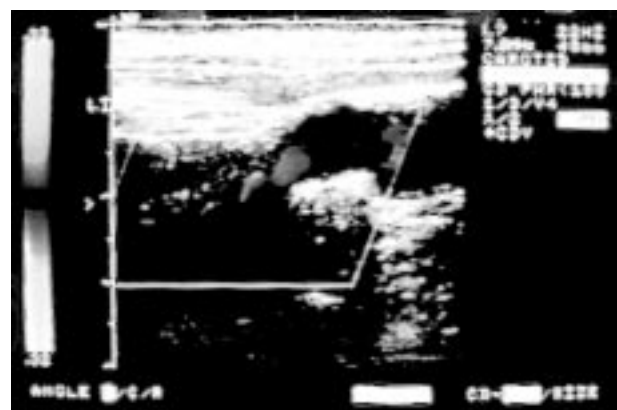


Fig. 2. String and pearl sign.

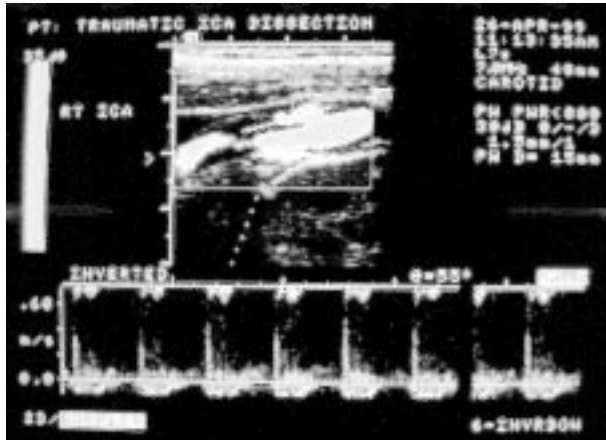


Fig. 3. Subintimal flow. Subintimal flow in the right internal carotid artery (ICA) is visible by use of power Doppler.

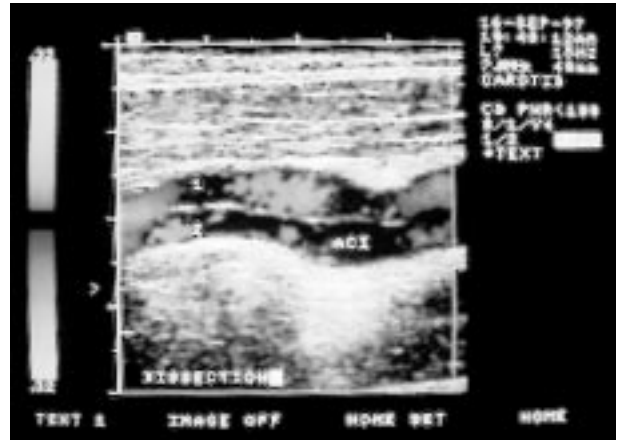


Fig. 4. Double lumen. Double lumen in the left internal carotid artery (ICA): the real and false lumina are separated by septum.

revealed ICA dissection. Carotid stenosis with double lumen under the plaque base (Fig. 5) was found in 17 patients (10 male and 7 female): 2 common carotid arteries, 13 bifurcation stenoses and 2 ICA stenoses with dissection under the plaque base. Hemodynamic spectra suggesting distal occlusion (Fig. 6) were found in 8 patients (5 male and 3 female): 3 ICA and 6 VA.

Multiple vessel involvement was found in 7 (16%) patients: in one female presenting as vertebral dissection and SAH, ICA dissection (double lumen) was found on ultrasonography and confirmed by angiography; in one male both ICA (string sign and subintimal flow); in one male ICA and VA (with distal occlusion of both, ICA recanalized after one year); in one male ICA (double lumen) and VA (distal occlusion, recanalized after one month); in one female ICA (string sign) and VA (distal occlusion); in

one male both common carotid arteries and 1 subclavian artery (double lumina all); and in one female ICA (double lumen) and VA dissection clinically suspected (not confirmed by ultrasonography).

Discussion

We found a broad spectrum of ultrasonographic findings in patients who clinically presented as CCAD. Previous studies were focused primarily on angiographic findings of CCAD, which can show string sign, intimal flap, double lumen, dissected aneurysm, and tapered stenosis with or without aneurysm formation^{4,13}. MR images visualize mural hematoma^{13,16}. CCAD is a changing rather than stable arterial disease, therefore serial follow-up studies are required. Noninvasive monitoring such as color Doppler

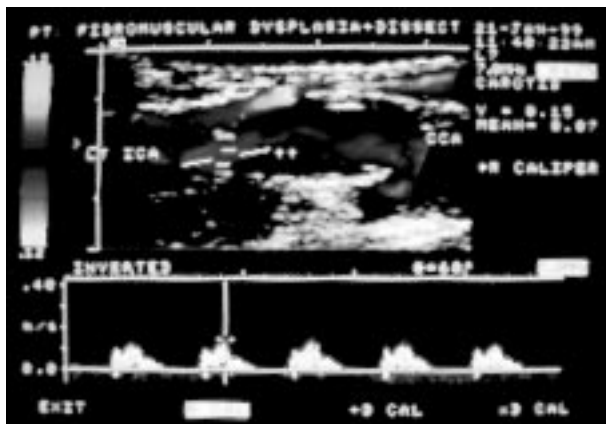


Fig. 5. Carotid stenosis with double lumen under the plaque base. Carotid stenosis with double lumen under the plaque base: the flow in the false lumen is seen by use pulsed Doppler spectrum.

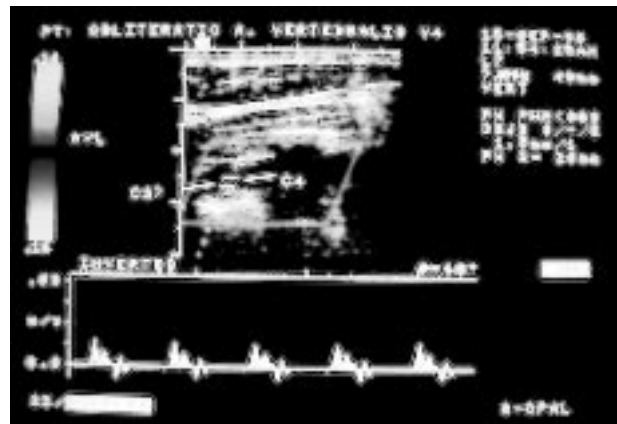


Fig. 6. Hemodynamic spectra suggesting distal occlusion.

ultrasound or MR provide a temporal profile of the recanalization¹⁶. The findings of Steinke *et al.* suggest that angiographic spectrum may be the consequence of visualization of the affected vessel in a different time interval from onset¹⁶. If angiography has not been performed during the first few hours, occlusion or pseudocclusion of the vessel is missed. Most ultrasound reports focus on Doppler spectra revealing a high resistance pattern^{14,16}. The diagnosis of dissection is usually based on a discrepancy between an abnormal Doppler signal and gray-scale image that shows a paucity of plaque^{28,29} as well as decreased carotid bulb velocities with either a high resistance or biphasic pattern or increased velocities. Other signs like intimal flap or double lumen are only described as case reports^{17,18}. Abrupt, smooth tapering of the arterial lumen also suggests dissection. For the possibility of performing ultrasonography within a short period from the onset of pain or ischemic symptoms, we were able to visualize a broad spectrum of CCAD. Distal occlusions were not missed owing to spectrum recognition early in the course of the disease²⁷. In two of these patients, complete recanalization was observed during the follow-up studies, with complete normalization of the hemodynamic spectra. Fisher *et al.*³⁰ were among the first to describe a variety of angiographic findings in 16 cases of spontaneous ICA dissection, only six of them verified. They included examples of angiographic string sign that actually turned out to be a severe atherosclerotic carotid disease. Although these are not truly spontaneous dissections in otherwise healthy vessels, the mechanism is similar. Atheromatous plaques may rupture, cause intimal tears, produce highly thrombogenic surfaces, and lead to thromboembolic stroke with carotid near-occlusion.

Multivessel involvement was observed in 7 (16%) patients, suggesting primary diseases of the arterial wall. It may occur at different times in different vessels. It may occur silently, without neurologic symptoms, and as such may be missed. A negative initial scan for dissection may be misleadingly encouraging. Therefore, repeat ultrasonic scans are required to reveal dissection or to show its progression or regression. Multivessel involvement was found from one third of patients⁴ to 7 of 23 patients³, and up to 7 of 10 patients¹². Besides the patients treated at Neurology Department, multivessel involvement was also found in two patients from Cardiology Department. These patients had a known aortic dissection radiating to the aortic arch vessels. Such a patient has been described as having visible double lumina in both common carotid arteries¹⁸. Our patients also had double lumina, and the dissection did not resolve on follow-up visits. In the false lumen, we observed the same high resistance pattern as reported by Tratting *et al.*¹⁸.

Monitoring of dissections was not possible in all patients. Whereas in some patients the dissection resolved (two patients with intracranial occlusion), the neurologic deficit persisted. On the contrary, Cardiology patients with double lumina had no ischemic or any other neurologic symptomatology. In these patients follow-up revealed no restoration. Patients with dissection under the plaque base were usually followed up for months, and dissection was observed to gradually resolve.

In case of SAH associated with aneurysm of VA³¹, an associated transmural dissection of intracranial VA cannot be excluded³². Various histologic stages can be seen in the same artery because the pathologic process proceeds in a stepwise manner. A dissecting aneurysm of the intracranial vertebral artery more frequently presents with SAH than ischemia. Extension of the dissection process involving the origin of the posterior-inferior cerebellar artery may not be apparent on the initial angiogram³³. Such a dissecting vertebral artery presenting as SAH with a posterior-inferior cerebellar artery aneurysm was present in our patient. Vertebral artery dissection may present as SAH, as seen in our patient.

Detection of emboli by TCD is an important tool for further treatment decision, because emboli positive CCAD patients are at a higher risk of developing ischemic symptoms^{34,35}. Heparin is therapy of choice in patients with CCAD³⁶. Some dissections resolve spontaneously within a short period of time, whereas other present continuously with ischemic symptoms, thus noninvasive monitoring is required¹⁶. TCD can therefore be used as an adjunctive tool to manage patients with suspect carotid dissection and may prove useful in evaluating the efficacy of treatment in reducing microemboli and subsequent stroke.

Carotid and vertebral CDFI and power Doppler can show a broad spectrum of findings in CCAD. Thus, ultrasound is useful in CCAD screening and for enabling continuous monitoring of dissection evolution and restoration.

References

1. BOGOUSLAVSKY J, REGLI F. Ischemic stroke in adults younger than 30 years of age. Cause and prognosis. *Arch Neurol* 1987;44:479-82.
2. LEYS D, LUCAS C, GOERT M, DEKLUNDER G, PRUVO JP. Cervical artery dissections. *Eur Neurol* 1997;37:3-12.
3. MOKRI B, SUNDT TM, HOUSER OW, PIEPGRAS DG. Spontaneous dissection of the cervical internal carotid artery. *Ann Neurol* 1986;19:126-38.
4. HOUSER OW, MOKRI B, SUNDT TM, BAKER HL, REESE DE. Spontaneous cervical cephalic arterial dissection and its residuum: angiographic spectrum. *AJNR Am J Neuroradiol* 1984;5:27-34.

5. MOKRI B, HOUSER OW, SANDOK BA, PIEPGRAS D. Spontaneous dissections of the vertebral arteries. *Neurology* 1988;38:880-5.
6. STURZENEGGER M, HUBER P. Cranial nerve palsies in spontaneous carotid artery dissection. *J Neurol Neurosurg Psychiatry* 1993;56:1191-9.
7. SCHIEVINK WI, MOKRI B, O'FALLON M. Recurrent spontaneous cervical-artery dissection. *N Engl J Med* 1994;330:393-7.
8. LEYS D, MOULIN Th, STOJKOVIC T, for the DONALD investigators. Long term course of cervical-artery dissection. *Cerebrovasc Dis* 1995;5:43-9.
9. ZUBER L, MEARY E, MEDER JF, MAS JL. Magnetic resonance imaging and dynamic CT scan in cervical artery dissections. *Stroke* 1994;25:576-81.
10. SUE DE, BRANT-ZAWADZKI MN, CHANCE J. Dissection of cranial arteries in the neck: correlation of MRI and arteriography. *Neuroradiology* 34:273-8.
11. MAS JL, BOUSSER MG, HASBOUN D, LAPLANE D. Extracranial vertebral artery dissections: a review of 13 cases. *Stroke* 1987;18:1037-47.
12. HOFFMANN M, SACCO RL, CHAN S, MOHR JP. Noninvasive detection of vertebral artery dissection. *Stroke* 1993;24:815-9.
13. AUER A, FELBER S, SCHMIDAUER C, WALDENBERGER P, AICHNER F. Magnetic resonance angiographic and clinical features of extracranial vertebral artery dissection. *J Neurol Neurosurg Psychiatry* 1998;64:474-81.
14. RINGELSTEIN EB, ZEUMAN H, POECK K. Non-invasive diagnosis of intracranial lesions in the vertebrobasilar system. A comparison of Doppler sonographic and angiographic findings. *Stroke* 1985;16:848-55.
15. STURZENEGGER M, MATTLE HP, RIVOIR A, RIHS F, SCHMID C. Ultrasound findings in spontaneous extracranial vertebral artery dissection. *Stroke* 1993;24:1910-21.
16. STEINKE W, RAUTENBERG W, SCHWARTZ A, HENNERICI M. Noninvasive monitoring of internal carotid artery dissection. *Stroke* 1994;25:998-1005.
17. SIDHU PS, JONKER ND, KHAW KT, PATEL N, BLOMLEY MJK, CHAUDHURI KR, FRACKOWIAK RSJ, COSGROVE DO. Spontaneous dissections of the internal carotid artery: appearances on colour Doppler ultrasound. *Br J Radiol* 1997;70:50-7.
18. TRATTING S, RAND T, THURNHER M, BREITENSEHER M, DAHA K. Colour-coded Doppler sonography of common carotid artery dissection. *Neuroradiology* 1995;37:124-6.
19. BRAY de JM, LHOSTE P, DUBAS F, EMILE J, SAUMET JL. Ultrasonic features of extracranial carotid dissections: 47 cases studied by angiography. *J Ultrasound Med* 1994;13:59-64.
20. BARTELS E, FLUGEL KA. Evaluation of extracranial vertebral artery dissection with duplex color-flow imaging. *Stroke* 1996;27:290-5.
21. LOVRENČIĆ-HUZJAN A. The role of ultrasound in diagnosing nonatherosclerotic vasculopathies of the nervous system. *Acta Clin Croat* 1998;37 (Suppl 1):68-72.
22. LOVRENČIĆ-HUZJAN A, BOSNAR M, HUZJAN R, DEMARIN V. Frequency of different risk factors for ischemic stroke. A one-year survey of patients admitted to Neurology Department, Sestre milosrdnice University Hospital. *Acta Clin Croat* 1999;38:159-63.
23. LOVRENČIĆ-HUZJAN A, BOSNAR-PURETIĆ M, VUKOVIĆ V, MALIĆ M, THALLER N, DEMARIN V. Correlation of carotid color Doppler and angiographic findings in patients with symptomatic carotid artery stenosis. *Acta Clin Croat* 2000;39:215-20.
24. LOVRENČIĆ-HUZJAN A, DEMARIN V, BOSNAR M, VUKOVIĆ V, PODOBNIK-ŠARKANJI S. Color Doppler Flow Imaging (CDFI) of the vertebral arteries – the normal appearance, normal values, and the proposal for the standards. *Coll Antropol* 1999;1:175-81.
25. ALEXANDROV AV, DEMARIN V. Insonation technique and diagnostic criteria for transcranial Doppler sonography. *Acta Clin Croat* 1999;38:97-108.
26. DEMARIN V, RUNDEK T, VUKOVIĆ V. Prevalence of cerebral emboli in patients with carotid artery disease. In: KLINGER-HÖFER J, BARTELS E, RINGELSTEIN EB, eds. *New trends in cerebral hemodynamics and neurosonology*. Amsterdam: Elsevier, 1997:420-4.
27. LOVRENČIĆ-HUZJAN A, VUKOVIĆ V, BOSNAR-PURETIĆ M, DEMARIN V. Sonographic features of vertebral artery occlusion (the role of color and power Doppler imaging). *Acta Clin Croat* 1999;38:279-84.
28. PROVENZALE JM. Dissection of the internal carotid and vertebral arteries: imaging features. *AJR Am J Roentgenol* 1995;165:1099-104.
29. SCHIEVINK WI. Spontaneous dissection of the carotid and vertebral arteries. *N Engl J Med* 2001;344:898-906.
30. FISHER CM, OJEMANN RG, ROBERSON GH. Spontaneous dissection of cervico-cerebral arteries. *Can J Neurol Sci* 1978;5:9-19.
31. KAPLAN SS, OGILVY CS, GONZALEZ R, GRESS D, PILE-SPPELLMAN J. Extracranial vertebral artery pseudoaneurysm presenting as subarachnoid hemorrhage. *Stroke* 1993;24:1397-9.
32. BIOUSSE V, BOUSSER MG, MAS JL. Extracranial vertebral artery dissection presenting as subarachnoid hemorrhage. *Stroke* 1994;25:714-5.
33. LATCHAWRE. The role of CT angiography in the long-term management of cerebrovascular dissection. *AJNR Am J Neuroradiol* 1998;19:992-3.
34. SRINIVASAN J, NEWELL DW, STURZENEGGER M, MAYBERG MR, WINN HR. Transcranial Doppler in the evaluation of internal carotid artery dissection. *Stroke* 1996;27:1226-30.
35. MOLINA CA, ALVAREZ-SABIN J, SCHONEWILLE W, MONTANER J, ROVIRA A, ABILLEIRA S, CODINA A. Cerebral microembolism in acute spontaneous internal carotid artery dissection. *Neurology* 2000;55:1738-41.
36. DEMARIN V, LOVRENČIĆ-HUZJAN A, ŠERIĆ V, VARGEK-SOLTER V, TRKANJEC Z, VUKOVIĆ V, LUPRET V, KALOUSEK M, DeSYO D, KADOJIĆ D, LUŠIĆ I, DIKANOVIĆ M, VITAS M. Recommendations for stroke management. *Acta Clin Croat* 2001;40:127-54.

Sažetak

SONOGRAFSKA OBILJEŽJA DISEKCIJE KRANIOCERVIKALNE ARTERIJE

A. Lovrenčić-Huzjan, M. Bosnar-Puretić, V. Vuković i V. Demarin

Dijagnoza disekcija krvnih žila glave i vrata postavlja se angiografijom, magnetskom rezonancijom (MR) mozga ili magnetskom angiografijom (MRA). Obojeni dopler krvnih žila glave i vrata podcijenjen je zbog lokalizacije disekcije, koja je najčešće smještena intrakranijski. Ipak, disekcija se može prikazati na različite načine, što omogućuje širok spektar nalaza obojenog doplera. Cilj ovoga rada je prikazati ultrazvučne nalaze u bolesnika koji su pokazivali kliničku sliku disekcije ili je ultrazvučni nalaz ukazivao na postojanje disekcije krvnih žila glave i/ili vrata. Analizirali smo 43 bolesnika tijekom dvije godine koji su se prikazali kao disekcija vratnih krvnih žila. Od toga je 23 bolesnika imalo kliničku sliku disekcije, a u devetoro bolesnika je ultrazvučno ustanovljen dvostruki lumen ili stenozna bifurkacije s dvostrukim lumenom. Obojeni dopler karotidnih i vertebralnih arterija učinjen je na Acuson 128 XP. Analizirali smo obojeni dopler i doplersku angiografiju, kao i hemodinamske spektre. Podaci su prikazani deskriptivno. Analizirali smo podatke za 43 bolesnika (28 muškaraca, 15 žena srednje dobi 59 ± 11 godina). Pomoću ultrazvuka ustanovili smo 49 diseciranih žila (37 karotidnih, 10 vertebralnih i 2 subklavijske arterije). Našli smo 'znak žice' u 5 bolesnika (5 unutarnjih karotidnih arterija (ICA)), 'znak žice i perle' u 2 bolesnika (1 ICA i 1 vertebralna arterija (VA)), subintimalni protok u jednog bolesnika (1 ICA), dvostruki lumen u 12 bolesnika (3 zajedničke karotidne arterije (ACC), 7 ICA, 3 VA, 2 subklavijske arterije), jedna bolesnica se prikazala kao disekcija VA i subarahnoidno krvarenje (ultrazvuk je pokazao disekciju ICA), zatim karotidnu stenozu s dvostrukim lumenom u bazu plaka u 17 bolesnika (2 CCA, 13 stenoza bifurkacije i 2 stenoze ICA s disekcijom u bazu plaka), dok je hemodinamski spektar ukazivao na distalnu okluziju u 8 bolesnika (3 ICA, 6 VA). Višestruka zahvaćenost krvnih žila bila je prisutna u 7 (16%) bolesnika. Ultrazvuk može pokazati širok spektar nalaza u disekciji krvnih žila glave i vrata, kao i znakove hemodinamski značajne opstrukcije protoka.

Ključne riječi: Bolesti karotidne arterije, dijagnostika; Disekcija unutarnje karotidne arterije, dijagnostika; Karotidna arterija, ultrasonografija; Vertebralna arterija, ultrasonografija