

CAROTID ANGIOPLASTY WITH CEREBRAL PROTECTION

Zoran Milošević¹, Bojana Žvan², Marjan Zaletel² and Miloš Šurlan¹

¹Clinical Radiology Institute and ²Department of Neurology, University Medical Centre Ljubljana, Ljubljana, Slovenia

SUMMARY – Carotid endarterectomy (CEA) is widely used in the management of high grade carotid stenosis. It is a surgical procedure requiring general anesthesia and is suitable only for lesions located at or close to the carotid bifurcation. It has complications, including stroke, death, cranial nerve palsies, wound hematoma and cardiac complications. The risk of complications is increased in patients with recurrent carotid artery stenosis following CEA, in subjects undergoing radiotherapy to the neck, and in the presence of cardiopulmonary disease. The drawbacks of CEA have led physicians to search for alternative treatment options. Carotid angioplasty and stenting (CAS) is less invasive than CEA. The method is particularly suitable for the treatment of recurrent stenosis after previous CEA and distal internal artery stenosis, which is inaccessible for CEA. CAS does not cause cranial nerve palsies. Moreover, it does not require general anesthesia and carries a lower morbidity and mortality in patients with severe cardiopulmonary disease. The complications of CAS include stroke due to distal embolization of a plaque or thrombus dislodged during the procedure, abrupt vessel occlusion due to thrombosis, dissection or vasospasm, and restenosis due to intimal hyperplasia. CAS is a relatively new procedure and it is essential to establish its efficacy and safety before it is introduced widely into clinical practice. In Slovenia, we have also started with carotid angioplasty by the study Slovenian Carotid Angioplasty Study (SCAS). According to our initial experience in 17 patients, CAS could gain more importance in stroke prevention with proper selection of patients with brain ischemia and improved cerebral protection during the procedure.

Introduction

Stroke is an important public health problem and the third most common cause of death, after heart diseases and cancer¹. In Slovenia, stroke incidence, measured as a first ever stroke *per* 100 000 population, is 190.5 and mortality rate is 19.3%². The proportion of ischemic stroke increases with age (33% before 45 and 80% after 50). Some 20% to 30% of all cases are supposed to be due to carotid stenosis³. The most common cause of carotid stenosis is atherosclerosis. The mechanism of brain is-

chemia has been thought to imply either a direct hemodynamic impact on the cerebral blood circulation or indirect as a source of thromboembolic material⁴. Three possible treatment modalities are available to prevent stroke caused by carotid stenosis. First is medical treatment, second surgical treatment, and third the newest approach, endovascular treatment by carotid angioplasty and stenting (CAS).

Platelet antiaggregants such as acetylsalicylic acid or ticlopidine reduce the risk of stroke^{5,6}. Recently, preventive treatment with clopidogrel in combination with acetylsalicylic acid has been recommended⁷. Correcting the risk factors such as smoking, obesity, dyslipidemia, hypertension, and diabetes is necessary.

In surgical approach, the atheromatous plaque is excised, removed, and the artery is sutured. The first operation on carotid artery, carotid endarterectomy (CEA),

Correspondence to: Zoran Milošević, M.D., Clinical Radiology Institute, Ljubljana University Medical Centre, Zaloška 2, SI-1525 Ljubljana, Slovenia
Phone: +386 1 5223421; Fax: +386 1 433 1044;
E-mail: zoran.milosevic@guest.arnes.si

was performed by DeBakey in 1953⁸. The number of the procedures increased in the following years. In 1984, 120 000 CEA operations were performed⁹, whereafter the number of CEA began to decrease because of uncertain effectiveness¹⁰. In 1991, randomized prospective surgical trials, North American Symptomatic Carotid Endarterectomy Trial (NASCET)¹¹ and European Carotid Surgery Trial (ECST)¹² demonstrated a significant stroke risk reduction by CEA compared with medical treatment in symptomatic patients with carotid stenosis greater than 70%. Reassessment of results by the American Heart Association (AHA) Stroke Council indicates that CEA was three times as effective as medical treatment in reducing the frequency of stroke¹³. However, CEA carries a risk of complications. The benefit of CEA depends on maintaining a low complication rate. Most important complications during the procedure are perioperative stroke and death. Combined stroke and death rates exceeding 3% for patients with asymptomatic stenosis and 6% for patients with symptomatic stenosis would eliminate the benefit in stroke reduction¹⁴. Postendarterectomy restenosis should also be mentioned, since it is not rare. The rate is estimated between 1.2% and 23.9%, depending on the operative technique¹⁵. The risk of complications associated with reoperation is high¹⁶. The rate of cranial nerve injuries due to neck incision is 7.6% to 27%¹⁷.

CEA is the 'gold standard' so far, but it is not without risks and limits as regards high risk patients (elderly patients, patients suffering from coronary diseases, respiratory insufficiency...), supra-aortic lesions located in the upper section, and carotid lesions associated with severe intracranial lesions. Therefore, less invasive CAS seems to have its place in the treatment of carotid stenoses.

CAS has a history of more than 20 years. After experiments on an animal model, in 1977 Mathias proposed the treatment of carotid stenosis using angioplasty for the first time¹⁸. The first carotid angioplasty was performed in 1980 by Kerber¹⁹. Carotid angioplasty with or without stenting has been investigated during the last two decades. This procedure has not received wide acceptance because of the risk of embolic stroke during the procedure. Till 1997, the rate of perioperative stroke following CAS without cerebral protection ranged from 5.3% to 8.2%^{20,21}. Initial results were criticized for the high rate of neurological complications²². The main cause of perioperative complications are thought to be embolic particles released from the carotid plaque during angioplasty²³. In 1990, Theron, the 'father' of a cerebral protection, developed and advocated the use of a cerebral protection device during

CAS²⁴. The risk of embolization and the need for cerebral protection during CAS was confirmed later²⁵.

The safety and efficacy of CAS with cerebral protection *versus* CEA were compared in a prospective randomized trial Carotid Revascularization Endarterectomy *versus* Stent Trial (CREST), launched at the beginning of 2001²⁶.

In Slovenia, we have also started with CAS by setting up the study Slovenian Carotid Angioplasty Study (SCAS), in order to evaluate the safety and efficacy of the method.

Patients and Methods

Study protocol

The study was designed as a prospective clinical trial conducted over a period of 2 years in 60 patients enrolled according to well-defined inclusion and exclusion criteria. The patients were evaluated independently by a neurologist prior to and during the procedure and follow-up examinations performed at 1, 6, 12 and 24 months. Evaluation of cerebral protection devices was incorporated in the study.

The safety of CAS was assessed on the basis of acute procedural success and occurrence of major clinical events during or within 30 days of the procedure. The efficacy of CAS was determined with respect to minor ipsilateral neurologic events, major stroke and death occurring during or within 30 days of the procedure, and recurrent stenosis established within 24 months of CAS.

Oral and written information on the study was provided to all patients, and a written, witnessed informed consent was obtained from each of them. The study was approved by the National Medical Ethics Committee.

Patients

We performed CAS in 17 patients aged 69 to 82 years, 12 male and five female. All patients were symptomatic with stenosis greater than 70%. Ten patients had suffered transient ischemic attacks, four patients minor stroke and three patients amaurosis fugax. Seven patients had stenosis of the right internal carotid artery, eight of the left internal carotid artery, and two of the right common carotid artery. Two patients had occlusion of the contralateral carotid artery. In the first six patients we did not use cerebral protection devices. In the other 11 patients cerebral protection filter devices were used.

Procedure

All patients were taking aspirin, 325 mg/d, and clopidogrel (75 mg/d) starting 7 days before the procedure. Heparin, given as an intra-arterial bolus, was titrated to maintain the activated clotting time between 200 and 250 seconds. The procedures were performed in local anesthesia. Neurologic status was monitored. Atropine (0.5-1 mg) was given as required during balloon inflation. Heart rate and blood pressure were monitored throughout the intervention.

Percutaneous access was gained through the femoral artery. Selective catheterization of carotid arteries was performed with standard techniques. Diagnostic angiography visualized the origins of the brachiocephalic arteries from the aortic arch, both carotid bifurcations, both vertebral arteries, intracranial parts of both carotid arteries and the dominant vertebral artery. Once diagnostic angiography was completed and the stenotic internal carotid artery was identified, a 5F catheter was advanced using a 0.035-inch glide wire (Terumo Radiofocus Guide Wire, Terumo, Inc.) into the ipsilateral external carotid artery. The glide wire was withdrawn and replaced with an extra stiff 0.035-inch exchange wire (Extra Stiff Amplatz Wire, 260 cm; Cook, Inc.). The 5F catheter was withdrawn, and an 8F 90-cm guiding sheath (Carotid Vista Brite Tip; Cordis, Inc.) was advanced into the common carotid artery over the exchange Amplatz wire, which was anchored in the external carotid artery. Carotid angiography was performed again to measure the vessel diameter to facilitate the sizing of balloons, stents and cerebral protection filter devices. In patients without cerebral protection, stenoses were then crossed with flexible coronary guidewires (V-18 Control Wire; Boston Scientific Corp, Watertown, Mass). Eleven patients underwent CAS with a cerebral protection filter device Angioguard (Cordis, Inc): a low-profile guidewire-based, filter-type device (4F) that was placed in the distal ICA after crossing the stenotic lesion. It captured embolic debris while maintaining distal perfusion. After that we started with the intervention on stenosis. The size of the initial angioplasty balloon was dictated by the severity of stenosis. Very severe lesions were predilated with low-profile coronary balloons (Bypass Speedy Monorail Catheter, Boston Scientific Corp); in case of less severe lesions, the initial dilatation might be performed with a definitive balloon sized to the distal normal artery. A Carotid Wallstent Monorail (Boston Scientific Corp) was deployed across the lesion. The stent was dilated at high pressure (14 to 16 atm) to firmly embed it into the vessel

wall. After that, the filter with trapped emboli was removed and the procedure was finished. Completion angiography was performed on the ipsilateral intracranial vessels. Patients were transferred to the intensive care unit, after which the sheaths were removed. Patients were discharged on either the first or second day after the procedure. Clopidogrel was continued for 3 weeks, and aspirin was continued permanently.

Results

Procedural results are summarized in Table 1. Technical success (<30% residual stenosis) was achieved in all cases. In 14 patients, no residual stenosis was found, whereas 15% residual stenosis persisted in two, and 30% residual stenosis in one patient.

In one patient (Patient 5, Table 1), hyperperfusion syndrome occurred. It occurred in a 72-year-old female with carotid stenosis of more than 90%, who had suffered amaurosis fugax in the past. Stenting was performed successfully without residual stenosis and immediate complications (Fig. 1). On day 5 after CAS, generalized seizure with Todd's hemiparesis on the right side occurred. Upon admission, we performed brain CT, which showed a small subarachnoid hemorrhage frontally on the left side (Fig. 2). She recovered completely after a week.

Periprocedural stroke occurred in one patient (Patient 6, Table 1). It was a 67-year-old male with a previous minor stroke and 90% stenosis of the left internal carotid artery due to a lipid-laden plaque and occluded right carotid artery. In this case, we used a cerebral protective filter. CAS was successfully performed (Fig. 3). Cerebral embolism occurred during filter removal. He developed aphasia and hemiplegia. The embolus at the middle cerebral artery bifurcation was dissolved by intra-arterial thrombolysis using rTPA (Fig. 4).

In 15 patients, CAS was performed without complications. In all patients, follow-up (average follow-up period of 3 months) revealed no transient ischemic attacks or new strokes. All patients remained at their neurologic baseline. Long-term clinical or imaging follow-up data are not yet available.

Discussion

Over the last years angioplasty has been successfully used in coronary and peripheral disorders and has also

Table 1. Procedure results in 17 patients

Pt	Vessel	Symptoms	Age, y	CLO	Stenosis %		Procedure stroke	Severe CAD	Comments
					Pre	Post			
1	R ICA	TIA	74		90	0	No	Yes	
2	L ICA	Stroke	72	Yes	99	0	No	No	
3	R ICA	TIA	63		70	0	No	No	
4	R CCA	TIA	68		80	0	No	Yes	
5	L ICA	Amaurosis fugax	72		95	0	No	No	After five days, an episode of seizure and transitory Todd's hemiparesis occurred. CT of the brain showed small subarachnoid hemorrhage on the left frontal side. After a week, she recovered completely.
6	L ICA	Stroke	67	Yes	87	0	Yes	Yes	Occlusion of right ICA. Cerebral embolism occurred during filter removal. He became aphasic and had right hemiplegia. We dissolved embolus at MCA bifurcation with intra-arterial thrombolysis using rTPA, but some hemiparesis persisted.
7	R CCA	TIA	66		80	0	No	No	Right iliac stenting in the same procedure.
8	L ICA	Amaurosis fugax	70	Yes	75	0	No	Yes	
9	R ICA	Stroke	64		90	15	No	No	
10	L ICA	TIA	68		76	0	No	No	
11	R ICA	TIA	82		80	0	No	Yes	
12	R ICA	TIA	68		71	0	No	No	
13	L ICA	TIA	82		75	0	No	Yes	
14	R ICA	TIA	61		73	0	No	No	
15	L ICA	Stroke	76		99	30	No	Yes	
16	R ICA	Amaurosis fugax	57		85	0	No	No	
17	L ICA	TIA	53		75	15	No	No	

Pt, patient; CLO, contralateral carotid occlusion; CAD, coronary artery disease; R, right; ICA, internal carotid artery; L, left; CCA, common carotid artery; MCA, middle cerebral artery;

*From patient 6 on, cerebral protection filter device used.

carotid angioplasty is to prevent cerebrovascular neurologic events and not to overshadow surgery. It could be an alternative or a complement to surgery if results are comparable or better. Indications must be defined through

been applied at the carotid level. Throughout the world, several teams are actively engaged in research in order to determine the indications, suitable techniques, adjunct treatments, and follow-up conditions. The final aim of

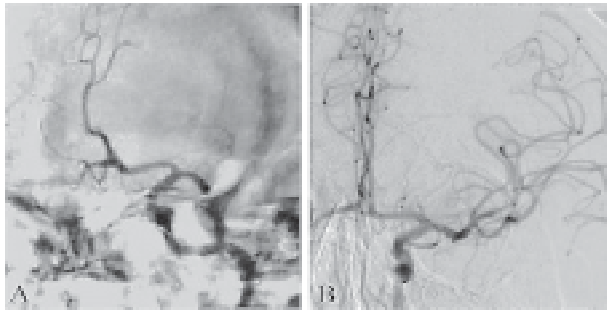


Fig. 1. Digital subtraction angiography. Lateral views of the left carotid artery bifurcation. A) High grade circumferential, atherosclerotic stenosis of the internal carotid artery origin before CAS. B) No residual stenosis after CAS.

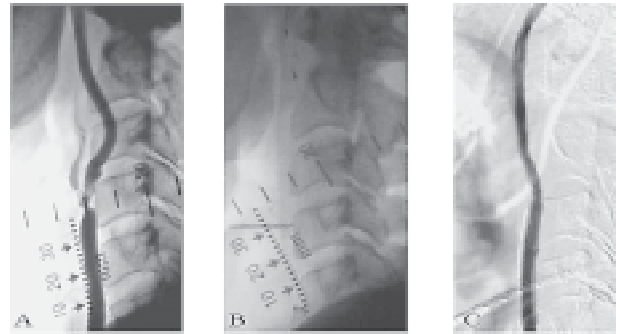


Fig. 2. CT of the brain shows small subarachnoid hemorrhage in the left frontal region.

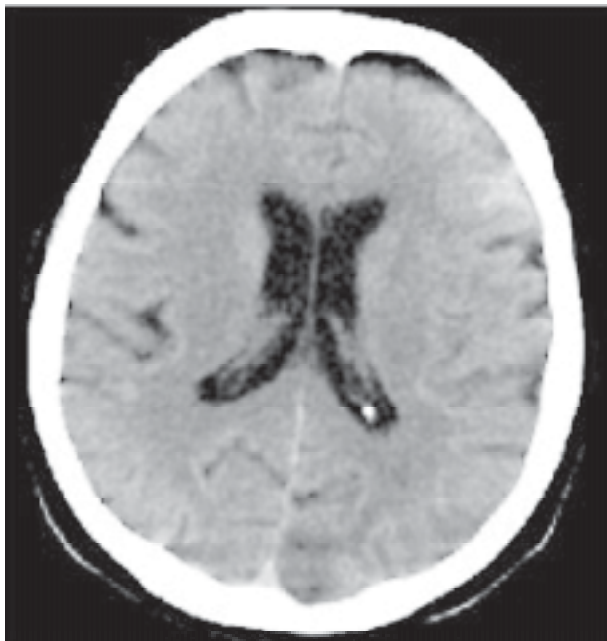

Fig. 3. Digital subtraction angiography. Lateral views of the left carotid artery bifurcation. A) 90% stenosis of the left internal carotid artery before CAS. B) Cerebral protection filter device during CAS. C) No residual stenosis after CAS.




Fig. 4. Digital subtraction angiography. Anteroposterior views of the left intracranial internal carotid artery with branches. A) Acute occlusion of the left middle cerebral artery at the bifurcation. B) Recanalization of the occlusion after intra-arterial thrombolysis.

randomized multi-center studies and are currently much debated. Some would like them to be limited to high risk patients, restenosis, radiation-induced lesions, or lesions located in the upper internal carotid artery near the skull, while others would like them to be much larger, including lesions of the carotid bifurcation²⁷. Lately cerebral protection devices have the potential to enhance the safety of CAS²⁸. First report of a larger series by Wholey²⁹ shows the rate of perioperative complications after CAS with

cerebral protection to be 1.6%, which is significantly lower than with CEA and CAS without cerebral protection.

Now we treat all patients using a cerebral protection filter device. In all filters, we found embolic material. In two cases, filters were occluded due to a massive amount of embolic material. We suppose that in such cases a high risk of complications exists, and it is very important to know the type of plaque that can dislodge a large amount of embolic material. For the evaluation of plaque compo-

sition we performed ultrasound. We did not perform CAS in patients with echolucent plaques (type 1) due to high embolic risk³⁰. Fibrous plaques seem to carry a very low risk of rupture and embolization. We expect to learn more about plaque composition using MRI. MR additionally shows the thickness of fibrous cap and pre-existent ruptures of the plaque³¹. By demonstrating thick or thin fibrous cap of the plaque and correlating data with the amount of emboli trapped in the filter, we could be able to analyze the risk of periprocedural complications. This information would enable better selection of patients for CAS. According to our initial experience in 17 patients, CAS could gain more importance in stroke prevention with proper selection of patients and improved cerebral protection during the procedure.

References

- HURST RW. Carotid angioplasty. *Radiology* 1996;201:613-6.
- ŽVAN B. Epidemiology of stroke in Republic of Slovenia. *Acta Clin Croat* 1998;37 (Suppl 1):95-7.
- De BAKEY M. Carotid endarterectomy revisited. *J Endovasc Surg* 1996;3:1-4.
- RILES TS, LIEBERMAN A, KOPELMAN I, IMPARATO AM. Symptoms, stenosis, and bruit: interrelationships in carotid artery disease. *Arch Surg* 1981;116:218-20.
- SZE PC, REITMAN D, PINCUS MM, SACKS HS, CHALMERS TC. Antiplatelet agents in the secondary prevention of stroke: meta-analysis of the randomized control trials. *Stroke* 1988;19:436-42.
- HASS WK, EASTON JD, ADAMS HP, and the Ticlopidine Aspirin Stroke Study Group. A randomized trial comparing ticlopidine hydrochloride with aspirin for the prevention of stroke in high-risk patients. *N Engl J Med* 1989;321:501-7.
- CAPRIE Steering Committee. A randomised, blinded trial of clopidogrel *versus* aspirin in patients at risk of ischaemic events (CAPRIE). *Lancet* 1996;348:1329-39.
- EASTCOTT HHG, PICKERING GW, ROB CG. Reconstruction of internal carotid artery in a patient with intermittent attacks of hemiplegia. *Lancet* 1954;2:994-6.
- POKRAS R, DYKEN ML. Dramatic changes in the performance of endarterectomy for diseases of the extracranial arteries of the head. *Stroke* 1988;19:1289-90.
- BARNETT HJM, PLUS F, WALTON JN. Carotid endarterectomy: an expression of concern. *Stroke* 1984;15:941-3.
- North American Symptomatic Carotid Endarterectomy Trial collaborators. Beneficial effect of carotid endarterectomy in symptomatic patients with high-grade carotid stenosis. *N Engl J Med* 1991;325:445-53.
- European Carotid Surgery Trialists' Collaborative Group. MRC European Carotid Surgery Trial: Interim results for symptomatic patients with severe (70-99%) or with mild (0-29%) carotid stenosis. *Lancet* 1991;337:1235-43.
- ALBERS GW, HART RG, LUTSEP HL, NEWELL DW, SACCO RL. Supplement to the guidelines for the management of transient ischemic attacks: from the Ad Hoc Committee on Guidelines for the Management of Transient Ischemic Attacks of the Stroke Council of American Heart Association. AHA medical/scientific statement. *Stroke* 1999;30:2502-11.
- MOORE WS, BARNETT HJ, BEEBE HG, BERNSTEIN EF, BRENER BJ, BROTT T, *et al.* Guidelines for carotid endarterectomy: a multidisciplinary consensus statement from the Ad Hoc Committee, American Heart Association. *Stroke* 1995;26:188-201.
- RAITHEL D. Recurrent carotid disease: optimum technique for redo surgery. *J Endovasc Surg* 1996;3:69-75.
- BERGERON P, CHAMBRAN P, BENICHOU H, ALESSANDRI C. Recurrent carotid disease: will stents be an alternative to surgery? *J Endovasc Surg* 1996;3:76-9.
- BROWN MM. Balloon angioplasty for extracranial carotid disease. *Adv Vasc Surg* 1996;4:53-69.
- MATHIAS K. Ein neues Kathetersystem zur perkutanen transluminal Angioplastie von Karotidstenosen. *Fortschr Med* 1977;95:1007-11.
- KERBER CW, HORNWELL LD, LOEHDEN OL. Catheter dilatation of proximal carotid stenosis during distal bifurcation endarterectomy. *AJNR Am J Neuroradiol* 1980;1:348-9.
- WHOLEY MH, ELES G, JARMOLOWSKI CR, LIM MC, VOZZI C, LONDERO H, *et al.* Percutaneous transluminal angioplasty and stents in the treatment of extracranial circulation. *J Invasive Cardiol* 1996;9:225-31.
- HENRY M, AMORM, MASSON I, HENRY I, TZVETANOV K, CHATI Z, *et al.* Endovascular treatment of atherosclerotic internal carotid artery stenosis. *J Endovasc Surg* 1997;4(Suppl 1):1-14.
- NAYLOR AR, BOLIA A, ABBOTT RJ, PYE IF, SMILTH J, LENNARD N, *et al.* Randomized study of carotid angioplasty and stenting *versus* carotid endarterectomy: a stopped trial. *J Vasc Surg* 1998;28:326-34.
- DeMONTE F, PEERLESS SJ, RANKIN RN. Carotid transluminal angioplasty with evidence of distal embolisation. *J Neurosurg* 1989;70:138-41.
- THERON J, COURTHEOUX P, ALACHKAR F, BOUVARD G, MAIZA D. New triple coaxial catheter system for carotid angioplasty with cerebral protection. *AJNR Am J Neuroradiol* 1990;11:869-74.
- OHKI T, MARIN M, LYON R, BERDEJO GL, SOUNDARARAJAN K, OHKI M, *et al.* *Ex vivo* human carotid artery bifurcation stenting: correlation of lesion characteristics with embolic potential. *J Vasc Surg* 1998;27:463-71.
- ROUBIN GS, HOBSON RW 2nd, WHITE R, DIETHRICH EB, FOGARTY TJ, WHOLEY M, ZARINS CK. CREST and CARESS to evaluate carotid stenting: time to get to work! *J Endovasc Ther* 2001;8:107-9.
- VEITH FJ, AMOR M, OHKI T, BEEBE HG, BELL PRF, BOLIA A, BERGERON P, CONNORS JJ, DIETHRICH EB, FERGUSON RDG, HENRY M, HOBSON RW, HOPKINS LN, KATZEN BT, MATTHIAS K, ROUBIN GS, THERON J, WHOLEY MH, YADAV SS. Current status of carotid bifurcation angioplasty and stenting based on a consensus of opinion leaders. *J Vasc Surg* 2001;31:S111-6.
- Jiri J, Vitek A, Gary SR, Al-Mubareka N, Gishel N, Sriram SI. Carotid artery stenting: technical considerations *AJNR Am J Neuroradiol* 2000;21:1736-43.
- WHOLEY MH. Will protection devices set free carotid angioplasty? Carotid Angioplasty Conference 2001 CV Channel Internet.

30. BRAY DE JM, BAUD JM, DELANOY P, CAMUZAT JP, DEHANS V, DESCAMP-LE CHEVOIR J, LAUNAY JR, LUIZY F, SENTOU Y, CALES P. Cerebrovasc Dis 1998;8:273-7. erosclerotic carotid plaque *in vivo* with high-resolution magnetic resonance imaging. Circulation 2000;102:959-64.
31. HATSUKAMI TS, ROSS R, POLISSAR NL, CHUN YUAN C. Visualization of fibrous cap thickness and rupture in human ath-

Sažetak

KAROTIDNA ANGIOPLASTIKA S CEREBRALNOM ZAŠTITOM

Z. Milošević, B. Žvan, M. Zaletel i M. Šurlan

Karotidna endarterektomija (CEA) u širokoj je uporabi pri liječenju karotidne stenozе visokog stupnja. Kirurški zahvat obavlja se u općoj anesteziji, a primjenjuje se samo pri oštećenjima na račvištu karotide ili u njegovoj neposrednoj blizini. Komplikacije koje se mogu pojaviti obuhvaćaju moždani udar, smrt, paralizu kranijjskih živaca, hematom na mjestu rane i srčane komplikacije. Rizik komplikacija povećan je u bolesnika s recidivirajućom stenozom karotidne arterije nakon CEA, u bolesnika u kojih je primijenjena radioterapija u području vrata te u bolesnika s kardiopulmonalnom bolesti. Nedostatci CEA potaknuli su liječnike da potraže alternativne načine liječenja. Karotidna angioplastika uz postavljanje stenta (CAS) manje je invazivna metoda od CEA. Ona je poglavito prikladna za liječenje recidivirajućih stenozа nakon prethodne CEA te za liječenje stenozе distalnog dijela unutarnje karotidne arterije koja je nedostupna za CEA. CAS ne uzrokuje paralizu kranijjskih živaca. Usto, nije nužna opća anestezija, a u bolesnika s teškom kardiopulmonalnom bolesti pobol i smrtnost su manji. U komplikacije CAS pripadaju moždani udar zbog distalne embolizacije plaka ili odvajanja tromba tijekom postupka, nagla okluzija krvne žile zbog tromboze, disekcija ili vazospazam te ponovna stenozа zbog hiperplazije intime. CAS je razmjerno nov postupak, pa je nužno utvrditi njegovu djelotvornost i sigurnost prije nego što se uvede u široku kliničku uporabu. U Sloveniji smo započeli s istraživanjem karotidne angioplastike u okviru projekta "Slovenian Carotid Angioplasty Study (SCAS)". Prema našim prvim iskustvima u 17 bolesnika, CAS bi se mogao pokazati važnim u prevenciji moždanog udara, uz dobar odabir bolesnika s moždanom ishemijom i uz bolju cerebralnu zaštitu tijekom postupka.