

THORACAL HERNIATION OF THE SPINAL CORD

J. Kenéz¹, P. Barsi¹, R. Veres², Gy. Varallyay³ and M. Bobest⁴

¹Neuroradiology of the Semmelweis Medical School and National Institute of Psychiatry and Neurology; ²National Institute of Neurosurgery; ³National Institute of Oncology, Budapest; ⁴Markusovszky County Hospital, Department of Neurosurgery, Szombathely, Hungary

SUMMARY – Herniation of the spinal cord through a dural defect is a rather rare deformity and very easily misdiagnosed as retromedullary occult intraspinal arachnoid cyst or meningocele. The possible origin of the dural defect can be traumatic, iatrogenic or unknown, so in these cases, congenital with great probability. On the thoracal part of the spinal column it shows a rather characteristic and misleading appearance. The anomaly leads to progressive Brown-Sequard syndrome, and the case history can be extremely long. Surgical repair of the dural defect results in improvement, or even complete recovery, if performed in time. These are the facts that emphasize the importance of early diagnosis.

Introduction

Herniation of the spinal cord through a dural defect is a rather rare entity and it is an interesting one, because it has a misleading appearance. Its rareness facilitates its misdiagnosis^{1,2}. From the etiologic point of view, it can be posttraumatic, iatrogenic, or spontaneous²⁻⁵, the latter being the rarest. The first paper on the topic was published by Cobb and Ehni in 1973, dealing with a case, where spinal cord herniated into an iatrogenic meningocele². Irrespective of its origin, the deformity leads to progressing myelopathy. Up to date, 32 cases have been published in the literature, three fourths of them posttraumatic, and one fourth iatrogenic and spontaneous, 50% each^{4,5}.

Spinal cord herniation on the thoracal part has particular importance, because of its very characteristic and misleading appearance. In case of iatrogenic origin, the case history and level of deformity are well known, so these cases will not be dealt with in this paper.

Case Reports

In the last 14 years, from 1987 till 2000, we detected three cases of transdural spinal cord herniation, two male and one female patient.

Case No. 1

A 59-year-old male patient had no history data suggesting the possibility of a dural defect. He had a ten-year history of slowly progressing weakness of his legs. At the time of the study, severe paraparesis and sensory disturbance were observed from thoracal vertebra IV downward. On MR examination, at the level of the fourth thoracal vertebra, the spinal cord became extremely thin, with a remarkably widened retromedullary CSF space (Fig. 1a). On axial T1 weighted image, the extremely thin spinal cord was found before the ventral CSF space, in the epidural compartment (Fig. 1b). At the first sight, an occult retromedullary intraspinal arachnoid cyst was suspected (as usually in most of misdiagnosed cases), however, it was excluded with the help of myelography (not shown). Definite diagnosis from the radiologic point of view was spinal cord herniation. We have no information on subse-

Correspondence to: *Professor Jozsef Kenéz*, Department of Neuro-radiology, Budapest, Hungary; phone: +3611763332

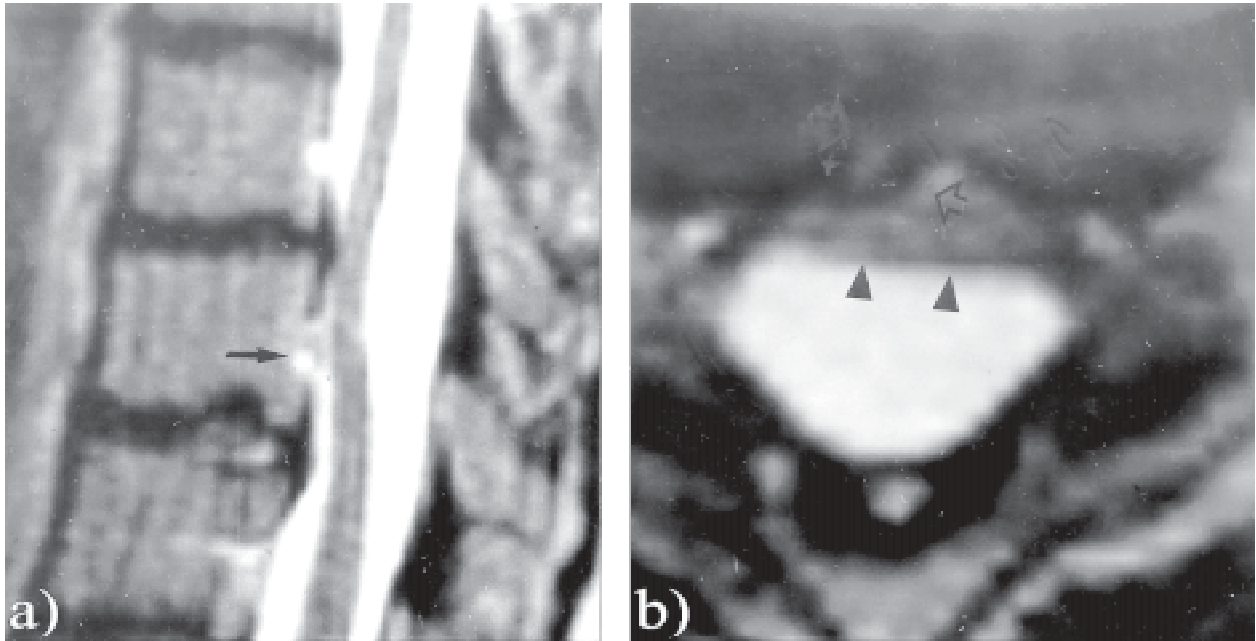


Fig. 1 a,b. T1 weighted sagittal (a) and T1 weighted axial (b) slices show herniated cord (arrows).

quent case history, but to our knowledge no neurosurgical intervention was performed.

Case No. 2

A 30-year-old male patient sustained a car accident 9 years before the MR examination. As a consequence of the accident, a compression fracture of the thoracal vertebral

body VII occurred, which was treated conservatively immediately after the accident. The patient was symptom-free for 4 years, but later he noticed weakening of his left leg. This complaint gradually worsened over the last 5 years. On MR study, on sagittal T1 and T2 weighted slices, the spinal cord was stretched to the ventral surface of the spinal canal, adhered to it, and a small part of the

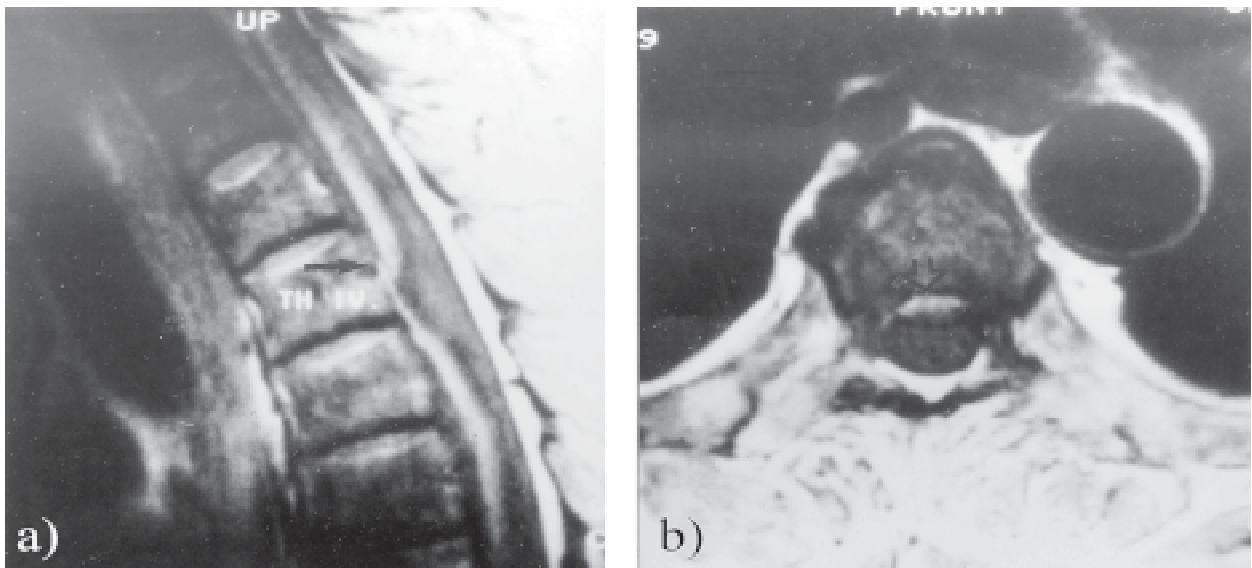


Fig. 2 a,b,c,d. On T1 and T2 weighted sagittal slices (a,b), arrows point to the atrophic, thin cord, along with the posttraumatic spinal deformity. The image of cord herniation is strengthened on axial T1 and T2 weighted slices (c,d). The artifacts caused by CSF circulation interfere with the evaluation of dorsal CSF space.

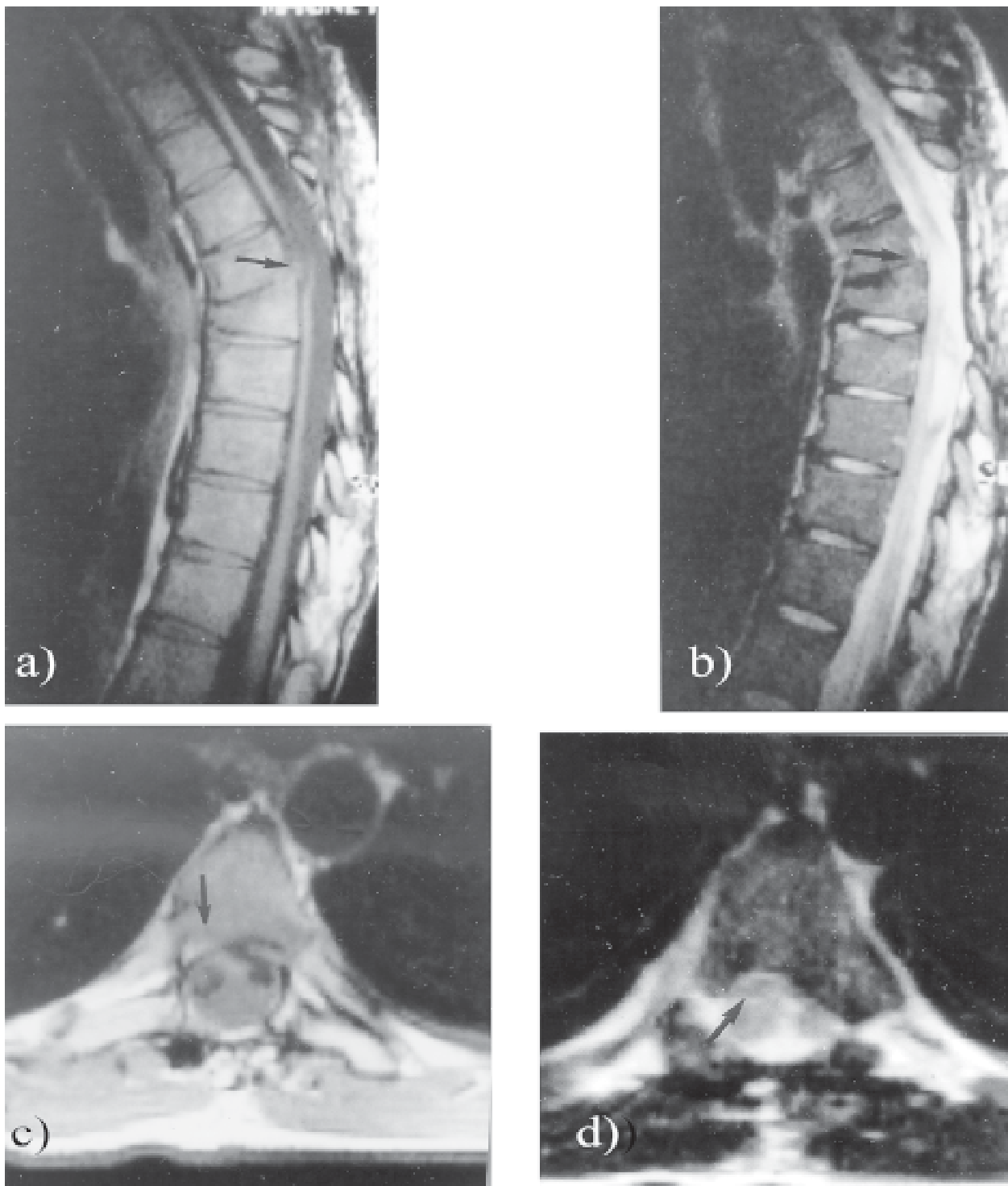


Fig. 3 a,b. On T2 weighted sagittal slice (a), arrow designates the epidurally located detail of the cord, while on axial T2, arrowheads point to the posterior border of the intraspinal part of the cord; empty arrows show the right sided parasagittal, herniated detail of the cord in the epidural space (b). On the sagittal slice, a Schmorl hernia is seen on the caudal endplate, which could be of a traumatic origin.

cord herniated into the epidural space (Fig. 2 a,b). Grossly, the cord was atrophic, thinned, the ventral CSF space was obliterated, while the dorsal one was extremely wide. The herniation was better depicted on axial T1 and T2 weighted slices (Fig. 2 c,d).

Case No. 3

A 40-year-old female patient had fallen from the bike a year and a half before the MR examination. She had no complaints just after the event. After a couple of months she noticed weakening of her right leg and pain on both sides. These complaints were the reason for MR examination. On T2 weighted sagittal (Fig. 3a) and axial (Fig. 3b) slices, a characteristic ventral CSF space obliteration, dorsal widening simulating occult arachnoid cyst, and right-sided parasagittal small herniation of the miniature part of the cord were visualized. The relatively short history could be the cause of the rather moderate atrophy of the spinal cord. Two months after the MR examination, the patient presented for control checkup, her condition being unchanged.

Discussion

According to most of the authors, the basic origin of the deformity is the injury of the dura, leading to dural defect, or it can be congenital dehiscence, these cases being in the literature referred to as of unknown origin. In most of the cases, trauma plays the leading role in the history. The "nuclear trail sign" described by Watters *et al.* in 1998⁴, suggests the possibility of disc herniation as a causative factor, even in idiopathic cases. They believe that a disc fragment causes dural injury in connection with herniation.

The pulsatile CSF pressure uses the spinal cord to "plug in" the dural defect, and because of the pressure effect, a small part of the cord moves into the epidural space having lower pressure. According to Masuzawa *et al.*⁶, before the cord herniation, sometimes an epidural CSF collection is formed at the site of the dural defect and the cord moves later into this cyst. None of our cases showed this pattern. The widening of the dorsal CSF compartment is secondary, probably it plays no major role in the pathomechanism. Thus the theory of Uchino *et al.*⁹, stating that the intradural occult arachnoid cyst pushes and compresses the cord forward, can only be accepted in cases when the theoretical cyst is really present behind the cord. For this reason, the walls of the cyst have to be de-

picated, and for this CT assisted myelography can be recommended^{4,9}.

The physiologic curvature of the spinal column plays an important role in the development of the disease. Spinal cord is in tight mutual relationship with the ventral wall of the spinal canal, because of dorsal kyphosis helping the contact between the dural defect and the cord. The mechanism has been evaluated in detail by Kumar *et al.*¹¹, stating that as the spinal cord and the dura are mobile in a certain degree, so the effects of heartbeats, flexion-extension and breathing produce anteroposterior and upward-downward movements. Adhesions can develop in cases when long lasting contact exists between the cord and the dura. These adhesions favor the development of arachnoid invaginations, which give rise to epidural arachnoid cyst that can be found in one third of operated cases¹². The ventrally located anterior spinal artery can be trapped by the herniated part of the cord, so circulatory disturbances can occur as well.

It should be emphasized again that the physiologic curvatures of the spinal column play an important role and reflect the fact that on the cervical and upper lumbar part, posterior herniation develops, mainly postoperatively and might be regarded as iatrogenic. Its occurrence is by far less characteristic and misleading than that of the thoracic one.

In therapy, neurosurgical intervention has a paramount role. Closure of the dural defect has a beneficial effect, as unanimously reported in the literature, even in case when the cord is remarkably atrophic. Postoperative improvement can also be expected in cases where intramedullary signal disturbances are present^{4,5}.

Detailed MR examination is essential for the accurate diagnosis of the disease. Morphological details have to be depicted with great accuracy. The characteristic but potentially misleading appearance of the deformity suggesting the presence of occult retromedullary intradural CSF collection, the progressive nature of the neurologic deficit, and the beneficial effect of neurosurgical intervention with repair of the dural defect, make the knowledge and recognition of the disease highly important. That is why we report on our experiences in the field.

References

1. HAUSMANN ON, MOSELEY IE. Idiopathic dural herniation of the spinal cord. *Neuroradiology* 1996;38:503-10.
2. COBB C, EHNI G. Herniation of the spinal cord into an iatrogenic meningocele. *J Neurosurg* 1973;39:533-6.

3. WORTZMAN G, TASKER RR, REWCASTLE B, RICHARDSON JC, PEARSON FG. Spontaneous incarcerated hernia of the spinal cord into a vertebral body: an unique case of paraplegia. *J Neurosurg* 1974;41:631-5.
4. WATTERS MR, STEARS JC, OSBORN AG, *et al.* Transdural spinal cord herniation: imaging and clinical spectra. *AJNR Am J Neuroradiol* 1998;19:1337-44.
5. DIX JE, GRIFFITT W, YATES C, JOHNSON B. Spontaneous thoracic spinal cord herniation through an anterior dural defect. *AJNR Am J Neuroradiol* 1998;19:1345-8.
6. MASUZAWA H, NAKAYAMA H, SHITARA N, SUZUKI T. Spinal cord herniation into a congenital extradural cyst causing Brown-Sequard syndrome. *J Neurosurg*;1981;55:983-6.
7. BORGES LF, ZERVAS NT, LEHRICH JR. Idiopathic spinal cord herniation: a treatable cause of Brown-Sequard syndrome. *Neurosurgery* 1995;36:1028-32.
8. ISU T, IIZUKA T, IWASAKI Y, *et al.* Spinal cord herniation associated with an intradural spinal arachnoid cyst diagnosed by magnetic resonance imaging. *Neurosurgery* 1991;29:137-9.
9. UCHINO A, KATO A, MOMOZAKI N, YUKITAKE M, KUDO S. Spinal cord herniation: report of two cases and review of the literature. *Eur Radiol* 1997;7:289-92.
10. SCAZZERI F, BAYON S, SALVADORI R, *et al.* Progressive Brown-Sequard syndrome: spontaneous development of a spinal cord herniation. *Riv Neuroradiol* 2001;14:339-41.
11. KUMAR R, TAHA J, GREINER AL. Herniation of the spinal cord. *J Neurosurg* 1995;82:131-6.
12. URBACH H, KADEN B, *et al.* Herniation of the spinal cord 38 years after childhood trauma. *Neuroradiology* 1996;67 (Suppl 2):64.
13. WADA E, YONENOBU K, *et al.* Idiopathic spinal cord herniation. Report of three cases and review of the literature.

Sažetak

TORAKALNA HERNIJACIJA KRALJEŠNIČNE MOŽDINE

J. Kenéz, P Barsi, R. Veres, Gy. Varallyay i M. Bobest

Hernijacija kralješnične moždine kroz duralne defekte prilično je rijetka deformacija koja se vrlo lako pogrešno dijagnosticira kao retromedularna okultna intraspinalna arahnoidna cista ili kao meningokela. Uzrok duralnog defekta može biti traumatski, jatrogeni ili nepoznat, a u ovim je slučajevima vrlo vjerojatno prirodan. Torakalni dio kralješnice pokazuje prilično karakterističan izgled, no koji može zavarati. Poremećaj uzrokuje pojavu progresivnog Brown-Séquardova sindroma, a anamneza može biti izrazito dugotrajna. Ako se provede na vrijeme, kirurško zatvaranje duralnog defekta dovodi do poboljšanja, pa čak i do potpunog oporavka, što upućuje na važnost rane dijagnoze.