

## SARCOIDOSIS – WHOLE BODY GALLIUM IMAGING

Ksenija Kovačić

Department of Oncology and Nuclear Medicine, Sestre milosrdnice University Hospital, Zagreb, Croatia

**SUMMARY** – The sensitivity of gallium scintigraphy in intra- and extrapulmonary sarcoidosis is about 97%. The method is by far more sensitive than other noninvasive methods/tests. Typical scintigraphic patterns are lambda and panda signs. In addition to its diagnostic value for revealing all areas involved and estimating their activity, gallium 67 scintigraphy is an excellent indicator of therapy efficacy.

**Key words:** *Sarcoidosis, radionuclide imaging; Gallium citrate, diagnostic use*

Sarcoidosis is a disease of unknown etiology, which may involve any organ or tissue, however, the lungs and mediastinal lymph nodes are most commonly affected. One of the methods used in the diagnosis of sarcoidosis is whole body gallium scintigraphy. The method is highly sensitive in revealing the activity and in assessing therapy efficacy. Although the lungs are most commonly involved, extrapulmonary localization of sarcoidosis is by no means rare, and it is exactly where whole body scintigraphy is of great value (Figs. 1, 1A, and 2).

Gallium (<sup>67</sup>Ga citrate), a cyclotron-produced radiopharmaceutical, has been in use since 1969. Its physical half-life is 78 hours. A biological system treats it as a ferric ion, however, unlike iron, gallium has less affinity for a majority of transporters and it cannot be reduced *in vivo*. During the first 5 days, 40% of the injected dose are excreted. The physiological distribution follows the distribution of transferrin and lactoferrin<sup>1-3</sup>.

Patients are intravenously injected with 74-185 MBq of <sup>67</sup>Ga citrate, and whole body imaging in AP and PA projection, and single images are performed 48-72 hours later with a gamma camera connected with a computer and equipped with a medium energy collimator. The connection with computer enables quantification of data,

which is very convenient for follow-up. It should be noted that each patient serves as his/her own control.

The sensitivity of gallium for extra- or intrapulmonary active sarcoidosis is about 97%. The method is by far more sensitive than other noninvasive methods/tests, including ACE. A combination of tests increases diagnostic specificity. In a group of patients with documented sarcoidosis, elevated serum ACE levels and positive gallium scintigraphy increased specificity to 99%. In addition to its diagnostic value in sarcoidosis by imaging the involved areas and assessing their activity, gallium scintigraphy also is an excellent indicator of therapeutic efficacy. It turns negative to steroid therapy and becomes positive again after its withdrawal (Fig. 5, 5A).

Activated lymphocytes and transferrin receptors have been proposed as being responsible for gallium uptake in sarcoidosis<sup>4-6</sup>.

Typical scintigraphic patterns are lambda sign, observed exclusively in sarcoidosis, and panda sign also associated with some other disorders, such as Sjögren's syndrome. The lambda pattern indicates involvement of the right paratracheal or azygos lymph node group (mediastinal), right and left para- and infra hilar lymph node group (intrapulmonary), and subcarinal lymph node group (mediastinal) (Figs. 1, 3, 4)<sup>7</sup>. The panda pattern indicates gallium uptake by lacrimal and salivary glands (Figs. 1, 2). Lymph nodes in other parts of the body may also be involved (Fig. 2). Gallium uptake was also recorded in soft tissue (skin) infiltrates (Fig. 1A). In such cases, gallium

Correspondence to: Ksenija Kovačić, M.D., Department of Oncology and Nuclear Medicine, Sestre milosrdnice University Hospital, Vinsogradska c. 29, HR-10000 Zagreb, Croatia

Received November 10, 2000, accepted January 5, 2001

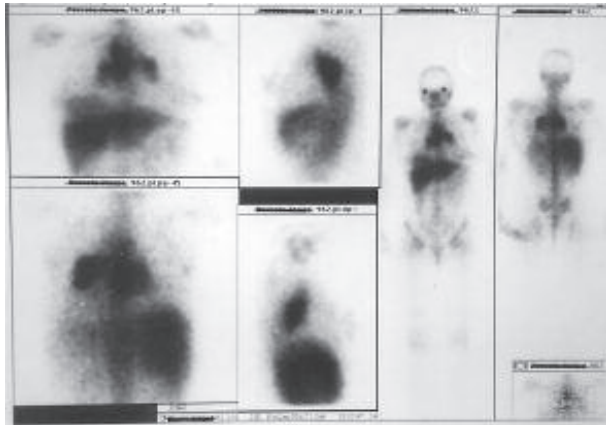


Fig. 1. Lambda and panda pattern in a 38-year-old female patient with sarcoidosis.

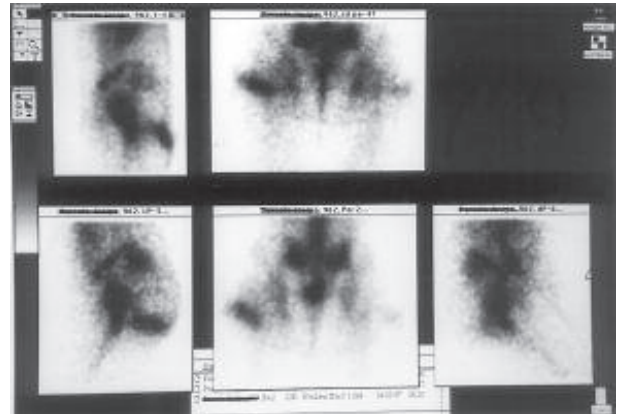


Fig. 1A. Increased gallium uptake by soft tissue infiltrates in the gluteal region of the same patient.

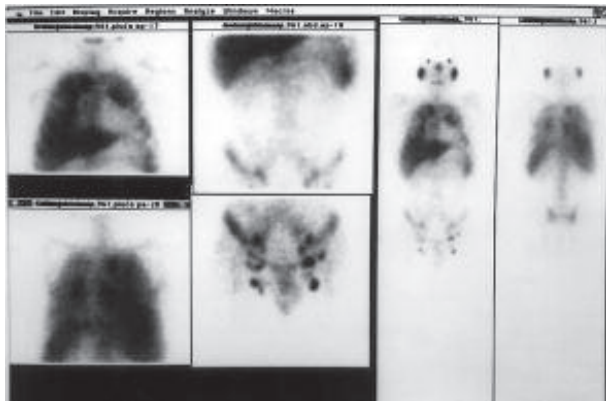


Fig. 2. Panda pattern, intrapulmonary uptake, and gallium uptake in iliac and inguinal lymph nodes in a 39-year-old patient with sarcoidosis.

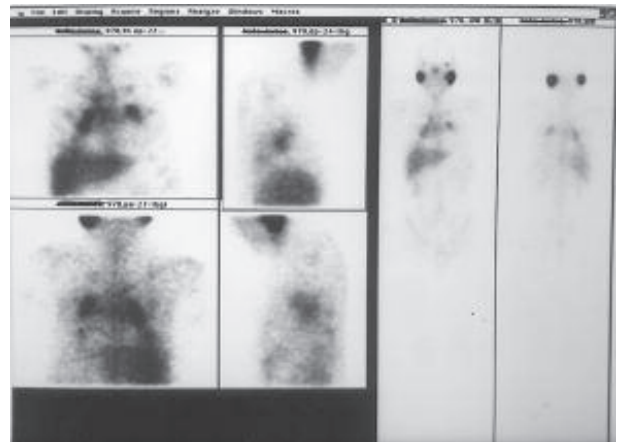


Fig. 3. Panda and lambda pattern in a 30-year-old patient, showing a predominance of panda pattern.

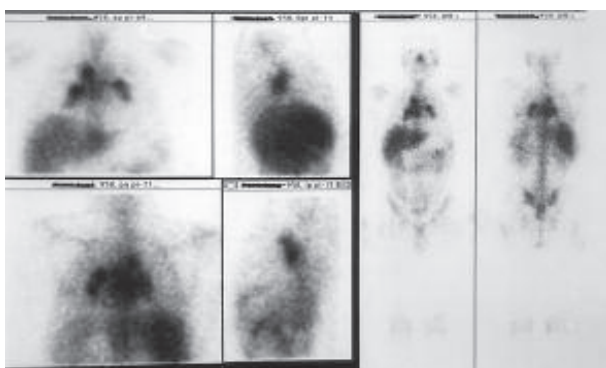


Fig. 4. Lambda pattern in a 42-year-old patient.

distribution can resemble some other diseases such as lymphoma or metastatic disease<sup>7,8</sup>.

Because of its high sensitivity, specificity and noninvasiveness, we believe that gallium scintigraphy should be

an unavoidable procedure in the diagnosis and follow-up in patients with sarcoidosis. If necessary, the method can be supplemented with target x-ray or computed tomography.

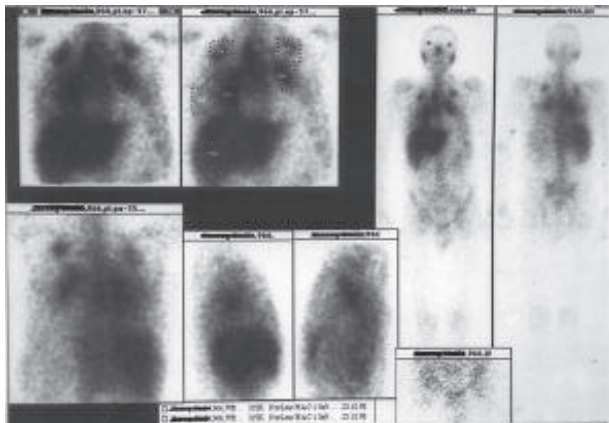


Fig. 5. Panda pattern and intrapulmonary gallium uptake in a 34-year-old patient before...

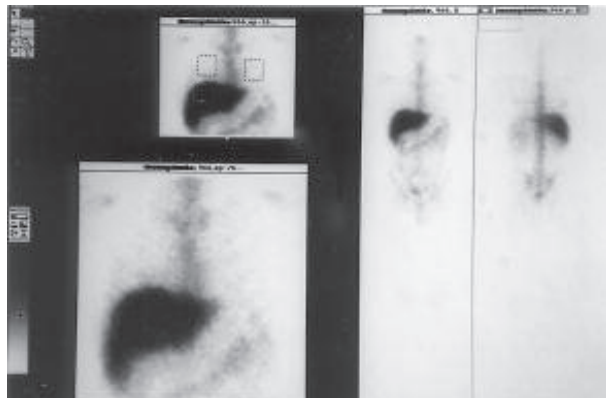


Fig. 5A. ...and after 6-month steroid therapy.

## References

1. PALESTRO CJ. The current role of gallium imaging in infection. *Semin Nucl Med* 1994;2:128-41.
2. KRAMER EL, DIVGI CR. Pulmonary applications of nuclear medicine. *Clin Chest Med.* 1991;1:55-75.
3. KIM SM, PARK CH, INTENZO CM, PATEL R. Gallium uptake in tryptophan-related pulmonary disease. *J Nucl Med* 1991;32:328-9.
4. CINTI DC, HAWKINS HB, SLAVIN JD. Radioisotope bone scanning in a case of sarcoidosis. *Clin Nucl Med* 1985;3:192-4.
5. MILLER RF, O'DOHERTY MJ. Pulmonary nuclear medicine. *Eur J Nucl Med* 1992;19:355-68.
6. SPECHT HD, BAKKE AC, BRAZIEL R, MILEY A, RASHIDI-NEZAMI S, GERMAIN L. Cellular basis for the elevated gallium-67 computed lung index in a rheumatoid lung patient. *J Nucl Med* 1991;32:2288-90.
7. SULAVIK SB, SPENCER RP, WEED DA, SHAPIRO RH, SHIUE S-T, CASTRIOTTA RJ. Recognition of distinctive patterns of gallium-67 distribution in sarcoidosis. *J Nucl Med* 1990;31:1909-14.
8. Anonymous. Pulmonary nuclear medicine – self-study test – sarcoidosis. *J Nucl Med* 1991;32:318.

## Sažetak

### SARKOIDOZA – SCINTIGRAFIJA CIJELOG TIJELA GALIJEM-67

K. Kovačić

Osjetljivost scintigrafije galijem za aktivnu sarkoidozu u plućima ili izvan njih je oko 97%. Metoda je znatno osjetljivija od drugih neinvazivnih metoda/pretraga. Tipičan scintigrafski nalaz je znak lambda i panda. Uz vrijednost u postavljanju dijagnoze, gdje otkriva zahvaćena mjesta i procjenjuje njihovu aktivnost, scintigrafija galijem je vrijedan pokazatelj odgovora na terapiju.

Ključne riječi: *Sarkoidoza, prikazivanje pomoću radionuklida; Galij citrat, dijagnostička primjena*