

IMMUNOMEDIATED PERIMYOCARDITIS AFTER STAPHYLOCOCCAL THROMBOPHLEBITIS

Tomislav Šušković and Dina Vukičević-Baudoin

Department of Medicine, Seste milosrdnice University Hospital, Zagreb, Croatia

SUMMARY – During the treatment of puerperal sepsis, a 26-year-old patient developed infectious thrombophlebitis of the left axillary vein and subclavian vein caused by *Staphylococcus aureus*. Eighteen days from completion of antibiotic therapy, the patient presented with perimyocarditis, left ventricular incompetence, and high levels of circulating immunocomplexes. The course of the disease suggested immunomediated perimyocarditis as a reaction to bacterial infection. After nine-month follow-up, spontaneous normalization of the ejection fraction occurred.

Key words: *Myocarditis, immunology; Myocarditis, diagnosis; Case report; Thrombophlebitis, complications*

Introduction

Multiple infective agents have been associated with myocarditis. The most common cause of myocarditis is Coxsackie B virus infection, whereas bacteria are less frequently identified. In predisposed individuals, the infective agent induces adverse immune response that persists despite the infective agent eradication¹⁻³.

Presentation is made of a female patient with thrombophlebitis induced by *Staphylococcus aureus*, complicated by immunomediated perimyocarditis.

Case Report

A 26-year-old pregnant woman underwent cesarean section for breech presentation of the fetus. The patient had previously only suffered from hay fever. Forty-eight hours after the parturition, she developed puerperal sepsis (*Streptococcus viridans*). The disease was complicated by disseminated intravascular coagulation with severe met-

orrhagia that required hysterectomy. Upon the completion of penicillin therapy, the patient was discharged from the hospital. Two days later, she presented to the department for infectious thrombophlebitis of the left axillary vein and subclavian vein, where a venous catheter was inserted. Physical examination performed on admission showed febrility (38°C), sinus tachycardia (110/min), and pericardial friction rub. Blood pressure was 110/70 mm Hg, while ECG showed a T wave inversion in precordial leads. The diagnosis was verified by phleboscintigraphy and chest computed tomography (CT). Ultrasonic cardiography revealed a left ventricle ejection fraction (EF) of 59% (normal >60%) and minor pericardial effusion without any inflow impairments. Laboratory findings: erythrocyte sedimentation rate (ESR) 103 mm/h; leukocytes $10.1 \times 10^9/L$; antistreptolysin O (ASO) titer 80 IU/l; and antistaphylococcal antibodies (ASA) 2.0 IU/l (normal <2). *Staphylococcus aureus* was isolated from the blood culture. Heparin and vancomycin therapy resulted in clinical and laboratory improvement, and the treatment was continued with warfarin on an outpatient basis. The patient presented again after 18 days for pericardial tamponade, with a prothrombin time (PT) of 27%. An amount of 2000 ml of serohemorrhagic sterile fluid was evacuated by pericardiocentesis. Subsequent ultrasonic cardiography showed a residual pericardial effusion, diffuse hypokine-

Correspondence to: Tomislav Šušković, M. D. Ph. D. Department of Medicine, Seste milosrdnice University Hospital, Vinogradska c. 29, HR-10000 Zagreb, Croatia

Received November 20, 2000, accepted in revised form March 13, 2001

sia of the left ventricle with EF decline to 33%, and bilateral pleural effusion. During the subsequent course of disease, the patient was afebrile, with persistent sinus tachycardia of 120-130/min and protodiastolic gallop. ESR was 30 mm/h, and leukocytes were normal. The repeated ASA test was negative, and so were antinuclear antibodies, anti-DNA, antibodies to cardiac muscle and lupus anticoagulant, and antibodies to Coxsackie B virus. High levels of circulating immunocomplexes (CIC) of 480 mg/l (normal <180 mg/l) were recorded immediately after pericardial tamponade (Fig. 1), which gradually normalized over the next three months. The patient was submitted to expectative follow-up, with discontinuation of warfarin therapy. No elements of infection were observed during the further course. The reduced exercise tolerance gradually improved with EF increase, and the myocardial function reached normal level with EF of 60% nine months after the cesarean section.

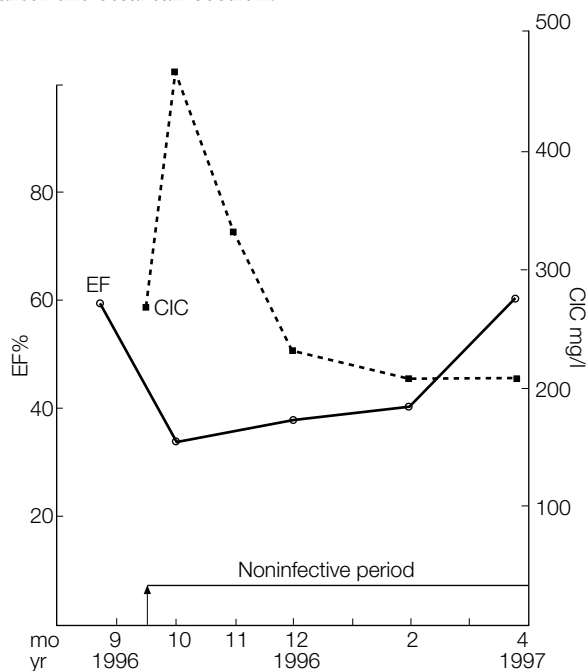


Fig. 1. Relation of ejection fraction (EF) and circulating immunocomplexes (CIC) during the postinfection period of immunomediated perimyocarditis.

Discussion

The course of disease in this patient proceeded in two phases. The first phase included infectious MRSA thrombophlebitis with possible dissemination to the pericardium, followed by the second, noninfectious phase, start-

ing on day 18 upon the completion of antibiotic therapy, with overt signs of perimyocarditis, high CIC values, and EF decline. The finding of ultrasonic cardiography indicated that at the moment, the myocardial lesion predominantly involved the left ventricle, which led to the left ventricular incompetence with bilateral transitory pleural effusion. The second, prolonged phase, characterized by the absence of any signs of bacterial infection, and by clinical and laboratory improvement, suggested an immune response to the initial bacterial infective agent. Pericardial tamponade coincided with therapeutically optimal PT in the presence of persisting pericarditis (*locus minoris resistentiae*).

Consistent with our observations, Miller and Witham⁴ have described four patients with pleuropericarditis after the treatment for *Staphylococcus aureus* sepsis. They emphasize a prolonged febrile period after successful treatment. The second phase of polyserositis was an immunomediated reaction. The report by Hingirani et al.⁵ is quite interesting as well. They present a patient with thrombophlebitis of axillary and subclavian veins accompanied by immunomediated myocarditis. As no infective agent was identified, they postulated it to be Coxsackie B virus!

Waldvogel⁶ has confirmed that sustained intravascular infections are associated with the development of rheumatoid factor, cryoglobulins and circulating immune complexes. It has been suggested that CIC can be detected in 50% of patients with *Staphylococcus aureus* endocarditis. According to Rotresen⁷, inflammation may be sustained upon eradication of staphylococcal infection by the action of bacterial fragments and their products (endotoxins, exotoxins and peptidoglycans), which may lead to the formation and accumulation of CIC deposits in predisposed individuals. This stimulates and maintains the second, postinfection stage of inflammation. Rotresen has established the process from staphylococcal arthritis, but the same biological pathway is also present in other organs and with other agents. Similarly, Diaz and Collazos⁸ have described a case of autoimmunomediated perimyocarditis triggered by cardiac infection with *Chlamydia psittaci*, and concluded that it was immune response to chlamydial heat shock protein. After eradication of the agent, the patient was asymptomatic, however, four months later he suffered heart failure that was compensated with conventional therapy. This case is similar to our patient, who developed heart failure after eradication of the infective agent and apparent recovery from the infection.

Accordingly, we believe that our patient developed immunomediated perimyocarditis secondary to the successfully treated staphylococcal infection. Perimyocarditis could not be verified by myocardial biopsy, because the exhausted patient refused the procedure. We are inclined to join the authors who do not consider the biopsy procedure indispensable for the diagnosis, since reliable findings are known to be obtained in not more than 19% of biopsy specimens^{1,9}. An absolute indication for myocardial biopsy is monitoring of a transplanted heart¹.

During the second phase of the disease, the patient was expectatively followed up, as previous experience with this type of myocarditis did not show any major benefit from immunosuppressive therapy¹⁰. According to the ultrasonic cardiography findings, the course of disease suggested EF normalization in spite of persisting intolerance of major physical strain.

The case presented calls for further studies of the pathogenesis of the myocardial lesion during and after a successfully treated bacterial infection, with simultaneous monitoring of immunologic parameters.

References

1. WYNNE J, BRAUNWALD E. The cardiomyopathies and myocarditis. In: BRAUNWALD E, ed. Heart disease. Philadelphia: WB Saunders, 1977:1404-64.
2. O'CONNEL JB, RENLUND DG. Myocarditis and specific myocardial disease. In: SCHAUT RC, ALEXANDER RW, eds. Hurst's the heart. New York: McGraw Hill, 1994:1591-7.
3. MALKIEL S, KNAN AP, DIAMOND B. Autoimmunity in heart disease: mechanisms and genetic susceptibility. *Mol Med Today* 1996;2:336-42.
4. MILLER GC, WITHAM AC. Delayed febrile pleuropericarditis syndrome. *Ann Intern Med* 1973;79:194-7.
5. HINGIRANI AD, DOLLERY CT, OAKLEY CM, BLOOM SR, COHEN J. Postinfectious myocarditis. *BMJ* 1992;304:1676-8.
6. WALDVOGEL FA. *Staphylococcus aureus*. In: MANDEL GL, BENNET JE, DOLIN R, eds. Principles and practice of infectious diseases. Philadelphia: Churchill Livingstone, 2000:2084-5.
7. ROTRESEN D. Infectious arthritis. In: ISSELBACHER KJ, BRAUNWALD E, WILSON JD, MARTIN JB, FAUCI AS, KASPER DL, eds. Harrison's principles of internal medicine. New York: McGraw Hill, 1994:554-8.
8. DIAZ F, COLLAZOS J. Myopericarditis due to *Chlamydia psittaci*. The role of autoimmunity. *Scand J Infect Dis* 1997;29:93-4.
9. DAVIES MJ. Need you biopsy for acute myocarditis. *Heart* 1996;75:476.
10. MASON JW, THOMAS EM. A clinical trial of immunosuppressive therapy for myocarditis. *N Engl J Med* 1995;333:269-75.

Sažetak

IMUNOPOSREDOVANI PERIMIOKARDITIS NAKON STAFILOKOKNOG TROMBOFLEBITISA

T. Šušković i D. Vukičević-Baudoin

Tijekom liječenja zbog puerperalne sepse 26-godišnja bolesnica oboljela je od infektivnog tromboflebitisa lijeve aksilarne i subklavijske vene izazvanog uzročnikom *Staphylococcus aureus*. Osamnaest dana nakon završetka antibiotske terapije pojavio se perimiokarditis, popuštanje lijevog srca i visoke vrijednosti serumskih cirkulirajućih imunokompleksa. Tijek bolesti upućivao je na imunoposredovani perimiokarditis kao reakcije na bakterijsku infekciju. Nakon 9 mjeseci praćenja nastupila je normalizacija ejakcijske frakcije.

Ključne riječi: *Miokarditis, imunologija; Miokarditis, dijagnostika; Prikaz slučaja; Tromboflebitis, komplikacije*