

ENDOSCOPIC THERAPY OF GASTROESOPHAGEAL VARICEAL HEMORRHAGE

Neven Ljubičić and Martina Špero

Division of Gastroenterology, Department of Medicine, Sestre milosrdnice University Hospital, Zagreb, Croatia

SUMMARY - Current concepts of endoscopic treatment of gastroesophageal variceal hemorrhage are discussed. There are two major endoscopic treatments of gastroesophageal varices: endoscopic injection sclerotherapy (EIS) and endoscopic variceal ligation (EVL). EIS and EVL alone are equally effective in controlling acute variceal bleeding, however, EVL is superior to EIS because it achieves variceal obliteration faster and with a lower rate of complications and rebleeding. Considering combined technique of EVL and EIS, it appears that initial EVL followed by long-term EIS on later sessions, when banded varices have become smaller, probably is a wiser approach for safe and longlasting variceal eradication. Histoacryl as a tissue glue is the only endoscopic treatment that has been proved to be effective for gastric varices. The use of endoscopic clips alone in the treatment of varices remains uncommon. The role of endoscopic ultrasound increases in the evaluation of portal hypertension, and it may gain a role in choosing an optimal treatment approach for individual patients.

Key words: *Esophageal and gastric varices, therapy; Gastrointestinal hemorrhage, therapy; Endoscopy, digestive system*

Introduction

Bleeding from gastroesophageal varices is a serious complication of portal hypertension and the leading cause of death in patients with portal hypertension, with a mortality of up to 50% for the initial bleed and 30% for subsequent bleeds^{1,2}. It is a common cause of upper gastrointestinal hemorrhage, accounting for approximately one third of diagnoses in individuals presenting with upper gastrointestinal bleeding.

Most cirrhotics eventually develop esophageal varices³⁻⁵, the incidence being approximately 50% among all cirrhotics. About one third of patients with esophageal varices experience a variceal hemorrhage^{6,7}. Identification of risk factors for esophageal variceal hemorrhage is important because of high mortality of each bleeding epi-

sode. The risk of bleeding is related to the degree of portal hypertension, variceal location (highest near the gastroesophageal junction), presence of red signs on the varices on endoscopy, and liver failure. After gastroesophageal varices have started bleeding, the hemorrhage spontaneously stops in only 50% of cases⁸. Upon cessation of active bleeding, the risk of rebleeding is high for approximately 6 weeks¹. The risk of early rebleeding is greatest within the first 48 hours, and about half of all early rebleeding episodes occur within this time period. The long-term course after an initial bleed is punctuated by repeated episodes of variceal hemorrhage with its attendant risks of exsanguination, hepatic encephalopathy, and liver failure^{1,9,10}. The risk of recurrent bleeding is related to the liver failure severity, continued alcoholism, variceal size, renal failure, and presence of hepatoma¹¹. Approximately 70% of all untreated patients experience further bleeding or die within one year of their initial bleeding¹².

The risk of bleeding from gastric varices depends on their location^{13,14}: gastroesophageal varices along the lesser curvature (GEV1) constitute more than 70% of

Correspondence to: *Neven Ljubičić, M.D., Ph.D., FACC*, Division of Gastroenterology, Department of Medicine, Sestre milosrdnice University Hospital, Vinogradska c. 29, HR-10000 Zagreb, Croatia
E-mail: neven.ljubicic@zg.hinet.hr

Received May 7, 2001, accepted June 11, 2001

gastric varices, but only 11% of GEV1 bleed. Isolated cluster of varices in the gastric fundus (IGV1) constitute 8% of all gastric varices and 80% of IGV1 bleed.

Endoscopic Injection Sclerotherapy

The treatment of variceal bleeding remained largely expectant until the second half of the twentieth century. The first report of endoscopic injection sclerotherapy (EIS) for variceal bleeding was published in 1939 by Crafoord and Frencker¹⁵. EIS remained unrecognized as a therapeutic option until the advent of flexible endoscopy in 1960s.

The goal of EIS is to inject the sclerosant that subsequently results in instantaneous coagulation necrosis and induction of variceal thrombosis and scarring; it may be performed by injection of the sclerosant directly into the varix (intravariceal) to produce thrombosis, or adjacent to the varix (paravariceal) to induce submucosal fibrosis and obliteration of deeper perforating vessels. In practice, a combination of both techniques may be utilized during the same session. Techniques of sclerotherapy vary and are operator-dependent. Several sclerosants have been employed in various combinations and volumes (Table 1). EIS schedules have also varied considerably; more frequent treatment intervals achieve more rapid variceal obliteration, with greater mucosal ulceration¹⁶⁻¹⁸.

Table 1. Most commonly used sclerosants

· Sodium - tetradecyl sulfate
· Sodium - morrhuate
· Ethanolamine
· Ethanol
· Polydocanol*

*Aethoxysclerol 1% (Kreussler Pharma, Germany), commonly used in Croatia.

Complications of EIS are common and are occasionally life threatening¹⁹. Fever, retrosternal discomfort and dysphagia frequently occur acutely and usually resolve within 48 hours. Injection-induced bleeding, postinjection esophageal ulceration with delayed bleeding, and esophageal perforation may also occur. Dysphagia may occur after EIS due to esophageal ulceration, dysmotility, or stricture formation that usually responds to dilatation. Other potential complications include mediastinitis, pleural effusion, bronchoesophageal fistula, and ARDS. Bac-

teremia is common during EIS. To avoid these complications, the present policy is to use lower volumes of sclerosant as varices decrease in size, in an attempt to reduce the extent of complications.

Endoscopic injection sclerotherapy has been widely used in the emergency treatment of patients with actively bleeding esophageal varices^{20,21}. Even though the initial bleed may be effectively controlled by sclerotherapy, the risk of subsequent bleeding is substantial. There is a general consensus that patients surviving a bleeding episode should be treated to prevent rebleeding. The aim is to achieve complete eradication of varices because it reduces rebleeding and death from esophageal varices. Considerable evidence has supported the use of repeated EIS to obliterate esophageal varices, thus to prevent further variceal bleeding.

Despite the widespread use of EIS for the treatment of bleeding esophageal varices and a plethora of published studies, accurate long-term data detailing recurrence, rebleeding rate after eradication, or the need of prolonged endoscopic surveillance are scanty^{22,23}. Despite the fact that repeated EIS eradicated esophageal varices in most patients, the most important limitation of long-term EIS is the high incidence of rebleeding from residual varices that occurred in 36% of patients²⁴.

Endoscopic injection sclerotherapy in the treatment of gastric varices

Bleeding from gastric varices continues to be a therapeutic challenge, due to their large size and extent. Sarin²⁵ demonstrated that gastric variceal EIS is effective for junctional, small size, lesser curvature varices associated with esophageal varices (GOV1), but is not suitable for large, major curvature varices (GOV2), and especially not for isolated fundal varices. EIS as well as endoscopic band ligation are unlikely to achieve complete obliteration of extensive variceal conglomerates; necrosis caused by these procedures may lead to fatal hemorrhage. Therefore, since standard gastric variceal EIS has shown disastrous results, such a treatment modality is not recommendable²⁶. Histoacryl is the only endoscopic treatment that has been shown to be effective for gastric varices^{27,28}.

Prophylactic endoscopic injection sclerotherapy

Prophylactic EIS has been extensively studied and it is not recommended due to the high procedural complication rates, which may outweigh any benefits of the treatment. Nonetheless, two randomized studies have been published in which EIS and endoscopic variceal ligation

were compared for prophylactic treatment of esophageal varices. Surprisingly, both studies showed equal or better results for EIS. Svoboda *et al.*²⁹ conducted a study in the Czech Republic and recommend EIS for primary prevention of esophageal variceal bleeding; the mean number of sessions required to achieve eradication was lower in the ligation group than in the sclerotherapy group, but the two endoscopic treatments were found to be equally effective in reducing the incidence of initial bleeding. The recurrence of esophageal varices was higher in the ligation group compared with the sclerotherapy group (31% *vs.* 11%; $p=0.01$). Total mortality was significantly lower in the sclerotherapy group compared with the control group (20% *vs.* 38%; $p=0.04$), but not in the ligation group compared with controls (23% *vs.* 38%; $p=0.10$). Gotoh *et al.*³⁰ performed a study in Japan, in which during 18-month follow-up the incidence of bleeding was significantly higher in patients treated with band ligation than in those receiving EIS (20% *vs.* 0%). The authors explained these findings by the higher rate of variceal recurrence in the band ligation group (56% *vs.* 16%).

viewing field because it is attached to the tip of the endoscope, rendering visualization difficult, especially in a setting of acute hemorrhage. During the last few years, endoscopists all around the world have been focusing their attention on ligating varices instead of injecting them.

Endoscopic band ligation

The results from several randomized, prospective trials, which have directly compared EIS and endoscopic band ligation (EBL) of esophageal varices, have shown both techniques to be equally effective in arresting acute esophageal variceal bleeding^{32,33} as well as in the prevention of recurrent bleeding³⁴⁻³⁸ (Fig. 1). EBL has been found to be superior to EIS for eradicating esophageal varices more rapidly and with fewer complications³⁴⁻³⁹ (Table 2).

EBL has a significantly lower rate of development of early complications and of bacteremia. Esophageal ulcers are a necessary accompaniment of sclerotherapy as well as of EBL, and would be seen universally following any injury to the variceal wall. The frequency of development or

Table 2. Endoscopic injection sclerotherapy (EIS) *vs.* endoscopic band ligation (EBL)

Authors, year	No. of sessions required (mean±SD)		Complication rate (%)		Obliteration of varices (%)		Recurrence of varices (%)	
	EIS	EBL	EIS	EBL	EIS	EBL	EIS	EBL
Steigmann <i>et al.</i> ³⁴ , 1992	4±2	5±2	22	2	56	55	50	33
Hou <i>et al.</i> ³⁵ , 1995	4.6±1.6	3.5±1.6	22.4	4.5	79.1	86.6	28	40
Sarin <i>et al.</i> ³⁶ , 1997	5.2±1.8	4.1±1.2	-	-	-	-	6.4	21.3
Avgerinos <i>et al.</i> ³⁷ , 1997	5.8±2.7	3.7±1.9	60	35	97.5	94.5	44	31
Baroncini <i>et al.</i> ³⁸ , 1997	4±0.1	3.5±0.1	31	11	92.5	93	13	30
Hou <i>et al.</i> ³⁹ , 1999	5.1±2.2	3.7±0.1	-	-	86	88	-	-

Endoscopic Variceal Ligation

Endoscopic variceal ligation (EVL) was initially introduced by Steigmann in 1986, with the anticipation that it would be approximately as efficacious as EIS, but associated with a lower incidence of complications³¹. EVL achieves hemostasis by physical constriction of the varix. It leads to local hemostasis and thrombosis with a variable effect on the interconnecting perforating vessels. The technique is easy to learn, and all current endoscope models can be used. It can be performed using bands and miniloops. The banding device substantially reduces the

worsening of portal hypertensive gastropathy is higher after EIS than after EBL, probably due to the rapid occlusion of varices and redistribution of blood flow in the gastric microcirculation after EIS, whereas EBL does not cause total occlusion of veins and some blood flow persists at the gastroesophageal junction, which prevents the sudden and near total redistribution of blood into the stomach.

Although EBL is a very attractive method because of faster eradication and fewer complications, it has been shown to be associated with a higher variceal recurrence rate than EIS. So, EIS is superior to EBL as a long-term treatment with a low variceal recurrence rate.

Table 3. Endoscopic band ligation (EBL) vs. combination of endoscopic band ligation plus endoscopic injection sclerotherapy (EIS)

	No. of sessions required (mean±SD)		Complication rate (%)		Obliteration of varices (%)		Recurrence of varices (%)	
	EBL	EBL+EIS	EBL	EBL+EIS	EBL	EBL+EIS	EBL	EBL+EIS
Authors, year								
Saeed <i>et al.</i> ⁴⁶ , 1997	3.3±0.4	4.1±0.6	25	65	64	54.5	16	23
Laine <i>et al.</i> ⁴⁵ , 1996	2.7±0.4	4.9±0.6	10	29	-	-	-	-
Lo <i>et al.</i> ⁴⁸ , 1998	3.7±0.9	3.4±1.1	-	-	91	97	43	14
Bhargava <i>et al.</i> ⁴⁷ , 1997	4.3±1.8	5.9±2.3	40	60	24	87	-	-
Masumoto <i>et al.</i> ⁴⁹ , 1999	3.5±1.1	2.3±0.5	31	44	84	81	72	22.1
Al Traif <i>et al.</i> ⁵⁰ , 1999	3.6±0.1	3.8±0.5	16	20	81	86	6	21

EBL also seems to be a viable option for the treatment of smaller gastric varices. In a study from Egypt, Shiha *et al.*⁴⁴ recorded a significantly lower rebleeding rate after EBL compared to the one previously reported for patients treated with EIS. However, large randomized and carefully designed trials with long-term follow-up are more than necessary to confirm the value of EBL in the treatment of gastric varices.

Endoscopic detachable miniloops

Detachable miniloops have been tested as an alternative to band ligation (Fig. 2). Sung and Chung⁴⁰ consider the method superior to band ligation for the ability to place an unlimited number of loops with the probable cost reduction and advantages of transparent cylinder for visualization. Furthermore, Hachisu *et al.*⁴² found that the eradication rates were nonsignificantly higher when miniloops were used. Although these studies have shown an initially good response with the use of miniloops for esophageal variceal ligation, the number of patients were too small and the follow-up periods too short. Obviously, further comparative studies are necessary to prove the superiority of detachable loops over multiple ligation devices, if already existing⁴³.

Cipolletta *et al.*⁴¹ found a significant reduction in the size of gastric varices in more than a half of patients when miniloops were used, without early bleeding over 2 to 6 months. Therefore, loop ligation appears to be better suited for gastric varices than band ligation. Anyway, according to our own experience, the technical 'simplicity' of gastric variceal loop ligation is very questionable, and more data are needed from a large number of patients and with a longer follow-up to establish loop ligation as the method of choice in gastric variceal ligation.

Combined endoscopic band ligation and injection sclerotherapy

There are two types of combined EBL and EIS: synchronous therapy as a combination of initial EBL and EIS together, and sequential therapy as a combination of variceal banding followed by sclerotherapy. The main idea of the technique using a combination of EIS and EBL is to overcome the limitations of the individual techniques and to achieve: 1) faster variceal obliteration, 2) fewer endoscopy sessions, 3) lesser complications, 4) lower recurrence rate, and 5) cost - benefit advantage over either technique used individually. Several clinical studies have attempted to address one or more of these issues using two different approaches: (1) comparing EIS alone with a combination of EBL and EIS; or (2) comparing EBL alone with a combination of EBL and EIS (Table 3).

Regarding the first two issues, i.e. whether the combined technique of EBL and EIS (combined therapy) can achieve faster obliteration of varices with fewer endoscopy sessions as compared with EBL alone, Laine *et al.*⁴⁵ and Saeed *et al.*⁴⁶ observed the opposite: combined therapy significantly increased the number of endoscopy sessions and the time required for variceal obliteration. Similar observations have been reported by Bhargava *et al.*⁴⁷, Lo *et al.*⁴⁸, and Masumoto *et al.*⁴⁹, and have once again been reaffirmed in the study of Al Traif *et al.*⁵⁰

Regarding the third issue, the frequency and severity of complications using a combined technique, nearly all available studies suggest that the frequency of complications was higher in patients treated with combination therapy. Saeed *et al.*⁴⁶ observed that deep ulcers were significantly more common and in fact led to more frequent ulcer-related bleeding episodes in the combination treated patients than in those treated with band ligation.

Similar observations have also been reported by Laine *et al.*⁴⁵

The fourth issue, the rate of variceal recurrence after initial obliteration, does not raise concern in the beginning when early variceal obliteration is the main aim. Nevertheless, it assumes great importance during the follow-up period. High recurrence rates following EBL could be attributed to two main limitations of the technique: 1) the inability to further ligate varices once they have become small, and 2) inadequate obliteration of the perforating veins that connect esophageal veins to paraesophageal collaterals. It is only the issue of variceal recurrence where the technique of EBL needs to be supplemented. Takeuchi *et al.*⁵¹ and Masumoto *et al.*⁴⁹ found that combined therapy helped reduce the high complication rate of EIS as well as the high recurrence rate after ligation therapy.

Considering the fifth issue, the cost - benefit advantage of combined therapy over individual techniques, there is only one published study evaluating the economic costs of treating esophageal variceal hemorrhage using EIS and EBL. Gralnek *et al.*⁵² evaluated direct costs of health care

with a possible increase in complications. Therefore, EVL alone appears to be as yet the treatment of choice for achieving variceal obliteration in patients who have bled from varices in the past. However, the prohibitive cost of disposable variceal banding equipment limits its universal use, particularly in developing countries with limited fiscal and health care resources (Table 4). According to our own experience, initial EVL followed by long-term EIS on later sessions, when banded varices have become smaller, may be a rational approach for safe and longlasting variceal eradication.

Prophylactic endoscopic variceal ligation

Until the year 2000, prophylactic EVL was considered a promising but not recommendable treatment for routine clinical use for prophylaxis of initial variceal bleeding.^{29,30,53,54} Lo *et al.*⁵³ found that EVL did not significantly reduce the risk of initial bleeding episode from esophageal varices in cirrhotic patients with a high risk of bleeding from esophageal varices. Only a subgroup of patients (Child-Pugh class B) had a reduced frequency of

Table 4. Cost items in Croatia

	Cost (HRK)
Esophagogastroduodenoscopy	180.00
Sclerotherapy needles (0.4-0.7 mm; GIP MediGlobe, Germany)	
– disposable	302.00
– nondisposable	1275.00
Polydocanol 1% (Aethoxysclerol 30 mL, Kreussler Pharma, Germany)	124.50
Histoacryl 0.5 mL (B/Braun, Germany) + Lipiodol 5 mL (Guerbet, Germany)	77.00 + 124.40
Saeed Ten Shooter Multi-Band Ligator (MBL-10; Wilson-Cook, USA)	2076.10
Quick-Loop for Variceal Ligation (HX-21L-1, MAJ-339; Olympus, Japan)	1567.70* + 1230.66

*Introducer (HX-21L-1), nondisposable. Cost items as *per* March 15, 2001 (1 DEM=3.95 HRK).

use and cost - effectiveness of EIS compared with EBL in the prevention of variceal rebleeding and patient survival at 1-year follow-up. The median total direct cost outcomes were similar in the two groups. EBL and EIS had similar costs *per* variceal rebleeding prevented and cost *per* survival. In the subgroup of active bleeders, EIS had a substantially lower cost *per* survival. The authors concluded that resource utilization was similar between the treatment groups and that the choice of endoscopic therapy for esophageal variceal hemorrhage must still rely on clinical grounds.

In conclusion, there is clear evidence that simultaneous addition of EIS hinders and delays obliteration of varices

the initial episode of esophageal variceal bleeding after prophylactic EVL with a trend of reducing mortality from variceal bleeding. Since the year 2000, prophylactic EVL is becoming an acceptable option for the prevention of initial bleeding from large esophageal varices, which has been confirmed in several trials⁵⁵: 1) meta-analysis reviewing eight randomized controlled studies, which showed reduced bleeding-related complications among EVL groups compared with either untreated controls or those receiving beta-blockers⁵⁶; 2) prophylactic EVL was found to be comparable to beta-blockers concerning prevention of initial bleeding, serious adverse events, rate of liver transplantation, and mean direct costs⁵⁷; and 3) prophylactic

lactic EVL was associated with a lower rate of variceal bleeding compared with untreated control subjects during a median observation period of 14 months⁵⁸. Anyway, the exact role of prophylactic EVL has not yet been completely defined.

Endoscopic Variceal Obliteration

Cyanoacrylate glue

Cyanoacrylate glue injection for endoscopic treatment of esophagogastric varices was first reported in 1986 by Soehendra *et al.*⁶⁷. For several years now, there has been an increasingly widespread use of tissue adhesives or glues in the treatment of bleeding esophagogastric varices to achieve rapid hemostasis and to prevent rebleeding.

There are two chemical forms of cyanoacrylate: N-butyl-2-cyanoacrylate (Histoacryl) and isobutyl-2-cyanoacrylate. Cyanoacrylate is a fast-solidifying substance, appropriately used for occlusion of the varices. It physically occludes the lumen of the bleeding vessel immediately due to the chain polymerization reaction triggered by contact between the cyanoacrylate and blood, which transforms the cyanoacrylate from its original liquid form into a solid substance. It is unlikely to cause inflammation and subsequent fibrosis of the esophageal wall, therefore it does not prevent the development of new varices. It is a highly effective agent for immediate hemostasis as well as for obliterating large varices.

To date, Histoacryl is the only endoscopic treatment that has been proved to be effective for gastric varices^{27,28,59,60,63}. After intravariceal application, Histoacryl undergoes an instantaneous polymerization reaction and hardens, thereby plugging the variceal lumen, enabling rapid hemostasis of an actively bleeding varix, and prevents rebleeding of the treated varix. However, reports on endoscopic treatment of esophageal varices using tissue glue are not absolutely favorable. Two studies by Sung *et al.*^{61,62} have not shown cyanoacrylate to be an attractive modality in comparison with either EBL or EIS; initial hemostasis was equal in all patient groups, but the early rebleeding and complication rates were higher in the glue group than in the ligation or sclerotherapy group. Fatal complications of the use of cyanoacrylate, despite its instantaneous polymerization process in the blood, have been reported in the literature: embolization of the solidified glue into the lungs⁶⁴ and brain⁶⁵, and progressive cardiac failure⁶⁶. Such reports support the view that its use should be limited to the treatment of massive acute bleeding and huge gastroesophageal

varices, particularly those that cannot be successfully treated with endoscopic ligation or injection sclerotherapy. Mucosal ulcerations always occur after glue injection and allow the solidified glue to extrude. It should therefore be regarded as a normal consequence of glue injection rather than a complication. Bleeding from such ulcers is only observed if the varix has not been completely obliterated during the initial injection. Today, Histoacryl is routinely diluted with the oily contrast agent lipidolol in a ratio of 1:1.5, in order to prevent premature solidification within or at the tip of the injection catheter during injection, because lipidolol alters the polymerization time of Histoacryl; and to permit x-ray monitoring as lipidolol is radiopaque, thus enabling evaluation of the Histoacryl extension toward the shunts (Fig. 3).

Poly-N-acetyl glucosamine (p-GlcNAc) gel

The substance originates from marine microalgae, is biocompatible, and has the effect of stimulating erythrocyte aggregation as well as vessel obliteration. In all cases, hemostasis was possible after three or four injections (the mean volume of the gel injected was 1.9 mL). Permanent obliteration of the vessels was achieved in all cases after one session. Over 90 days, the gel was gradually replaced by connective tissue. Embolization to other organs, stricture formation, and development of antibodies against the substance were not observed. Kulling *et al.*⁶⁸ suggest that p-GlcNAc gel may be a potential alternative to cyanoacrylate glue. The advantages of the gel may include its easier application, without the risk of distant embolization associated with cyanoacrylate.

Endoscopic Clipping

Clipping of esophageal varices was originally demonstrated in 1990 by Miyoshi *et al.*⁶⁹ as another method whereby esophageal varices were ligated by an endoscopically guided clipping device. Since the use of EIS for the control of esophageal varices was widespread in Japan at the beginning of the 1990s, in an effort to reduce the risk of complications, Urita *et al.*⁷⁰ developed a method that combined endoscopically guided clipping and EIS: by first clipping, then injecting sclerosant solution within and beside the varix, it was retained for an extended period, thus permitting the use of a smaller volume of sclerosant. Comparing the combined method with EIS alone, the authors found that fewer repeated endoscopic sessions and

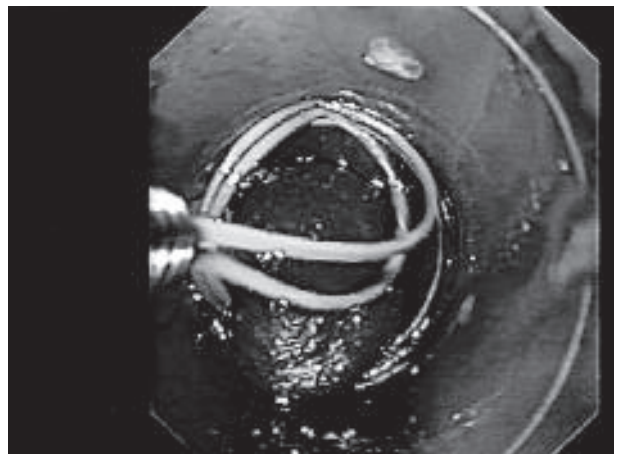
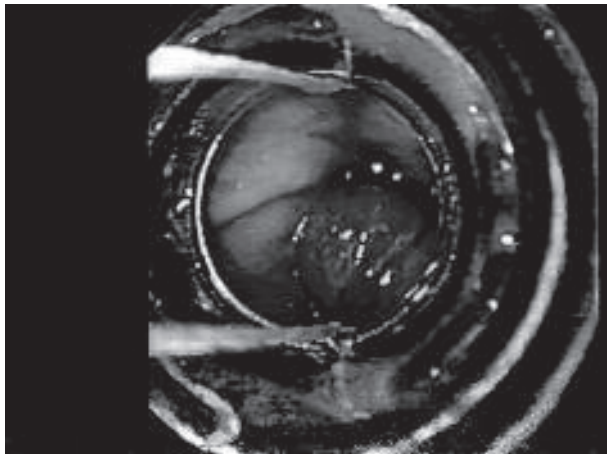
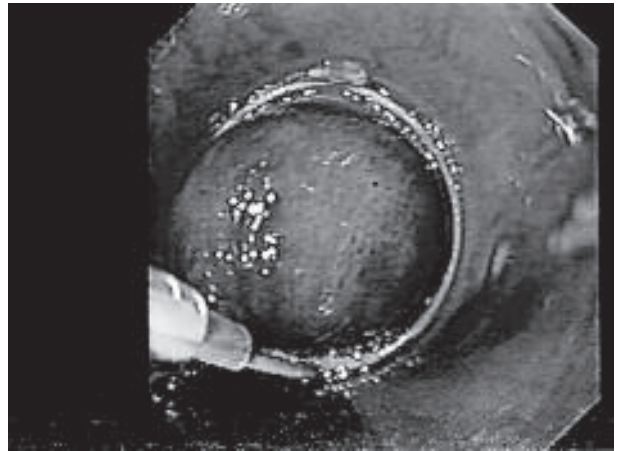
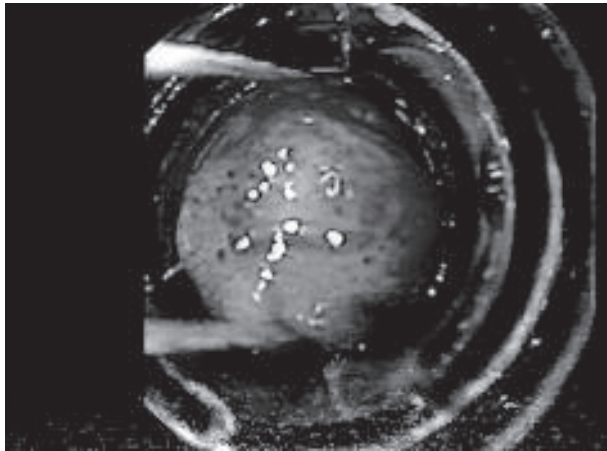


Fig. 1. Endoscopic Multi-Band Ligator (Wilson-Cook, USA) for variceal ligation.

*(a) The varix is sucked into the cylinder.
(b) The band-ligator in place.*

Fig. 2. Endoscopic Detachable Miniloop (Olympus, Japan) for variceal ligation.

*(a) The varix is sucked into the cylinder.
(b) The detachable miniloop in place.*

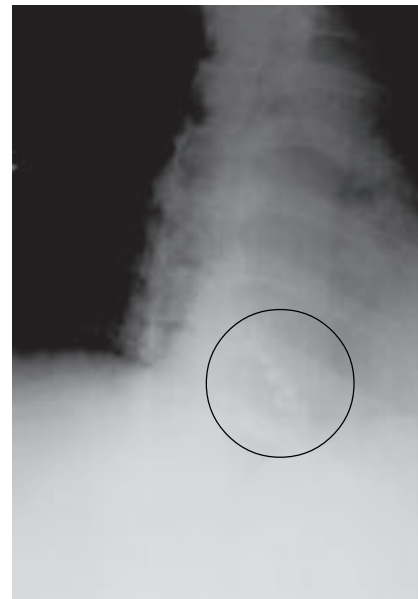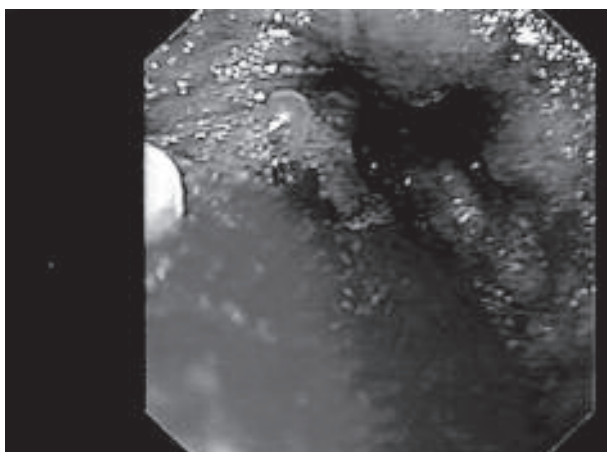


Fig. 3.

*(a) Esophageal varix obliterated with Histoacryl - Lipiodol mixture.
(b) Obliterated varix is seen on the x-ray.*

lesser sclerosant solution volume were required, with a higher success rate and fewer complications than with EIS alone. However, the use of clips alone in the treatment of varices remains uncommon. This method fails to achieve permanent variceal eradication, and is therefore unlikely to be cost-effective⁴³.

Endosonography in the Treatment of Varices

The role of endoscopic ultrasound (EUS) has increased in the evaluation of portal hypertension and esophagogastric varices. Today, EUS can be used to investigate the pattern of varices and collaterals, and to monitor therapeutic effect. EUS has a role in evaluating the risk of recurrence and rebleeding after endoscopic treatment, as confirmed again by the study of Lo *et al.*⁷¹. So, the high-resolution EUS miniprobe was found to be able to visualize the intramural, paraesophageal and periesophageal vascular structures in detail, as well as to demonstrate the therapeutic effect of EIS and EBL⁴³. The diameter of perforating veins was found to positively correlate with the presence of red spots and grade of esophageal varices. Periesophageal veins were more common in patients with high-grade varices and red spots. Patients in whom perforating and periesophageal veins disappeared after EIS were observed to have a low risk of variceal recurrence. On the other hand, patients who underwent EBL therapy were found to have persistent perforating and periesophageal veins even after eradication, which could explain the high recurrence rates observed with this treatment modality. The authors give the opinion that the exact visualization of the collateral circulation could be a prerequisite for the eradication of varices and might help predict inappropriate endoscopic treatment or recurrence. However, further investigations of this new diagnostic approach are required to determine whether these observations will have an impact on the management of variceal bleeding, particularly in choosing among different modalities.

References

- GRAHAM DY, SMITH JL. The course of patients after variceal hemorrhage. *Gastroenterology* 1981;80:800-9.
- D'AMICO G, PAGLIARO L, BOSCH J. The treatment of portal hypertension; a meta-analytic review. *Hepatology* 1995;22:332-54.
- CALES P, DESMORAT H, RAVAND A *et al.* Incidence and rate of occurrence of large oesophageal varices in cirrhotic patients: application to screening for prophylaxis of first haemorrhage. *J Hepatol* 1988;7:515-24.
- CHRISTENSEN E, FAVERHOLDT L, SCHILCHILING P *et al.* Aspect of the natural history of gastrointestinal bleeding in cirrhosis and the effect of prednisolone. *Gastroenterology* 1981;81:520-8.
- DAGRADI AE. The natural history of esophageal varices in patients with alcoholic liver disease: an endoscopic and clinical study. *Am J Gastroenterol* 1972;57:520-31.
- GRACE ND. Prevention of initial variceal hemorrhage. *Gastroenterol Clin North Am* 1992;21:149-63.
- MERKEL C, BOLOGNESI M, ANGELI P *et al.* Prognostic indicators of survival in patients with cirrhosis and esophageal varices without previous bleeding. *Am J Gastroenterol* 1989;84:717-32.
- PRANDI D, RUEFF B, ROCHE-SICOT J *et al.* Life threatening hemorrhage of the digestive tract in cirrhotic patients. *Am J Surg* 1976;131:204-16.
- GRACE ND. A hepatologist's view of variceal bleeding. *Am J Surg* 1990;160:26-39.
- SMITH JL, GRAHAM DY. Variceal hemorrhage: a critical evaluation of survival analysis. *Gastroenterology* 1982;82:968-84.
- DeFRANCHIS R, PASCAL JP, ANCONA E *et al.* Definitions, methodology and therapeutic strategies in portal hypertension: a consensus development workshop. *J Hepatol* 1992;15:256-75.
- BURROUGHS AK, McCORMICK PA. Prevention of variceal rebleeding. *Gastroenterol Clin North Am* 1992;21:119-35.
- SARIN SK. Diagnostic issues: portal hypertensive gastropathy and gastric varices. In: DeFRANCHIS R, ed. *Portal hypertension II: Proceedings of the Second Baveno International Consensus Workshop on Definitions, Methodology and Therapeutic Strategies*. Oxford: Blackwell Science, 1996:30-55.
- SARIN SK, LAHOTI D, SAXENA SP *et al.* Prevalence, classification and natural history of gastric varices: long-term follow-up study in 568 patients with portal hypertension. *Hepatology* 1992;95:434-52.
- CRAFOORD C, FRENCKER P. New surgical treatment of varicose veins of the oesophagus. *Acta Otolaryngol* 1939;27:422-9.
- HIGASHI H, KITANO S, HASHIZUME M *et al.* A prospective randomized trial of schedules for sclerosing esophageal varices: 1-*versus* 2-week intervals. *Hepatogastroenterology* 1989;36:337-40.
- WESATBLY D, MELIA WM, MacDOUGALL BRD *et al.* Injection therapy for esophageal varices: a prospective randomized trial of different treatment schedules. *Gut* 1984;25:129-32.
- SARIN SK, SACHDEV G, NANDA RN *et al.* Comparison of the two time schedules for endoscopic sclerotherapy: a prospective randomized controlled study. *Gut* 1986;27:710-4.
- ROBERTS LR, KAMATH PS. Pathophysiology and treatment of variceal hemorrhage. *Mayo Clin Proc* 1996;71:973-83.
- TERBLANCHE J, KRIGE JEJ, BORNMAN PC. The treatment of esophageal varices. *Annu Rev Med* 1992;43:69-82.
- TERBLANCHE J. Issues in gastrointestinal endoscopy: oesophageal varices: inject, band, medicate or operate. *Scand J Gastroenterol* 1992;27(Suppl 192):63-6.
- PUGH S, LEWIS S, SMITH PM. Bleeding oesophageal varices in alcoholic cirrhosis: long-term follow-up of endoscopic sclerotherapy. *QJM* 1993;86:241-5.
- WAKED I, KORULA J. Analysis of long-term endoscopic surveillance during follow-up after variceal sclerotherapy from a 13-year experience. *Am J Med* 1997;102:192-9.

24. KRIGE JEJ, BORNMAN PC, GOLDBERG PA, TERBLANCHE J. Variceal rebleeding and recurrence after endoscopic injection sclerotherapy: a prospective evaluation in 204 patients. *Arch Surg* 2000;135:1315-22.
25. SARIN SK. Long term follow up of gastric variceal sclerotherapy: an eleven-year experience. *Gastrointest Endosc* 1997;46:8-14.
26. BINMOELLER KF, BORSATTO R. Variceal bleeding and portal hypertension. *Endoscopy* 2000;32:189-99.
27. D'IMPERIO N, PIEMONTESE A, BARONCINI D *et al.* Evaluation of undiluted N-butyl-2-cyanoacrylate in the endoscopic treatment of upper gastrointestinal tract varices. *Endoscopy* 1996;28:239-43.
28. BINMOELLER KF, SOEHENDRA N. "Superglue": the answer to variceal bleeding and fundal varices? *Endoscopy* 1995;27:392-6.
29. SVOBODA P, KANTOROVA I, OCHMANN J *et al.* A prospective randomized controlled trial of sclerotherapy *vs.* ligation in the prophylactic treatment of high risk esophageal varices. *Surg Endosc* 1999;13:580-4.
30. GOTOH Y, IWAKIRI R, SAKATA Y *et al.* Evaluation of endoscopic variceal ligation in prophylactic therapy for bleeding of esophageal varices: a prospective, controlled trial compared with endoscopic injection sclerotherapy. *J Gastroenterol Hepatol* 1999;14:241-4.
31. STEIGMANN GV, CAMBRE T, SUN JH. A new endoscopic elastic band ligating device. *Gastrointest Endosc* 1986;32:230-3.
32. LAINE L, COOK D. Endoscopic ligation compared with sclerotherapy for treatment of esophageal varices and bleeding: a meta-analysis. *Ann Intern Med* 1995;123:280-7.
33. DeFRANCHIS R, BANARES R, SILVAIN C. Emergency endoscopy strategies for improved outcomes. *Scand J Gastroenterol* 1998;226:25-36.
34. STEIGMANN GV, GOFF JS, MICHALETZ-ONODY PA *et al.* Endoscopic sclerotherapy as compared with endoscopic ligation for bleeding esophageal varices. *N Engl J Med* 1992;326:1527-32.
35. HOU MC, LIN HC, KUO BI, CHEN CH, LEE FY, LEE SD. Comparison of endoscopic variceal injection sclerotherapy and ligation for the treatment of esophageal variceal hemorrhage: a prospective randomized trial. *Hepatology* 1995;21:1517-22.
36. SARIN SK, GOVIL A, JAIN AK, GUPTAN RC, ISSAR SK, JAIN M. Prospective randomized trial of endoscopic sclerotherapy *versus* variceal band ligation for esophageal varices: influences on gastropathy, gastric varices and variceal recurrence. *J Hepatol* 1997;26:826-32.
37. AVGERINOS A, ARMONIS A, MANOLOKOPOULOS S *et al.* Endoscopic sclerotherapy *versus* variceal ligation in the long term management of patients with cirrhosis after variceal bleeding: a prospective randomized study. *J Hepatol* 1997;26:1034-41.
38. BARONCINI D, MILANDRI GL, BORIONI D *et al.* A prospective randomized trial of sclerotherapy *versus* ligation in the elective treatment of bleeding esophageal varices. *Endoscopy* 1997;29:235-40.
39. HOU MC, LIN HC, KUO BI, LEE FY, CHANG FY, LEE SD. The rebleeding course and long-term outcome of esophageal variceal hemorrhage after ligation: comparison with sclerotherapy. *Scand J Gastroenterol* 1999;34:1071-6.
40. SUNG JJY, CHUNG SCS. The use of a detachable mini-loop for the treatment of esophageal varices. *Gastrointest Endosc* 1998;47:1780-1.
41. CIPOLLETTA L, BIANCO MA, ROTONDANO G *et al.* Emergency endoscopic ligation of actively bleeding gastric varices with a detachable snare. *Gastrointest Endosc* 1998;47:400-3.
42. HACHIN T, SATOH SI, FUJII T *et al.* Endoscopic ligation of esophageal varices using a detachable snare and transparent cap with rim. *Dig Endosc* 1997;9:183-8.
43. BOHNACKER S, MAYDEO A, SOEHENDRA N. Variceal bleeding and portal hypertension: still a therapeutic challenge? *Endoscopy* 1999;31:26-37.
44. SHIHA G, EL-SAYED SS. Gastric variceal ligation: a new technique. *Gastrointest Endosc* 1999;49:437-41.
45. LAINE L, STEIN C, SHARMA V. Randomized comparison of ligation *versus* ligation plus sclerotherapy in patients with bleeding esophageal varices. *Gastroenterology* 1996;110:529-33.
46. SAEED ZA, STEIGMANN GV, RAMIREZ FC *et al.* Endoscopic variceal ligation is superior to combined ligation and sclerotherapy for esophageal varices: a multicenter prospective randomized trial. *Hepatology* 1997;25:71-4.
47. BHARGAVA DK, POKHARMA R. Endoscopic variceal ligation *versus* endoscopic variceal ligation and endoscopic sclerotherapy: a prospective randomized study. *Am J Gastroenterol* 1997;92:950-3.
48. LO GH, LAI KH, CHENG JS *et al.* The additive effect of sclerotherapy to patients receiving repeated endoscopic variceal ligation: a prospective randomized trial. *Hepatology* 1998;28:391-5.
49. MASUMOTO H, TOYONAGA A, OHO K, IWAO T, TANIKAWA K. Ligation plus low volume sclerotherapy for high risk esophageal varices: comparison with ligation therapy or sclerotherapy alone. *J Gastroenterol* 1998;33:1-5.
50. AL TRAI F, SBEIH F, AL JUMAH AR *et al.* Randomized trial of ligation *vs.* combined ligation and sclerotherapy for bleeding esophageal varices. *Gastrointest Endosc* 1999;50:1-6.
51. TAKEUCHI M, NAKAI Y, SHA S *et al.* Combined ligation and paravariceal injection sclerotherapy for esophageal varices: outcome over 3 years. *Gastrointest Endosc* 1997;39:1189-95.
52. GRALNEK IM, JENSEN DM, KOVACS TOG *et al.* The economic impact of esophageal variceal hemorrhage: cost-effectiveness implications of endoscopic therapy. *Hepatology* 1999;29:44-50.
53. LO GH, LAI KH, CHENG JS, LIN CK, HSU PI, CHIANG HT. Prophylactic band ligation of high-risk esophageal varices in patients with cirrhosis: a prospective randomized trial. *J Hepatol* 1999;31:451-6.
54. LUKETIC VA, SANYAL AJ. Esophageal varices. I. Clinical presentation, medical therapy, and endoscopic therapy. *Gastroenterol Clin North Am* 2000;29:337-85.
55. KASSEM AM. Gastrointestinal bleeding. *Endoscopy* 2000;32:845-9.
56. IMPERIALE TF, CHALASANI N. A meta-analysis of prophylactic variceal ligation for esophageal hemorrhage in patients with cirrhosis. *Gastroenterology* 2000;118:A964.
57. JUTABHA R, JENSEN DM, MARTIN P *et al.* Initial report of a randomized, prospective study of prophylactic propranolol compared to rubber band ligation for prevention of first variceal hemorrhage in cirrhotics with large esophageal varices. *Gastroenterology* 2000;118:AB212.
58. OMAR MM, ATTIA MH, MOSTAFA IM. Prophylactic band ligation to prevent first bleeding from large esophageal varices. *Gastrointest Endosc* 2000;51:AB122.
59. OHO K, IWAO T, SUMINO M *et al.* Ethanolamine oleate *versus* butyl cyanoacrylate for bleeding gastric varices: a nonrandomized study. *Endoscopy* 1995;27:349-54.
60. RAMOND MJ, VALLA D, MOSNIER JF *et al.* Successful endoscopic obturation of gastric varices with butyl cyanoacrylate. *Hepatology* 1989;10:488-93.

61. SUNG JY, LEE YT, SUEN R *et al.* Banding is superior to cyanoacrylate for the treatment of esophageal variceal bleeding: a prospective randomized study. *Dig Dis Week Abstract Book* 1998;A524.
62. SUNG JY, YEO W, SUEN R *et al.* Injection sclerotherapy for variceal bleeding in patients with hepatocellular carcinoma: cyanoacrylate *versus* sodium tetradecyl sulfate. *Gastrointest Endosc* 1998;47:235-9.
63. OGAWA K, ISHIKAWA S, NARITAKA Y *et al.* Clinical evaluation of endoscopic injection sclerotherapy using N-butyl-2-cyanoacrylate for gastric variceal bleeding. *J Gastroenterol Hepatol* 1999;14:245-50.
64. NAGA M, FODA A. An unusual complication of Histoacryl injection. *Endoscopy* 1997;29:140.
65. SEE A, FLORENT C, LAMY P *et al.* Cerebral infarction following endoscopic obliteration of esophageal varices using isobutyl-2-cyanoacrylate: report of 2 cases. *Gastroenterol Clin Biol* 1986;10:8-9.
66. TSOKOS M, BARTEL A, SCHOEL R *et al.* Fatal pulmonary embolus after endoscopic embolization of a "down-hill" oesophageal varix. *Dtsch Med Wochenschr* 1998;123:691-5.
67. SOEHENDRA N, NAM VC, GRIMM H, KEMPENEERS I. Endoscopic obliteration of large esophagogastric varices with bucrylate. *Endoscopy* 1986;18:25-6.
68. KULLING D, HAWES RH, WOO S *et al.* Endoscopic injection of bleeding esophageal varices using poly-N-acetyl glucosamine gel induces hemostasis and varix obliteration in one session. *Dig Dis Week Abstract Book* 1998:A871.
69. MIYOSHI H, TOKURA Y, YAMAFUJI K, OTANI Y, ASAMI A, KATSUMATA K. Endoscopic esophageal variceal ligation using clipping apparatus. *Progr Dig Endosc* 1990;37:112-4.
70. URITA Y, KONDO E, MUTO M *et al.* Combined endoscopic clipping and injection sclerotherapy for esophageal varices. *Gastrointest Endosc* 1996;43:140-3.
71. LO GH, LAI KH, CHENG JS *et al.* Prevalence of paraesophageal varices and gastric varices in patients achieving variceal obliteration by banding ligation and by injection sclerotherapy. *Gastrointest Endosc* 1999;49:428-36.

SAŽETAK

ENDOSKOPSKO LIJEČENJE KRVARENJA IZ GASTROEZOFAGUSNIH VARIKOZITETA

N. Ljubičić i M. Špero

Prikazane su suvremene mogućnosti endoskopskog liječenja krvarenja iz gastroezofagusnih varikoziteta. Dva su glavna načina endoskopskog liječenja gastroezofagusnih varikoziteta: endoskopska injekcijska skleroterapija i endoskopska ligacija varikoziteta. Endoskopska skleroterapija i ligacija varikoziteta kao samostalne metode podjednako su učinkovite u zaustavljanju akutnog krvarenja iz varikoziteta, no endoskopska ligacija varikoziteta bolja je metoda u odnosu na skleroterapiju jer se njome obliteracija varikoziteta postiže brže i u manjem broju tretmana te s manjim brojem komplikacija. Glede kombinacije ligacije i skleroterapije, inicijalna ligacija, a potom postupci skleroterapije kad podvezani varikoziteti postanu manji, vjerojatno je prikladniji postupak za sigurno i dugotrajno iskorjenjivanje varikoziteta. Obliteracija varikoziteta Histoacrylom jedini je potvrđen i djelotvoran način endoskopskog liječenja varikoziteta želuca. Upotreba endoskopskih klipsa kao samostalan način liječenja još uvijek nije preporučljiva. Uloga endoskopskog ultrazvuka u procjeni portalne hipertenzije raste, a isti može steći ulogu u odabiru najboljeg pristupa liječenju svakog bolesnika pojedinačno.

Ključne riječi: *Ezofagusni i želučani varikoziteti, terapija; Gastrointestinalno krvarenje, terapija; Endoskopija, probavni sustav*