

Dubravka Negovetić Vranić¹, Josipa Jurković², Jesenka Jeličić³, Antonija Balenović⁴, Gordana Stipančić⁵, Ivana Čuković-Bagić¹

Hitna stanja u dječjoj stomatologiji

Medical Emergencies in Pediatric Dentistry

¹ Zavod za dječju i preventivnu stomatologiju Stomatološkog fakulteta Sveučilišta u Zagrebu, Hrvatska
Department of Pediatric and Preventive Dentistry, School of Dental Medicine, University of Zagreb, Croatia

² Privatna ordinacije dentalne medicine, Zagreb, Hrvatska
Private dental office, Zagreb, Croatia

³ Dom zdravlja Zagreb – Istok, Zagreb, Hrvatska
Health Center Zagreb – East, Zagreb, Croatia

⁴ Dom Zdravlja Zagreb – Centar, Zagreb, Hrvatska
Health Center Zagreb – Center, Zagreb, Croatia

⁵ Katedra za pedijatriju Stomatološkog fakulteta Sveučilišta u Zagrebu, Hrvatska
Paediatric Department, School of Dental Medicine, University of Zagreb, Croatia

Sažetak

Hitna stanja opasna za život mogu se dogoditi, i događaju se, i u ordinaciji dentalne medicine. Mogu nastati zbog komplikacija osnovne bolesti i kao reakcija na lijekove koja može biti alergijska i toksična. Najčešće toksične reakcije uzrokuju lokalni anestetici, a alergije se pojavljuju uglavnom pri primjeni antibiotika, najčešće penicilina. Kao reakcija na stres najčešće nastaje vazovagalna sinkopa. Ostali uzroci mogu biti povezani s osnovnom bolesti određenog sustava (akutni astmatski napadaj, dijabetička ketoacidoza, hipoglikemija, epileptički napadaji itd.), ili su nesretni slučajevi (aspiracija stranog tijela, što uzrokuje opstrukciju dišnog sustava). Za sve navedeno propisane su smjernice koje je potrebno znati. Ako nastanu komplikacije, a ne poduzmu se potrebne mjere, može se dogoditi zastoj srca ili prestanak disanja pa je potrebna kardiopulmonalna reanimacija. Sve postupke i doze nužno je prilagoditi dobi djeteta.

Zaprimljen: 1. veljače 2016.
Prihvaćen: 5. ožujka 2016.

Adresa za dopisivanje
doc. dr. sc. Dubravka Negovetić Vranić
Sveučilište u Zagrebu
Stomatološki fakultet
Zavod za dječju i preventivnu
stomatologiju
Gundulićeva 5, 10000 Zagreb
Tel.: 01/4802-110
dnegovetic@sfgz.hr

Ključne riječi

dječja stomatologija; hitni postupci;
prva pomoć; maske; reanimacija

Uvod

Hitna stanja opasna za život mogu se dogoditi, a i događaju se, i u ordinaciji dentalne medicine. U dostupnoj literaturi većina preporuka za njihovo tretiranje odnosi se na odrasle pacijente (1). No kako djeca nisu odrasle osobe u malom, postupke je potrebno prilagoditi (2). Preporuke za liječenje hitnih stanja kod djece nisu dovoljno obrađene.

Doktor dentalne medicine trebao bi obaviti svaki svoj zahvat tako da se ne dogode nepotrebne komplikacije. No kako bismo spriječili komplikacije ili ih barem ublažili, potrebno je detaljno proučiti anamnezu, doznati sve o djetetovim prijašnjim i sadašnjim bolestima te se, ako je potrebno, konzultirati s njegovim liječnikom. Katkad je nužna premedikacija. Ako dijete boluje od neke teže bolesti zbog koje bi se tijekom zahvata mogle pojaviti komplikacije koje ugrožavaju život, zahvat se odgađa i poslije obavlja u bolničkim uvjetima (1).

Razlike između djece i odraslih očituju se u veličini i obliku tijela, u težini, te u kognitivnim sposobnostima i emotivnoj zrelosti, ali važne su i razlike u fiziologiji njihova organizma – dišnoga i kardiovaskularnoga te imunosnog sustava.

Introduction

Life threatening emergencies can occur in the dental office. Most recommendations for treatment of emergencies which can be found in the recently published literature refer to adult patients (1). Since children are not miniature adults, it is necessary to adapt the approach (2). Recommendations for treating emergencies in children have not yet been sufficiently addressed.

A dentist should perform each procedure in a way to avoid unnecessary complications. To prevent or reduce complications, it is necessary to take a detailed medical history, document all of the child's previous and current diseases, and, if necessary, consult with the referring general practitioner (GP) or pediatrician. Sometimes it can be necessary to administer premedication. If a child suffers from a serious illness, which could lead to life-threatening complications during the procedure, the surgery should be postponed and performed in a hospital setting (1).

Differences between children and adults are reflected in the size and shape of the body along with emotional and cognitive maturity, but differences in physiology, such as the re-

Mora se uzeti u obzir i razlika u farmakokinetici lijekova u djetetovu organizmu (3, 4).

Oprema koja se koristi mora biti prilagođena dobi pacijenta, tako npr. postoje različite veličine maski za disanje (slika 1. i tablica 1.) te orofaringealnoga (slika 2. i tablica 2.) i endotrahealnog tubusa koji moraju biti ispravno odabrani kako bi bili učinkoviti.

Orofaringealni tubus (slika 3.) djeci se uvodi direktnom metodom, a odraslima konkavitom prema nepcu do mekoga nepca i laganom rotacijom za 180° postavlja na mjesto. Ta se rotacija ne preporučuje kod djece zbog nježne strukture dišnih putova te zbog veličine jezika u odnosu na usnu šupljinu koji se pri uvođenju tubusa kontrolira špatulom.

Doziranje lijekova prijeko potrebnih u hitnim stanjima, kao i tehnike aplikacija, razlikuju se od onih za odrasloga pacijenta (5).

Ishemijske bolesti srca

U ishemijske bolesti srca ubrajaju se angina pectoris i infarkt miokarda.

Simptomi: nagla retrosternalna bol koja se širi u vrat, donju čeljust, ramena i ruke (slika 4.), a može se manifestirati kao osjećaj stezanja i nemogućnost disanja (6).

Terapija: potrebno je prekinuti stomatološki zahvat i pozvati hitnu pomoć; dati pacijentu sublingvalno 0,4 mg nitroglicerina u obliku tableta; bol u slučaju angine pectoris će prestati, a ako ne prestane, možemo posumnjati na infarkt miokarda i dok čekamo hitnu pomoć pacijentu treba dati 325 mg aspirina te prema potrebi kisik (7, 8).

Srčani zastoj

Zastoj srca nagli je prestanak rada srčane crpke. Klinički ga obilježavaju nemogućnost palpacije bila, gubitak svijesti i apneja. Iako srčani zastoj kod djeteta može biti posljedica respiratornoga ili cirkulacijskog zatajenja, ipak je najčešće problem u dišnom sustavu. Terapija ako dijete ne diše ili povremeno teško diše: treba otvoriti dišni put (slika 5.) i pet puta upuhnuti zrak (prije svakog upuha spasilac treba duboko udahnuti i upuhnuti zrak žrtvi što je prije moguće da se kisikom u udahnutom zraku ne bi koristila njegova pluća); ako je spasilac siguran da palpira bilo i njegovu frekvenciju višu od 60 u minuti, treba nastaviti s umjetnom ventilacijom do dolaska kvalificirane pomoći; ako bila nema, treba početi s vanjskom masažom srca.

Djeci se vanjska masaža srca obavlja iznad donje polovine prsne kosti izbjegavajući kompresiju ksifoidnog nastavka, ritmom od 15 vanjskih masaža srca i dva upuha zraka.

Postupak oživljavanja ritmom 15 : 2 primjenjuje se kod djece do puberteta, a starija djeca i adolescenti oživljavaju se istim postupkom kao odrasli (2).

Pri vanjskoj masaži srca malog djeteta (slika 6.) zamislite crtu koja spaja njegove bradavice i položite na prsni koš tri prsta: kažiprst, srednjak i prstenjak. Kažiprst mora biti tik

spiratory, cardiovascular, and immune systems, are also important. The pharmacokinetics of drugs in the body of the child must also be taken into account (3, 4).

The equipment used must be adapted to the patient's age, for example there are different sizes of breathing masks (Figure 1 and Table 1) and oropharyngeal (Figure 2 and Table 2) or endotracheal tubes, which must be properly selected because if the size is not adequate, the efficiency is not adequate.

An oropharyngeal tube (Figure 3) should be introduced directly in children, as opposed to the way of applying the tube in adults in which the tube is concavely applied to the palate to reach the soft palate and then rotated by 180° to put it into position. Rotation is not recommended for children because of the delicate structure of their airway, and because of the size of the tongue in relation to the oral cavity. The dosage of medication to be used in emergency situations, as well as the application techniques, are different from those of an adult patient (5).

Ischemic heart disease

Ischemic heart disease includes angina pectoris and myocardial infarction.

Symptoms: sudden retrosternal pain that radiates to the neck, lower jaw, shoulders and arms (Figure 4), and can be manifested as a feeling of tightness and an inability to breathe (6).

Treatment: it is necessary to discontinue dental treatment, call an ambulance; administer dose of nitroglycerin 0.4 mg in tablets, sublingually and to stop the pain of angina pectoris; if the pain persists, myocardial infarction must be suspected and the patient given 325 mg aspirin and, if necessary, oxygen, while waiting for an ambulance (7, 8).

Cardiac arrest

Cardiac arrest is the sudden stopping of the heart. It is represented by the lack of pulse, loss of consciousness and apnea. Cardiac arrest in children may be a consequence of respiratory or circulatory failure, although usually the problem is in the respiratory system. Therapy: if the child is not breathing or has agonal breathing at times, open the airway (Figure 5) and apply five breaths of air; before each breath of air the rescuer should take a deep breath and supply air to the victim as soon as possible, so that oxygen in the inhaled air is not derived from his or her own lungs; if the rescuer is sure that the palpable pulse frequency of the patient is greater than 60 ppm, he or she should continue with artificial ventilation until the arrival of qualified assistance; if there is no pulse, he or she should begin with chest compressions, which are performed in children over the lower half of the sternum, avoiding compression of the xiphoid bone. The procedure should consist of 15 external cardiac massages and two breaths of air; this procedure for reviving children with a rhythm of 15:2 applies to children up to puberty, whereas older children and adolescents receive the reviving procedure similarly to adults (2).

The procedure for external cardiac massage in a small child is as follows (Figure 6): imagine a line that connects the nipples

uz zamišljenu crtu koja spaja bradavice. Podignite kažiprst u zrak te počnite s masažom pritiskom na sternum s preostala dva prsta. Ako pod prstenjakom osjetite ksifoidni nastavak, pomaknite malo prste prema zamišljenoj crti.

Pri vanjskoj masaži srca djeteta (slika 7.) opipajte srednjim prstom ksifoidni nastavak i položite uz njega kažiprst na sternum, zatim položite dlan na sternum uz točku koju ste dodirivali kažiprstom te počnite masirati. Tijekom masaže laktovi moraju biti ispruženi. Ksifoidni nastavak može se lako slomiti pod izravnim pritiskom, a to može izazvati obilno unutarnje krvarenje zbog rupture jetre i drugih unutarnjih organa. Zato je kod vanjske masaže srca nužno slijediti upute na slikama 5. i 6.

Dijabetička ketoacidoza

Dijabetička ketoacidoza razvija se kod bolesnika s apsolutnim ili relativnim nedostatkom inzulina i rezultira visokom hiperglikemijom, nakupljanjem ketona i razvojem metaboličke acidoze.

Simptomi: polidipsija, polifagija, poliurija, opća slabost, mučnina, povraćanje, hiperventilacija, zažareni obrazi, miris daha po acetonu, a može se pojaviti i poremećaj svijesti.

Terapija: prvi sat ili dva davati od 10 do 20 mL fiziološke otopine po kilogramu tjelesne težine; nakon dva sata takve terapije uključiti intravensku nadoknadu inzulina (9).

Hipoglikemija

Hipoglikemija je niska razina glukoze u krvi. To je najčešća akutna komplikacija dijabetesa, a može se pojaviti i kod pacijenata koji nemaju tu bolest.

Simptomi: tremor, glad, palpitacije, anksioznost, znojenje, glavobolja, umor, poremećaji svijesti, konvulzije i bljedilo (4).

Terapija: prekinuti sve zahvate; pacijenta smjestiti u nje mu udoban položaj, najčešće to znači uspravno sjediti; obratiti pozornost na disanje i cirkulaciju; dati ugljikohidrate oralno (šećer otopljen u vodi, sok od naranče, čokoladice), jedna porcija sadržava 40 g glukoze, te ponavljati dozu svakih 10 minuta dok simptomi ne nestanu; ako ne djeluje, dati 1 mg glukagona intramuskularno ili 50 mL 50 % dekstroze intravenski tijekom dvije do tri minute (10).

Akutna respiracijska insuficijencija zbog opstrukcije dišnih puteva

Mogu biti opstruirani gornji i donji dišni putovi, a ovisno o tome gdje je uzrok opstrukcije pojaviti će se različiti simptomi.

Simptomi: opstrukcija gornjih dišnih puteva klinički se očituje kašljem, cijanozom i inspiracijskim stridorom, a u slučaju opstrukcije donjih dišnih puteva prisutni su kašalj, gušenje, inspiracijsko-ekspiracijski stridor, otežano disanje i cijanoza, a ako opstrukcija potraje, pacijent može izgubiti svijest.

of a child. Put the following three fingers on the chest: index, third and fourth finger. The index finger should be close to the imaginary line that joins the nipples. Raise the index finger in the air and start massaging by putting pressure on the sternum with the two remaining fingers. If the fourth fingers feel the ziphoid bone, move the little finger towards the imaginary line.

Procedure for external cardiac massage in a child (Figure 7): feel with the middle finger the ziphoid bone and place the index finger on the sternum, then put hands on the sternum to the point you had touched with the index finger and start the massage. During the massage, the elbows are extended. The ziphoid bone can be easily broken under direct pressure, which may cause profuse internal bleeding because of rupture of the liver and other internal organs. Therefore, for external cardiac massage, the instructions shown in Figures 5 and 6 must be followed.

Diabetic ketoacidosis

Diabetic ketoacidosis can develop in patients with an absolute or relative insulin deficiency, resulting in high hyperglycemia, the accumulation of ketones and the development of metabolic acidosis. Symptoms: polydipsia, polyphagia, polyuria, weakness, nausea, vomiting, hyperventilation, red face, and the smell of acetone; it can lead to disorders of consciousness. Treatment: in the first hour, administer saline at a dose of 10–20 ml/kg body weight, and after 2 h of this treatment, include intravenous insulin (9).

Hypoglycemia

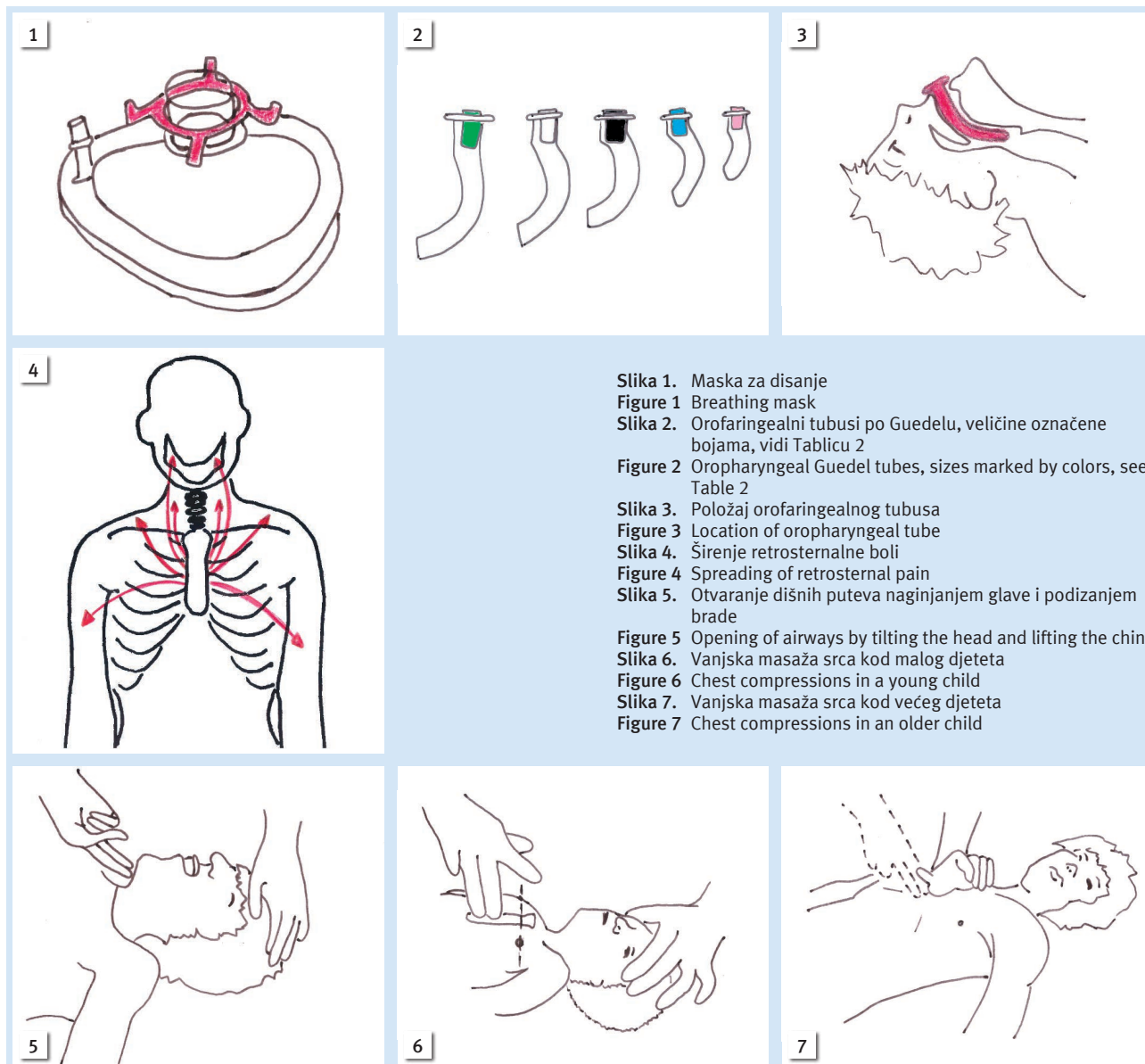
Hypoglycemia is a condition of low blood glucose levels. It represents the most common acute complication of diabetes but can also develop in patients who do not have diabetes.

Symptoms: tremor, hunger, palpitations, anxiety, sweating, headache, fatigue, disturbances of consciousness, convulsions and pallor (4).

Treatment: stop all procedures, place the patient in a comfortable position (usually this means to sit up straight), pay attention to breathing and circulation, give oral carbohydrates (sugar dissolved in water, orange juice, chocolate), with one dose containing 40 g of glucose. Repeat the dose every 10 min until symptoms disappear; if not effective, give 1 mg glucagon intramuscularly or 50 ml of 50% dextrose intravenously over 2–3 minutes (10).

Acute respiratory insufficiency resulting from obstruction of the airways

Upper and lower airways can be obstructed, and depending upon where the cause of the obstruction occurs, different symptoms will appear. Symptoms: obstruction of the upper airways is clinically manifested by coughing, cyanosis and inspirational stridor, while in the lower respiratory tract obstruction, cough is present along with shortness of breath, inspiratory - expiratory wheezing, shortness of breath and cyanosis. If obstruction persists it can cause loss of consciousness.



Slika 1. Maska za disanje

Figure 1 Breathing mask

Slika 2. Orofaringealni tubusi po Guedelu, veličine označene bojama, vidi Tablicu 2

Figure 2 Oropharyngeal Guedel tubes, sizes marked by colors, see Table 2

Slika 3. Položaj orofaringealnog tubusa

Figure 3 Location of oropharyngeal tube

Slika 4. Širenje retrosternalne boli

Figure 4 Spreading of retrosternal pain

Slika 5. Otvaranje dišnih puteva naginjanjem glave i podizanjem brade

Figure 5 Opening of airways by tilting the head and lifting the chin

Slika 6. Vanjska masaža srca kod malog djeteta

Figure 6 Chest compressions in a young child

Slika 7. Vanjska masaža srca kod većeg djeteta

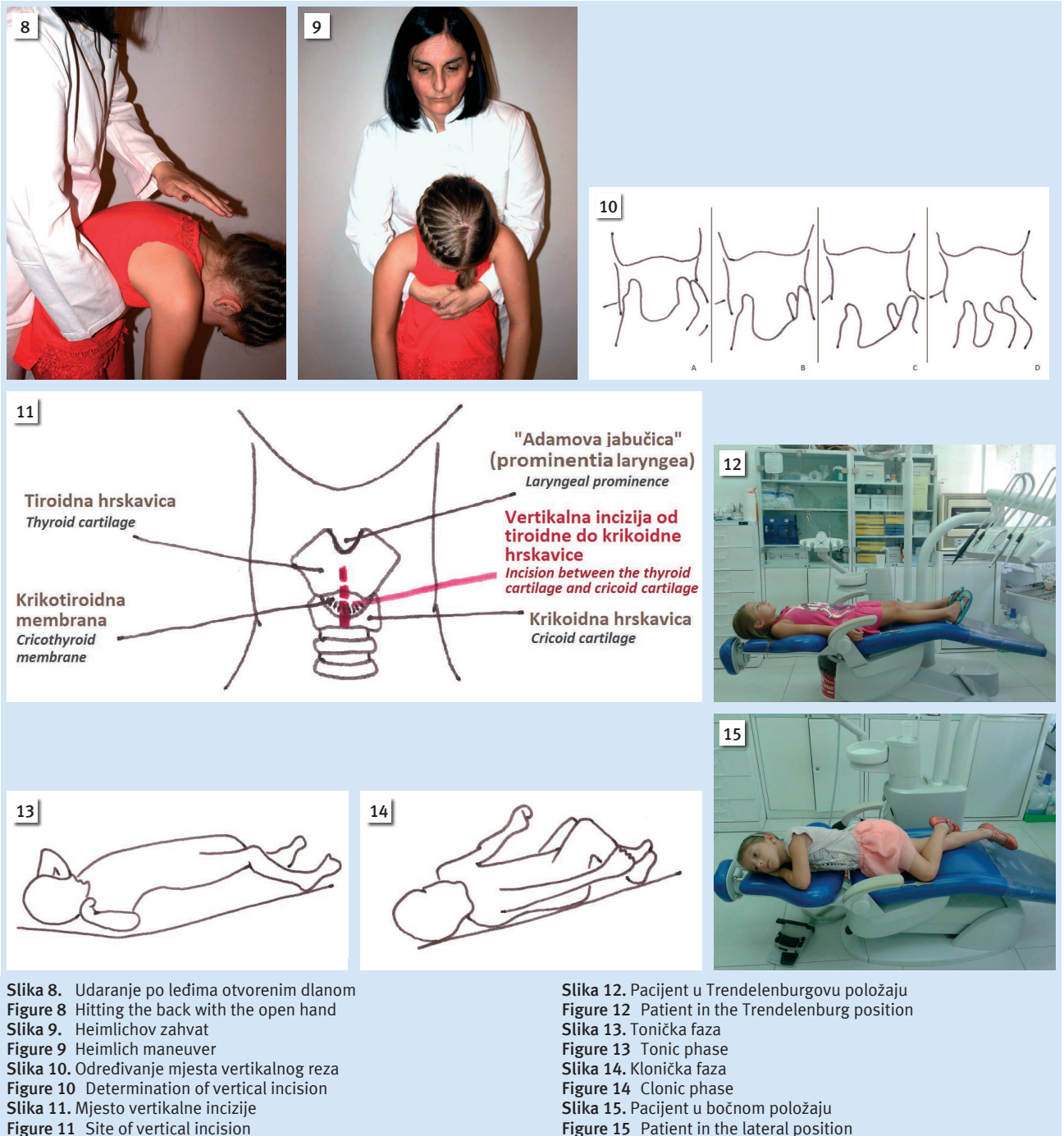
Figure 7 Chest compressions in an older child

Terapija: ako dijete kašlje, treba ga potaknuti jer je spontani kašalj učinkovitiji u terapiji opstrukcije od bilo kojega drugog vanjskog postupka.

Intervenira se kad kašalj postane neučinkovit, a to znači kad dijete između kašlja ne može govoriti, plakati ili udahnuti: najprije se primjenjuje pet udaraca otvorenim dlanom po leđima (slika 8.); ako se opstrukcija ne riješi, pet puta se primjenjuje Heimlichov zahvat (slika 9.).

Heimlichov zahvat obavlja se tako da terapeut stane iza djeteta i obuhvati ga rukama, jednu šaku stavi na njegov trbuh iznad pupka, a ispod ksifoida, a dlanom druge ruke obuhvati šaku prve ruke te tada obje snažno pritisne prema trbuhu i gore. Ako dijete izgubi svijest i ne diše potrebno ga je ventilirati, a ako nema znakova cirkulacije potrebna je i vanjska masaža srca (4); ako se objekt opstrukcije ne izbaci tijekom navedenih terapijskih postupaka, potrebna je krikotireotomija (11).

Treatment: If the child is coughing, encourage the child to do so, because a spontaneous cough is more effective in the treatment of obstruction than any other external process. Interventions are needed when coughing becomes ineffective, so when the child cannot talk, cry or breathe between coughs, do the following: first proceed with 5 strokes on the back with an open palm (Figure 8); if the obstruction is not resolved, apply the Heimlich maneuver (Figure 9) five times (the Heimlich maneuver is performed with the rescuer standing behind the victim and clasping his hands; one hand is made into a fist and placed on the child's abdomen above the navel while the palm of the other hand holds the fist as they strongly press against the child's belly and move upwards); if the child becomes unconscious and is not breathing, the child needs to be ventilated. If there are no signs of circulation, then chest compression is required (4). If the object causing the obstruction is not ejected with the above treatment procedures, it is necessary to perform a tracheotomy (11).



Slika 8. Udaranje po leđima otvorenim dlanom

Figure 8 Hitting the back with the open hand

Slika 9. Heimlichov zahvat

Figure 9 Heimlich maneuver

Slika 10. Određivanje mjesta vertikalnog reza

Figure 10 Determination of vertical incision

Slika 11. Mjesto vertikalne incizije

Figure 11 Site of vertical incision

Slika 12. Pacijent u Trendelenburgovu položaju

Figure 12 Patient in the Trendelenburg position

Slika 13. Tonička faza

Figure 13 Tonic phase

Slika 14. Klonička faza

Figure 14 Clonic phase

Slika 15. Pacijent u bočnom položaju

Figure 15 Patient in the lateral position

Postupak krikotireotomije:

1. Odrediti mjesto vertikalnog reza (slika 10.)
 - a. palcem i kažiprstom obuhvatiti podjezičnu kost
 - b. spustiti palac i srednji prst niže i opipati tiroidnu hrskavicu
 - c. spustiti prste još niže i opipati krikoidnu hrskavicu
 - d. položiti kažiprst na krikotiroidnu membranu koja se nalazi točno na sredini, između palca i srednjeg prsta.
2. Napraviti vertikalnu inciziju od tiroidne do krikoidne hrskavice (slika 10. i 11.);
3. Unutar reza palpirati krikotiroidnu membranu nedominantnim prstom;

Tracheotomy procedure:

1. Determine the location of the section (Figure 10)
 - A. With a thumb and forefinger, locate the hyoid bone
 - B. Move the thumb and middle finger down to feel the thyroid cartilage
 - C. Place the fingers even lower and locate the cricoid cartilage
 - D. Pass the index finger over the cricothyroid membrane, which is located exactly in the middle, between the thumb and middle finger
2. Make a vertical incision in the thyroid cartilage to the cricoid (Figures 10 and 11)

4. Učiniti vodoravni rez kroz membranu. Okrenuti oštricu (proširiti rez).

Akutni astmatski napadaj

Astma je kronična upalna bolest cijeloga respiratornog sustava kod osoba s alergijskom dijatezom.

Simptomi: dispneja, stezanje u prsima, čujno zviždanje ili sipljivo disanje, u fizikalnom statusu najvažniji nalaz je produljeni i otežani ekspirij, s mnogo ekspiratornih zvižduka (12).

Terapija: hitno liječenje počinje primjenom inhalacije β -agonista (salbutamol) koji će biti dovoljan ako je u pitanju blagi napadaj; u slučaju teškoga akutnog napadaja indicirana je primjena adrenalina intramuskularno ili subkutano, i to 0,01 mL/kg otopine 1:1000, najviše 0,3 mL, daje se (13, 14).

Sinkopa

Sinkopa je kratkotrajni reverzibilni gubitak svijesti i posturalnog tonusa koji nastaje u slučaju nagloga, prolaznoga i difuznog poremećaja moždane funkcije zbog naglog smanjenja dotoka krvi u mozak.

Simptomi: zbunjenost, hladni znoj, bljedilo, pacijent obično kaže da mu nije dobro, poslije se pojavljuje pupilarna dilatacija, pojačana respiracija, dezorijentacija i gubitak svijesti, s gubitkom svijesti disanje postaje nepravilno i plitko, a može i izostati pa se pojavljuje bradikardija, tlak pada, a bilo je slabo (15).

Terapija: postavite pacijenta u Trendelenburgov položaj (slika 12.), sinkopa traje kratko – od nekoliko sekundi do nekoliko minuta; pacijentu pri svijesti može se dati slatki napitak da se spriječi hipoglikemija; pacijentu bez svijesti dati od 36 do 50 % otopine glukoze intravenski ili glukagona intramuskularno; ako osoblje nije osposobljeno za injiciranje lijekova ili ih nema, može se u bukalnu brazdu utrljati med ili zaslađeni napitak, no oprezno da ne bi došlo do aspiracije (16).

Epileptički napadaj (grand mal)

Napadaju može prethoditi aura (preiktalna faza) koja se očituje kao promjena u jednom od osjetila, a uglavnom se kod određenog pacijenta pojavljuje na isti način prije svake epizode i traje nekoliko sekundi. Sljedeća faza naziva se ictalnom i tu se pojavljuje gubitak svijesti, zatim toničke kontrakcije miškulature koje traju od 10 do 20 sekundi (slika 13.). Zatim slijedi klonička faza za koju je svojstveno grčenje cjelokupne miškulature (slika 14.). Može se pojaviti i pjena na ustima zbog miješanja zraka i sline, a pacijent se može tijekom kloničkih kontrakcija ugristi i ozlijediti meka tkiva intraoralno pa može i krvariti. Ova faza traje dvije do pet minuta. U postiktalnoj fazi disanje postaje normalno i postupno se vraća svijest. Zbog relaksacije sfinktera može se dogoditi urinarna ili fekalna inkontinencija (17).

Terapija: odmaknuti od pacijenta sve instrumente i izvaditi sve što mu je u tom trenutku u ustima; spustiti stolac što

3. In this section, feel the cricothyroid membrane with the finger
4. Make a horizontal incision through the membrane and turn the blade to expand the cut.

Acute asthma attack

Asthma is a chronic inflammatory disease of the entire respiratory system in patients with allergic diseases. Symptoms: dyspnea, chest tightness, audible wheezing or problematic breathing. For physical status, the most significant findings are extended and difficult-expiration, with a marked expiratory whistle (12). Treatment: immediate treatment begins with the inhalation of beta-agonists (salbutamol), which will be sufficient if the problem is a mild attack; in severe attacks, administration of epinephrine is indicated at a dose of 0.01 to 0.03 ml/kg of a 1:1000 solution, administered intramuscularly or subcutaneously (13,14).

Syncope

Syncope is a short-term reversible loss of consciousness and postural tonus, which results from a sudden, transient and diffuse disorder of brain function resulting from a sharp reduction in the delivery of blood to the brain.

Symptoms: the patient shows signs of confusion, has cold sweat, turns pale and usually says that he or she is not well. Later, pupillary dilation appears, along with increased respiration, disorientation and loss of consciousness; breathing becomes irregular, shallow and may be absent; bradycardia occurs; the blood pressure drops and the pulse is weak (15).

Therapy: if the patient is placed in the Trendelenburg position (Figure 12), the duration of syncope is short and lasts from a few seconds to a few minutes; the patient is conscious and can be given a sweet drink to prevent hypoglycemia. In patients who are unconscious, it is indicated to give 36–50% glucose solution intravenously or intramuscular glucagon; if the staff are not trained to inject drugs or there are not any medications available, it is possible to rub honey or a sweet drink in the buccal fold taking care to avoid aspiration (16).

Epileptic seizure (grand mal)

The attack may be preceded by aura (postictal phase), which is manifested as a change in one of the senses. Aura mainly occurs in the same way in a given patient before each attack and lasts a few seconds. The next phase is termed the ictal phase, which leads to loss of consciousness, followed by tonic contraction of muscles, which takes 10 to 20 sec (Figure 13). Then, the clonic phase occurs, which is characterized by contraction of the whole musculature (Figure 14). Foaming at the mouth can occur because of mixing of air and saliva, the patient may bite themselves during the clonic contractions and injure soft tissue intraorally, and blood may be visible; this phase lasts for 2–5 min. In the last stage, breathing becomes normal and the patient gradually returns to consciousness. Urinary or fecal incontinence may occur because of relaxation of the sphincter (17). Treatment: move all of the instruments away from the patient and remove everything from the mouth that is there at

niže; pacijenta položiti na bok kako bi se smanjila mogućnost aspiracije sekreta ili dentalnih materijala u ustima (slika 15.); pacijenta nemojte obuzdavati ili stavljati mu prste u usta i obvezno mjerite trajanje napadaja; ako je napadaj dulji od tri minute, pozovite hitnu pomoć; ako napadaj traje dulje od pet minuta ili su napadaji učestali, injicirajte 0,25 mg/kg diazepam IV.

Nemojte dopustiti pacijentu da napusti ordinaciju dok ne bude potpuno pri svijesti; pregledajte usnu šupljinu kako biste ustanovili ima li novonastalih ozljeda te pacijenta otpustite kući obvezno u pratnji roditelja (18).

Toksične reakcije

Lokalni anestetici najčešći su uzrok toksičnih reakcija (19). Uglavnom nastaju zbog prebrze apsorpcije lijeka u krvotok, prevelike doze i intravaskularne injekcije (20, 21). Simptomi: zbunjenost, nerazgovijetan govor, podrhtavanje lica i ekstremiteta, povišen krvni tlak, visok broj otkucaja i frekvencija disanja, vrtoglavica, nistagmus, glavobolja, zujanje u ušima, dezorijentiranost, gubitak svijesti, toničko-klonički grčevi; prva faza je ekscitacijska, a poslije se pojavljuje depresija živčanog sustava i smanjuju se krvni tlak, broj otkucaja i frekvencija disanja (22, 23).

Terapija: pacijenta postaviti u ležeći položaj; provjeriti cirkulaciju, disanje i protok zraka; ako pacijent ima toničko-kloničke grčeve, potrebno je osigurati dotok kisika – tada klonička faza traje kraće od jedne minute; ako nije osiguran dotok kisika, pacijent ulazi u acidozu zbog zadržavanja CO₂; obvezno je osigurati dišni put i normalno disanje; ako bilo koja faza traje dulje od dvije minute i pacijent ne diše, pozvati hitnu pomoć (24, 25).

Anafilaktična reakcija

Nastaje zbog reakcije antigen – antitijelo, a za razvoj akutne anafilaktične reakcije potrebna je antigenska stimulacija imunskog sustava formacijama IgE antitijela, latentno razdoblje nakon ekspozicije tijekom kojega se antigeni senzibiliziraju mastociti i bazofili i ponovna reeksponiranost. Kada mastociti tijekom reekspozicije reagiraju s antigenom, počinju se otpuštati histamini i vazoaktivni amini. Reakcija može nastati za nekoliko sekundi, ali i za nekoliko sati ili, ako je riječ o zakašnjoj reakciji, između nekoliko sati do nekoliko dana nakon ekspozicije alergena.

Simptomi: respiratorni (kašljanje, stezanje u prsima, dispneja i zvuk zviždanja, laringealni edem, bronhospazam); kardiovaskularni (glavobolja, palpitacije, sinkopa, tahikardija, disritmija, ortostatska hipotenzija i šok); gastrointestinalni (grčevi, abdominalna bol, mučnina, povraćanje i proljev); kožni i mukozni znakovi (urtike, eritem i svrbež, angioedem se obično pojavljuje periorbitalno, perioralno, intraoralno i na ekstremitetima) (26, 27).

Terapija: adrenalin (ampule adrenalina pakiraju se u omjeru 1:1000 i u količini od 1 mL, doza za djecu je 0,01 mL/kg tjelesne težine, znači ako dijete ima 20 kg, doza adre-

the moment; lower the seat as close to the floor as possible; the patient should lie on their side to reduce the possibility of aspiration of secretions or dental materials in the mouth (Figure 15); do not restrain the patient or put your fingers into the patient's mouth; measure the duration of the seizure; if the seizure lasts more than 3 minutes, call an ambulance; if a seizure lasts longer than 5 minutes or frequent seizures occur, administer 0.25 mg/kg of diazepam IV; do not allow the patient to leave the clinic until the level of consciousness is fully restored; perform a brief examination of the oral cavity to establish the existence of new injuries; the patient is required to go home accompanied by his or her parents (18).

Toxic reactions

The most common cause of toxic reactions is local anesthetics (19). Toxic reactions occur because of rapid absorption of the drug into the blood stream, overdosing and intravascular injection (20, 21). Symptoms: confusion, slurred speech, tremors of the face and limbs, high blood pressure, rapid heartbeat and breathing, dizziness, nystagmus, headache, tinnitus, disorientation, loss of consciousness, tonic-clonic seizures. Following the first phase of excitation, the patient subsequently passes through a depression of the nervous system and experiences a reduction in blood pressure, heart rate and respiratory rate (22).

Treatment: place the patient in a supine position, check circulation, breathing and air flow; if the patient exhibits tonic-clonic convulsions, it is necessary to ensure the supply of oxygen; then the clonic phase lasts less than one minute. If the supply of oxygen is not secured, the patient enters acidosis because of CO₂ retention; be sure to secure the airway and allow for normal breathing; if any phase lasts longer than two minutes and the patient is not breathing, call an ambulance (24, 25).

Anaphylactic reaction

Anaphylactic reactions occur because of antigen - antibody interaction. For the development of acute anaphylactic reactions, antigen is required to stimulate the immune system and form IgE antibodies. Then, a latent period occurs after exposure to the antigen, during which the mast cells and basophils are sensitized and exposure to the antigen takes place. When the mast cells react with antigen during re-exposure, a release of histamine and vasoactive amines occurs. Such a reaction can develop between a few seconds and several hours (or if it is a delayed reaction, at a few hours to several days) after exposure to an allergen.

Symptoms: respiratory (coughing, chest tightness, dyspnea and whistling sound, laryngeal edema, bronchospasm); cardiovascular (headaches, palpitations, syncope, tachycardia, dysrhythmia, orthostatic hypotension and shock); gastrointestinal (cramps, abdominal pain, nausea, vomiting and diarrhea); cutaneous and mucosal signs (rash, erythema and pruritus, angioedema usually occurs at periorbital, perioral and intraoral sites and on the extremities) (26, 27).

Therapy: Adrenaline (epinephrine vials are diluted at a ratio of 1:1000 in an amount of 1 mL; the dose for chil-

nalina je 0,2 mL – doza se može ponavljati svakih 5 do 10 minuta, intravenski se adrenalin daje u razrjeđenju 1:10.000, tako da se u 1 mL tvorničkog pripravka doda 9 mL fiziološke otopine, doza za djecu tada iznosi 0,1 mL/kg; antihistaminici (idealni antihistaminik trebao bi se primjenjivati parenteralno i djelovati brzo, a u praksi se tako primjenjuju difenhidramin ili klorfeniramin; u Hrvatskoj je registriran samo peroralni oblik difenhidramina, a od parenteralnih pripravaka jedino kloropiramin (*Synopen*) koji nije predviđen za djecu, iako se prema preporuci proizvođača polagano intravenski može dati pola ampule); inhalacija β_2 agonista (upotrebljava se kada uz anafilaksiju postoji i bronhospazam, treba biti oprezan u slučaju hipotenzije jer β_2 agonisti djeluju vazodilatacijski, djeci do pet godina daje se u dozi od 2,5 mg, a starijoj od pet godina 5 mg; oksigenacija (kisik je prijeko potreban u slučaju respiracijskih simptoma ili hipotenzije); kortikosteroidi (kortikosteroidi nisu lijekovi prvog izbora, oni su efikasni u redukciji kasne faze alergijskog odgovora; može se dati metilprednizolon u dozi od 1 do 2 mg/kg intravenski ili hidrokortizon u dozi od 4 mg/kg intravenski) (28, 29).

Zaključak

Većina pravilnika za reagiranje u hitnim situacijama odnosi se na odraslu populaciju. Rad s djecom dodatno je otežan zbog njihove dobi i razlike u fiziološkom i psihološkom smislu. Svaki doktor dentalne medicine trebao bi znati terapijske doze i postupke prilagođene dječjoj dobi kako bi se komplikacije izbjegle ili svele na minimum. Preporučuje se u ordinaciji imati napisane terapijske postupke u slučaju hitnih stanja i antišok-terapiju, nabaviti defibrilator te kontrolirati rok valjanosti lijekova (30).

Izjava

Autori opovrgavaju bilo kakav sukob interesa.

Priznanje

Svi crteži su autorstvo dr. Jesenke Jeličić.

dren is 0.01 ml/kg body weight, so a 20 kg child has an epinephrine dose of 0.2 ml; the dose can be repeated every 5–10 min; intravenous epinephrine is administered at a dilution of 1:10,000, so 9 mL of saline is added to 1 ml of the factory dilution, and the dose for children is 0.1 ml/kg; antihistamines (ideally, an antihistamine should be administered parenterally and quickly; in practice, the parenterally administered compound is diphenhydramine or chlorpheniramine; Croatia has registered only an oral form of diphenhydramine; regarding parenteral formulations, only chloropyramine (*Synopen*) has been registered, which is not suitable for children, although the manufacturer can provide half ampoules to be administered slowly and intravenously; inhalation of β_2 -agonists (used when there is anaphylaxis and bronchospasm, and should be administered carefully in cases of hypotension because β_2 agonists have a vasodilatory effect; given at a dose of 2.5 mg for children up to 5 years, and at 5 mg for children over 5 years of age); oxygenation (oxygen is essential in cases with respiratory symptoms or hypotension); corticosteroids (corticosteroids are not the drug of first choice, but they are effective in reducing the late-phase allergic response). Notably, corticosteroids may be administered, with a dose of 1–2 mg/kg methylprednisolone or 4 mg/kg hydrocortisone administered intravenously (28, 29).

Conclusion

Most of the regulations and guidelines for emergency responses refer to the adult population. Working with children is more difficult because of their young age and differences in the physiological and psychological senses. Every dentist should know the therapeutic dose and procedures adapted to children to avoid complications or reduce them to a minimum and should also have a defibrillator (30).

Transparency declaration

The authors deny any conflict of interest.

Acknowledgment

All drawings are originally made by Dr. Jesenka Jeličić.

Abstract

Medical emergencies that are life threatening can occur in dental practice. Complications may arise because of an underlying disease or a reaction to medication. Reactions to medications may be allergic and toxic. The most common reactions are toxic reactions to local anesthetics, whereas allergies occur mainly as a consequence of the application of antibiotics, usually penicillin. In response to stress, vasovagal syncope typically occurs. Other causes may be related to an underlying disease-specific pathology (such as acute asthma attack, diabetic ketoacidosis, hypoglycemia, or seizures) or accidents (aspiration of a foreign body causing obstruction of the respiratory system). For all the above conditions, guidelines have been established that need to be known. If complications occur or necessary measures are not taken, it can lead to cardiac and respiratory arrest. Therefore, cardiopulmonary resuscitation is needed. All procedures and dosages should be adapted to the age of the child.

Received: February 1, 2016

Accepted: March 5, 2016

Address for correspondence

Dubravka Negovetić Vranić
University of Zagreb
School of Dental Medicine
Department of Paediatric and
Preventive Dentistry
Gundulićeva 5
HR-10000 Zagreb, Croatia
Tel.: +385 1 4802-110
dnegovetic@sfg.hr

Key words

Dental Care for Children; Emergency Treatment; First Aid; Masks; Resuscitation

References

- Goepferd SJ. Medical emergencies in the pediatric dental patient. *Pediatr Dent*. 1979 Jun;1(2):115–21.
- Degoricija V. *Hitna medicina*. Zagreb: Libar; 2011.
- Malamed SF. *Medical emergencies in the dental office*. 7th ed. St. Louis: Mosby; 2015.
- Meštrović J. *Hitna stanja u pedijatriji*. 2. hrv. izd. Zagreb: Medicinska naklada; 2012.
- Zideman D, Bingham R, Beattie T, et al. Guidelines for paediatric life support: a statement by the paediatric life support working party of the European Resuscitation Council. *Resuscitation* 1994;27:91–105 (1993).
- Biarent D, Bingham R, Eich C, et al. European Resuscitation Council guide-lines for resuscitation 2010 section 6 paediatric life support. *Resuscitation* 2010;81:1364–88.
- Malamed SF. Emergency medicine in pediatric dentistry: preparation and management. *J Calif Dent Assoc*. 2003 Oct;31(10):749–55.
- Malamed SF. Allergic and toxic reactions to local anesthetics. *Dent Today*. 2003;22:114–21.
- Longstreth Jr WT, Copass MK, Dennis LK, Rauch-Matthews ME, Stark MS, Cobb LA. Intravenous glucose after out-of-hospital cardiopulmonary arrest: a community-based randomized trial. *Neurology* 1993;43:2534–41.
- Srinivasan V, Spinella PC, Drott HR, Roth CL, Helfaer MA, Nadkarni V. Association of timing, duration, and intensity of hyperglycemia with intensive care unit mortality in critically ill children. *Pediatr Crit Care Med* 2004;5:329.
- Waage NS, Baker S, Sedano HO. Pediatric conditions associated with compromised airway: part I--congenital. *Pediatr Dent*. 2009 May-Jun;31(3):236–48.
- DeCaen A, et al. Part 6: Pediatric advanced life support: 2015 international consensus on cardiopulmonary resuscitation and emergency cardiovascular care science with treatment recommendations. *Circulation* (In press).
- Becker DE. Management of respiratory complications in clinical dental practice. Pathophysiological and technical considerations. *Anesth Prog*. 1990 Jul;37(4):169–75.
- Rosenberg M. Preparing for medical emergencies: the essential drugs and equipment for the dental office. *J Am Dent Assoc*. 2010 May; 141 Suppl 1:14S–9S.
- Randhawa S, Roberts-Turner R, Woronick K, DuVal J. Implementing and sustaining evidence-based nursing practice to reduce pediatric cardiopulmonary arrest. *West J Nurs Res* 2011;33:443–56.
- Gold DL, Mihalov LK, Cohen DM. Evaluating the Pediatric Early Warning Score (PEWS) system for admitted patients in the pediatric emergency department. *Acad Emerg Med* 2014;21:1249–56 (official journal of the Society for Academic Emergency Medicine).
- Petranker S, Nikoyan L, Ogle OE. Preoperative evaluation of the surgical patient. *Dent Clin North Am*. 2012 Jan; 56(1):163–81.
- Chung WL. Anesthesia equipment for the oral and maxillofacial surgery practice. *Oral Maxillofac Surg Clin North Am*. 2013 Aug; 25(3):373–83.
- Herlich A. Anesthetic emergencies in oral surgery: malignant hyperthermia, endocrinopathy, and neurologic events. *Oral Maxillofac Surg Clin North Am*. 2013 Aug;25(3):507–14.
- Agarwal R, Porter MH, Obeid G. Common medical illnesses that affect anesthesia and their anesthetic management. *Oral Maxillofac Surg Clin North Am*. 2013 Aug;25(3):407–38.
- Krost WS. Pediatric pulmonary emergencies. *Emerg Med Serv*. 2004 Jan;33(1):71–7.
- Todd DW. Pediatric sedation and anesthesia for the oral surgeon. *Oral Maxillofac Surg Clin North Am*. 2013 Aug;25(3):467–78.
- Campbell RL, Bellolio MF, Knutson BD, et al. Epinephrine in anaphylaxis: higher risk of cardiovascular complications and overdose after administration of intra-venous bolus epinephrine compared with intramuscular epinephrine. *J Allergy Clin Immunol Pract* 2015;3:76–80.
- Del Pizzo J, Callahan JM. Intranasal medications in pediatric emergency medicine. *Pediatr Emerg Care* 2014;30:496–501 (quiz 2–4).
- Petranker S, Nikoyan L, Ogle OE. Preoperative evaluation of the surgical patient. *Dent Clin North Am*. 2012 Jan;56(1):163–81.
- Rosenberg MB. Medical emergencies in the pediatric patient: airway management. *J Mass Dent Soc*. 2004 Winter;52(4):46–8.
- Rotta AT, Wiryawan B. Respiratory emergencies in children. *Respir Care*. 2003 Mar;48(3):248–58.
- Choi J, Lee GL. Common pediatric respiratory emergencies. *Emerg Med Clin North Am*. 2012 May;30(2):529–63.
- Jones P, Dager S, Denjoy I, et al. The effect of atropine on rhythm and conduction disturbances during 322 critical care intubations. *Pediatr Crit Care Med* 2013;14:e289–97 (a journal of the Society of Critical Care Medicine and the World Federation of Pediatric Intensive and Critical Care Societies).
- Rossano JQ, Schiff L, Kenney MA, et al. Survival is not correlated with defibrillation dosing in pediatric out-of-hospital ventricular fibrillation. *Circulation* 2003;108:320–1.