

## THE EFFECT OF AMIODARONE ON THE CORNEA

Mia Zorić-Geber, Boris Starčević,\* Ivanka Petric, Renata Iveković, Zdravko Mandić

University Departments of Ophthalmology and Cardiology,\* Sestre milosrdnice University Hospital, Zagreb, Croatia

**SUMMARY** – The most common side-effect of the anti-arrhythmic amiodarone is keratopathy. The goal of this study was to assess the frequency of this side-effect in our population of cardiology patients treated with amiodarone. We also wanted to assess the consequences on eye sight. The study was conducted as a collaboration between the divisions of ophthalmology and cardiology of Sestre milosrdnice University Hospital, Zagreb and it included patients receiving amiodarone for longer than 6 months (100-800 mg/day). Changes on the cornea were objectively evaluated using a biomicroscope and have been classified into three stages. Clinical changes on the cornea have been observed in 92% of the patients. Changes in eye sight were not observed. Amiodarone keratopathy is related to dosage and duration of treatment. This keratopathy progresses even with reduced dosage; however, complete regression occurs once administration of medication is discontinued.

Taking this study into account, as well as the available published data, we are of the opinion that amiodarone therapy should not be discontinued due to changes in the eye-sight and if the amiodarone therapy is of critical importance to the welfare of the patient.

**Key words:** amiodaron keratopathy, corneal microdeposits

### Introduction

Amiodarone was developed in the 1960s for the treatment of angina pectoris. It proved to be effective for recurrent ventricular tachycardia or fibrillation resistant to other drugs. It is also used to maintain sinus rhythm in patients with atrial fibrillation. As the usage of the drug has become more common, various side-effects have emerged.<sup>1-3</sup>

The ocular changes caused by amiodarone were first described in 1967.<sup>4</sup> Using electron microscopy, lysosome-like intracytoplasmic membranous lamellar bodies were found in extraocular muscle fibers, corneal epithelial, stromal, and endothelial cells, conjunctival epithelium, scleral cells, lens epithelium, iris, ciliary body, choroid, retina, large diameter axons of the optic nerve and the endothelium of all ocular blood vessels.<sup>5</sup> Moreover, it has been

shown that the lamellar bodies found in the epithelial basal cells of the cornea contain large quantities of iodine. This fits in very well with the fact that there are two iodine atoms in each molecule of amiodarone.<sup>6,7</sup> Some investigators believed that these inclusions represent lipofuscin, although others believe that they represent a drug lipid complex that cannot be metabolized by lysosomal phospholipases.<sup>8</sup>

The most common findings were in the cornea. Amiodarone corneal opacities usually appear simultaneously in both eyes. They are invisible to the naked eye but can be seen by slit-lamp biomicroscopy.

### Patients and methods

The goal of this study was to assess the frequency of this side-effect in population of cardiology patients treated with amiodarone as well as the consequence on eye sight.

Patients were eligible for participation in the clinical investigation of amiodarone if they had a severe ventricular arrhythmia uncontrollable by any other therapeutic regimen.

Correspondence to: *Mia Zorić-Geber, MD*, University Department of Ophthalmology, Sestre milosrdnice University Hospital, Vinogradska cesta 29, 10000 Zagreb, Croatia

The study was conducted as a collaboration between the divisions of ophthalmology and cardiology of Sestre milosrdnice University Hospital, Zagreb.

Thirty six patients without any eye-related pathology were included in the study. Twenty-five of the patients in the series were male and eleven were female; ages ranged from 58 + 5.2 years. The average length of follow-up was 9.3 + 2.1 months. Eleven patients were reexamined at six month intervals, five patients had their dose reduced and six patients discontinued the therapy during this study. The dosage of medication varied from 100 – 800 mg per day. The patients received amiodarone for a period longer than 6 months.

Changes on the cornea were objectively evaluated using a slit-lamp biomicroscopy as well as photo slit – lamp photography. Other tests included visual acuity, applanation tonometry and detailed fundoscopic exam.

The corneal changes which had been recorded were classified after Miller (1969) into three stages.

**Results**

Using the biomicroscope, we found signs of keratopathy in thirty three patients (fig. 1). Other parameters were not significantly different.

These microdeposits have a golden – brown color and are biomicroscopically present at the level of the epithelium just anterior Bowman's membrane. Characteristically, keratopathy begins in the area of the lower pupillary margin as an amorphous collection of the deposits which become linear in configuration with time and finally advice to a whorl of vortex-like patterns.

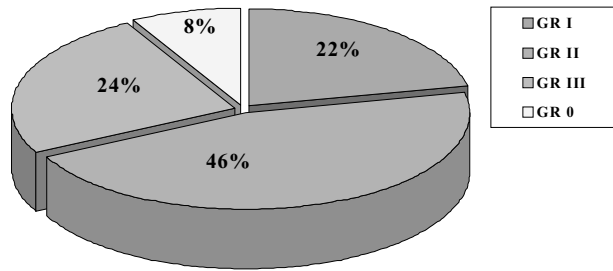


Fig. 2

The results were grouped according to the degree of keratopathy (fig. 2).

Seven patients were taking low doses of amiodarone for shorter periods of time tended to have the 1st degree of keratopathy. One exception was a patient using a low dose for an extended period of time.

The second degree was noted in seventeen patients taking low doses for extended periods of time or intermediate doses for brief periods of time.

However, the 3rd degree was noted in nine patients taking either very high doses or for an extended period of time. Only three patients had no changes even though one of them has been taking amiodarone for 96 months.

During the course of the study, 5 patients had their dose reduced. However, after six-months of follow-up, the level of keratopathy remained the same. At the same time, 6 patients discontinued the therapy. On six-month follow-up, five of the patients had no signs of keratopathy remaining and one of the patients had it reduced from 3rd degree to 1st degree.

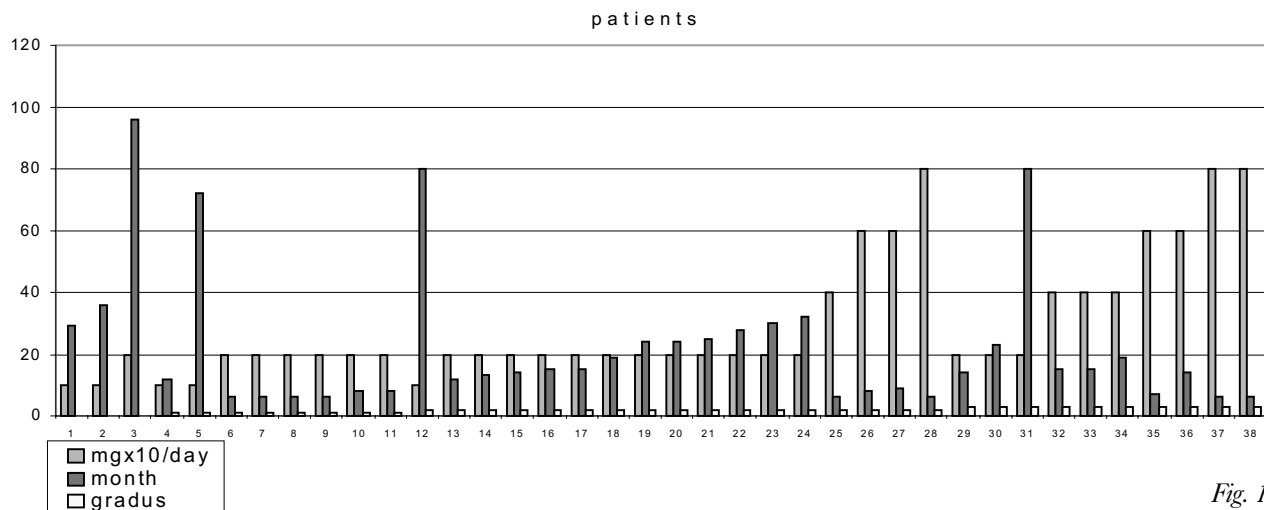


Fig. 1

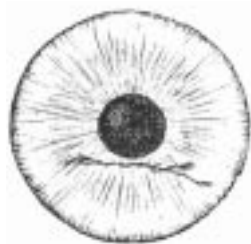


Fig. 3



Fig. 4

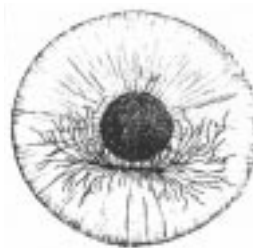


Fig. 5

## Discussion

Keratopathy is common in patients taking amiodarone. On the basis of published series, 76% to 100% of patients who received doses of 200 to 800 mg/day had corneal involvement. These opacities do not cause visual loss.<sup>7,9,10</sup>

Amiodarone keratopathy is comparable clinically and morphologically with the corneal alterations seen in Fabry's disease and in chloroquine use as an example of a drug-induced lipid storage disorder. This clinical similarity was first noted by Francois, who grouped these three entities under the descriptive term "cornea verticillata".<sup>11</sup> Interestingly, the keratopathy associated with chloroquine has no relationship to dosage or duration of treatment, yet the retinopathy is closely related to total dosage.<sup>12</sup> Unlike chloroquine keratopathy, the keratopathy associated with amiodarone is related to dosage and duration of treatment. It has also been found that no retinopathy is associated with amiodarone.<sup>13,14</sup>

In 1969, Miller<sup>13</sup> classified the amiodarone keratopathy into three stages: stage 1 is characterized by the coalescence of fine, punctate, grayish golden-brown opacities into a horizontal linear pattern in the inferior cornea (fig. 3); stage 2 is characterized by additional arborizing and horizontal lines (fig. 4); stage 3 is characterized by a verticillate, whorl-like pattern, and these arborizing lines may extend into the visual axis (fig. 5). Histopathologic studies have shown these opacities to be located in the epithelial basal cell layer.

## Conclusion

Even though the frequency of keratopathy accompanying therapy with amiodarone was significant, it did not have any effect on the patients' eye sight. The degree of keratopathy correlated with the daily dose and length of therapy. Reducing the dose did not lead to regression of the keratopathy; however, a complete regression was observed following discontinuation of therapy.

Taking this study into account, as well as the available published data, we are of the opinion that amiodarone therapy should not be discontinued due to changes of the cornea, unless there are changes in the eye-sight. Additionally, the critical importance of amiodarone for the welfare of the patient should be taken into consideration. Amiodarone is a safe drug but patients must be examined at regular intervals.

## References

- ROSENBAUM MB, CHIALE PA, HALPERN MS, ET AL. Clinical efficacy of amiodarone as an antiarrhythmic agent. *Am J Cardiol* 1976; 38:934-944.
- COTE P, BOURASSA MG, DELAYE J, ET AL. Effects of amiodarone on cardiac and coronary hemodynamics and on myocardial metabolism in patients with coronary artery disease. *Circulation* 1979; 59:1165-1172.
- ZAKHAROV VN, KUZNETSOV KK. Study of effectiveness of cordarone in different types of arrhythmia. *Kardiologija* 1977; 17:90-93.
- INGRAM DV, JAGGARAO NSV, CHAMBERLAIN DA. Ocular changes resulting from therapy with amiodarone. *Br J Ophthalmol* 1982; 66:676-679.
- BOCKHARDT H, DRENCKHAHN D, LÜLLMANN-RAUCH R. Amiodarone - induced - lipidosis - like alterations in ocular tissues of rats. *Albrecht Von Graefes Arch Klin Exp Ophthalmol* 1978; 207:91.
- HAUG SJ, FRIEDMAN AH. Identification of amiodarone in corneal deposits. *Am J Ophthalmol* 1991; 111: 518-519.
- D'AMICO DJ, KENYON KR, RUSKIN JN. Amiodarone keratopathy: Drug-induced lipid storage disease. *Arch Ophthalmol* 1981; 99:257-261
- HIRST LW, SANBORN G, GREEN WR, ET AL. Amiodarone ocular changes. *Arch Ophthalmol* 1982; 100: 1300-1304.
- BABEL J, STANGOS N. Lésions oculaires iatrogènes; l'action d'un nouveau médicament contre l'angor pectoris. *Arch Ophthalmol* 1970; 30: 197-208.
- MAIJA MÄNTYJÄRVI, KAIJA TUPPURAINEN, KIRSI IKÄHEIMO. Ocular side-effects of amiodarone. *Surv Ophthalmol* 1998; 42: 360-366.

11. FRANCOIS J. Cornea verticillata. Bull Soc Belge Ophthalmol 1968; 150: 656-670.
12. BERNSTEIN HN. Chloroquine ocular toxicity. Surv Ophthalmol 1967; 12: 415-446.
13. MILLER HA. Keratopathie consecutive au traitement par cordarone. Bull Soc ophthalmol 1969; 69: 1059-1060.
14. BABEL J. STANGOS N. L'action de l'amiodarone sur les tissus oculaires. Schweiz med Wochenschr 1972; 102:220-222.

#### Sažetak

### UČINAK AMIODARONA NA ROŽNICU

*M. Zorić-Geber; B. Starčević,\* I. Petric, R. Iveković, Z. Mandić*

Kod primjene antiaritmika amiodarona najčešće registrirana nuspojava je keratopatija. Cilj ovog rada je ispitati koliko je ova nuspojava frekventna u populaciji naših kardioloških pacijenata na terapiji amiodaronom i od kakavog je značaja za kvalitetu vida. Ispitivanje je provedeno u suradnji klinike za oftalmologiju i kardiologiju KB "Sestre milosrdnice", Zagreb. Uključeni su pacijenti na terapiji amiodaronom duže od 6 mjeseci (100-800 mg/dan). Promjene na rožnici objektivno su registrirane biomikroskopom i svrstane u tri stupnja. One su registrirane kod 92% pacijenata. Promjene kvalitete vida nisu registrirane.

Amiodaronska keratopatija u korelaciji je s dnevnom dozom i duljinom trajanja terapije. Smanjenje dnevne doze ne dovodi do regresije keratopatije, dok je kompletna regresija zabilježena nakon prestanka primjene lijeka.

S obzirom na ovo istraživanje i podatke iz literature, mišljenja smo, da nije potrebno prekidati terapiju amiodaronom zbog promjena na rožnici ukoliko nema poremećaja vida i ako je terapija amiodaronom od vitalnog značenja za pacijenta.

Ključne riječi: *amiodaronska keratopatija, rožnična mikroulaganja*