

## LEBER'S HEREDITARY OPTIC NEUROPATHY – A CASE REPORT

Jelena Petrinović-Dorešić, Ljerka Henč-Petrinović, Biljana Kuzmanović

Department of Ophthalmology, General Hospital "Sveti Duh", Zagreb, Croatia

**SUMMARY** – LHON is characterised by bilateral asynchronous visual loss in young adults. This type of neuropathy is related to mitochondrial DNA mutation and therefore is maternally inherited. Males are predominantly affected but they do not transmit the disease to their offspring. Clinical picture - although characteristic - is not impressive. At the beginning of the disease, there is a large discrepancy between the symptoms and signs. In contrast to marked central visual loss, the only visible sign is retinal teleangiectatic microangiopathy in the peripapillary region. Fluorescein angiography shows intact capillary network without leakage disproving its inflammatory nature.

**Key words:** Hereditary optic atrophy, mitochondrial DNA mutation

### Case report

A boy of 17 experienced a sudden progressive loss of right eye central vision. Several weeks later the other eye was also affected. Family history was negative. At the time of the referral, two months after the onset of the disease, visual acuity was 0,1 in the right eye and 0,05 in the left, with bilateral central scotoma. Although the fundoscopic appearance suggested LHON, ancillary testing excluding other causes of optic neuritis (infectious, MS-related) were also performed. Retinal angiography revealed intact tortuous teleangiectatic papillary and peripapillary capillaries without any leakage. Retrobulbar part of optic nerve showed no abnormalities on echography. Pattern visual evoked potentials with bilaterally reduced P100 amplitude and prolonged latency confirmed retinocortical conduction defect. Due to strong clinical suspicion mitochondrial DNA analysis was done. The mutation at nucleotide 11778 was found confirming the diagnose. 14-month follow-up showed no visual improvement of the right eye, but the visual acuity of the left eye gradually recovered to 0,7. Genetic study of other family members is under way.

### Introduction

Leber's hereditary optic atrophy (LHON) was described as a clinical entity more than a century ago. Characteristic bilateral, but usually not simultaneous, acute or subacute loss of central vision accompanied by dyschromatopsia puzzled ophthalmologists until Wallace found the causative point mutation in the mitochondrial DNA (mtDNA).<sup>1</sup> As mitochondria with its DNA are only found in the cytoplasm of cells, the disease is maternally inherited. Primary point mutations occur at nucleotide positions 3460, 11778 and 14484 of the mitochondrial genome coding for protein subunits of the respiratory chain complexes. The 11778 mutation is most frequently observed, accounting for 80-90% of described cases.<sup>2</sup>

Young males are primarily affected (80-90%), usually in their third decade of life. Females, carriers of the disease, rarely express the symptoms.

Here, we report a case of LHON with typical clinical presentation and unusual late spontaneous improvement of one eye vision. To our knowledge, this is the first described case of the disease in our country.

### A case report

A boy of 17 experienced a sudden progressive diminution of right eye central vision. The condition deteriorat-

Correspondence to: *Jelena Petrinović-Dorešić, MD*, Department of Ophthalmology, General Hospital "Sveti Duh", Sveti Duh 64, 10000 Zagreb, Croatia [e-mail: jelena.doresic@post.hinet.hr](mailto:jelena.doresic@post.hinet.hr)

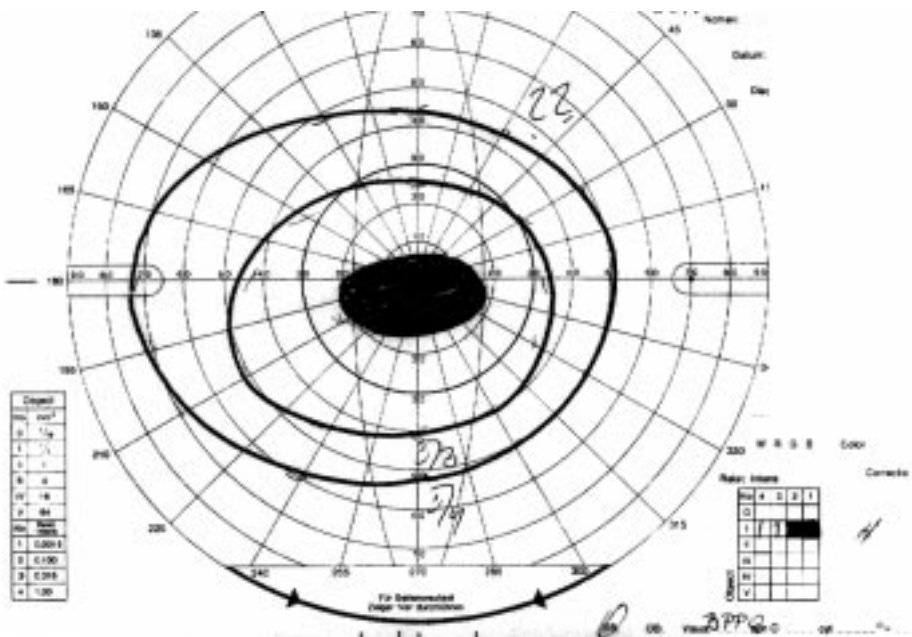
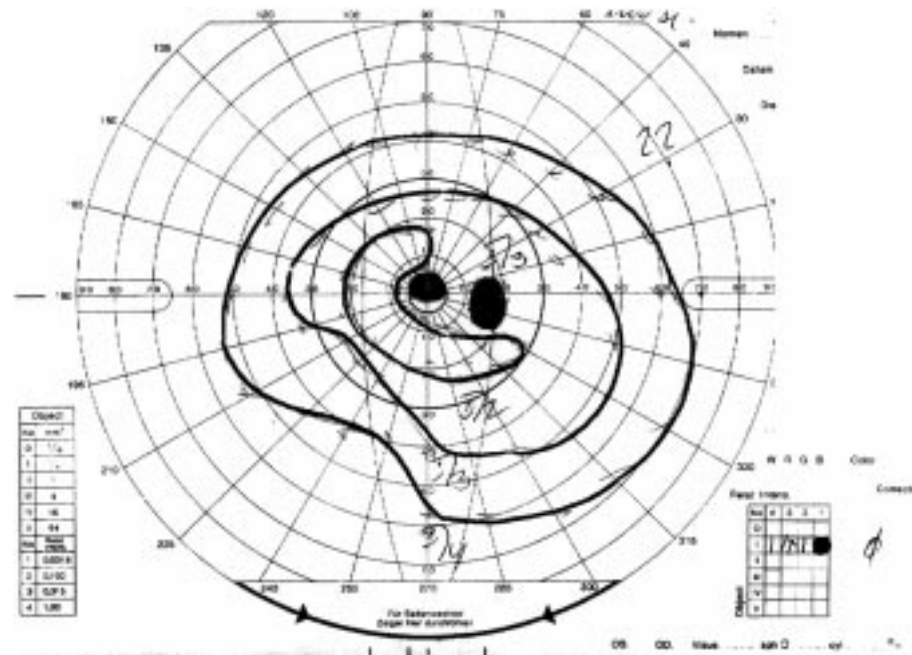
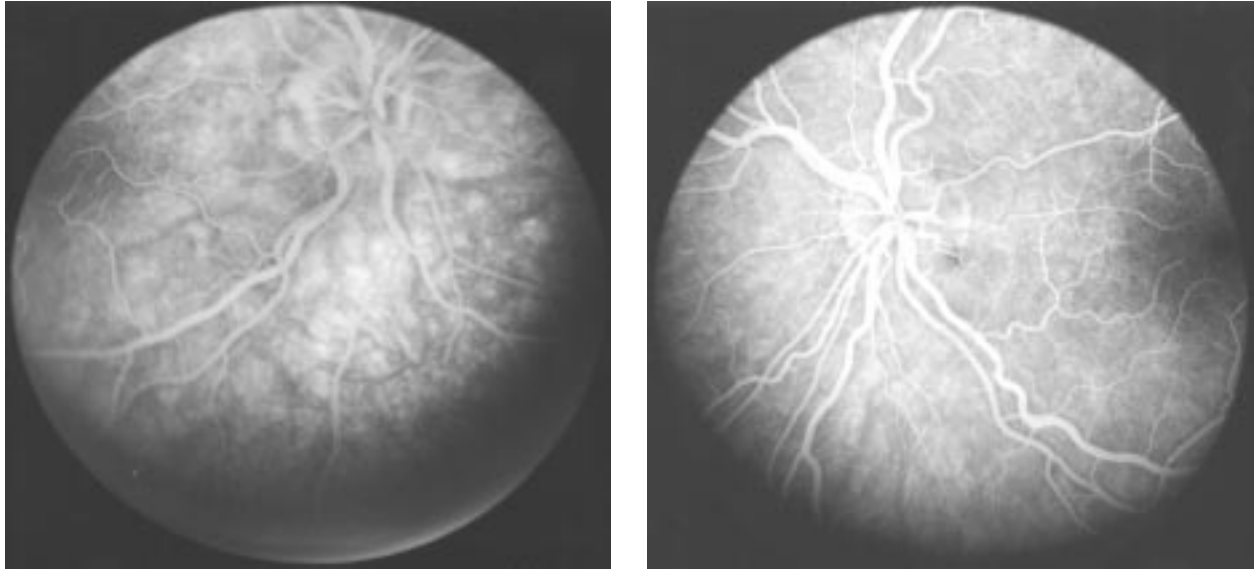


Fig. 1.  
Bilateral central scotoma  
at the time of presentation

ed over a few days. He also noticed that the colors when viewed with the right eye, were extremely pale. The left eye was similarly affected within the following 6 weeks. He had a healthy younger brother, with no visual disturbances. His mother could not remember any member of

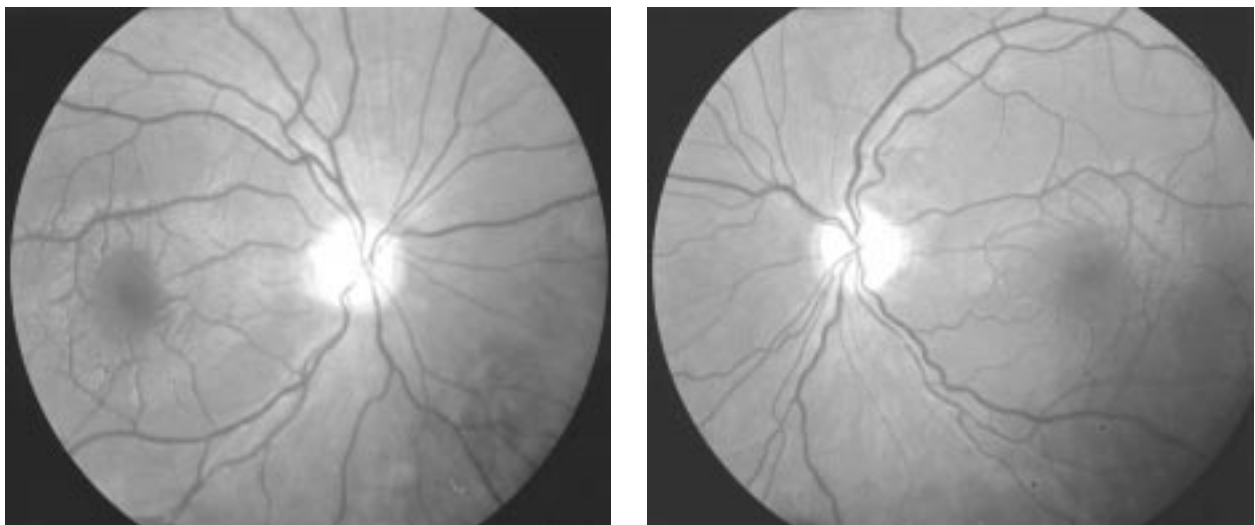
the family having problems with vision. The patient did not smoke, nor did he consume any alcohol and was well nourished. He was a school attendant and in his environment he was not exposed to heavy metals.



*Fig. 2. Fluorescein angiography (late phase) of the right (A) and the left (B) eye shows intact papillary and retinal vasculature with no leakage*

At the time of the referral, two months after the onset of the disease, visual acuity was 0,1 in the right eye, and 0,05 in the left. During visual field testing, central scotoma on the right eye and centrocoecal scotoma on the left eye were found (Fig. 1.). Subjectively present profound dyschromatopsia could not be objectively proved due to very low central vision. Pupillary responses were normal, and relative afferent pupillary defect could not be detected. There were no signs of intraocular inflammation and

intraocular pressure was normal. Fundoscopic appearance was not impressive – the only thing that could be seen was slightly tortuous papillary capillary network and very discrete dilatation and tortuosity of small peripapillary vessels, more pronounced on the left eye. On fluorescein angiography, the vessels were intact, with no leakage (Fig. 2.). Pattern visual evoked potentials (VEP) were bilaterally almost extinct, with hardly discernible P100. Retrobulbar part of optic nerve showed no abnormalities on orbital



*Fig. 3. Fundus appearance 14 months after the onset of the disease with bilateral profound optic disc atrophy.*

echography. Standard imaging studies (CT, MRI) excluded the presence of chiasmal or other intracranial mass lesion as well as foci of demyelination. The presence of sarcoidosis, tuberculosis and syphilis was also excluded with the appropriate serological tests and chest radiography.

Peripheral blood sample was taken for mitochondrial DNA (mtDNA) isolation from leukocytes. A G11778A mutation was found in leukocyte mtDNA and the mutation was homoplasmic. This finding confirmed earlier presumptive diagnose of LHON.

Follow-up showed no improvement of central visual acuity for almost a year, but thereafter the left eye vision started to improve. On the last check-up, 14 months after the onset of the disease, left eye visual acuity recovered to 0,7 but the right eye stayed at 0,1. On ophthalmoscopy, bilateral profound optic atrophy with "empty", pale discs was found (Fig. 3.). On control pattern VEP there were no changes.

The mother's leukocyte mtDNA has already been isolated and sent for analysis. We hope to get a consent from other family members to perform studies on their mitochondrial genome.

## Discussion

It is estimated that LHON accounts for 2% of blindness in individuals younger than 65 (3), but the exact data regarding the prevalence of the disease are still missing.

Even before the discovery of causative mtDNA mutations, the maternal inheritance of LHON was clearly observed. Initially it was suspected that the disease had had an X-linked mode of transmission, but after the discovery made by Wallace in 1988 the mode of inheritance was explained.<sup>1</sup>

Carriers of the mutation have in all cells of their organism either only mitochondria with mutant DNA (homoplasmy) or a mixture of normal and mutant form (heteroplasmy). Heteroplasmy indicates that there has been a new, recent mutation. It tends to change to homoplasmy in the subsequent generations.<sup>4</sup>

Egg cell with its big cytoplasm contributes almost exclusively to the cytoplasm of the future zygote. Compared to egg cell, human sperm cytoplasm has insignificant number of mitochondria and therefore an affected man can not transmit the disease to his offspring. When the fertilized egg begins its division in a case of heteroplasmy, mutant and normal mitochondria will be randomly distributed to the daughter cells. Therefore, some tissues will have more

abnormal mitochondria than the other, and that can also contribute to the different expression of the disease.<sup>5</sup> In our case, it was strange that the family history was negative, considering the presence of the homoplasmic mutation. This could be explained in part by the fact that there were more female members through maternal lineage than male. The follow-up of the family will show whether the younger brother of the patient will express the disease in the course of time.

Although the genetic basis of LHON is now pretty clear, this still does not explain why and how these mutations lead to the disease. Some new insights were given by Sadun *et al.*, who analyzed ultrastructure of optic nerves of two patients with LHON. They found a preferential loss of the smallest axons corresponding to the P-cell population and a relative preservation of the M-cells in the optic nerve.<sup>6</sup> This is in concordance with the results of functional studies utilizing pattern electroretinography (PERG). In patients with LHON, marked and selective N95 component loss is observed, indicating ganglion cell dysfunction.<sup>7</sup> The results of these studies explain the characteristic clinical features of LHON with central scotomas and dyschromatopsia due to selective P-cell population death, and preserved pupillary functions.

Another still unanswered question is the sex distribution of the disease. Mode of inheritance would presume that both sexes would be equally affected, but males constitute 80% to 90% of all patients. Females are only silent carriers of the mutation in vast majority of cases. Efforts to find an additional X-linked susceptibility locus that would explain this fact, have failed so far. It has been clearly shown that cigarette smoking and alcohol abuse can precipitate the occurrence of the disease,<sup>8</sup> but that could only in small part explain the sexual preponderance of the disease. Our patient and his younger brother were advised to avoid these risk factors.

The prognosis for recovery of central vision depends on the location of primary mutation. According to the published data, the chances for improvement with the 11778 mutation are less than 5%.<sup>9</sup> With the 3460 or 14484 mutations the prognosis is much better, with up to 60% of spontaneous improvement, especially if the disease manifested itself before the age of 20.<sup>10</sup> The unexpected late recovery (but to subnormal level) of the left eye vision in our patient suggest that these patients should be followed for a long period of time.

In conclusion, we report a patient with typical presentation of LHON and most frequent causative primary mtDNA mutation at 11778 location and asymmetric late central vision recovery.

## References

1. WALLACE DC, SINGH G, LOTT MT *et al.* Mitochondrial DNA mutations associated with Leber's hereditary optic neuropathy. *Science*. 1988;242:1427.
2. KERRISON JB. Neuro-Ophthalmology. *Ophthalmol Clin North Am*. 14: 1-11, 2001.
3. MACKAY DA. Epidemiology of Leber's hereditary optic neuropathy in Australia. *Clin Neurosci* 2:162-164, 1994.
4. De LAEY JJ. Leber's hereditary optic neuropathy. In: EUPO 2000 Course on strabismus and neuroophthalmology. Leuven, Belgium, 2000.
5. SMITH KH, JOHNS DR, HEHER KL *et al.* Heteroplasmy in Leber's hereditary optic neuropathy. *Arch Ophthalmol* 111:1486-1490, 1993.
6. Sadun AA, Win Ph, Ross-Cisneros FN, Walker SO, Carelli V. Leber's hereditary optic neuropathy differentially affects smaller axons in the optic nerve. *Trans Am Ophthalmol Soc* 2000;98:223-32.
7. Holder GE. Clinical visual electrophysiology: principles and practice. In: Berninger T, ed. *Manual of the 11th Electrophysiology Course*. Munich, Germany 2001.
8. Tsao K, Aitken PA, Johns DR. Smoking as an aetiological factor in a pedigree with Leber's hereditary optic neuropathy. *Br J Ophthalmol* 83:557-581, 1999.
9. Newman NJ, Lott MT, Wallace DC. The clinical characteristics of pedigrees of Leber's hereditary optic neuropathy with the 11778 mutation. *Am J Ophthalmol* 111:750-762, 1991.
10. Riordan-Eva p, Sanders MD, Govan GG, *et al.* The clinical features of Leber's hereditary optic neuropathy defined by the presence of the pathogenic mitochondrial DNA mutation. *Brain* 118:319-337, 1995.

### Acknowledgment

The authors would like to express their gratitude to Mrs Sara Seneca, PhD, from Center for Medical Genetics, Academisch Ziekenhuis – Vrije Universiteit Brussel, Belgium, for performing mtDNA analysis, and to Mrs Ksenija Fumić, PhD, from Clinical Hospital Center Zagreb, Clinical Institute of Laboratory Diagnosis, Zagreb University School of Medicine, Croatia, for mt DNA isolation.

### Sažetak

#### LIBEROVA HEREDITARNA OPTIKONEUROPATIJA – PRIKAZ SLUČAJA

*J. Perkočić-Dorešić, Lj. Henč-Petrinović, B. Kužmanović*

Leberova hereditarna optikoneuropatija je karakterizirana bilateralnim asinkronim gubitkom vida kod mladih osoba. Ovaj je tip neuropatije povezan sa mutacijom mitohondrijske DNA i stoga se nasljeđuje s majčine strane.

Bolest prvenstveno zahvaća muškarce, ali oni je ne prenose na potomstvo. Klinička slika, premda karakteristična, nije impresivna. Na početku bolesti velika je razlika između simptoma i znakova. Unatoč značajnom gubitku vidne oštrine, jedini vidljivi znak je retinalna teleangietatska mikroangiopatija u peripapilarnom području. Fluorescinska angiografija pokazuje netaknutu kapilarnu mrežu bez curenja kontrasta čime se isključuje upalna geneza poremećaja.

Ključne riječi: *nasljedna atrofija n. optikusa; mutacija mitohondrijske DNA*