

# A clinical algorithm for wound biofilm identification

Recognition of the existence of biofilm in chronic wounds is increasing among wound care practitioners, and a growing body of evidence indicates that biofilm contributes significantly to wound recalcitrance. While clinical guidelines regarding the involvement of biofilm in human bacterial infections have been proposed, there remains uncertainty and lack of guidance towards biofilm presence in wounds. The intention of this report is to collate knowledge and evidence of the visual and indirect clinical indicators of wound biofilm, and propose an algorithm designed to facilitate clinical recognition of biofilm and subsequent wound management practices.

wound biofilm; identification; algorithm; clinical assessment

**D.G. Metcalf**,<sup>1</sup> PhD,  
Senior Research Advisor;  
**P.G. Bowler**,<sup>1</sup> MPhil, Vice  
President;  
**J. Hurlow**,<sup>2</sup> GNP,  
CWOCN;  
<sup>1</sup> Science & Technology  
R&D, ConvaTec Ltd. UK;  
<sup>2</sup> Wound Practitioner  
LLC, Memphis, US.  
Email: daniel.metcalf@  
convatec.com

## Declaration of interest

D. Metcalf and P. Bowler are employed by ConvaTec Ltd. but have no other conflict of interest to declare. J. Hurlow is owner of Wound Practitioner LLC but has no other conflict of interest to declare.

**C**hronic wounds are defined by prevention or delay of the normal wound healing process. While underlying etiologies, such as venous insufficiency, ischaemia and hypoxia have a major impact on wound chronicity, microorganisms can also play a significant role.<sup>1</sup> Recent scientific studies have identified the presence of surface-associated bacterial communities in the form of biofilm in chronic wounds.<sup>2-9</sup> Specifically, independent research groups in the US<sup>2</sup> and Europe<sup>3</sup> used specialist microscopic techniques to examine debridement and biopsy samples; both groups observed biofilm microscopically in approximately 60% of all chronic wounds. Subsequent *in vivo* studies using a number of controlled animal models have confirmed that the presence of biofilm in wounds delays healing by interfering with granulation tissue formation, epithelialisation<sup>10-13</sup> and host defences.<sup>14-19</sup> Additionally, case studies and retrospective clinical studies in patients have demonstrated that biofilm-targeting treatment regimes, including sharp debridement, antibiotics, cleansers and some antimicrobial dressings, improved wound healing outcomes compared to standard care.<sup>20-23</sup> This body of evidence now strongly supports the notion that wound biofilm plays a significant role in delaying wound healing.<sup>24</sup> Moreover, it is now accepted that biofilm exists in a majority of chronic wounds,<sup>2-3</sup> is implicated in at least 80% of all human bacterial infections,<sup>25-26</sup> and is a key risk factor for wound infection.<sup>27</sup>

In the context of wound care, biofilm may be defined as communities of microorganisms attached to a surface (e.g. wound tissue, wound dressings), embedded within a hydrated matrix of extracellular polymeric substances (EPS; or slime), that provides protection against antimicrobial agents and host defenses. EPS is considered to be predominantly polysaccharide-based (although variable between bacteria),<sup>28-30</sup> with protein, lipids and DNA also involved.<sup>31</sup> In most locations where it can develop in the human body (e.g. lungs,<sup>32</sup> indwelling devices,<sup>33</sup> catheters<sup>34</sup>) biofilm is not apparent to the naked eye, either due to its internal location, or due to its microscopic nature. However, in some instances biofilm can exist as a macroscopic and visible structure, for example as a dental plaque in individuals with poor oral hygiene.<sup>35</sup> A number of clinicians have recently described what they consider to be visible biofilm in chronic wounds, in the form of translucent, slimy patches or layers,<sup>36</sup> or more opaque, green-yellow substance on the wound surface.<sup>20</sup> This suspected biofilm is tolerant to many antimicrobial interventions and can re-form quickly after debridement unless managed with effective antimicrobial agents and appropriate dressing technologies.<sup>20-21</sup> Following debridement, exposed bacteria remaining in the wound can re-establish biofilm quickly, often within 24 hours,<sup>20</sup> in order to evade host responses and antimicrobial therapies.<sup>37</sup> This is in contrast to devitalised host tissue such as slough or fibrin which is much slower to re-form,<sup>20</sup> but can itself be a sub-



**Fig 1. CLSM images of fluorescent *Pseudomonas aeruginosa* biofilm cultured on membrane filters.<sup>43</sup> (A) Fluorescence of the biofilm bacteria. (B) Fluorescence of the dye that stains EPS and bacteria. (C) Fluorescence images of (A) and (B) overlaid.**

strate for biofilm formation. Whereas biofilm on the wound surface may be reasonably easy to remove atraumatically using debridement methods such as swabs, fabric pads or curettage, slough is more contiguous with the underlying wound tissue and can be more difficult to remove.<sup>20-21</sup> In addition, proteinaceous, devitalised host tissue may be more responsive to enzymatic or autolytic debridement than the complex EPS of biofilm,<sup>20</sup> which may be a way to distinguish between slough and biofilm.

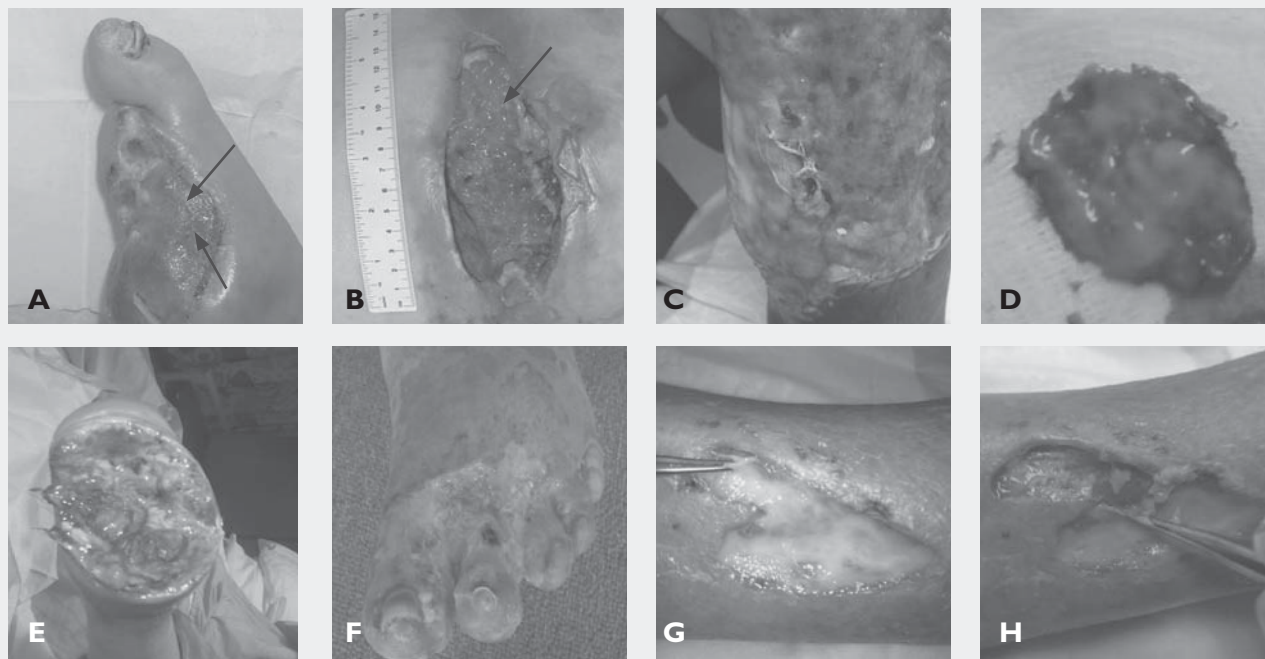
#### Identification of biofilm

Whether the material frequently observed by clinicians is actually biofilm rather than slough, fibrin or a combination of devitalised host tissue and biofilm is the subject of debate in the scientific and clinical communities.<sup>38-41</sup> In the absence of a routine test for the presence and location of wound

biofilm,<sup>42</sup> this distinction is difficult to confirm. Recently, there have been calls for point-of-care wound biofilm detection methods,<sup>25,39,41</sup> which, in the future may be useful to guide effective wound bed preparation and dressing selection. In our own laboratories, we have demonstrated how biofilm cultured *in vitro* can be rapidly and specifically stained. Using a membrane filter substrate,<sup>43</sup> biofilm of a fluorescent strain of *Pseudomonas aeruginosa* was cultured. The biofilm was then stained with a photosensitive dye, based on dental plaque disclosing agents, that stains EPS and bacteria and fluoresces at a different wavelength to the bacterial fluorescence. This allowed imaging of the biofilm (Figure 1A) and dye location (Figure 1B) separately, by confocal laser scanning microscopy (CLSM). By overlaying these images, the intimate correlation between the biofilm bacteria, surrounding EPS and the dye was apparent (Figure 1C), confirming that

**Table 1. Indirect clinical indications of wound biofilm by routine clinical assessment.**

Clinical observation	Clinical and scientific commentary
Excessive moisture	Bacteria thrive in a moist environment; excessive moisture is likely to encourage biofilm development. <sup>21</sup>
Poor-quality granulation tissue e.g. friable, hypergranular	Biofilm may be implicated in friable granulation tissue that has been associated with wound infection. <sup>44</sup>
Signs of local infection (redness, heat, swelling, pain, odour)	Biofilm is a precursor to infection, <sup>27</sup> and may trigger early warning signs of infection.
History of antibiotic failure or persistent or recurring infection, despite choice of antimicrobial therapy	Biofilm bacteria often evade the action of antibiotics. In the event of antibiotic success, return of an infection following cessation of antibiotics is a sign of continued biofilm presence. <sup>25</sup> Biofilm may contain populations of bacterial persister cells that can survive antimicrobial therapies. They may re-emerge once therapy ceases, acting as seeding agents and recruiters for subsequent biofilm re-formation. <sup>45</sup>
Culture-negative results despite signs of bacterial colonisation or a high suspicion of clinical infection	Biofilm bacteria metabolise more slowly, reproduce less frequently and show different traits (phenotypes) than planktonic bacteria, and standard microbiological culture techniques are incapable of identifying all species present in wound samples. <sup>46</sup> As a result, wound biofilm bacteria are often difficult or impossible to culture. <sup>47</sup>
Wound remains recalcitrant even though all obvious underlying comorbidities have also been addressed	There is another factor keeping the wound in a chronic state, and this factor, even though it is not always visible, may be biofilm.



**Fig 2. Visual indicators of wound biofilm;** (A) a static, non-progressing wound on a stable diabetic patient that had amputation of four toes. The shiny appearance of parts of the wound bed may be biofilm (as indicated by arrows); (B) a stage IV pressure ulcer with a heavily colonised wound bed. There may be a layer of suspected biofilm over some of the wound bed, particularly on the right side of the wound where this substance appears to be slightly thicker and opaque (as indicated by arrow); (C) an ischaemic and infected wound with suspected biofilm forming through and over a previously-applied gauze dressing; (D) green-pigmented suspected biofilm formed within 24 hours in a chronic wound beneath, and on, a silver alginate dressing; (E) forefoot amputation with bone exposure. Viscous, pale, green-blue, slimy suspected biofilm covered most of the wound bed; (F) surgical wound, post-necrotising fasciitis. The subsequent skin graft failed to take, and the wound had been static with minimal progress. The wound surface exhibited yellow suspected biofilm, possibly mixed with slough, with granulation tissue attempting to form beneath; (G) an ischaemic wound exhibiting signs of infection. This suspected biofilm re-formed quickly over granulation tissue despite antibiotic usage; (H) the suspected biofilm could be removed atraumatically using forceps to reveal the granulation tissue beneath.

the fluorescent dye was capable of staining biofilm. The technique of fluorescence detection offers one potential route towards a point-of-care wound biofilm detection method, perhaps using a biofilm stain and a hand-held inspection device. Such a device could be used to inspect wounds for biofilm to aid effective debridement and cleansing and to monitor wound status over time, although this might be limited to detecting surface-associated biofilm rather than any invasive, sub-surface biofilm.

However, even in the absence of a point-of-care biofilm visualisation technique, it is possible to compile clinical indicators and conditions that can facilitate judgement on the presence or absence of wound biofilm, based on current understanding of biofilm formation, composition, appearance, behaviour and treatment strategies. The intention of the current work is to consider ways in which wounds can be assessed for biofilm, and to propose a clinical algorithm that is designed to help clinicians to determine the presence of biofilm.

### Visual indicators of wound biofilm

In some established chronic wounds, biofilm formation may progress to a stage where it is macroscopic and visible to the experienced naked eye. For example, a shiny, translucent substance on the surface of the wound (Fig 2A) may be indicative of thin but observable biofilm, careful debridement of which may reveal a healthier wound bed.<sup>20</sup> At this stage, the wound may be cleansed and covered with an appropriate dressing that minimises the opportunity for remaining bacteria to re-form biofilm. Wound biofilm may also present as opaque, loosely-attached patches in some parts of the wound (Fig 2B), that can be carefully and atraumatically dislodged using standard debridement methods.<sup>21</sup> Viscous, slimy or gel-like substances can form on, beneath or even within some dressings (Fig 2C), including some antimicrobial dressings (Fig 2D). In some instances, the proliferation of certain bacterial species can result in the secretion of pigments, and in the case of two common wound-associated pathogens, *Pseudomonas aerugi-*

References

- 1 Edwards, R., Harding, K.G. Bacteria and wound healing. *Curr Opin Infect Dis* 2004; 17: 2, 91–96.
- 2 James, G.A., Swogger, E., Wolcott, R., et al. Biofilms in chronic wounds. *Wound Repair Regen* 2008; 16: 1, 37–44.
- 3 Kirketerp-Møller, K., Jensen, P.Ø., Fazli, M., et al. Distribution, organization, and ecology of bacteria in chronic wounds. *J Clin Microbiol* 2008; 46: 8, 2717–2722.
- 4 Bjarsholt, T., Kirketerp-Møller, K., Jensen, P.O., et al. Why chronic wounds will not heal: A novel hypothesis. *Wound Repair Regen* 2008; 16: 1, 2–10.
- 5 Fazli, M., Bjarsholt, T., Kirketerp-Møller, K., et al. Nonrandom distribution of *Pseudomonas aeruginosa* and *Staphylococcus aureus* in chronic wounds. *J Clin Microbiol* 2009; 47: 12, 4084–4089.
- 6 Fazli, M., Bjarsholt, T., Kirketerp-Møller, K., et al. Quantitative analysis of the cellular inflammatory response against biofilm bacteria in chronic wounds. *Wound Repair Regen* 2011; 19: 3, 387–391.
- 7 Kennedy, P., Brammah, S., Wills, E. Burns, biofilm and a new appraisal of burn wound sepsis. *Burns* 2010; 36: 1, 49–56.
- 8 Han, A., Zenilman, J.M., Melendez, J.H., et al. The importance of a multifaceted approach to characterizing the microbial flora of chronic wounds. *Wound Repair Regen* 2011; 19: 5, 532–541.
- 9 Neut, D., Tjeldens-Creusen, E.J., Bulstra, S.K., et al. Biofilms in chronic diabetic foot ulcers – a study of 2 cases. *Acta Orthopaedica* 2011; 82: 3, 383–385.
- 10 Schierle, C.F., de la Garza, M., Mustoe, T.A., et al. Staphylococcal biofilms impair wound healing by delaying reepithelialization in a murine cutaneous wound model. *Wound Repair Regen* 2009; 17: 3, 354–359.

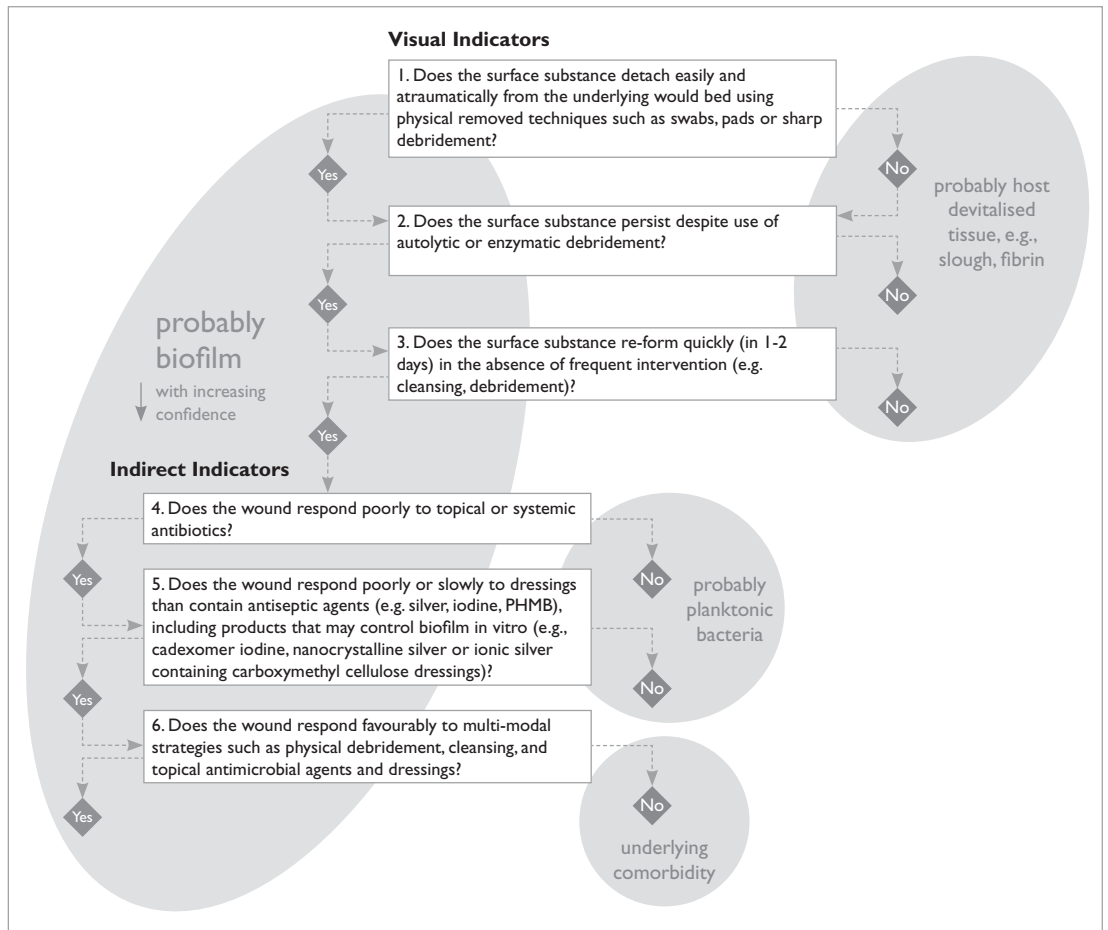


Fig 3. Clinical algorithm for wound biofilm identification.

*nosa* and *Staphylococcus aureus*, this may result in pale green or pale yellow biofilm, due to the production of pyocyanin (green-blue; Figure 2E) or staphyloxanthin (golden; Figure 2F), respectively. However, this coloured substance may be difficult to visibly distinguish from slough. While it may resemble host devitalised tissue, it behaves differently than slough or fibrin in that it can be more easily removed but re-forms quickly – a key indicative sign of wound biofilm. This substance may lie on the wound surface, rather than being contiguous with the underlying wound tissue (Figure 2G), and may be carefully removed, for example by forceps, to reveal cleaner granulation tissue beneath (Figure 2H).

**Indirect clinical indicators of biofilm**

In many instances where wound biofilm is not clearly distinguishable to the experienced naked eye, other clinical cues may indicate the presence of biofilm. Table 1 summarises some of these indirect clinical indicators of biofilm presence which should be considered during routine clinical assessment.

**A clinical algorithm**

By combining the above visual (Fig 2) and indirect indicators of wound biofilm (Table 1), an algorithm is proposed that may assist clinicians in confirming wound biofilm and subsequently taking appropriate measures to manage it (Fig 3). This algorithm poses questions around the appearance of substances in the wound and their response to wound bed preparation techniques, then considers the wound's behaviour to antimicrobial agents. It may be started at question 1 or question 4, depending on the appearance of the wound. This algorithm may thus facilitate clinical judgement of the likely substances involved (e.g. biofilm – viable, bacteria-derived tissue; slough – non-viable, host tissue) and the predominant mode of bacterial existence (i.e. biofilm or planktonic). This algorithm is concerned with local wound factors and should be considered only once other, endogenous pathophysiological factors, e.g. hypoxia or ischaemia, and external factors, e.g. pressure or lifestyle, have been addressed and minimised. With an increasing number of affirmative answers in the algorithm,



there will be a likewise increase in the probability of biofilm presence and its involvement in wound recalcitrance.

## Conclusion

Through a review of the literature and our current understanding of wound biofilm, it has been possible to collate a variety of visual indicators that may

directly indicate the presence of biofilm, together with other indirect clinical indicators, which have collectively enabled the development of a clinical algorithm for wound biofilm presence. While much-needed wound biofilm research and guidance is being published at a great pace,<sup>48</sup> this algorithm will hopefully facilitate clinical recognition of biofilm and subsequent optimal wound management. ■

- 11 Dalton, T., Dowd, S.E., Wolcott, R.D., et al. An *in vivo* polymicrobial biofilm wound infection model to study interspecies interactions. *PLoS ONE* 2011; 6: e27317.
- 12 Seth, A.K., Geringer, M.R., Gurjala, A.N., et al. Treatment of *Pseudomonas aeruginosa* biofilm-infected wounds with clinical wound care strategies: A quantitative study using an *in vivo* rabbit ear model. *Plast Reconstr Surg* 2012; 129: 2, 262e–274e.
- 13 Pastar, I., Nusbaum, A.G., Gil, J., et al. Interactions of methicillin resistant *Staphylococcus aureus* USA300 and *Pseudomonas aeruginosa* in polymicrobial wound infection. *PLoS ONE* 2013; 8: e56846.
- 14 Davis, S.C., Ricotti, C., Cazzaniga, A., et al. Microscopic and physiologic evidence for biofilm-associated wound colonization *in vivo*. *Wound Repair Regen* 2008; 16: 1, 23–29.
- 15 Zhao, G., Hochwalt, P.C., Usui, M.L., et al. Delayed wound healing in diabetic (db/db) mice with *Pseudomonas aeruginosa* biofilm challenge: A model for the study of chronic wounds. *Wound Repair Regen* 2010; 18: 5, 467–477.
- 16 Gurjala, A.N., Geringer, M.R., Seth, A.K., et al. Development of a novel, highly quantitative *in vivo* model for the study of biofilm-impaired cutaneous wound healing. *Wound Repair Regen* 2011; 19: 3, 400–410.
- 17 Seth, A.K., Geringer, M.R., Galiano, R.D., et al. Quantitative comparison and analysis of species-specific wound biofilm virulence using an *in vivo*, rabbit ear model. *J Am Coll Surg* 2012; 215: 3, 388–399.
- 18 Seth, A.K., Geringer, M.R., Hong, S.J., et al. Comparative analysis of single-species and polybacterial wound biofilms using a quantitative, *in vivo*, rabbit ear model. *PLoS ONE* 2012; 7: e42897.
- 19 Nguyen, K.T., Seth, A.K., Hong, S.J., et al. Deficient cytokine expression and neutrophil oxidative burst contribute to impaired cutaneous wound healing in diabetic, biofilm-containing chronic wounds. *Wound Repair Regen* 2013; doi: 10.1111/wrr.12109.
- 20 Hurlow, J., Bowler, P.G. Clinical experience with wound biofilm and management: a case series. *Ostomy Wound Manage* 2009; 55: 4, 38–49.
- 21 Hurlow, J., Bowler, P.G. Potential implications of biofilm in chronic wounds: a case series. *J. Wound Care* 2012; 21: 3, 109–115.
- 22 Wolcott, R.D., Rhoads, D.D. A study of biofilm-based wound management in subjects with critical limb ischaemia. *J Wound Care* 2008; 17: 4, 145–153.
- 23 Wolcott, R.D., Cox, S. More effective cell-based therapy through biofilm suppression. *J Wound Care* 2012; 22: 1, 26–31.
- 24 Metcalfe, D.G., Bowler, P.G. Biofilm delays wound healing: a review of the evidence. *Burns Trauma* 2013; 1: 1, 5–12.
- 25 Hall-Stoodley, L., Stoodley, P., Kathju, S., et al. Towards diagnostic guidelines for biofilm-associated infections. *FEMS Immunol Med. Microbiol* 2012; 65: 2, 127–145.
- 26 Davies, D. Understanding biofilm resistance to antibacterial agents. *Nat Rev Drug Discov* 2003; 2: 2, 114–122.
- 27 Percival, S.L., Bowler, P.G. Biofilms and their potential role in wound healing. *Wounds* 2004; 16: 7, 234–240.
- 28 Steinberger, R.E., Holden, P.A. Macromolecular composition of unsaturated *Pseudomonas aeruginosa* biofilms with time and carbon source. *Biofilms* 2004; 1: 1, 37–47.
- 29 Jiao, Y., Cody, G.D., Harding, A.K., et al. Characterization of extracellular polymeric substances from acidophilic microbial biofilms. *Appl Environ Microbiol* 2010; 76: 9, 2916–2922.
- 30 Tsuneda, S., Aikawa, H., Hayashi, H., et al. Extracellular polymeric substances responsible for bacterial adhesion onto solid surface. *FEMS Microbiol Lett.* 2003; 223: 2, 287–292.
- 31 Branda, S.S., Vik, A., Friedman, L., et al. Biofilms: the matrix revisited. *Trends Microbiol* 2005; 13: 1, 20–26.
- 32 Costerton, J.W. Cystic fibrosis pathogenesis and the role of biofilms in persistent infection. *Trends Microbiol* 2001; 9: 2, 50–52.
- 33 Adair, C.G., Gorman, S.P., Feron, B.M., et al. Implications of endotracheal tube biofilm for ventilator-associated pneumonia. *Intensive Care Med* 1999; 25: 10, 1072–1076.
- 34 Trautner, B.W., Darouiche, R.O. Role of biofilm in catheter-associated urinary tract infection. *Am J Infect Control* 2004; 32: 3, 177–183.
- 35 Marsh, P.D., Bradshaw, D.J. Dental plaque as a biofilm. *J. Industr Microbiol* 1995; 15: 3, 169–175.
- 36 Lenselink, E., Andriessen, A.A. cohort study on the efficacy of polyhexanide-containing bioocellulose dressing in the treatment of biofilms in wounds. *J Wound Care* 2011; 20: 11, 534–538.
- 37 Wolcott, R.D., Rumbaugh, K.P., James, G. et al. Biofilm maturity studies indicate sharp debridement opens a time-dependent therapeutic window. *J Wound Care* 2010; 19: 8, 320–327.
- 38 Cowan, T. Wound biofilms – a controversial issue. *J Wound Care* 2012; 21: 3, 106.
- 39 White, R.J., Cutting, K.F. Wound biofilms – are they visible? *J Wound Care* 2012; 21: 3, 140–141.
- 40 Hurlow, J. Response to White and Cutting critique. *J Wound Care* 2012; 21: 4, 981.
- 41 Leaper, D.J., Schultz, G., Carville, K., et al. Extending the TIME concept: what have we learned in the past 10 years? *Int. Wound J* 2012; 9: Suppl. 2, 1–19.
- 42 Hess, C.T., Kirsner, R.S. Understanding the presence of biofilms in wound healing: opportunities for prevention. *Today's Wound Clinic* 2012; 6: 3, 12–18.
- 43 Kirker, K.R., Secor, P.R., James, G.A., et al. Loss of viability and induction of apoptosis in human keratinocytes exposed to *Staphylococcus aureus* biofilms *in vitro*. *Wound Repair Regen* 2009; 17: 5, 690–699.
- 44 Cutting, K.F., Harding, K.G. Criteria for identifying wound infection. *J Wound Care.* 1994; 3: 4, 198–201.
- 45 Percival, S.L., Hill, K.E., Malic, S., et al. Antimicrobial tolerance and the significance of persister cells in recalcitrant chronic wound biofilms. *Wound Repair Regen* 2011; 19: 1, 1–9.
- 46 Davies, C.E., Hill, K.E., Wilson, M.J., et al. Use of 16S ribosomal DNA PCR and denaturing gradient gel electrophoresis for analysis of the microfloras of healing and nonhealing chronic venous leg ulcers. *J Clin Microbiol* 2004; 42: 8, 3549–3557.
- 47 Dowd, S.E., Sun, Y., Secor, P.R., et al. Survey of bacterial diversity in chronic wounds using pyrosequencing, DGGGE, and full ribosome shotgun sequencing. *BMC Microbiol* 2008; 8: 43.
- 48 Dowsett, C. Biofilms: A practice-based approach to identification and treatment. *Wounds UK* 2013; 9: 2, 68–72.

## Acknowledgements

The authors gratefully acknowledge Rowland Lees, BSc for the CLSM images in Figure 1, and Dale Copson MSc, RN and Lisa Wood, BSc, RN, Medical Affairs Specialists, ConvaTec Ltd., for the images and descriptions of wounds in Fig 2A-B and 2E-F.

## S A Ž E T A K

### KLINIČKI POSTUPNIK ZA PREPOZNAVANJE BIOFILMA U VRIJEDU

D. G. METCALE, P. G. BOWLER i J. HURLOW<sup>1</sup>

*Science & Technology R&D, ConvaTec Ltd., UK i <sup>1</sup>Wound Practitioner LLC, Memphis, US*

Broj publiciranih referenci koje ukazuju na prisutnost biofilma u kroničnim ranama je u porastu. Sve je veći broj dokaza koji potvrđuju da biofilm značajno sudjeluje u nezacjeljivanju rane i u bakterijskim infekcijama. Iz navedenih razloga postavlja se pitanje nedostatka postupnika o dokazima prisutnosti biofilma u rani. Namjera je ovog rada specificirati vidljive dokaze i indirektno dati kliničke smjernice tretmana biofilma u rani, te predložiti određeni postupnik za olakšanje kliničkog prepoznavanja biofilma da bi se potom promijenilo ciljano liječenje vrijeda.

*Ključne riječi:* biofilm rane; prepoznavanje; postupnik; klinička procjena

---

Ovaj je postupnik preisak rada iz časopisa *Journal of Wound Care* 2014; 23(3) s dozvolom od 10. veljače 2016. godine.