

Review

The characteristics of craniofacial and cervicovertebral morphology in different genetic syndromes - a literature review and three case reports

Lazić, Emira ¹; Jakovljević, Aleksandar ²; Nikodijević Latinović, Angelina ¹; Nedeljković, Nenad ¹

¹ Department of Orthodontics, School of Dental Medicine, University of Belgrade, Serbia

² Department of Oral Surgery and Implantology, School of Dental Medicine, University of Belgrade, Serbia

ABSTRACT

Introduction: Patients with genetic syndromes were characterized by variety of skeletal craniofacial and cervicovertebral morphology. Skeletal anomalies are recognized concomitants of the various genetic syndromes.

The aim of the study was to review the current literature on this topic and to present the characteristics of craniofacial and cervicovertebral morphology and subsequent anomalies in three patients with Crouzon syndrome, Treacher Collins syndrome and cleidocranial dysplasia.

Materials and methods: A comprehensive electronic search was performed using PubMed via Medline, Web of Science and SCOPUS. A manual search involved references from articles retrieved for possible inclusion. There were no restrictions as to date of publication, study design or language. The search, evaluation of relevant articles, and their critical appraisal were performed by two independent judges. Discrepancies between reviewers were resolved through a consensus with a third party.

Case reports: Additionally, this paper presents a radiographic analysis of craniofacial and cervicovertebral morphology in patients with cleidocranial dysplasia, Crouzon, and Treacher Collins syndromes. The most characteristic findings of cervicovertebral morphology were the presence of cervical spine fusions in all three patients. The intervertebral fusions in patients with Crouzon and Treacher Collins syndromes have been characterized with "block vertebrae". Cervicovertebral complex of the patient with cleidocranial dysplasia is characterized by delayed mineralization of vertebral bodies (C1–C7).

Results: Although craniofacial and cervicovertebral anomalies in presented syndromes have different phenotype expression, the vast majority of cases are caused by mutations in specific, syndrome-related genes (FGFR2, FGFR3, RUNX2, TCOF1, POLR1C, POLR1D). Craniofacial anomalies, that include changes in development of hard and soft tissues, were considered as traditional concomitant of presented syndromes. Apart from these changes, cervicovertebral region could also be affected. Recent reports show different changes in vertebral structure (delayed mineralization) and unphysiological relations (cervical spine fusions).

Conclusion: The limitation of cervical range of motion resulting from these anomalies may have clinical significance on multidisciplinary management approach in these patients. Recent progress in dentistry resulted in better diagnostic and therapeutic options and outcomes for individuals with genetic syndromes.

Lazić E, Jakovljević A, Nikodijević Latinović A, Nedeljković N. The characteristics of craniofacial and cervicovertebral morphology in different genetic syndromes - a literature review and three case reports. *South Eur J Orthod Dentofac Res.* 2016;3(1):24-33.

Submitted: December 10, 2015; Revised: February 28, 2016; Published April 22, 2016

INTRODUCTION

Craniofacial and cervicovertebral anomalies can occur primarily as a result of alterations in the embryonic development or secondary after birth as a result of pathologic processes or through trauma. ¹

Skeletal anomalies are recognized concomitants of the various genetic syndromes. ² Many types of primary craniofacial and cervicovertebral anomalies are rare, and they are consequence of different chromosome aberrations. ³

Crouzon syndrome (CS) or craniofacial dysostosis was first described in 1912 by Louis Edouard Octave Crouzon, a French neurologist. ⁴ Half of the cases are sporadic, and the other half are autosomal dominant with complete penetrance and variable expression. ⁵ Its incidence is currently estimated to occur in 16.5 out of every 1,000,000 people. ⁶ CS has no racial or sex predilection and these patients are typically of normal intelligence. ^{7,8}

Corresponding Author:

Nenad Nedeljković,

Department of Orthodontics, School of Dental Medicine,
University of Belgrade,

Gastona Gravijea 2, 11 000 Belgrade, Serbia

E-mail: nenad.nedeljkovic@stomf.bg.ac.rs

It belongs to a family of autosomal dominant craniosynostoses. Craniosynostosis, which refers to the premature closure of one or more cranial sutures, is present in most infants with CS. The degree of deformity is determined by the order and rate of suture fusion.⁹ Bicoronal synostosis is the most common pattern observed, resulting in a brachycephalic head shape (a broad and short head), although scaphocephaly and trigonocephaly have been described. Premature closure of all sutures, except squamosal and metopic sutures, leads to the most dramatic malformation known as cloverleaf skull.⁸ When multiple sutures between calvarial and cranial base are involved the skull base may fuse prematurely, causing maxillary hypoplasia, hypertelorism, exophthalmos, occasional upper airway obstruction, and multiple other features.^{7,10} An additional finding among patients with CS was elevated intracranial pressures, probably due to abnormal cranial vault formation.¹¹

CS is associated with mutations in fibroblast growth factor receptors 2 or 3 (FGFR2, FGFR3) genes linked to a tyrosine kinase protein receptor and located on chromosome 10 (10q25q-26 chromosome location).¹² Mutations within these genes cause premature conversion of fibrous suture lines to permanent osseous bone matrix.¹³ Furthermore, these mutations affect the outcome of the first branchial arch development that is essential for normal craniofacial growth.¹⁰

Cleidocranial dysplasia (CCD), also known as cleidocranial dysostosis or Marie-Sainton syndrome is an uncommon (1:1.000.000) genetic skeletal condition that is inherited as an autosomal dominant disorder. It is characterized with high penetrance and wide expressive variability.¹⁴ CCD has no racial or gender predilection and these patients are characterized with normal intelligence.¹⁵ The earliest recognizable report of CCD in the medical literature has been attributed to Meckel in 1760.¹⁶ In 1898, the French physicians Marie and Sainton¹⁷ described condition that has been formally named "cleidocranial dysostosis". Formerly the disease was considered to influence only the bones which undergo intramembranous ossification (the skull, clavicle and flat bone). However, it was reported in subsequent studies that the disease also affects the bones formed by endochondral ossification. Hence, the disease was named CCD to describe the broad spectrum of symptoms.¹⁸

The major manifestations of this genetic syndrome are clavicular hypoplasia, delayed fusion of cranial sutures and dental abnormalities.¹⁹ The dental manifestations include delayed exfoliation of deciduous teeth, delayed eruption or failure of eruption of permanent teeth, supernumerary teeth, retention cysts, and enamel hypoplasia.¹⁹⁻²² This disorder may be caused by heterogeneous mutation in the transcription core binding factor A1 (CBFA1), also known as runt-related transcription factor two gene (RUNX2), located on chromosome 6p21.²³ RUNX2 is a member of the runt-related family of transcription factors that together with two other members (RUNX1 and RUNX3) and the common partner (CBF β) form the

core binding factor complex.²⁴ It has been identified as an osteoblast-specific transcription factor and is also regulated by bone morphogenetic proteins (BMPs) and vitamin D3.²⁵ Along with its role in bone development, RUNX2 participates in tooth development by mediating interactions between epithelial and mesenchymal cells during tooth morphogenesis and histodifferentiation of the epithelial enamel organ.²⁶ RUNX2 (CBFA1) is the only gene in which mutation is known to cause CCD. Molecular genetic testing of RUNX2 detects pathogenic variants in 60%-70% of individuals with a clinical diagnosis of CCD. To date, total of 62 types of CBFA/RUNX2 mutation have been identified in CCD patients, including deletion, insertion, nonsense mutation, missense mutation and change in splicing site.²⁷⁻²⁹ However, 40% to 50% of the cases of CCD appear spontaneously with no apparent genetic cause.³⁰

Treacher Collins syndrome (TCS), otherwise known as mandibulofacial dysostosis, is a rare autosomal dominant genetic disorder of the craniofacial and cervicovertebral morphogenesis with a high degree of penetrance and variable phenotypic expression.³¹⁻³⁴ Affecting the proper formation of the first and second branchial arches, this syndrome occurs during the fifth to eighth weeks of embryonic development with an incidence of 1 in 50,000 live births without gender predilection.^{2,32-34} TCS patients have normal intelligence with no associated developmental delay or neurologic disease. However, as a result of distorted physical appearance, patients often face social challenges and stigma throughout life.³⁵ TCS was first introduced and examined in 1889 as congenital neonatal deformity with the colobomata of the lower eyelids by George Andreas Berry.³⁶ In 1900, a British ophthalmologist named Edward Treacher Collins reported the essential features of the syndrome that was named after him.³⁷ The first extensive review of the condition was detailed by Adolphe Franceschetti and David Klein in 1949, who used the term mandibulofacial dysostosis to describe its clinical features.³⁸

TCS is characterized by numerous bilateral symmetrical developmental anomalies that are restricted to the head and neck region. Hypoplasia of the facial bones, particularly the mandible and zygomatic complex is an extremely common feature of TCS. Overall, the facial profile in TCS is convex due to the pronounced retrognathia. The most severe forms of TCS may have significantly deficient proximal mandible or even lacking the ramus/condyle unit altogether.^{33,34,39-41} Hypoplasia of the facial bones may result in dental malocclusion. The teeth may be widely spaced, malpositioned or reduced in number. In a number of cases the palate is high, arched and occasionally cleft.⁴²⁻⁴⁴ Ophthalmic anomalies include downward slanting "antimongoloid" of the palpebral fissures with notching of the lower eyelids and a paucity of lid lashes medial to the defect.⁴⁵ Other clinical features of TSC include changes in the shape, size and position of the external ears, which are frequently associated with atresia of the external auditory canals and anomalies of the middle ear ossicles. As a consequence, bilateral conductive

hearing loss is commonly found in TCS patients.^{46,47}

TCS results from a loss-of-function mutation in Treacher Collins-Franceschetti syndrome 1 (TCOF1) gene located on chromosome 5q32-33.1. TCOF1 mutations occur in over 93% of TCS patients, but mutations can also occur in polymerase (RNA) I polypeptide C (POLR1C) and polypeptide D (POLR1D) genes.^{31,48,49} TCOF1 contains 26 exons and encodes a 1411 amino acid phosphoprotein named treacle that may serve as a link between ribosomal RNA (rRNA) gene transcription and pre-RNA processing. It is involved in the production of rRNA that helps assemble amino acids into functioning proteins, which is essential for normal functioning and survival of cells.^{50,51} Treacle helps in neuroepithelial survival and neural crest cell proliferation that is central to normal craniofacial development. Mutation in TCOF1 leads to high degree of neuroepithelial apoptosis and consequent loss of neural crest cells. More than 60 % of TCS cases have no family history and arise, as a result of de novo mutation. Subsequently, more than 130 distinct mutations have been implicated in yielding the TCS phenotype.^{48,52}

It is well known that changes in cervicovertebral morphology can disturb proper functioning of the skeletal system.^{2,53} The characteristics of craniofacial malformations caused by various genetic syndromes are well documented.^{2,5,14,32} On the other hand, the deviations in cervicovertebral morphology in patients with cleidocranial dysplasia, Crouzon and Treacher-Collins syndromes are poorly reported.^{54,55} In this regard, the aim of the study was to review available literature on this topic and to present the characteristics of craniofacial and cervicovertebral morphology in three patients with different genetic syndromes.

MATERIALS AND METHODS

A comprehensive electronic search was performed using PubMed via Medline, Web of Science and SCOPUS. All mentioned databases provided title, abstract and key words. The search of key words included the following combination of medical subject heading terms “Crouzon syndrome”, “Cleidocranial dysplasia”, “Cleidocranial dysostosis”, “Treacher Collins syndrome”, “cervical spine”, “dental”, “anomalies”, “outcome”. The manual search involved references from articles retrieved for possible inclusion. There were no restrictions as to date of publication, study design or language. The search, evaluation of relevant articles, and their critical appraisal were performed by two independent judges. Discrepancies between reviewers were resolved through consensus with a third party.

CASE REPORT 1

A 15-year-old girl with Crouzon syndrome came to the Clinic of Orthodontics, School of Dental Medicine, University of Belgrade for orthodontic treatment. During standard diagnostic procedures, the measurements were performed on lateral cephalograms (Table 1). Written informed consent was

obtained from the patient’s guardian for publication of this case report and accompanying images.

In this case, the radiographic analysis showed the presence of craniofacial deformities. According to standards for that age, angular parameters showed maxillary retrognathism, mandibular prognathism, and skeletal Class III. Posterior maxillary and anterior mandibular inclinations caused skeletal deep bite (Table 2). Changes in the development caused the higher value of sella angle and lower values of articulare and gonial angles. Furthermore, we noticed the lower value of anterior facial height and anterior facial growth rotations. Linear measurements have revealed a decrease in cranial base and maxillary length while the ramus length increased (Table 2). Reported changes in cranial base and poor growth of the midface have resulted in relative mandibular prognathism and gave the effect of the patient’s concave face (Figure 3). Further radiographic analysis of cervicovertebral morphology showed changes in its development. In this case of Crouzon syndrome we have noticed C2-C3-C4 and C5-C6 intervertebral fusions, and higher atlas (C1) position (Figure 3). The intervertebral fusions have been characterized with “block vertebrae”, which included partial or complete fusion, either cartilaginous or bony, of two or more vertebrae. Additionally, the atlas (C1) position was closer, but not fused, with occipital bone (Figure 4).

Table 1. Descriptions and definitions of the cephalometric measurements illustrated on Figure 1 and 2.

Abbreviation	Name of the measurement
SNA(°)	Maxillary prognathism
SNB(°)	Mandibular prognathism
ANB (°)	Sagittal intermaxillary angle - Skeletal Class
SN/SPP(°)	Maxillary plane angle
SN/MP (°)	Mandibular plane angle
SpP/MP (°)	Intermaxillary vertical angle
NSAr (°) SArGo (°) ArGoMe (°)	Sella angle Articular angle Gonial angle
ΣBjörk (°)	Sum of angles for the Björk polygon ΣNSAr+SArGo+ArGoMe
SGo (mm)	Posterior face height
NMe (mm)	Anterior face height
%SGo/NMe	Percentage ratio of the posterior and anterior face height
N-S (mm)	Anterior cranial base length
S-Ba (mm)	Posterior cranial base length
N-Ba (mm)	Total cranial base length
Snp-Sna (mm) Go-Gn (mm) Cd-Go (mm)	Maxillary length Mandibular length Ramus length

Table 2. Craniofacial parameters in different genetic syndromes

Craniofacial parameters	Standard values* (Me ± SD)	Crouzon syndrome	Standard values** (Me ± SD)	Treacher Collins syndrome	Cleidocranial dysostosis
Angular parameters (°)					
SNA	83.2±2.24	67	84.0±2.38	80	83
SNB	81.2±1.86	83	81.2±2.26	65	85
ANB	2.0±1.65	-16	2.8±1.95	15	-2
SN/SPP	12	17	12	18	5
SN/MP	29.5±2.60	27	29.3±3.10	48	16
SPP/MP	21.8±2.97	10	22.40±3.42	30	11
NSAr	121.4±3.52	132	121.2±2.92	121	110
SArGo	143	133	143	147	165
ArGoMe	125.5±4.02	125	125.60±3.60	130	102
ΣBjörk	396±3	390	396±3	398	377
Linear parameters (mm)					
SGo	-	73	109.20±4.05	52	85
NMe	112.6±3.97	94	62-65	85	105
%SGo/NMe	62-65	77.66	69.20±2.38	61.18	80.95
N-S	69.7±2.33	57	44.30±2.10	55	62
S-Ba	44.9±1.65	32	53.30±3.22	40	44
Snp-Sna	54.1±2.61	37	75.00±3.95	35	50
Go-Gn	75.7±2.88	70	44.10±3.00	45	73
Cd-Go	46.0±3.18	55	109.20±4.05	34	65

* Standard values for 15-year-old female according to Broadbent et al. (85)

**Standard values for 13-year-old female according to Broadbent et al. (85)

Figure 1. Angular parameters.

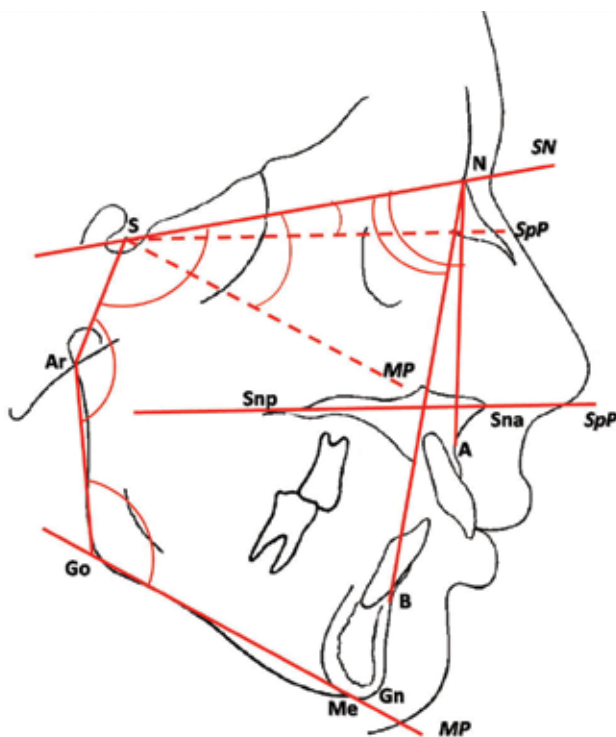


Figure 2. Linear parameters.

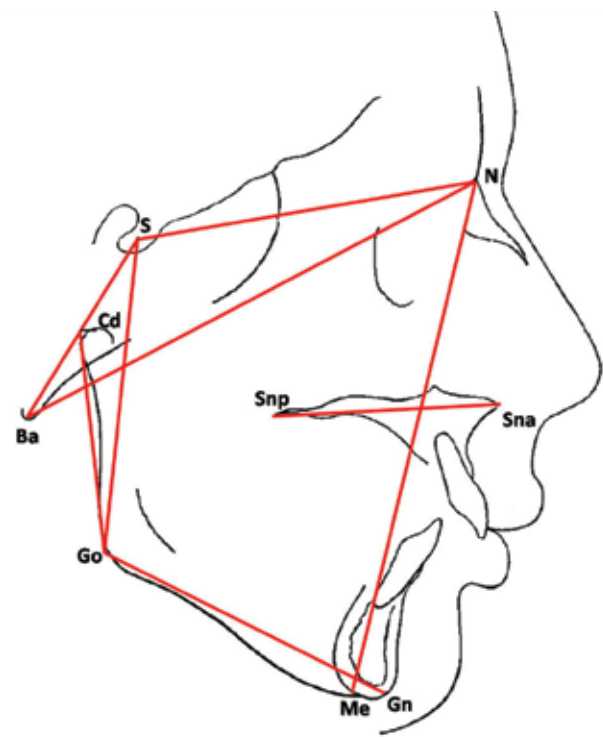
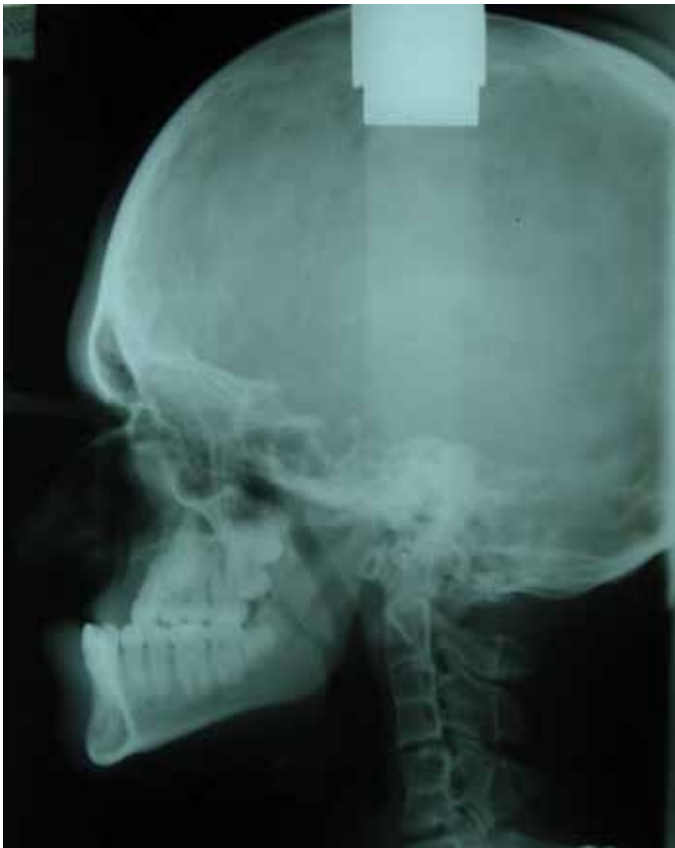

Figure 3. Lateral cephalogram of Crouzon syndrome.



CASE REPORT 2

A 15-year-old girl with cleidocranial dysplasia referred for orthodontic treatment at the Clinic of Orthodontics, School of Dental Medicine, University of Belgrade. On that occasion standard diagnostic procedures, including radiographic analysis on lateral cephalograms, were performed (Table 1). Written informed consent was obtained from the patient's guardian for publication of this case report and accompanying images.

The expressive frontal prominence, dysplastic nose bones, hypoplasia of the maxilla and zygomatic bones were the most characteristic craniofacial changes that we have observed in this case. Cephalometric analysis revealed maxillary and mandibular prognathism and skeletal Class III. We have found higher anterior maxillary and mandibular plane inclination with skeletal deep bite. Similar to the previous case report, this patient was characterized by anterior facial growth rotation and increase of articulare angle. According to standards for that age, linear measurements showed smaller anterior cranial base and higher ramus length (Table 2). Midfacial hypoplasia and anterior facial growth rotation led to a small face phenotype. Consequently, we observed many unerupted and impacted teeth. These findings are common in cleidocranial dysplasia, but they are not syndrome-specific. The CBFA1 gene mutations have been related to delayed bone ossification and poor development of the ossification centers of the embryonic vertebral bodies.²³ In this case, cervicovertebral

complex characterized by delayed mineralization of vertebral bodies (C1–C7). They retained infantile shape with convex upper and lower plates and vertebral arches defects (Figure 5). The specific findings on the cranium were multiple intrasutural bones throughout the occipital region known as Wormian bones and no basilar invagination (Figure 6).⁵⁶

Figure 4. Lateral cephalogram of Crouzon syndrome

1. High atlas (C1) position
2. Block vertebrae C2, C3, C4 and C5, C6.

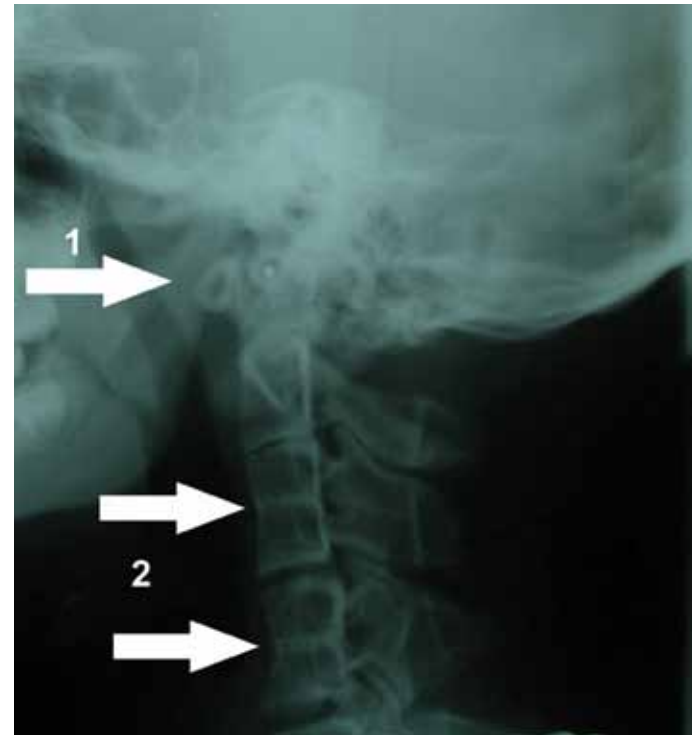
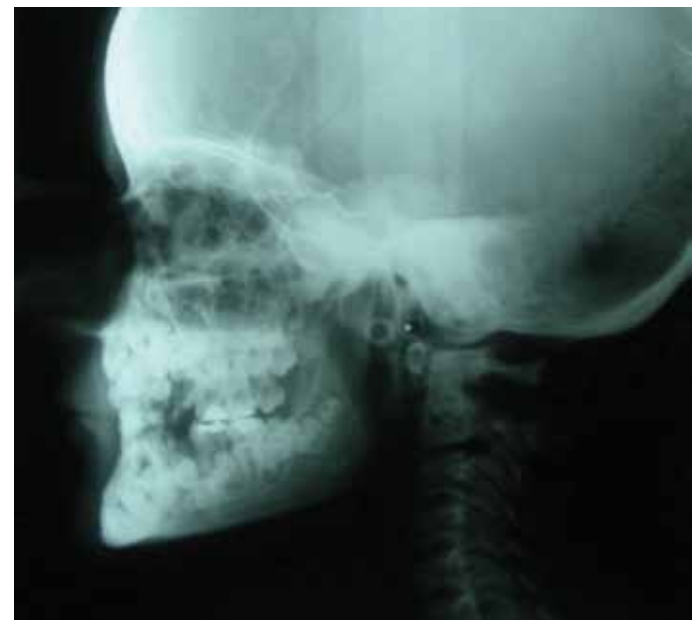

Figure 5. Lateral cephalogram of Cleidocranial dysplasia.



CASE REPORT 3

A 13-year-old girl with Treacher Collins syndrome was seeking orthodontic treatment at the Clinic of Orthodontics, School of Dental Medicine, University of Belgrade. The same standard diagnostic procedures were conducted (Table 1). Written informed consent was obtained from the patient's guardian for publication of this case report and accompanying images.

The most characteristic findings on cranium were the absence of the zygomatic bones and poor development of anterior cranial base. Additionally, according to standards for that age, we noticed mandibular retrognathism and skeletal Class II. Posterior maxillary plane and higher posterior mandibular plane inclinations caused skeletal open bite (Table 2). Decreased values of craniofacial parameters, such as anterior and posterior facial height, maxillary, mandibular and ramus length, contribute to patient's convex profile (Figure 7). Cervicovertebral morphology is characterized with C2-C3 and C6-C7 intervertebral fusions. They were like "block vertebrae" fusions with complete fusions between vertebral bodies and neural arches (Figure 8).

Figure 7. Lateral cephalogram of Treacher Collins syndrome.

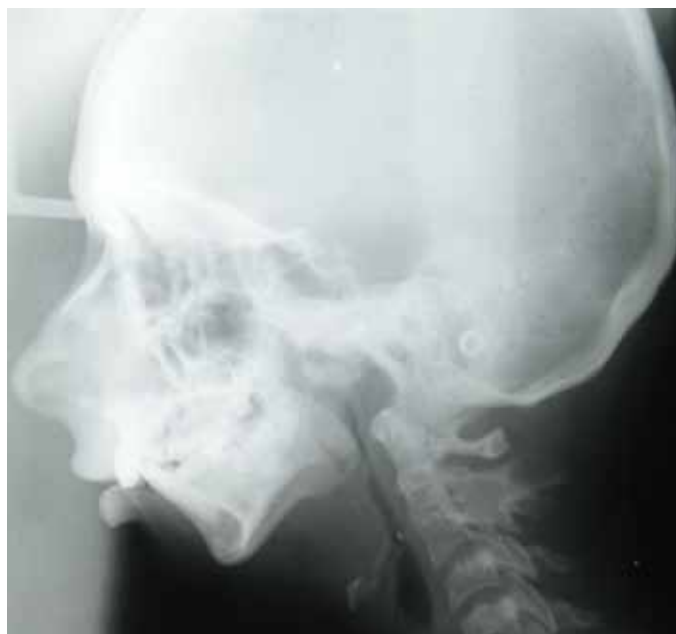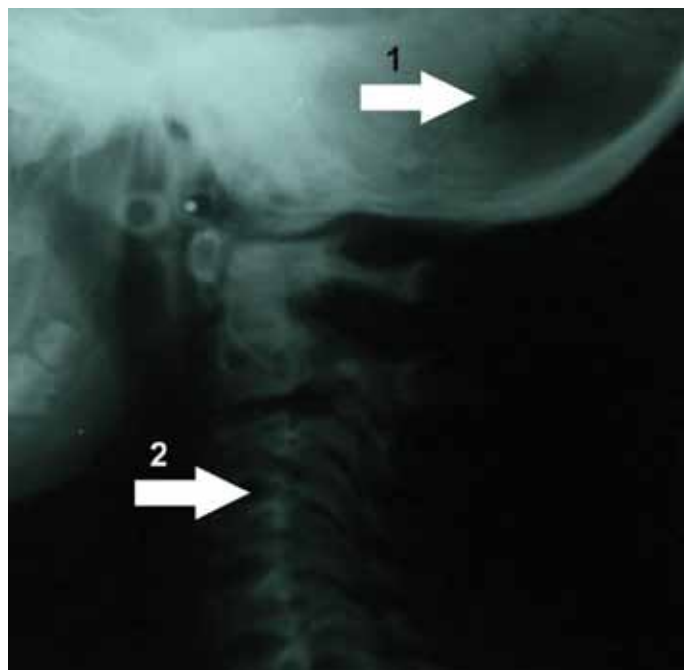


Figure 8. Lateral cephalogram of Treacher Collins syndrome
1. Block vertebrae C2-C3.

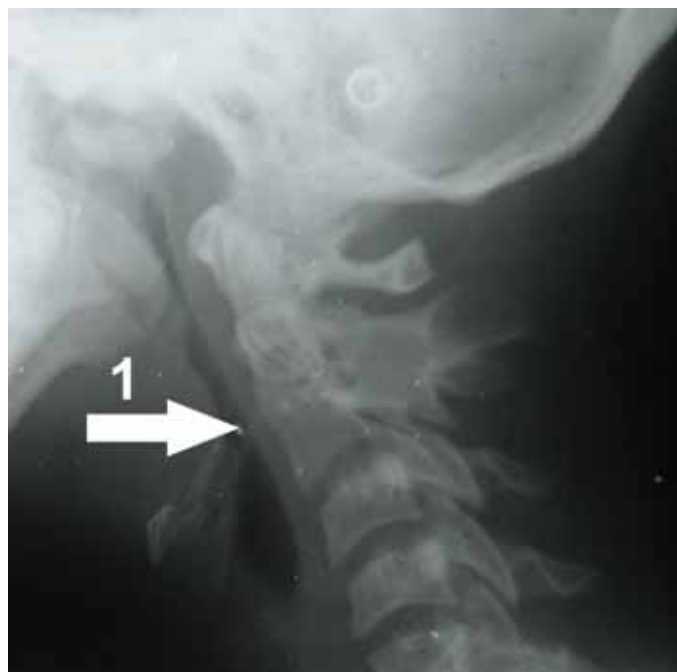

Figure 6. Lateral cephalogram of Cleidocranial dysplasia

1. Wormian bones
2. Delayed mineralization.



DISCUSSION

In these reports, an attempt has been made to emphasize the deviations of normal craniofacial and cervicovertebral morphology in patients with different genetic syndromes. Deviations of the craniofacial and cervical system in genetic syndromes are the result of changes during the embryonic or fetal period. Many muscle and skeletal structure derive from neural crest, so affection of neural crest cells leads to craniofacial and

cervicovertebral morphology deformities. Also, the early splicing suture between the cranium and facial bones leads to disturbances in the growth, especially in the middle third of the face.

Patients with genetic syndromes were characterized with varied skeletal craniofacial and cervicovertebral morphology. The patterns of spinal anomalies were variable, suggesting that the underlying genetic mutation has variable expressivity in cervical spine development as it does elsewhere in the craniofacial

skeleton. All three patients whose cases that are presented in this paper, first appeared at the Clinic of Orthodontics for orthodontic treatment, after previous treatment by other medical specialties. In these case of Crouzon syndrome, changes in the development caused the insufficient growth of the cranial base and the midface which results in relative mandibular prognathism and gave the effect of the patient's concave face. In the case of Treacher Collins syndrome absent of the zygomatic bone, poor development of anterior cranial base, anterior and posterior facial height, maxillary, mandibular and ramus length, also posterior maxillary plane and higher posterior mandibular plane inclinations caused skeletal open bite and contributed to convex patient's profile. Midfacial hypoplasia and anterior facial growth rotation led to a small face phenotype in the case of Cleidocranial dysplasia. In these cases of Crouzon and Treacher Collins syndrome cervicovertebral morphology is characterized with intervertebral fusions. They were like "block vertebrae" fusions with complete fusions between vertebral bodies and neural arches, while in the case of Cleidocranial dysplasia cervicovertebral complex is characterized by delayed mineralization of vertebral bodies. Findings of the craniofacial and cervicovertebral anomalies presented in these reports are in line with the previously reported results.^{10,14,19,54,57,58} Nevertheless, the most characteristic finding of cervicovertebral morphology was the presence of cervical spine fusions. The fusions of the cervical spine were observed in all three case reports. Regarding the diagnostic procedures it is necessary to distinguish one syndrome from other related disorders. Differential diagnosis of CS is made with the syndromes of Apert, Pfeiffer, Carpenter and Saethre-Clotzen syndrome. Apert syndrome is a distinct craniosynostosis because of its characteristic malformations of the hands and feet, with symmetric syndactyly that involves the second, third and fourth digit.⁵⁹ Pfeiffer syndrome shows craniosynostosis, broad thumb and great toes, both possessing a valgus deformity, cardiovascular malformations and soft-tissue syndactyly of hand and feet. Further determinations can be done by measuring the angles between these extended digits.⁶⁰ Carpenter syndrome also shows syndactyly, heart defects and craniosynostosis but mental retardation is seen in nearly all cases.⁶¹ Saethre-Clotzen syndrome is a mild form of congenital bone deformation with craniosynostosis, low set frontal hair line, parrot-beaked nose, variable facial symmetry and brachydactyly. Saethre-Clotzen syndrome does not have the syndactyly feature of Apert and the ptosis and hypertelorism are less expressed than in Crouzon syndrome.^{62,63}

Other conditions share some characteristics with CCD. The differential diagnosis of CCD includes Crane-Heise syndrome, Yunis Varon syndrome, CDAGS syndrome, mandibuloacral dysplasia, pycnodysostosis, etc. These anomalies have affected similar skeletal elements as CCD. This could suggest that some of these conditions may result from mutation of genes that affect the action of RUNX2 on its downstream targets.⁶⁴ On the other hand, these are all autosomal recessive disorders and have other specific features.³⁰

Crane-Heise syndrome is a rare autosomal recessive disorder characterized by a large head, poorly mineralized calvarium, cleft lip and palate, low-set dysplastic ears, hypoplastic clavicles and scapulae, agenesis of some cervical vertebrae, and genital hypoplasia.⁶⁵ The clinical features of Yunis Varon syndrome include prenatal growth deficiency, wide-open fontanels and sutures, unusual mineralization of the skull, and hypoplastic clavicles. The thumbs and great toes are hypoplastic or absent. It is characterized with autosomal recessive inheritance. This syndrome is caused by mutation of (Factor-Induced Gene) FIG4 genes, which encodes a phosphoinositide phosphatase.⁶⁶ CDAGS syndrome is characterized by craniosynostosis, delayed closure of the fontanels, cranial defects, clavicular hypoplasia, anal and genitourinary malformations, and skin eruption. It brings together the apparently opposing pathophysiologic and developmental processes of accelerated suture closure and delayed ossification. Inheritance is autosomal recessive.⁶⁷ Mandibuloacral dysplasia is also inherited autosomal recessive disorder usually associated with mutation of (lamin A/C) LMNA or (Zinc Metallopeptidase STE24) ZMPSTE24 genes. It is characterized by short stature, delayed closure of cranial sutures, mandibular hypoplasia, and dysplastic clavicles. The skin is atrophic with decreased subcutaneous fat. Several individuals developed a hyperpigmented rash over the trunk and hyperkeratotic papular lesions of the extremities.⁶⁸

Pycnodysostosis (PYCD) is caused by pathogenic variants in the gene that encodes cathepsin K, a lysosomal protease excreted by the osteoclasts for bone matrix degradation. PYCD is characterized by short stature, osteopetrosis with increased bone fragility, short terminal phalanges, and failure of closure of the cranial sutures with persistence of an open fontanel. It shares the similar way of inheritance as above mentioned disorders.⁶⁹

A number of conditions exhibit phenotypic overlap with TCS. Differential diagnosis of TCS includes acrofacial dysostosis (Nager and Miller syndrome) and oculoauriculovertebral spectrum (hemifacial microsomia and Goldenhar syndrome). Nager syndrome has similar facial features to TCS, particularly in the region of the eyes that are down slanting with a deficiency of eyelashes. On the other hand, preaxial limb abnormalities, hypoplastic, aplastic or duplicated thumbs and fused ulna and radius are a consistent features of Nager syndrome.⁷⁰ Miller syndrome also has similar features as TCS with the additional diagnostic feature of ectropion or out turning of the lower lids. In addition, some patients may exhibit congenital heart defects.⁷¹⁻⁷³ Hemifacial microsomia primarily affects the development of the ear, mouth and mandible, while Goldenhar syndrome shows vertebral abnormalities, epibulbar dermoids and facial deformities.⁷⁴

Management of craniofacial syndromes is aimed at the specific needs of each individual. In general, it is a multidisciplinary approach that requires a myriad of surgical, medical and psychosocial interventions.¹³ Early treating of Crouzon syndrome

usually starts in early infancy with treatment of prioritizes including airway management and offsetting elevated intracranial pressure. It is recommended to perform the craniostomy at 3-6 month of age to allow for remodeling and reshaping of the cranial cavity. This early interventions serve as means of improving cranial and facial esthetics and offsets the morbidity associated with elevated intracranial pressure.⁷⁵ Distraction of the hypoplastic midface follows craniostomy repair and traditionally occurs between 4 and 8 years of age, with some adolescent patients requiring readvancement (9-12 years of age) with Le Fort II osteotomy or monoblock advancement by distraction osteogenesis. Maxillary hypoplasia yields dental crowding and class III malocclusion, which can persist even after midface advancement. Thus, corrective treatment of midface hypoplasia improves exophthalmos as well as dental occlusion.⁷⁶ Later interventions are tailored toward management of obstructive sleep apnea, malocclusion, speech and language pathology evaluation and consultation with psychological counselors.¹³

The dental management of individuals with CCD is challenging and involves comprehensive orthodontic and surgical treatments.¹⁹ The four main therapeutic approaches reported in the literature are the Toronto-Melbourne, Belfast-Hamburg, Jerusalem, and Bronx methods.¹⁴ In all methods, management commences depends on the stage of root development of the underlying permanent teeth. Toronto-Melbourne approach is based on serial surgical procedures in general anesthesia and it consists of extraction of deciduous and supernumerary teeth.^{77,78} The Belfast-Hamburg method advocates only a single surgical procedures in general anesthesia to extract all retained deciduous and supernumerary teeth. After wound healing is complete, orthodontic appliance is used to promote further eruption of permanent teeth.⁷⁹ The Jerusalem approach involves at least 2 surgical interventions in different periods of childhood.⁸⁰ The specificity of the Bronx approach is that the natural eruption of the permanent teeth orthodontic appliances are used to bring the teeth into occlusion. Additionally, a Le Forte I osteomy-orthognathic procedure is performed and dental implants are placed.⁸¹

The protocol for the management of TCS can be divided into three epochs. It is important to anticipate staged treatment throughout early neonatal life, childhood and late adolescence. From birth to age of 2, early priorities are focused on airway management, feeding and growth. From age 2 to 12 years, speech therapy and reconstruction of the upper face is performed either with bone grafts or with vascularized bone flaps. This subsequent management of hard and soft tissues typically requires multiple surgeries, and initially eyelid coloboma and palatal clefting are corrected in the earliest years of life. This is followed by orbital reconstruction at about 5-7 years of age when most of the eye socket growth is complete and mandibular distraction or maxilla-mandibular osteotomies may be performed around the same time. Reconstruction of the external and inner ear usually can be attempted at around age of 6 years. In addition, implantation of appropriate bone-anchored conductive hearing

devices improves hearing loss in TCS patients. From age 13 to 18 years orthognathic surgery with further revision or bone grafting should be performed. It is recommended that orthodontic and dental corrections should be undertaken once definitive skeletal repair is finalized.^{33,34,44,49,82}

Clinical examination allows observing many craniofacial changes of these syndromes, but many abnormalities of the cervical spine do not manifest themselves symptomatically until adolescence or young adulthood. The cervical spine anomalies can be divided into syndromic and nonsyndromic malformations. Vastardis and Evans⁸³ described several cervical spine anomalies that can be found in relation to different syndromes. In addition, they reported that nonsyndromic anomalies usually include changes due to infection, inflammation, and/or fractures. The cervical spine area present in lateral cephalograms is omitted in cephalometric tracings. Unfortunately, radiographic abnormalities of the cervical spine do not always signal their existence. Neck pain, tenderness, limitation of neck mobility, poor reflexes or strength, and loss of sensation may or may not accompany a cervical pathologic disorder.⁸⁴ Orthodontists do not have to be experts in cervical vertebrae abnormalities, but they must be aware of the standard radiological anatomy of the cervical spine on the lateral cephalogram. The cervical spine is vital due to the specific anatomical structure. The neck is the most mobile part of the spine and has an important role in maintaining an optimum position of the head and neck. A prerequisite for the normal function of each part of the spine is the anatomical integrity of all parts, including the cervical morphology. The orthodontist may be the first who detect some of these problems and enable timely identification of these changes and improved quality of life of these patients.

CONCLUSION

Morphological alterations in patients with different genetic syndromes constitute the primary cause of functional disorders. The limitation of cervical range of motion resultant from these anomalies may have clinical significance concerning multidisciplinary management approach in these patients. Treating craniofacial and cervicovertebral deformities in genetic syndromes through comprehensive, well-coordinated and integrated strategies can provide satisfactory management of individual conditions. Recent progress in dentistry resulted in better diagnostic and therapeutic options and outcomes for individuals with genetic syndromes. It is expected that this information will help the practitioners develop a basis for improving treatment strategies for the management of these very challenging conditions.

ACKNOWLEDGMENTS

Supported by grant #175075 from the Ministry of Education, Science and Technological Development of the Republic of Serbia. We thank to Mr. Nenad Tešić for technical support during the preparation of the manuscript.

REFERENCES

1. Hemmer KM, McAlister WH, Marsh JL. Cervical spine anomalies in the craniosynostosis syndromes. *Cleft Palate J*. 1987;24(4):328-33.
2. Gorlin RJ, Cohen MM Jr, Hennekam RCM. *Syndromes of the head and neck*. 4th ed. Oxford, UK: Oxford University Press; 2001;306-10.
3. Bonaventure J, El Ghouzzi V. Molecular and cellular bases of syndromic craniosynostoses. *Expert Rev Mol Med*. 2003;5(4):1-17.
4. Crouzon O. Dysostose cranio-faciale héréditaire. *Bull Mem Soc Med Hop Paris*. 1912;33:545-55. French.
5. Cohen MM Jr, Kreiborg S. Birth prevalence studies of the Crouzon syndrome: comparison of direct and indirect methods. *Clin Genet*. 1992;41(1):12-5.
6. Mohan RS, Vemanna NS, Verma S, Agarwal N. Crouzon syndrome: clinico-radiological illustration of a case. *J Clin Imaging Sci*. 2012;2:70.
7. Giordano BP, Tuli SS, Ryan SF, Stern M, Tuli SY. Crouzon syndrome: Visual Diagnosis. *J Pediatr Health Care*. 2015.
8. Derderian C, Seaward J. Syndromic craniosynostosis. *Semin Plast Surg*. 2012;26(2):64-75.
9. Cohen MM Jr. Etiopathogenesis of craniosynostosis. *Neurosurg Clin N Am*. 1991;2(3):507-13.
10. Trainor PA, Andrews BT. Facial dysostoses: Etiology, pathogenesis and management. *Am J Med Genet C Semin Med Genet*. 2013;163C(4):283-94.
11. Gault DT, Renier D, Marchac D, Jones BM. Intracranial pressure and intracranial volume in children with craniosynostosis. *Plast Reconstr Surg*. 1992;90(3):377-81.
12. Reardon W, Winter RM, Rutland P, Pulleyn LJ, Jones BM, Malcolm S. Mutations in the fibroblast growth factor receptor 2 gene cause Crouzon syndrome. *Nat Genet*. 1994;8(1):98-103.
13. Helman SN, Badhey A, Kadakia S, Myers E. Revisiting Crouzon syndrome: reviewing the background and management of a multifaceted disease. *Oral Maxillofac Surg*. 2014;18(4):373-9.
14. Roberts T, Stephen L, Beighton P. Cleidocranial dysplasia: a review of the dental, historical, and practical implications with an overview of the South African experience. *Oral Surg Oral Med Oral Pathol Oral Radiol*. 2013;115(1):46-55.
15. Lee C, Jung HS, Baek JA, Leem DH, Ko SO. Manifestation and treatment in a cleidocranial dysplasia patient with a RUNX2 (T420I) mutation. *Maxillofac Plast Reconstr Surg*. 2015;37(1):41.
16. Meckel JF. Cited by Siggers CD. Cleidocranial dysostosis. *Dev Med Child Neurol*. 1975;17:552-4.
17. The classic: Marie, P., and Sainton P.: Sur la dysostose cleido-cranienne hereditaire. *Rev. neurol*. 6:835, 1898. On hereditary cleido-cranial dysostosis. *Clin Orthop Relat Res*. 1968;58:5-7.
18. Rimoin DL. International Nomenclature of Constitutional Diseases of Bone: revision-May, 1977. *Birth Defects Orig Artic Ser*. 1978;14(6B):39-45.
19. Park TK, Vargervik K, Oberoi S. Orthodontic and surgical management of cleidocranial dysplasia. *Korean J Orthod*. 2013;43(5):248-60.
20. Suda N, Hattori M, Kosaki K, Banshodani A, Kozai K, Tanimoto K, Moriyama K. Correlation between genotype and supernumerary tooth formation in cleidocranial dysplasia. *Orthod Craniofac Res*. 2010;13(4):197-202.
21. Yoda S, Suda N, Kitahara Y, Komori T, Ohyama K. Delayed tooth eruption and suppressed osteoclast number in the eruption pathway of heterozygous Runx2/Cbfa1 knockout mice. *Arch Oral Biol*. 2004;49(6):435-42.
22. Angle AD, Rebellato J. Dental team management for a patient with cleidocranial dysostosis. *Am J Orthod Dentofacial Orthop*. 2005;128(1):110-7.
23. Mundlos S, Otto F, Mundlos C, Mulliken JB, Aylsworth AS, Albright S, et al. Mutations involving the transcription factor CBFA1 cause cleidocranial dysplasia. *Cell*. 1997;89(5):773-9.
24. Blyth K, Vaillant F, Jenkins A, McDonald L, Pringle MA, Huser C, Stein T, Neil J, Cameron ER. Runx2 in normal tissues and cancer cells: A developing story. *Blood Cells Mol Dis*. 2010;45(2):117-23.
25. Ducey P, Zhang R, Geoffroy V, Ridall AL, Karsenty G. Osf2/Cbfa1: a transcriptional activator of osteoblast differentiation. *Cell*. 1997;89(5):747-54.
26. Yamashiro T, Aberg T, Levanon D, Groner Y, Thesleff I. Expression of Runx1, -2 and -3 during tooth, palate and craniofacial bone development. *Mech Dev* 2002;119:Suppl1:S107-10.
27. Otto F, Kanegane H, Mundlos S. Mutations in the RUNX2 gene in patients with cleidocranial dysplasia. *Hum Mutat*. 2002;19(3):209-16.
28. Machuca-Tzili L, Monroy-Jaramillo N, González-del Angel A, Kofman-Alfaro S. New mutations in the CBFA1 gene in two Mexican patients with cleidocranial dysplasia. *Clin Genet*. 2002;61(5):349-53.
29. Yoshida T, Kanegane H, Osato M, Yanagida M, Miyawaki T, Ito Y, Shigesada K. Functional analysis of RUNX2 mutations in Japanese patients with cleidocranial dysplasia demonstrates novel genotype-phenotype correlations. *Am J Hum Genet*. 2002;71(4):724-38.
30. Mendoza-Londono R, Lee B. Cleidocranial Dysplasia. In: Pagon RA, Adam MP, Ardigen HH, et al., editors. *GeneReviews*® [Internet]. Seattle (WA): University of Washington, Seattle; 1993-2016. Available from: <http://www.ncbi.nlm.nih.gov/books/NBK1513/>.
31. Positional cloning of a gene involved in the pathogenesis of Treacher Collins syndrome. The Treacher Collins Collaborative Group. *Nat Genet* 1996;12(2):130-6.
32. Dixon MJ. Treacher Collins syndrome. *Hum Mol Genet*. 1996;5Spec No:1391-6.
33. Chang CC, Steinbacher DM. Treacher Collins syndrome. *Semin Plast Surg*. 2012;26(2):83-90.
34. Trainor PA, Dixon J, Dixon MJ. Treacher Collins syndrome: etiology, pathogenesis and prevention. *Eur J Hum Genet*. 2009;17(3):275-83.
35. Beaune L, Forrest CR, Keith T. Adolescents' perspectives on living and growing up with Treacher Collins syndrome: a qualitative study. *Cleft Palate Craniofac J*. 2004;41(4):343-50.
36. Scully C, Langdon J, Evans J. Marathon of eponyms: 20 Treacher Collins syndrome. *Oral Dis*. 2011;17(6):619-20.
37. Collins ET. Cases with symmetrical congenital notches in the outer part of each lid and defective development of the malar bones. *Trans Ophthalmol Soc U K*. 1900;20:190-2.
38. Franceschetti A, Klein D. The mandibulofacial dysostosis; a new hereditary syndrome. *Acta Ophthalmol (Copenh)*. 1949;27(2):143-224.
39. Posnick JC, al-Qattan MM, Moffat SM, Armstrong D. Cranio-orbitozygomatic measurements from standard CT scans in unoperated Treacher Collins syndrome patients: comparison with normal controls. *Cleft Palate Craniofac J*. 1995;32(1):20-2.
40. Chong DK, Murray DJ, Britto JA, Tompson B, Forrest CR, Phillips JH. A cephalometric analysis of maxillary and mandibular parameters in Treacher Collins syndrome. *Plast Reconstr Surg*. 2008;121(3):77e-84e.
41. Steinbacher DM, Bartlett SP. Relation of the mandibular body and ramus in Treacher Collins syndrome. *J Craniofac Surg*. 2011;22(1):302-5.
42. da Silva Dalben G, Costa B, Gomide MR. Prevalence of dental anomalies, ectopic eruption and associated oral malformations in subjects with Treacher Collins syndrome. *Oral Surg Oral Med Oral Pathol Oral Radiol Endod*. 2006;101(5):588-92.

43. Renju R, Varma BR, Kumar SJ, Kumaran P. Mandibulofacial dysostosis (Treacher Collins syndrome): A case report and review of literature. *Contemp Clin Dent*. 2014;5(4):532-4.
44. Mehrotra D, Hasan M, Pandey R, Kumar S. Clinical spectrum of Treacher Collins syndrome. *J Oral Biol Craniofac Res*. 2011;1(1):36-40.
45. Hertle RW, Ziylan S, Katowitz JA. Ophthalmic features and visual prognosis in the Treacher-Collins syndrome. *Br J Ophthalmol*. 1993;77(10):642-5.
46. Buchanan EP, Xue AS, Hollier LH Jr. Craniofacial syndromes. *Plast Reconstr Surg*. 2014;134(1):128e-153e.
47. Phelps PD, Poswillo D, Lloyd GA. The ear deformities in mandibulofacial dysostosis (Treacher Collins syndrome). *Clin Otolaryngol Allied Sci*. 1981;6(1):15-28.
48. Dauwerse JG, Dixon J, Seland S, Ruivenkamp CA, van Haeringen A, Hoefsloot LH, et al. Mutations in genes encoding subunits of RNA polymerases I and III cause Treacher Collins syndrome. *Nat Genet*. 2011;43(1):20-2.
49. Kadakia S, Helman SN, Badhey AK, Saman M, Ducic Y. Treacher Collins Syndrome: the genetics of a craniofacial disease. *Int J Pediatr Otorhinolaryngol*. 2014;78(6):893-8.
50. Wise CA, Chiang LC, Paznekas WA, Sharma M, Musy MM, Ashley JA, et al. TCOF1 gene encodes a putative nucleolar phosphoprotein that exhibits mutations in Treacher Collins Syndrome throughout its coding region. *Proc Natl Acad Sci U S A*. 1997;94(7):3110-5.
51. Sakai D, Trainor PA. Treacher Collins syndrome: unmasking the role of Tcof1/treacle. *Int J Biochem Cell Biol*. 2009;41(6):1229-32.
52. Conte C, D'Apice MR, Rinaldi F, Gambardella S, Sangiuolo F, Novelli G. Novel mutations of TCOF1 gene in European patients with Treacher Collins syndrome. *BMC Med Genet*. 2011;12:125.
53. McKay SD, Al-Omari A, Tomlinson LA, Dormans JP. Review of cervical spine anomalies in genetic syndromes. *Spine (Phila Pa 1976)*. 2012;37(5):E269-77.
54. Pun AH, Clark BE, David DJ, Anderson PJ. Cervical spine in Treacher Collins syndrome. *J Craniofac Surg*. 2012;23(3):e218-20.
55. Martins RB, de Souza RS, Giovanni EM. Cleidocranial dysplasia: report of six clinical cases. *Spec Care Dentist*. 2014;34(3):144-50.
56. Golan I, Baumert U, Hrala BP, Müssig D. Early craniofacial signs of cleidocranial dysplasia. *Int J Paediatr Dent* 2004;14(1):49-53.
57. Anderson PJ, Hall C, Evans RD, Harkness WJ, Hayward RD, Jones BM. The cervical spine in Crouzon syndrome. *Spine (Phila Pa 1976)*. 1997;22(4):402-5.
58. Kreiborg S, Barr M Jr, Cohen MM Jr. Cervical spine in the Apert syndrome. *Am J Med Genet*. 1992;43(4):704-8.
59. Cohen MM Jr, Kreiborg S, Lammer EJ, Cordero JF, Mastroiaco P, Erickson JD, et al. Birth prevalence study of the Apert syndrome. *Am J Med Genet*. 1992;42(5):655-9.
60. Cohen MM Jr. Pfeiffer syndrome update, clinical subtypes, and guidelines for differential diagnosis. *Am J Med Genet*. 1993;45(3):300-7.
61. Hidestrand P, Vasconez H, Cottrill C. Carpenter syndrome. *J Craniofac Surg*. 2009;20(1):254-6.
62. Pantke OA, Cohen MM Jr, Witkop CJ Jr, Feingold M, Schaumann B, Pantke HC, et al. The Saethre-Chotzen syndrome. *Birth Defects Orig Artic Ser*. 1975;11(2):190-225.
63. Sharma A, Patel N, Arora S, Ramachandran R. Child with Saethre-Chotzen syndrome: anesthetic management and literature review. *Acta Anaesthesiol Belg*. 2014;65(4):179-82.
64. Goto T, Aramaki M, Yoshihashi H, Nishimura G, Hasegawa Y, Takahashi T, et al. Large fontanells are a shared features of haploinsufficiency of RUNX2 and its coactivator CBFβ. *Congenit Anom (Kyoto)*. 2004;44(4):225-9.
65. Petit F, Devisme L, Toutain A, Houfflin-Debarge V, Dieux-Coeslier A, Manouvrier-Hanu S, et al. Crane-Heise syndrome: two further case reports. *Eur J Med Genet*. 2011;54(2):169-72.
66. Campeau PM, Lenk GM, Lu JT, Bae Y, Burrage L, Turnpenney P, et al. Yunis-Varón syndrome is caused by mutations in FIG4, encoding a phosphoinositide phosphatase. *Am J Hum Genet*. 2013;92(5):781-91.
67. Mendoza-Londono R, Lammer E, Watson R, Harper J, Hatamochi A, Hatamochi-Hayashi S, et al. Characterization of a new syndrome that associates craniosynostosis, delayed fontanel closure, parietal foramina, imperforate anus, and skin eruption: CDAGS. *Am J Hum Genet*. 2005;77(1):161-8.
68. Slimani S, Megateli I, Ladjouze-Rezig A. Mandibuloacral dysplasia. *Joint Bone Spine*. 2014;81(3):263.
69. Farronato G, Salvadori S, Nolet F, Borgonovo A, Esposito L. Pycnodysostosis: review and case report. *Minerva Stomatol*. 2014;63(6):229-37. English, Italian.
70. Chemke J, Mogilner BM, Ben-Itzhak I, Zurkowski L, Ophir D. Autosomal recessive inheritance of Nager acrofacial dysostosis. *J Med Genet*. 1988;25(4):230-2.
71. Ogilvy-Stuart AL, Parsons AC. Miller syndrome (postaxial acrofacial dysostosis): further evidence for autosomal recessive inheritance and expansion of the phenotype. *J Med Genet*. 1991;28(10):695-700.
72. Verrotti C, Benassi G, Piantelli G, Magnani C, Giordano G, Gramellini D. Acrofacial dysostosis syndromes: a relevant prenatal dilemma. A case report and brief literature review. *J Matern Fetal Neonatal Med*. 2007;20(6):487-90.
73. Wiczorek D. Human facial dysostoses. *Clin Genet*. 2013;83(6):499-510.
74. Gorlin RJ, Cohen MM Jr, Levin S. *Syndromes of the head and neck*. 3rd ed. New York: Oxford University Press; 1990. p.649-52.
75. Yamaguchi K, Imai K, Fujimoto T, Takahashi M, Maruyama Y, Sakamoto H, et al. Cranial distraction osteogenesis for syndromic craniosynostosis: long-term follow-up and effect on postoperative cranial growth. *J Plast Reconstr Aesthet Surg*. 2014;67(2):e35-41.
76. Lee DW, Ham KW, Kwon SM, Lew DH, Cho EJ. Dual midfacial distraction osteogenesis for Crouzon syndrome: long-term follow-up study for relapse and growth. *J Oral Maxillofac Surg*. 2012;70(3):e242-51.
77. Smylski PT, Woodside DG, Harnett BE. Surgical and orthodontic treatment of cleidocranial dysostosis. *Int J Oral Surg*. 1974;3(6):380-5.
78. Hall RK, Hyland AL. Combined surgical and orthodontic management of the oral abnormalities in children with cleidocranial dysplasia. *Int J Oral Surg*. 1978;7(4):267-73.
79. Richardson A, Swinson T. Combined orthodontic and surgical approach to cleidocranial dysostosis. *Trans Eur Orthod Soc*. 1987;62:23.
80. Becker A, Shteyer A, Bimstein E, Lustmann J. Cleidocranial dysplasia: Part 2--Treatment protocol for the orthodontic and surgical modality. *Am J Orthod Dentofacial Orthop*. 1997;111(2):173-83.
81. Berg RW, Kurtz KS, Watanabe I, Lambrakos A. Interim prosthetic phase of multidisciplinary management of cleidocranial dysplasia: „the Bronx Approach“. *J Prosthodont*. 2011;20 Suppl 2:S20-5.
82. Thompson JT, Anderson PJ, David DJ. Treacher Collins syndrome: protocol management from birth to maturity. *J Craniofac Surg*. 2009;20(6):2028-35.
83. Vastardis H, Evans CA. Evaluation of cervical spine abnormalities on cephalometric radiographs. *Am J Orthod Dentofacial Orthop*. 1996;109(6):581-8.
84. Orenstein JB, Klein BL, Ochsenschlager DW. Delayed diagnosis of pediatric cervical spine injury. *Pediatrics* 1992;89(6 Pt 2):1185-8.
85. Broadbent BH, Broadbent BH Jr, Golden WH. *Bolton standards of dentofacial developmental growth*. 1st ed. Saint Louis: C.V. Mosby; 1975.