

ELECTROCARDIOGRAPHIC CHANGES  
FOLLOWING BITES AND STINGS  
OF VENOMOUS ANIMALS

Z. MARETIĆ

Medical Centre, Pula

(Received for publication July 6, 1982)

Data on the effects of certain animal venoms on the ECG in men and experimental animals are presented. The *Latrodectus* bites in humans caused sinus bradycardia, high P waves in II and III leads, flattened T-waves, and a prolonged QTc-interval. In guinea pigs Wenckebach's phenomenon was observed. Negative T-waves including atrioventricular block I degree were also seen after envenomation of guinea pigs with the venoms of the spiders *Steatoda paykulliana* and *Pterinochilus* sp. In guinea pigs injected with the venom of the scorpion *Mesobuthus gibbosus* sinus bradycardia, Wenckebach's phenomenon, elevated ST-intervals and atrioventricular dissociation were seen. Following stings of *Hymenoptera* in humans, a wandering pacemaker, negative T-waves and slow ventricular tachycardia were observed. Weeverfish and scorpionfish stings in some patients resulted in an atrioventricular block I degree. After the injuries by the sea anemone *Anemonia sulcata*, the jelly-fish *Pelagia noctiluca*, *Scelopendra cingulata*, Tabanids and *Vipera ammodytes* no significant ECG changes were registered.

The effects of animal toxins on the cardiovascular system particularly in man, are not well understood. Envenomation by animals may involve cardiovascular damage which may lead to death. Thus, the ECG changes provoked by venoms are of fundamental importance, particularly in an area like Istria, Yugoslavia, which has an abundant fauna of venomous animals, of perhaps more than 25 species.

SUBJECTS, MATERIAL AND METHODS

During the period between 1953 and 1981 approximately 2 400 patients who had been bitten or stung by various venomous animals were seen. In most of them standard and precordial ECG tracings were taken. Control ECGs were taken after the patients had recovered.

The effects of some animal venoms on the electrocardiograms of guinea pigs were also examined. A total of 74 guinea pigs of 250—360 g body weight of both sexes were used. Envenomation was induced by a direct sting or bite of the animal which was aggravated to provoke a maximum ejection of venom. For weever envenomation mechanical stings by spines were used. ECGs were taken on guinea pigs before as well during the acute phase of intoxication. In guinea pigs only standard leads were studied. In most cases an one-channel »Heillige-Ei Niš« electrocardiograph was used. In most patients one millimetre equals 0.04 s, in guinea pigs 0.02 s.

## RESULTS

### *Latrodectus*

The venom of *Latrodectus tredecimguttatus* is toxic to the nervous system and also acts as a stressor agent on all organs and systems. In one bite *Latrodectus* ejects 0.3—0.5 mg of venom wet weight (1). Hypertension of convergent type is common; however, cardiac symptoms and signs are infrequent. In 11 patients with severe symptoms and signs of latrodectism (pain, oppression in the chest, sweating, muscular rigidity, and hypertension) ECGs were taken during the acute phase of poisoning. Four patients had sinus bradycardia, high P waves in II and III leads, flattened to negative T-waves, and prolonged QT-intervals with a depression of the ST-segment. The QTc-interval was prolonged, once for 0.48 s, with a sinus rhythm of 42/min, and in another patient for 0.38 s with a sinus rhythm of 96/min (2).

In 32 experimental guinea pigs, envenomation by the bite of *Latrodectus*, caused myocardial hyperaemia, occasional parenchymatous degeneration, miliary perivascular haemorrhages and subacute perivascular myocarditis (2, 3, 4).

According to the ECG findings in guinea pigs reported earlier (5), a normal animal showed these values: sinus rhythm about 200/min, P-wave 0.03 s, PQ-interval 0.06 s, QRS-complex 0.02 s, QT-interval 0.14—0.16 s. The T-wave had the shape of a sharp triangle with equal sides. In 24 envenomed animals a sinus rhythm of 96—300/min was found. In two cases, supraventricular extrasystoles were present. QP-interval had a tendency to grow longer, even to 0.20 s, with a sinus rhythm of 120/min. The QRS complex had a tendency to enlarge; the ST-segment was sometimes markedly depressed; the T-wave in 21 animals was flattened to negative in D<sub>1</sub> and D<sub>2</sub> and the QTc-interval was prolonged to 0.26 s in two animals (2). In four animals typical Wenckebach's phenomenon was observed.

### *Other spiders*

ECG changes were noted also after the bites by other spiders. The venom of *Steatoda paykulliana*, from the same family as *Latrodectus*,

produces similar manifestations. However, the quantity of the venom is smaller (0.2—0.3 mg) and the venom is weaker in its effect than that of *Latrodectus* (6). The bites in humans were not observed, but in eight out of 15 guinea pigs intoxicated by direct bites, prolonged PQ-interval, low, even negative T-waves and a depressed ST-segment were observed. On recovery these changes disappeared.

The venom of the East African Mygaliform spider *Pterinochilus sp.* provoked in guinea pig similarly deep T-waves and also sinus bradycardia, 70/min, with the PQ-interval prolonged by 0.20 s. ECG tracings showed changes in five out of nine guinea pigs studied. The signs of intoxication in guinea pigs after a bite of *Pterinochilus*, which contains about 3.25 mg of venom (7), consisted of excitation with vocalization and hair bristling. Dyspnea, salivation, lacrimation, tonic convulsions, ejaculation and paretic and paralytic signs followed. Death occurred within 35 min to 25 h.

The venoms of some scorpions are important due to their effect on the heart. In Yugoslavia those most frequently found are *Euscorpis germanicus*, *E. carpathicus*, and *E. italicus*, whose stings usually do not provoke any significant changes, either in man, or in guinea pigs (8). In addition to these scorpions according to Hadži *Mesobuthus gibbosus* is found in Macedonia and Montenegro (9). Its stings in humans have not been reported in the literature. The picture in envenomed guinea pigs, however, was very dramatic: local signs were insignificant but soon after the bite violent convulsions, jerks, salivation, lacrimation, and ejaculation occurred. Animals died within 15—25 min. However, in guinea pigs injected with about 4.5 mg of the venom, ECG tracings of four animals taken 10 min. after the bite showed a sinus tachycardia of up to 300/min or an extreme sinus bradycardia of up to 34/min, prolongation of the PQ-interval, Wenckebach's phenomenon, atrioventricular dissociation or abnormal final complexes (elevated ST in I and II leads, negative T-waves and prolongation of the QT-interval). Some of the changes were combined and observed in a single animal (10).

Statistics show that the greatest number of fatalities caused by venomous animals are provoked by Hymenoptera. A bee has at least 0.6 mg of venom (11), and a hornet 0.92 mg (12). In our own practice among the 2 400 cases of bites and stings by various venomous animals, there were three deaths following the stings by hornets, and two due to the bites of vipers. According to statistics in USA, of 460 persons who died during the 1950—1959 period from stings of venomous animals 50% of fatalities were caused by *Hymenoptera* stings (13). Following the sting of *Hymenoptera* an intense pain develops locally, and a papule with a white centre surrounded by redness and oedema appears. In hypersensitive persons, in cases of multiple stings, or if the venom penetrates into a blood vessel, there can appear general symptoms and signs, including increased temperature, shivering, nausea, vomiting, urticaria and ana-

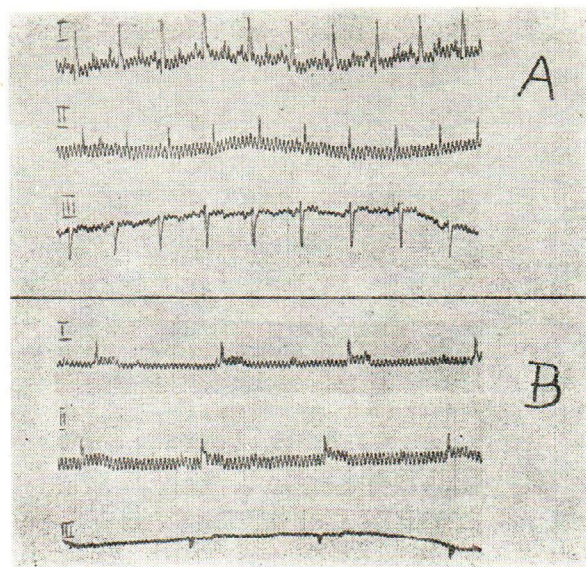


Fig. 1. Above (A): ECG of a healthy guinea pig of 250 g. Below (B): Fifty-three minutes after a sting of *Mesobuthus gibbosus*. To note atrioventricular dissociation along a bradycardia of 5/min and the elevated ST in I and II (1 mm = 0.02 s)

phylactic shock. In our 89 patients, sting by *Hymenoptera* there were 17 (19.1%) pathological ECG curves. Abnormalities included a wandering pacemaker, negative T-waves, ventricular extrasystoles and in a case of a hornet sting, paroxysmal atrial fibrillation.

The tracing of a boy aged 14 stung by a hornet deserves a special consideration. On the record taken immediately after admission to hospital a probable slow ventricular tachycardia was noted. According to his history the boy never suffered from a heart disease or hypersensitivity. He received i. v. twice diphenhydraminehydrochloride 10 mg + calcium bromolaktiobionate 1 g (Dimidril-Calcium Pliva) and twice dexamethasone 14 mg (Dexametason Krka). After 7 h and 35 min his ECG became normal (Fig. 2). Fig. 3. shows the ECG of a girl aged nine, stung in the foot by the wasp *Vespa vulgaris*. A lowered T-wave in  $D_2$  and  $V_5$  was registered, as was a wandering pacemaker, which improved after an intravenous injection of calcium and antihistamine (Dimidril-Calcium Pliva). The girl did not display general symptoms. In both patients the blood pressure was unaffected.

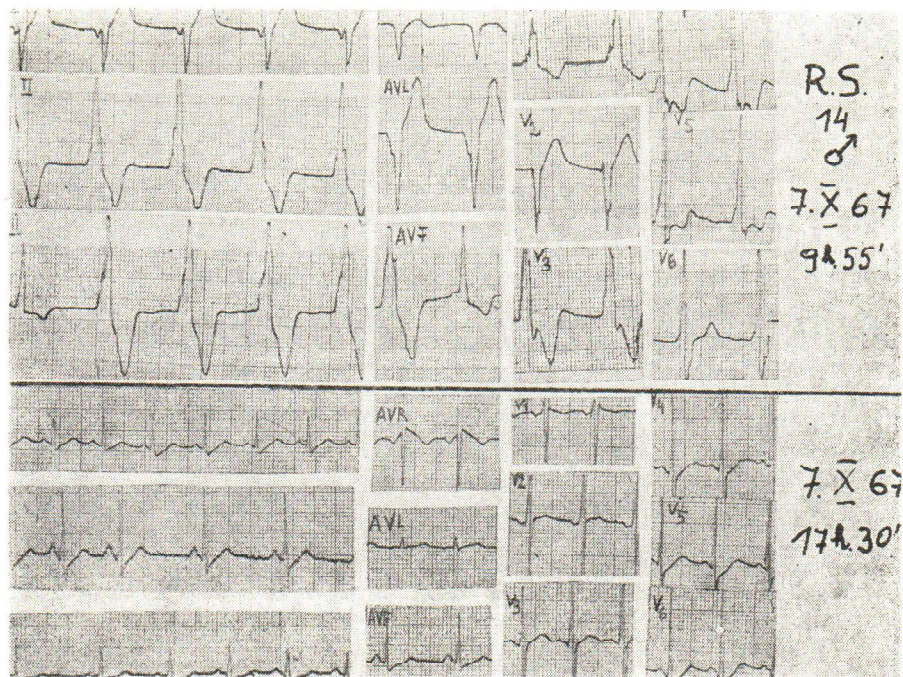


Fig. 2. A probably »slow ventricular tachycardia« in a boy aged 14 stung by a hornet (*Vespa crabro*) in the acute phase of intoxication (above), and (below) a normal electrocardiogram after recovery (1 mm = 0.04 s).

The venoms of some fish may also elicit ECG changes. Our most venomous fish are the weevers (*Trachinus draco*, *T. radiatus*, *T. araneus*, *T. vipera*). Although their stings provoke chiefly severe local signs, with pain, oedema and blisters, they may also elicit a shock. Bradycardia and palpitations have been reported in the literature (14, 15). Among 118 poisoned patients whose ECGs were taken, in 23 (18.6%) the following changes were found: microvoltage, sinus tachycardia, extrasystoles and flattened and negative T-waves. In six of these 118 (5%) a prolongation of the PQ-interval (0.22 s — 0.26 s), with a frequency of 100—60/min, was found (Fig. 4). Of 10 guinea pigs stung in the buttocks with the venomous spines of the dorsum and gill fins, a total atrioventricular block was registered in one guinea pig (Fig. 5).

Patients stung by Adriatic scorpion fish have local signs and symptoms, but to a lesser degree than after weeverfish stings. Of 20 patients stung by scorpionfish (*Scorpeana scrofa*, *S. porcus*) a wandering pace-

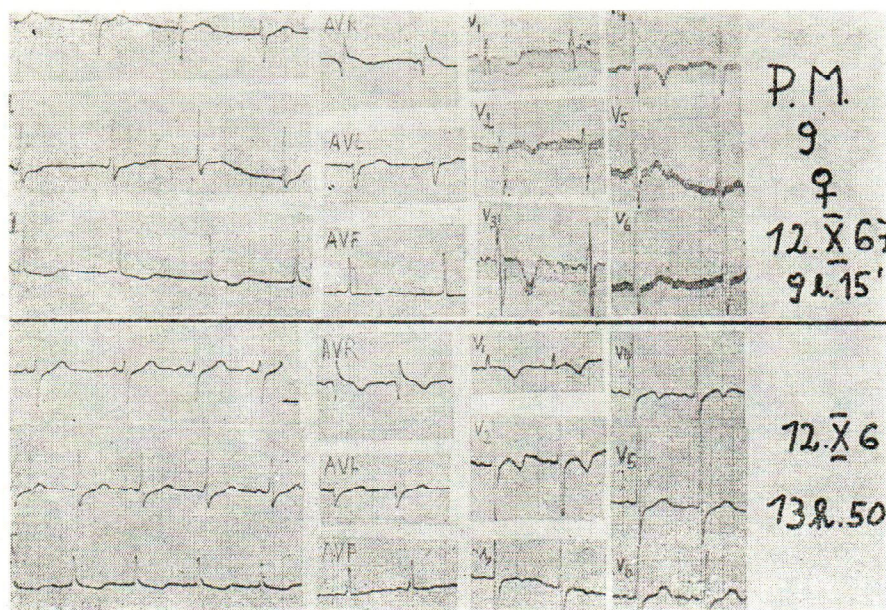


Fig. 3. On the electrocardiogram of a girl aged nine, stung by a wasp (*Vespa vulgaris*) a wandering pacemaker, negative T-waves in  $V_1-V_4$  (above) are seen. Four and a half hours after the treatment (below), the curve became normal (1 mm = 0.04 s)

maker was found in one. In an otherwise healthy boy, aged 16, having only slight local signs on the stung finger, there was a prolongation of PQ to 0.24 s, with a frequency of 60/min. In a woman aged 56, there were markedly lowered ST-segments in  $D_2$  and  $V_6$ .

In two cases of stingray stings (*Trygon thalassis* and *Myliobatis aquila*) with lacerated wounds and local signs, only a low or biphasic T-wave in  $D_2$  was seen. In four other patients stung by these fish, ECG tracings were normal.

Snakes are generally considered to be medically the most important venomous animals, though in our 107 patients bitten by *Vipera ammodytes ammodytes* few significant ECG changes were seen with the exception of flattened T-waves in a few cases.

Following stings by *Anemonia sulcata*, the jelly-fish *Pelagia noctiluca* and bites by *Scolopendra cingulata* and Tabanids no significant changes were found in the ECG taken from groups of at least 20 patients bitten or stung by each of these animals.

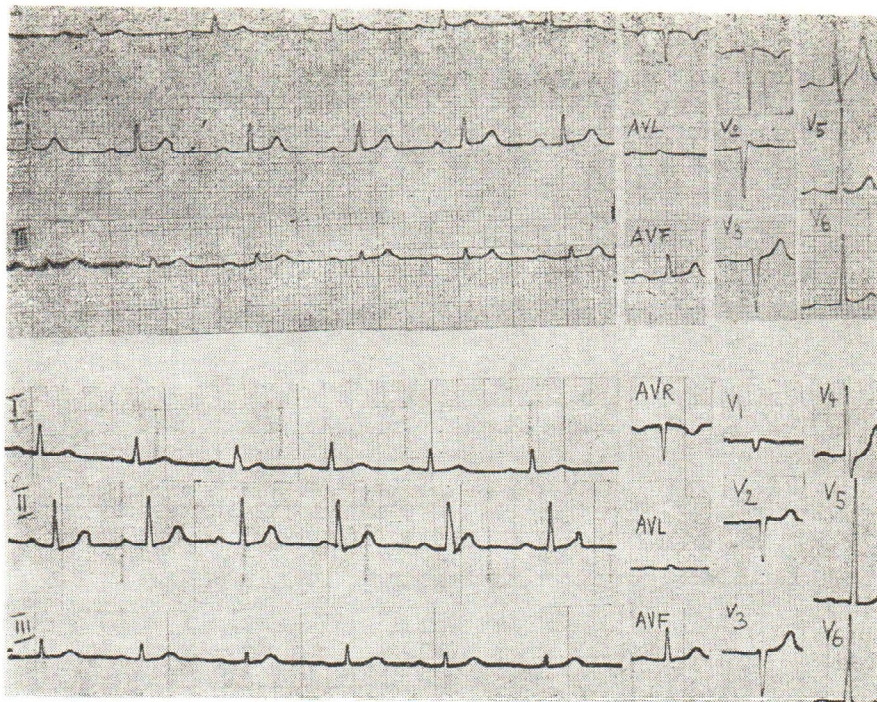


Fig. 4. Atrioventricular block I degree ( $PQ = 0.26$  s) in a man aged 35 four hours after a weever (*Trachinus draco*) sting (above), and (below) a normal curve after recovery (1 mm = 0.04 s)

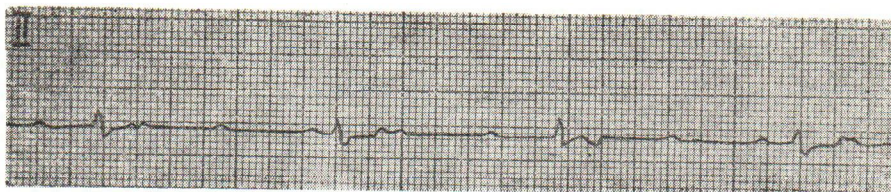


Fig. 5. The electrocardiogram of a guinea pig intoxicated with weever venom shows, 10 hours later, a total atrioventricular block with a bradycardia of 86/min (lead  $D_1$ ; 1 mm = 0.02 s)

## DISCUSSION

Venoms of various animals do not act on the cardiovascular system to an equal extent or in a similar manner. It is evident that the venom of *Latrodectus* provokes a number of changes in the ECG, affecting the frequency, P-wave, PQ-interval, QRS complex, ST-segment, T-wave and QT-interval. The high P in II and III leads could, perhaps, be explained by the strain of the right atrium; in latrodectism spasm of the pulmonary arterioles and bronchospasm may occur (4).

The prolongation of the QTc-interval along the lowered ST-segment might reflect changes in the levels of electrolytes; the flattening of T-waves may be due to changes in the coronary circulation. The notorious feeling of oppression in the chest and pavor mortis during latrodectism perhaps also speak in favour of this.

Some scorpion venoms may be of special interest to cardiologists, since they can provoke a toxic myocarditis. They may provoke hypoxia of the myocardium and an increase in tension in the vessels within the myocardium (16). The effect of the venom on the sympathetic system increases the level of catecholamines in the circulation (16, 17). *Poon-King* in 1963, described the clinical picture and ECG changes in 45 patients stung by *Tityus trinitatis* and concluded that a toxic myocarditis developed (18). *Braun* and co-workers (16) observed ECG changes similar to myocardial infarction following the sting of *Buthus quinquestratus*; they were of the opinion that these could be provoked by an increased secretion of catecholamines.

In reality, *Hymenoptera* are undoubtedly the medically most important venomous animals due to their ubiquity and number and also owing to the fact that a relatively large number of individuals are sensitive to their toxins. Although the etiological factors of death or severe signs are usually not of cardiac nature, ECG changes sometimes similar to myocardial infarction (19) were described in patients.

The venom of the weeverfish acts most characteristically upon atrioventricular conduction. This conduction was involved in 5.0% of all 118 tracings taken. Similarly, although to a lesser extent, the venom of the Adriatic scorpionfishes also has an effect on the ECG.

Our own experience with the action of the venom of stingrays on the cardiovascular system is scarce, since six cases only were treated. However, the research of *Russell* and co-workers (20) showed that the toxin of the American species *Urolophus halleri* had a deleterious effect on the cardiovascular system of mammals, provoking atrioventricular blocks of various degrees, changing the ST-segment and T-waves, producing a heterotopic rhythm, and causing cardiac arrest.

Some animals having a very toxic venom, such as *Vipera ammodytes ammodytes* inject large quantities but the ECG does not usually show major changes.



It may therefore be concluded that some animal venoms have a specific effect on the heart which is evidenced in ECG changes. On the other hand, venoms of some very toxic animals usually do not provoke ECG changes. The ECG patterns provoked by various animal venoms are different, due to the influence of their component fractions on certain parts of the heart. The study of ECG tracings following poisonings by animal venoms may give important clues on the pathophysiology of their activities.

Sometimes intoxications by animal venoms produce acute medical emergencies and sudden deaths may occur, so that knowledge of the effects of animal venoms on the heart and ECG, has a practical application.

#### ACKNOWLEDGEMENT

I am indebted to Professor Findlay E. Russell, M. D., Ph. D. Los Angeles, USA for his very useful suggestions.

#### Literatura

1. Vellard, J.: Le venin des araignées, Masson et Cie, Paris, 1936.
2. Maretić, Z.: Toxicon, 1 (1963) 127.
3. Maretić, Z.: Araneizam, Thesis, Medical Faculty, University of Zagreb, Zagreb, 1959.
4. Maretić, Z., Lebez, D.: Araneism. With Special Reference to Europe, National Library of Medicine, Bethesda — Nolit, Beograd, 1979.
5. Maretić, Z., Levi, H. W., Levi, L. R.: Toxicon, 2 (1964) 149.
6. Maretić, Z., Homadovski, J., Razbojnikov, S., Brečević, V.: Med. Klin., 52 (1957) 1950.
7. Maretić, Z.: Venom of an East African Orthognath Spider, In: Animal Toxins, F. E. Russell, P. R. Saunders, Eds., Pergamon Press, Oxford — New York, 1967, p. 23.
8. Maretić, Z., Žunić, I.: Med. jadert., 2 (1970) 5.
9. Hadži, J.: Naše škorprije kao otrovnice, Lij. vjes., 53 (1931) 261.
10. Lebez, D., Maretić, Z., Ladavac, J., Meden, M.: *Mesobuthus gibbosus* — A Potentially Dangerous European Scorpion, 8. Internat. Arachnologen-Kongress, Verhandlungen, Wien 1980, p. 187.
11. O'Connor, R., Peck, M. L.: Venoms of *Apidae*, In: Arthropod Venoms, S. Bettini, Ed., Springer Verlag, Berlin-Heidelberg-New York, 1978, p. 622.
12. Edery, H., Ishay, J., Gitter, S., Joshua, H.: Venoms of *Vespidae*, In: Arthropod Venoms, S. Bettini, Ed., Springer Verl., Berlin-Heidelberg-New York, 1978, p. 715.
13. Parrish, H. M.: Am. J. Med. Sci., 245 (1963) 129.
14. Russell, F. E., Emery, J. A.: Ann. N. Y. Acad. Sci., 90 (1960) 805.
15. Maretić, Z., Maržan, B.: O otrovanjima izazvanim ribama Jadrana, Medicina, 7 (1970) 167.
16. Braun, K., Stern, S., Werkson, S.: Isr. J. Med. Sci., 5 (1969) 853.
17. Gueron, M., Yaron, R.: Chest, 57 (1970) 156.
18. Poon-King, T.: Brit. Med. J., 1 (1963) 374.
19. Kaiser, E., Michl, H.: Biochemie der tierischen Giften, F. Deuticke Verl., Wien, 1958, p. 29.
20. Russell, F. E., Barrit, W. C., Fairchild, M. D.: Proc. Exp. Biol. Med., 96 (1957) 634.

*Sažetak*

ELEKTROKARDIOGRAFSKE PROMJENE NAKON UJEDA I UBODA  
OTROVNIH ŽIVOTINJA

Prikazuje se djelovanje nekih životinjskih otrova na elektrokardiogram bolesnika i pokusnih životinja. Kod latrodektizma ljudi opažala se sinus bradikardija, visoki P valovi u II i III odvodu, niski T valovi i produženi QT interval. Kod intoksiciranih zamoraca mogao se vidjeti Wenckebachov fenomen. Negativni T-valovi, kao i atrioventrikularni blokovi I stupnja bili su nazočni kod zamoraca uslijed djelovanja otrova pauka *Steatoda paykulliana*, kao i *Pterinochilus sp.* Otrov škorpiona *Mesobuthus gibbosus* izazivao je u zamoraca sinus bradikardiju, atrioventrikularnu disocijaciju i Wenckebachov fenomen, te podignute ST-intervale. Nakon uboda opnokrilaca zabilježili smo u bolesnika lutanje centra vodiča, negativne T-valove i ventrikularnu tahikardiju sporog tipa (slow ventricular tachycardia). Ubodi morskog pauka i škarpine izazivali su u nekih bolesnika atrioventrikularne blokove I stupnja. Iza uboda, odnosno ujeda smeđe vlasulje, meduze *Pelagia noctiluca*, skolo-pendra, obada i poskoka nisu zapažene značajnije elektrokardiografske promjene.

*Medicinski centar, Pula*

*Primljeno 6. VII 1982.*