

## INTRAOPERATIVE FROZEN SECTION ANALYSES IN OF THE CENTRAL NERVOUS SYSTEM AND PITUITARY GLAND PATHOLOGY

Jasna Talan-Hranilović, Majda Vučić, Monika Ulamec and Mladen Belicza

Ljudevit Jurak University Department of Pathology, Sestre milosrdnice University Hospital, Zagreb, Croatia

**SUMMARY** – In spite of sophisticated preoperative imaging techniques, intraoperative frozen biopsies continue to play an important role in rapid diagnosis of the central nervous system (CNS) and pituitary gland tumors and lesions. The aim of the study was to assess the frequency and accuracy of intraoperative frozen sections in CNS and pituitary gland tumors and lesions during the 1998-2004 period. During the study period, there were a total of 1385 (45.3% of all CNS biopsies) CNS and 122 (47.3% of all pituitary sections) pituitary gland frozen sections. The accuracy rate of intraoperative frozen section diagnosis was 92.4% for CNS and 95.9% for pituitary gland. These results supported the reliability of intraoperative frozen sections in neurosurgery.

**Key words:** *Intraoperative frozen biopsy; Central nervous system; Pituitary gland*

### Introduction

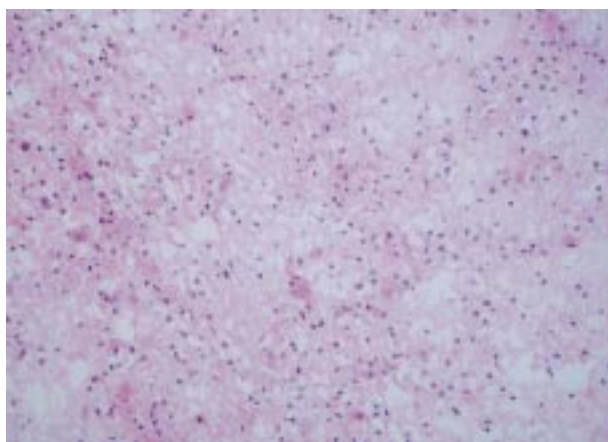
The preoperative diagnosis of the central nervous system (CNS) tumors and lesions has become increasingly refined over recent years, due to the introduction of sophisticated imaging techniques<sup>1</sup>. However, it must be kept in mind that even most sophisticated preoperative investigations may prove misleading and that the request for intraoperative frozen section can be of value to the surgeon rather than just a waste of time. Neurosurgical frozen sections should answer three questions: Is the specimen a tumor tissue? Is it benign or malignant? What is its histologic type?<sup>2</sup> In pituitary surgery there is little need of intraoperative consultation if pituitary hormone hypersecretion has been serologically proved and if there is radiologic evidence of the tumor<sup>3</sup>. Surgeons have suggested that the role of intraoperative consultation in the management of pituitary tumors is restricted to distinguishing pituitary adenomas from other lesions in the

sellar region (such as meningiomas, germinomas, cranio-pharyngeomas, metastatic tumors, and different types of inflammatory lesions)<sup>4</sup>. The aim of this study was to assess the frequency and accuracy of intraoperative frozen sections in CNS and pituitary gland tumors and lesions.

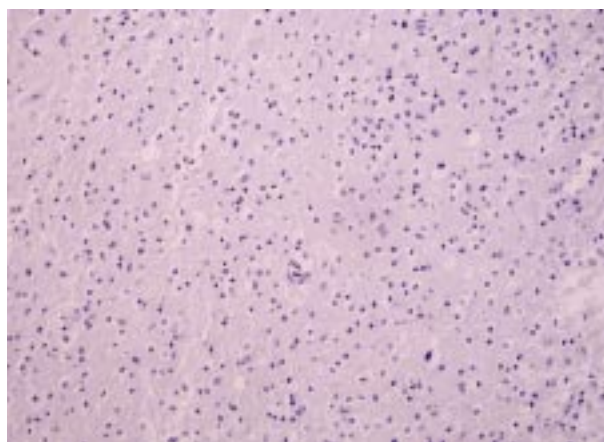
### Methods

Surgical biopsies excised at University Department of Neurosurgery were the source of data. Pathologic reports were entered in the Thanatos computer registry and analyzed retrospectively for the 1998-2004 period. Frozen sections were performed on the Shandon Cryostat model OT frozen at -17 °C for CNS and -15 °C for pituitary gland tumors and lesions. For rapid freezing, pretreatment with the New Envi-Ro-Tech refrigerant freezer spray (Thermo Shandon) was used. The spray speeds up freezing and minimizes ice artifacts, which is especially important for the central nervous tissue glial tumors that develop considerable ice artifacts<sup>5</sup>. Intraoperative sections were stained with rapid H&E method. Paraffin biopsies were additionally treated with histochemical and immunohistochemical stains (Figs. 1-6). We analyzed the prevalence of

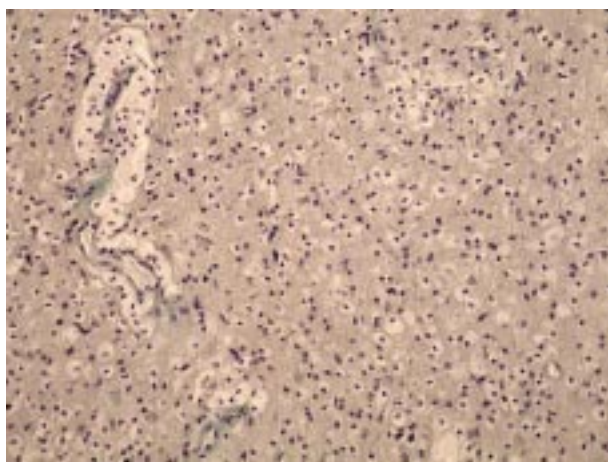
Correspondence to: *Majda Vučić M.D.*, Ljudevit Jurak University Department of Pathology, Sestre milosrdnice University Hospital, Vinogradska c. 29, HR-10000 Zagreb, Croatia  
E-mail: mvucic@kbsm.hr



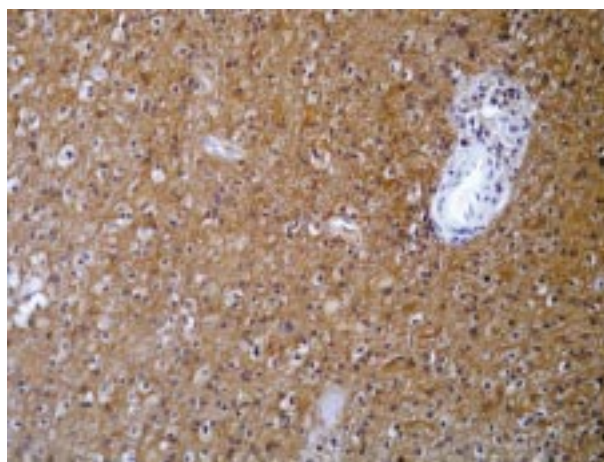
*Fig. 1. Oligoastrocytoma: (A) intraoperative frozen biopsy (H&E, X200);*



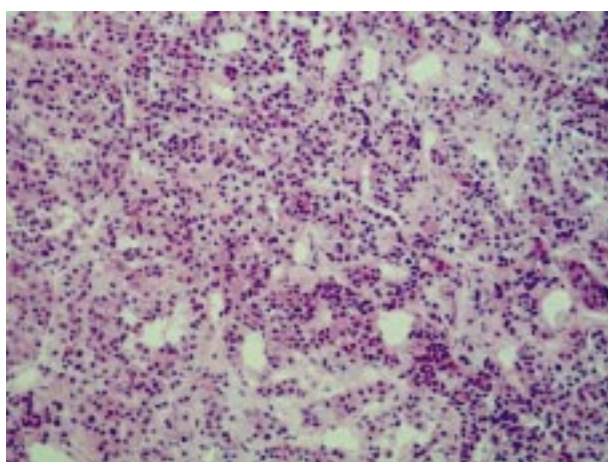
*Fig. 1. B) paraffin biopsy (H&E X200).*



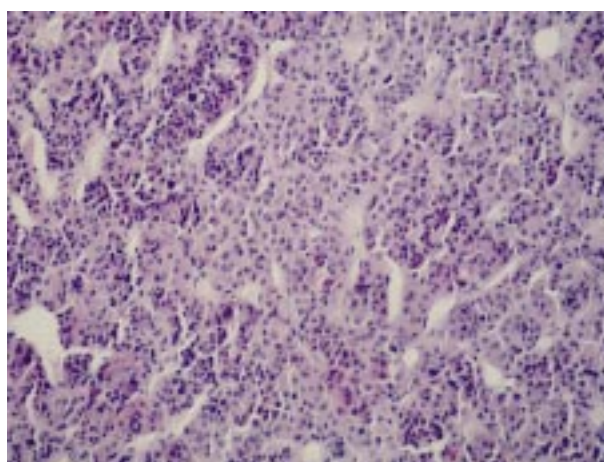
*Fig. 2. Oligoastrocytoma; paraffin biopsy (Mallory, X200).*



*Fig. 3. Oligoastrocytoma; paraffin biopsy (GFAP immunoreactivity, X400).*



*Fig. 4. Pituitary gland adenoma: (A) intraoperative frozen biopsy (H&E, X200);*



*Fig. 4. B) paraffin biopsy (H&E X200).*



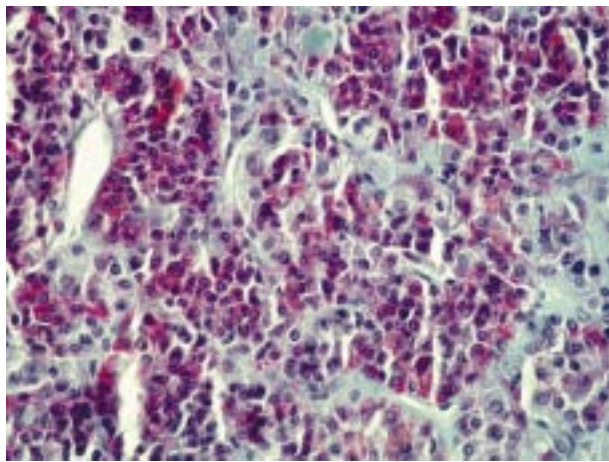


Fig. 5. Pituitary gland adenoma; paraffin biopsy (Mallory, X400).

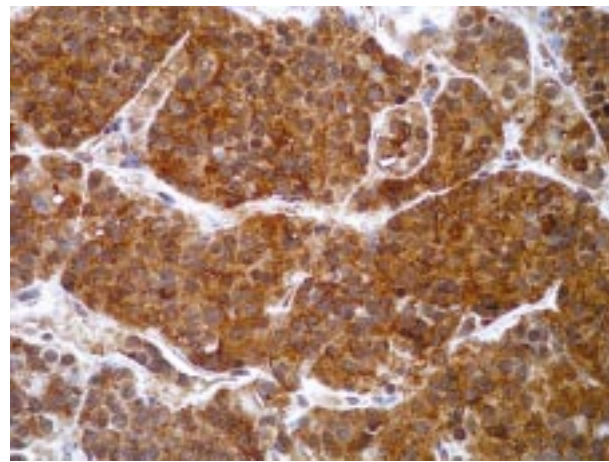


Fig. 6. Pituitary gland adenoma; paraffin biopsy (prolactin immunoreactivity, X400).

frozen sections in total biopsy material of CNS and pituitary gland tumors and lesions. Agreement between frozen and paraffin section diagnosis was also studied.

## Results

During the 6-year study period, there were a total of 1507 intraoperative biopsies of the CNS and pituitary gland, i.e. 1385 (45.3% of all CNS biopsies) CNS frozen sections and 122 (47.3% of all pituitary sections) pituitary frozen sections. The survey showed the prevalence of intraoperative frozen sections in the total number of CNS biopsies to range from 42.6% to 47.1% (ratio 1:1.3 to 1:1.1) during the 6-year period (Fig. 7). The prevalence of intraoperative frozen sections in the total number of pituitary surgery ranged from 21.2% to 35.2% (ratio 1:3.7 to 1:3) during the same period (Fig. 8).

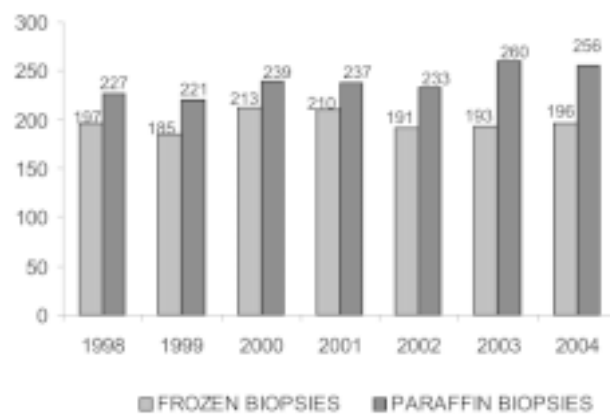


Fig. 7. Frequency of central nervous system (pituitary gland excluded) intraoperative frozen and paraffin biopsies during the 1998-2004 period.

Agreement between intraoperative and paraffin section diagnosis was 92.4% for CNS lesions and 95.9% for pituitary lesions.

## Discussion and Conclusion

Cryostat sections continue to play an important role in the rapid diagnosis of CNS and pituitary tumors and lesions. In practice, the frequency of cryostat sections depends on personal preference and experience of the neurosurgeon (especially in pituitary surgery)<sup>6</sup>. There are few literature data on the intraoperative frozen section analysis of CNS and pituitary gland. However, cytologic touch intraoperative analyses are more frequent in the literature. There are no intraoperative techniques that can really be effective without full knowledge of clinical circumstances and radioimaging techniques. Intraopera-

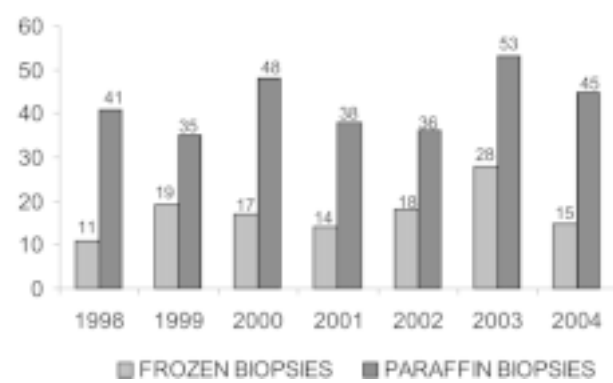


Fig. 8. Frequency of pituitary gland intraoperative frozen and paraffin biopsies during the 1998-2004 period.

tive biopsy specimens from each patient should be accompanied by a request form, which summarizes the following clinical features: age, sex, nature and duration of symptoms, relevant family history, details of previous neurosurgery, previous neuropathologic diagnosis and treatment, neuroradiology – side and approximate size of lesion, contrast enhancement on CT and MRI scans, characteristics of tumor margins, relative tissue density, and effect on adjacent structures including edema. Relevant intraoperative neurosurgical findings should also be recorded: precise location and size of the lesion, appearance of the lesion and its margins, presence of necrosis, hemorrhage, calcification or cysts, and associated lesions<sup>1,2</sup>. The process of freezing is used to remove water from the frozen tissue by sublimation of the solid phase at a low temperature and to provide a hardened matrix for sectioning<sup>7</sup>. In practice, however, the process of transforming water into ice can dramatically alter the physical and chemical structure of cells and tissue. These effects are collectively known as ice crystal artifacts. During freezing of the sample the objective is to limit ice crystal formation as much as possible by controlling the cooling rate. This form of artifact is avoided by using the rapid tissue freezing method (appropriate temperature, freezer spray) and selection of pieces of tissue that are not too large to disable rapid freezing. Other specific problems considering frozen sections mainly occur while cutting sections with the microtome: for example, dispersing of the blade produces parallel lines in the section and the thickness of the section may be somewhat variable<sup>8</sup>. Additional problems of interpretation in pituitary surgery are due to the small size of samples obtained by transsphenoidal surgery. To avoid drying damage, rapid handling of the tissue is essential for these small fragments<sup>9,10</sup>. In our analyses, the rate of accuracy of intraoperative frozen biopsies was greater than 90% for both CNS (92.4%) and pituitary (95.9%) tumor and lesions due to optimal

freezing, specimen processing and experience in interpretation. These results demonstrated the reliability of intraoperative frozen sections in neurosurgery and pituitary surgery. A reliable intraoperative histologic diagnosis will help the surgeon remove the lesion selectively to preserve endocrine function in pituitary surgery<sup>11</sup>. This article contributes to the knowledge of importance and challenges of intraoperative frozen sections in neurosurgery.

## References

1. MOSS TH, NICOLL JAR, IRONSIDE JW. Intraoperative diagnosis of CNS tumors. London: Arnold, 1997:1-67.
2. REGRAGUI A, AMARTI RA, MAHER M, EI KHAMLICH A, SAIDI A. Accuracy of intraoperative diagnosis in central nervous system tumors: report of 1315 cases. *Neurochirurgie* 2003;49:67-72.
3. HAR-el G, RAO C, SWEANSON RM, ABDU AF, MILHRAT TH. Frozen section in pituitary surgery. *J Neurol Neurosurg Psychiatry* 1997;63:554-6.
4. ASASL. Intraoperative consultation in tumors of the pituitary gland. 3<sup>rd</sup> ed. Washington: AFIP, 1998:37-9.
5. DUBOCHET J, LEPAULT J, FREEMAN R, BERRIMAN JA, HOMO JC. Electron microscopy of frozen and aqueous solutions. *J Microsc* 1982;128:219-37.
6. RASMUSSEN DH. Ice formation in aqueous systems. *J Microsc* 1982;128:167-74.
7. DOWELL LG, RINFRET AP. Low temperature forms of ice as studied by x-ray diffraction. *Nature* 1960;158:1142-8.
8. BARNARD T. Rapid freezing techniques and cryoprotection of biomedical specimens. *Scanning Microsc* 1987;1:1224-7.
9. ADELMAN LS, POST KD. Intraoperative frozen section technique for pituitary adenomas. *Am J Surg Pathol* 1979;3:173-5.
10. FARMER P, DHER JH, COOPER P. Frozen section diagnosis in neuropathology: usefulness and accuracy. *Acta Neuropathol Exp Neurol* 1981;40:349.
11. SAVARGAONKAR P, FARMER PM. Utility of intraoperative consultation for the diagnosis of central nervous system lesions. *Ann Clin Lab Sci* 2001;31:133-9.

Sažetak

ANALIZA INTRAOPERACIJSKIH SMRZNUTIH REZOVA BIOPSIJA SREDIŠNJEGA ŽIVČANOG SUSTAVA I HIPOFIZE

*J. Talan-Hranilović, M. Vučić, M. Ulamec i M. Belicza*

Intraoperacijske smrznute biopsije i dalje, unatoč sofisticiranim prijeoperacijskim radiološkim tehnikama, imaju važnu ulogu u brznoj dijagnostici tumora središnjega živčanog sustava (SŽS) i hipofize. Cilj ovoga rada bio je odrediti učestalost i pouzdanost intraoperacijskih smrznutih biopsija za tumore i promjene SŽSa i hipofize u razdoblju od 1998. do 2004. godine. Ukupan broj smrznutih biopsija SŽSa u analiziranom razdoblju bio je 1385 (45,3% svih biopsija SŽSa), dok je ukupan broj smrznutih biopsija hipofize bio 122 (47,3% svih biopsija hipofize). Prema našim rezultatima pouzdanost dijagnoza intraoperacijskih smrznutih biopsija je 92,4% za SŽS, odnosno 95,9% za hipofizu. Ovi rezultati potvrđuju važnost intraoperacijskih smrznutih biopsija u neurokirurgiji.

Ključne riječi: *Intraoperacijske smrznute biopsije; Središnji živčani sustav; Hipofiza*