

## Preemptive kidney transplantation from living donor

### *Preemptivna transplantacija bubrega od živog darivatelja*

Dean Markić, Josip Španjol, Kristian Krpina, Antun Gršković, Dražen Rahelić, Mauro Materljan, Marin Trošelj, Martina Pavletić Peršić, Lidija Orlić, Ivan Bubić, Andrea Arefijev, Sanjin Rački\*

---

#### Summary

Pre-emptive kidney transplantation is the type of transplantation that is performed before starting dialysis. It allows a better quality of life to the patient and significant reduction of costs in comparison with dialysis, and also is connected with higher survival rate of graft and patient. We present a 26-year-old patient diagnosed with chronic kidney disease (CKD) due to IgA nephropathy. His kidney function, despite of immunosuppressive therapy, gradually decreased in time but an onset of acute enterocolitis has lead to significant and permanent deterioration of kidney function with the forthcoming need for renal replacement therapy. His mother was accepted as a living kidney donor. The left kidney of the mother was transplanted to the right iliac fossa of the patient. The operation went without any complications. The postoperative course was uneventful with induction therapy with monoclonal antibody against interleukin 2 receptor and standard triple immunosuppressive therapy consisting of corticosteroid, mycophenolat mofetil and tacrolimus. One year after the transplantation, the patient has a good functioning kidney transplant without any surgical or immunological complications. Conclusively, pre-emptive kidney transplantation is an effective treatment for patients with end-stage renal disease and it should be recommended to all patients where this type of treatment is possible.

**Key words:** pre-emptive transplantation, living donor, chronic kidney disease, IgA nephropathy

---

#### Sažetak

Preemptivna transplantacija bubrega je vrsta transplantacije koja se radi prije početka dijalitičkog liječenja. Ona omogućuje bolju kvalitetu života i značajno smanjenje troškova liječenja u odnosu na dijalizu, a također je uz nju vezano bolje preživljenje, kako presatka, tako i bolesnika. Prikazali smo 26-godišnjeg bolesnika koji ima kroničnu bubrežnu bolest (KBB) uzrokovanu IgA nefropatijom. Bubrežna funkcija bolesnika je unatoč primijenjenoj imunosupresivnoj terapiji postupno slabila tijekom vremena, ali je jedan napadaj akutnog enterokolitisa doveo do značajnog i trajnog slabljenja bubrežne funkcije. Kod bolesnika se tada počelo razmišljati o nadomještanju bubrežne funkcije. Bolesnikova majka je prihvaćena kao živi darivatelj. Lijevi bubreg majke je transplantiran u desnu ilijačnu jamu. Operacija i rani postoperacijski tijek prošli su bez komplikacija. Postoperacijski, a kao indukcijaska terapija, koristila su se monoklonska protutijela protiv interleukina 2 sa standardnom trojnom imunosupresivnom terapijom koja se sastojala od kortikosteroida, mikofenolat-mofetila i takrolimusa. Godinu dana nakon transplantacije bolesnik ima dobro funkcionirajući presadak bez ikakvih kirurških ili imunoloških komplikacija. Zaključno može se reći da je preemptivna transplantacija bubrega efikasna metoda liječenja pacijenta s kroničnim bubrežnim zatajenjem i treba biti preporučena u svih bolesnika u kojih se može učiniti transplantacija.

**Ključne riječi:** preemptivna transplantacija, živi darivatelj, kronična bubrežna bolest, IgA nefropatija.

*Med Jad 2016;46(1-2):43-46*

---

\* **University Hospital Rijeka, Department of Urology, Rijeka, Croatia** (assist. prof. Dean Markić, MD, assist. prof. Josip Španjol, MD, Kristian Krpina, PhD, MD, Antun Gršković, MD, Dražen Rahelić, MD, Mauro Materljan, MD, Marin Trošelj, MD); **Department of Nephrology, Dialysis and Kidney Transplantation** (Martina Peršić Pavletić, MD, assist. prof. Lidija Orlić, MD, full prof. Ivan Bubić, MD, full prof. Sanjin Rački, MD); **Faculty of Medicine, University of Rijeka, Rijeka, Croatia** (Andrea Arefijev, student)

Correspondence address / *Adresa za dopisivanje:* Dean Markić, MD, PhD, Assist. Prof. of Urology, Department of Urology, University Hospital Rijeka, Tome Strižića 3, 51 000 Rijeka; Tel.: ++385 51 407 493; Fax: ++385 51 218 861; E-mail: dean.markic@ri.htnet.hr

Primljeno / *Received* 2015-11-16; Ispravljeno / *Revised* 2015-12-23; Prihvaćeno / *Accepted* 2016-01-22.

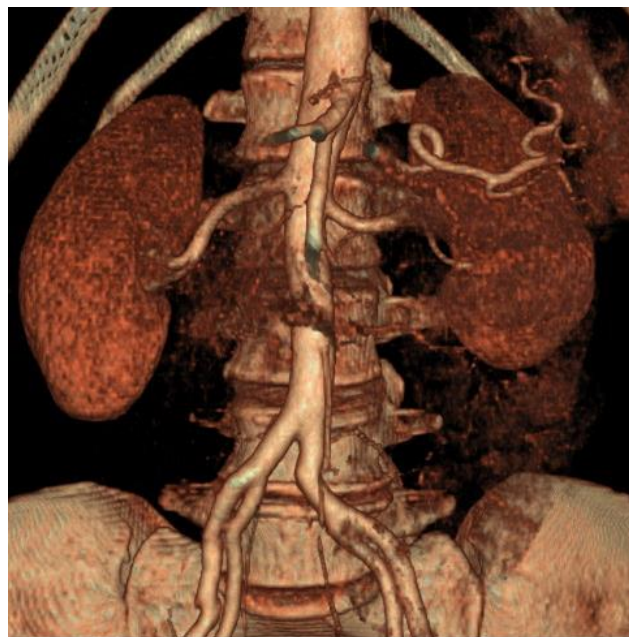
## Introduction

End-stage renal disease (ESRD) is a significant health problem worldwide with high mortality and morbidity rate. Nowadays, patients with ESRD have three types of treatments available: haemodialysis, peritoneal dialysis and kidney transplantation. According to many studies, transplantation is the best option for long term survival. New and more effective immunosuppressive drugs, growing experience in transplantation surgery have made kidney transplantation the best treatment option.<sup>1</sup> Every patient with ESRD is also a candidate for pre-emptive transplantation. Pre-emptive kidney transplantation (PKT) is done before the beginning of dialytic treatment. Current opinions support chronic kidney disease (CKD) patients to receive PKT when their glomerular filtration rate (GFR) is 15 ml per minute or less and preparation for transplantation should be started at the time of diagnosing chronic kidney disease. Recent studies show that PKT has better outcomes than nonpreemptive kidney transplantation (NPKT).<sup>2,3</sup> The long-term patient and graft survival are two major motivators for choosing PKT.<sup>1</sup> The following could be a benefit in avoiding the cardiovascular side effects of long-term dialysis treatment and lower costs in the long term. Lower incidence of hypertension and infection and less acute rejection episode rates in PKT patients are probably the main reasons for these results.<sup>1</sup> PKT also allows the prevention of complications associated with haemodialysis, higher haemoglobin levels before transplantation, less cardiovascular disease and coronary artery calcification rates, better compliance to immunosuppressive therapy and better quality of life. We will present a patient from our centre in which PKT was performed.

## Case report

Our patient was a 26-year-old male diagnosed with CKD due to IgA nephropathy. The disease was diagnosed in 2009 when the first kidney biopsy was done due to subnephrotic range proteinuria with preserved kidney function. Therapy with angiotensin converting enzyme inhibitor was started after which he was lost to follow up until three years later when he had kidney function deterioration. We performed a second biopsy that confirmed IgA nephropathy with mesangioproliferative glomerulonephritis, according to the Oxford classification of IgA nephropathy (2009) M1, E1, S1, T1.<sup>4</sup> We started treatment with pulsative corticosteroid therapy and had to stop after the first dose due to acute psychosis which the patient developed. He was then put on prednisolone in

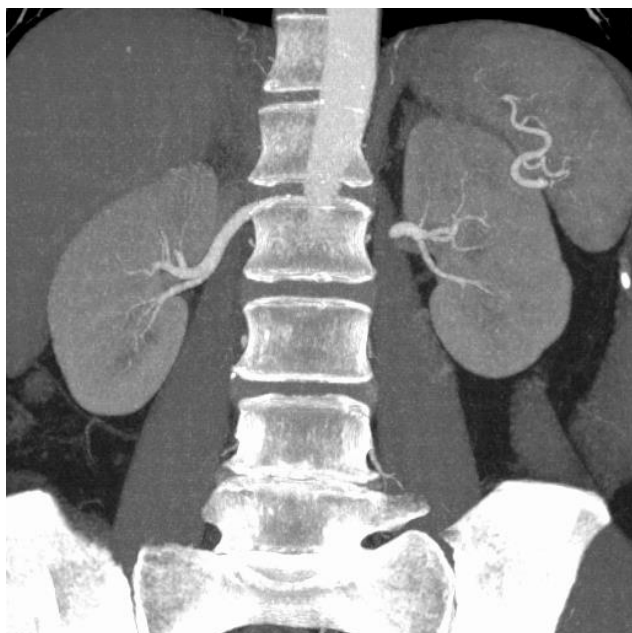
standard doses with mycophenolate-mofetil. He was discharged with proteinuria of 0.98 g/L and serum creatinine of 216  $\mu\text{mol/L}$ . In spite of the therapy, proteinuria was progressing with slow deterioration of kidney function. An onset of acute enterocolitis lead to significant and permanent loss of kidney function. We started preparations for PKT from a living donor (mother) who was accepted as donor after standard protocol investigations were performed. Both kidneys were similar in morphology and the left kidney was chosen (Picture 1 and 2).



Picture 1 Computerized tomography reconstruction of renal vasculature of donor kidneys

*Slika 1. Rekonstrukcija krvnih žila bubrega donorskih bubrega, uz pomoć kompjuterizirane tomografije*

In March 2014, after standard preparation including induction therapy with monoclonal antibody against interleukin 2 receptor, the left kidney of the mother was transplanted into the right iliac fossa of the patient. Warm ischemia lasted 30 minutes, without cold ischemia, and the whole operation lasted for 140 minutes. The operation went through without any complications. Five days after the operation, the drain was removed, and seven days later the urinary catheter was removed. The postoperative course was uneventful with standard triple immunosuppressive therapy consisting of corticosteroid, mycophenolat mofetil and tacrolimus. One year after the transplantation, the patient has good functioning kidney transplant with normal creatinine level and without any surgical or immunological complications.



Picture 2 Computerized tomography of renal vasculature of donor kidneys with contrast  
*Slika 2. Kompjuterizirana tomografija prikazuje vaskularne strukture donorskog bubrega*

### Discussion

Renal transplantation is the best type of treatment for the end stage chronic kidney disease in all patients where this type of treatment of possible. The survival rate of the patient and graft are better compared to dialytic treatment. Choosing PKT as treatment may reduce morbidity and mortality of patients with chronic kidney failure. Studies have shown that prolonged haemodialysis duration may be a cause of cardiovascular morbidities even if the transplantation was successful.<sup>5</sup> Mange and Weir showed a 52% decrease of graft loss for PKT recipients after the first year of transplantation comparing with the NPKT recipients in 8481 patients.<sup>6</sup> In a retrospective study by Kasike et al. similar results in favour of PKT were reported.<sup>7</sup> Recent studies show evidence that PKT has advantages for patient and transplant survival.<sup>8</sup> Avoidance of dialysis-associated comorbidities, diminished immune response and cardiovascular complications are the main benefits of PKT.<sup>9</sup>

IgA nephropathy was first described by Berger and Hinglais in 1968.<sup>10</sup> IgA nephropathy is the most common primary glomerulonephritis with variable frequency in different parts of the world. Primary IgA nephropathy is an immune-complex-mediated glomerulonephritis defined immunohistologically by the presence of glomerular IgA deposits accompanied by

a variety of histopathologic lesions. Although primary IgA nephropathy receives the most attention, many other diseases are also associated with glomerular IgA deposits. The most common of these is Schönlein–Henoch purpura. This condition may indeed be indistinguishable from primary IgA nephropathy and may represent a systemic form of the disease process.

Although primary IgA nephropathy was considered a benign condition for many years, it is now clear that a large number of cases eventually progress to renal failure. Indeed, IgA nephropathy is the main cause of end-stage renal disease in patients with primary glomerular disease who require renal-replacement therapy.<sup>10</sup>

Clinical presentation ranges from asymptomatic hematuria to rapidly progressive glomerulonephritis. Most commonly, patients present with macroscopic hematuria or microscopic hematuria and/or mild proteinuria. Nephrotic-range proteinuria is uncommon and can be seen at different stages of the disease. About 30% of patients with IgA nephropathy are at risk to reach end stage renal disease (ESRD) after 10 years of progression of the disease. In patients with active and progressive IgA nephropathy (hematuria, proteinuria >1 g/day, increasing serum creatinine), the use of corticosteroids is usually associated with a decrease of urinary protein excretion and lower risk of progression to ESRD.<sup>11</sup>

One of the problems of patients suffering with IgA nephropathy is recurrence of disease after transplantation. The rate of return is, according to some studies, relatively high with the incidence between 12 and 53%.<sup>12,13</sup> Possible risk factors for recurrence include the following: living-related-donor kidney, specific human leukocyte antigen (HLA) alleles in recipient including HLA-B35, HLA-DR4, HLA-B8, HLA-DR3, good HLA match between donor and recipient and high IgA concentration. The risk of recurrence may be higher among recipients of living-related-donor kidneys, compared with deceased-donor kidneys. The causes of return of IgA nephropathy have still not been investigated enough and there is need for additional studies, basic science and clinical science to differentiate risks for it, so it might be predicted in the future. Our patient is very young and needs good follow up so the renal failure caused by recurrence of the disease could be avoided or postponed.

Conclusively, we can say that PKT is an effective method in treating patients with ESRD and it should be considered as an option in all patients. The possibility of return of the primary kidney disease must be discussed before transplantation, especially with those having IgA nephropathy due to its large proportion of return in graft.

### References

1. Sayin B. Preemptive kidney transplantation. Ortiz J, Andre J, eds. Understanding the complexities of kidney transplantation. Publisher: InTech, 2011 ISBN 978-953-307-819-9, Available from: <http://www.intechopen.com/books/understanding-the-complexities-of-kidney-transplantation/preemptive-kidney-transplantation>.
2. Friedewald JJ, Reese PP. The kidney-first initiative: what is the current status of pre-emptive transplantation? *Adv Chronic Kidney Dis.* 2012; 19:252-6.
3. Piskin T, Unal B, Eroglu A. Pre-emptive kidney transplantation: the initial experience of a single centre. *Transplant Proc.* 2015;47:1382-4.
4. Cattran DC, Coppo R, Cook HT et al. Working Group of the International IgA Nephropathy Network and the Renal Pathology Society. The Oxford classification of IgA nephropathy: rationale, clinicopathological correlations, and classification. *Kidney Int.* 2009;76:534-45.
5. Mange KC, Joffe MM, Feldman HI. Effect of the use or non-use of long-term dialysis on the subsequent survival of renal transplants for living donors. *N Eng J Med.* 2001;344:726-31.
6. Mange KC, Weir MR. Pre-emptive renal transplantation: why not? *Am J Transplant.* 2003;3: 1336-40.
7. Kasiske BL, Snyder JJ, Matas AJ, Ellison MD, Gill JS, Kausz AT. Pre-emptive kidney transplantation: the advantage and the advantaged. *J Am Soc Nephrol.* 2002;13:1358-64.
8. Son YK, Oh JS, Kim SM, Jeon JM, Shin YH, Kim JK. Clinical outcome of pre-emptive kidney transplantation in patients with diabetes mellitus. *Transplant Proc.* 2010;42:3497-502.
9. Sayin B, Colak T, Tutal E, Sezer S. Comparison of pre-emptive kidney transplant recipients with nonpre-emptive kidney recipients in single center: 5 years of follow-up. *Int J Nephrol Renovasc Dis* 2013;6:95-9.
10. Donadio JV, Grande JP. IgA nephropathy. *N Engl J Med.* 2002;347:738-48.
11. Ioanna R, Pantelitsa K, Sinodi Z, Miltiades G, Dimitrios G, Christos I. Corticosteroids in IgA nephropathy: Daily oral or intravenous pulses followed by every other day oral administration. *Saudi J Kidney Dis Transpl.* 2015;26:804-5.
12. Kamal Aziz A, Mousson C, Berthoux F, Ducloux D, Chalopin JM. Renal transplantation outcome in selected recipients with IgA nephropathy as native disease: a bicentric study. *Ann Transplant.* 2012; 17:45-51.
13. Chandrakantan A, Ratanapanichkich P, Said M, Barker CV, Julian BA. Recurrent IgA nephropathy after renal transplantation despite immunosuppressive regimens with mycophenolate mofetil. *Nephrol Dial Transplant.* 2005;20:1214-21.